

RESEARCH COMMUNICATION

Inhibitory Effects of Crude α -Mangostin, a Xanthone Derivative, on Two Different Categories of Colon Preneoplastic Lesions Induced by 1, 2-dimethylhydrazine in the Rat

Viengvansay Nabandith¹, Masumi Suzui¹, Takamitsu Morioka¹, Tatsuya Kaneshiro¹, Tatsuya Kinjo¹, Kenji Matsumoto², Yukihiko Akao², Munekazu Inuma³, Naoki Yoshimi^{1*}

Abstract

The purpose of this study was to examine whether crude α -mangostin (a major xanthone derivative in mangosteen pericarp (*Garcinia mangostana*)) has short-term chemopreventive effects on putative preneoplastic lesions involved in rat colon carcinogenesis. The crude preparation was obtained by simple recrystallization of an ethylacetate extract of mangosteen pericarps. A total of 33 five-week-old male F344 rats were randomly divided into 5 experimental groups. Rats in groups 1-3 were given a subcutaneous injection of 1,2-dimethylhydrazine (DMH)(40 mg/kg body weight) once a week for 2 weeks. Starting one week before the first injection of DMH, rats in groups 2 and 3 were fed a diet containing 0.02% and 0.05% crude α -mangostin, respectively, for 5 weeks. Rats in group 4 also received the diet containing 0.05% crude α -mangostin, while rats in group 5 served as untreated controls. The experiment was terminated 5 weeks after the start. Dietary administration of crude α -mangostin at both doses significantly inhibited the induction and/or development of aberrant crypt foci (ACF) ($P < 0.05$ for 0.02% crude α -mangostin, $P < 0.01$ for 0.05% crude α -mangostin), when compared to the DMH-treated group (group 1). Moreover, treatment of rats with 0.05% crude α -mangostin significantly decreased dysplastic foci (DF) ($P < 0.05$) and β -catenin accumulated crypts (BCAC) ($P < 0.05$), to below the group 1 values. The proliferating cell nuclear antigen (PCNA) labeling indices of colon epithelium and focal lesions in groups 2 and 3 were also significantly lower than in group 1 and this effect occurred in a dose dependent manner of the crude α -mangostin. This finding that crude α -mangostin has potent chemopreventive effects in our short-term colon carcinogenesis bioassay system suggests that longer exposure might result in suppression of tumor development.

Key Words: Chemoprevention - α -mangostin - preneoplastic lesions - rat colon carcinogenesis - proliferation

Asian Pacific J Cancer Prev, 5, 433-438

Introduction

In recent decades, there has been increasing interest in the use of herbs to maintain human health, many growing in the Southern and Eastern Asian countries. One example, pericarps of *Garcinia mangostana* (GM), called mangosteen, have been in use for hundreds of years as a traditional herbal medicine for a variety of purposes, including treatment of skin infections and wounds (Mahabusarakam, 1987), or malaria infections (Likhitwitayawuid et al., 1998). Investigators have recently focused on the medical properties

of natural compounds such as a traditional Japanese or Chinese herbal medicines called Kampo that may have biological activities, including anticancer effects (Yoshimi et al., 1992; Tagami et al., 2004). It is important to identify active components of herbs and to examine their mechanisms of action in order to assess their potential for clinical use and particularly possible adverse effects. In fact, studies have been conducted to examine the anticancer activities of some types of mangosteen pericarps on human hepatoma (Ho et al., 2002), breast cancer (Moongkarndi et al., 2004) and leukemia cell lines (Matsumoto et al., 2003).

¹Tumor Pathology Division, Faculty of Medicine, University of the Ryukyus, 207 Uehara, Nishihara-cho, Okinawa 903-0215, Japan.

²Gifu International Institute of Biotechnology, 1-1 Naka-Fudogaoka, Kakamigahara, Gifu 504-0838, Japan. ³Gifu Pharmaceutical University, 5-6-1 Mitahora-higashi, Gifu 502-8585, Japan.

*Corresponding Author: Tel: (+81) -98-895-1118 Fax: (+81) - 98-895-1406, E-mail: yoshimi@med.u-ryukyu.ac.jp

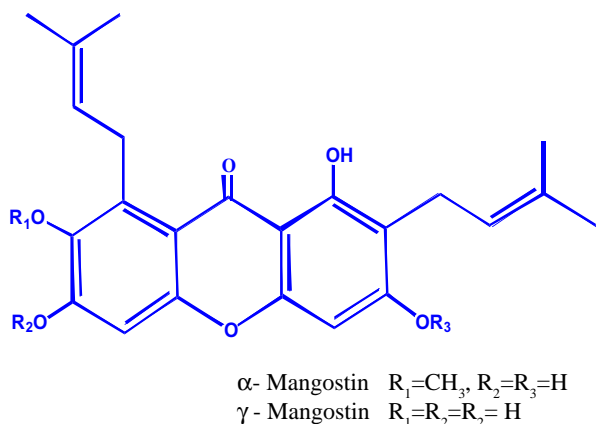


Figure 1. The Chemical Structures of α - and γ -Mangostin

Colorectal cancer is a common malignancy ranking third in frequency on a world wide basis and which causes about 500,000 deaths annually (Parkin et al., 2001). Aberrant crypt foci (ACF) are putative precursor lesions of colon carcinogenesis in rodents (Bird, 1987; Bird and Good, 2000), and these lesions are generally considered as useful preneoplastic biomarkers (Yoshimi et al., 1997). The APC/ β -catenin pathway plays a major role in the colon carcinogenesis model systems induced by a wide variety of chemical carcinogens (Suzui et al., 1999; Hirose et al., 2003; Yamada et al., 2003). Azoxymethane (AOM)-induced rat colon carcinomas have been shown to accumulate β -catenin protein in the cytoplasm and/or nuclei (Yamada et al., 2001b). Thus β -catenin accumulated crypt (BCAC) are also considered to be useful as preneoplastic biomarkers (Hirose et al., 2003). So far, there is only a limited number of studies that investigate possible chemopreventive activity of GM. Therefore, in the present study, we examined a possible short-term chemopreventive effect of crude α -mangostin on these biomarkers of colon carcinogenesis in male F344 rats.

Materials and Methods

Animals

Four weeks old male F344 rats were purchased from Shizuoka Laboratory Animal Center (Hamamatsu, Japan).

All rats were housed in wire cages (three rats/cage) with free access to tap water and a basal diet, CE-2 (CLEA Japan Inc., Tokyo, Japan), under controlled conditions of humidity ($50 \pm 10\%$), lighting (12 h light/dark cycle) and temperature ($23 \pm 2^\circ\text{C}$). Animals were quarantined for 7 days after arriving and then randomized by body weight into experimental and control groups.

Treatment

Dried and ground mangosteen pericarps were extracted with ethylacetate under reflux. The extract was concentrated under reduced pressure and stood at room temperature. The precipitated crude crystals were collected by filtration. The crude crystals were composed of α -mangostin (77.8%), γ -mangostin (15.9%), and some other unknown constituents after high-pressure liquid chromatographic analysis (Asai et al., 1995). Of these, crude α -mangostin (Fig. 1) was used for the present experiment. Experimental protocol is shown in Fig. 2. The experiments were carried out in accordance with the guidelines for animal experiments of the University of the Ryukyus. Thirty-three male F344 rats were randomly divided into five experimental groups. Rats in groups 1-3 were given subcutaneous injections of 1,2-dimethylhydrazine (40 mg/kg body weight) (DMH, Sigma Chemical Company, St. Louis, MO) once a week for 2 weeks. One week before the first injection of DMH, rats in groups 2 and 3 were fed a diet containing 0.02% and 0.05% crude α -mangostin, respectively, for 5 weeks. Rats in group 4 were fed a diet containing 0.05% crude α -mangostin. Rats in group 5 were given the basal diet alone and served as untreated controls. All rats were carefully observed and weighed weekly during the experiment. The experiment was terminated at 5 weeks after the start of the experiment and all animals were euthanized under CO_2 anesthesia. Colons were carefully removed, washed with saline, opened longitudinally, and then fixed with 10% buffered formalin.

Identification of ACF and DF

Colon tissues were stained in a 0.5% methylene blue solution for 30 s and immediately washed with distilled water, and then placed on a glass plate with the mucosal surface up. Using a light microscope at a magnification of

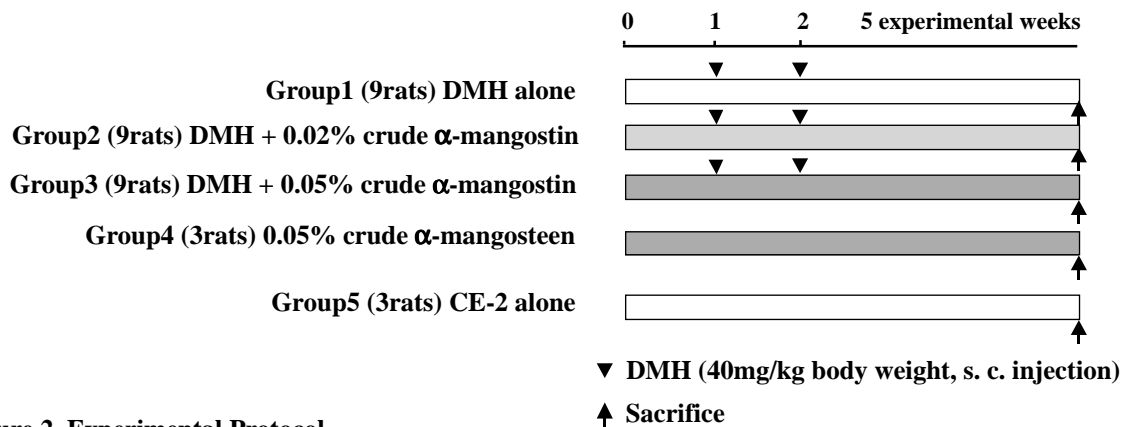


Figure 2. Experimental Protocol

x40, ACF were counted according to the criteria described elsewhere (Bird, 1987; Yoshimi et al., 1997). After ACF counting, colon tissues were longitudinally cut into two exact halves. One piece of the colon tissue was embedded in paraffin and processed for histological examination of DF and immunohistochemistry of BCAC. DF were identified as focal lesions displaying paneth cell metaplasia, presence of mitosis, dyskaryosis according to the criteria described earlier (Yoshimi et al., 2004).

Immunohistochemical Staining of BCAC

Distal and middle segments of the colon tissue were used for immunostaining of BCAC. In brief, immunohistochemical staining of BCAC was performed using an enface preparation method with 4 μm-thick serial sections of colonic mucosa. Sections were prepared to include the middle portion between the surface and the bottom of the crypt. These sections were incubated in 3% H₂O₂ for 20 min to block the endogenous peroxidase activity. Sections were submerged in 1 mM EDTA (pH 9.0) and heated in a pressure cooker for 10 min. After cooling, sections were treated with 5% bovine serum albumin in a humidified chamber at room temperature for 10 min and incubated with a primary antibody of the β-catenin protein (Transduction Laboratories, Lexington, KY, 1: 100 dilution) at room temperature for 60 min. Sections were then stained with a Simple Stain kit (Nichirei, Tokyo, Japan).

Immunohistochemical Staining of PCNA

Proliferating activity of cells in the colonic mucosa was examined by the established method with slight modifications. Briefly, 4 μm-thick serial sections were prepared with a rolled colonic mucosa. These sections were used to measure PCNA labelling index in the colonic epithelial cells. PCNA labelling index in ACF and BCAC was also determined in sections of epithelial cells consisting of the crypts of ACF and BCAC. Sections were irradiated in a microwave oven in a 2 s on/2 s off cycle for 2 min using

an anti-PCNA antibody (DAKO Co. Ltd., Kyoto, Japan, 1: 50 dilution). The PCNA labeling index was determined by calculating the ratio of PCNA-positive nuclei/total number of nuclei counted as described earlier (Morioka et al., 2004a).

Statistical Analysis

Statistical analyses by Student's or Welch's t-test were performed to determine the significance of the differences between groups. All statements of significance are P<0.05.

Results

General Observation

A total of 33 F344 rats survived at the end of the experiment and none of them developed colon tumors. The mean body, liver and relative liver weights in all groups are shown in Table 1. No significant effect of DMH and/or crude α-mangostin on body, liver, and relative liver weight were seen. Liver weight of rats treated with DMH and 0.02% crude α-mangostin was slightly increased (P<0.05) when compared to that of DMH-treated rats (group 1). Relative liver weight of control untreated rats (group 5) was decreased (P<0.01) when compared to that of DMH-treated rats (group 1).

Inhibitory Effect of Crude α-Mangostin on ACF

Mean number of ACF per colon is shown in Table 2. All rats in groups 1-3 developed ACF. No ACF were seen in rats in groups 4 and 5. Total number of ACF/colon in groups 2 (126.0 ± 45.9, P<0.05) and 3 (94.6 ± 35.1, P<0.01) was significantly lower than that of group 1 (174.4 ± 21.2). Total number of ACF containing 1-3 crypts/colon of groups 2 (123.2 ± 45.8, P<0.05) and 3 (92.0 ± 34.6, P<0.01) was also significantly lower than that of group 1 (170 ± 22.3). However, there was no statistical difference in total number of ACF containing more than 4 crypts/colon between groups. These results indicate that dietary administration of crude extract α-mangostin significantly inhibited the number of

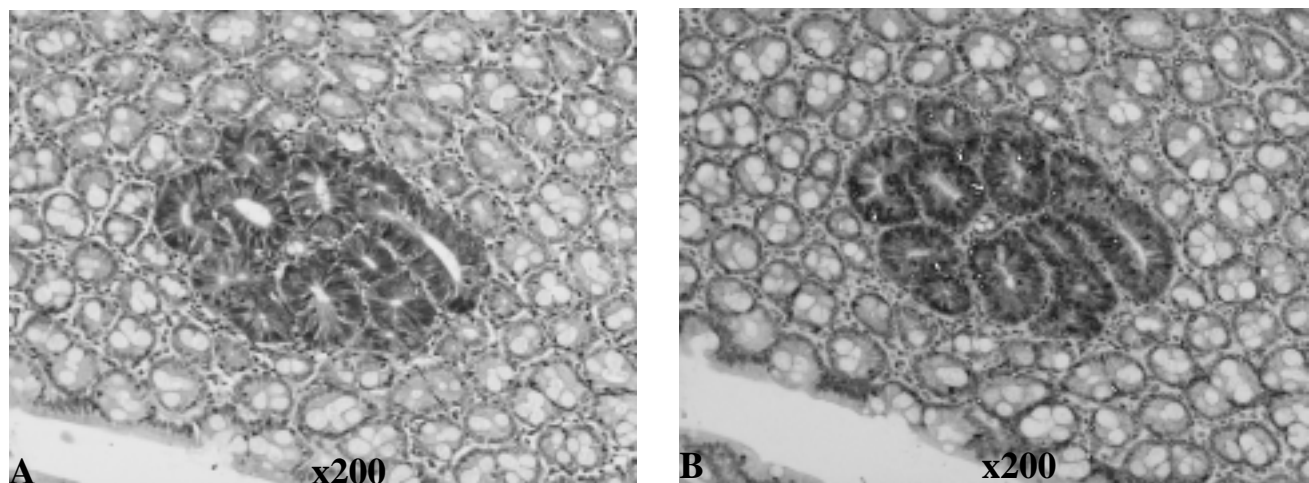


Figure 3. (A) Representative View of DF in Hematoxylin & Eosin Staining and (B) BCAC in Immunohistochemical Staining

Table 1. Body, Liver, and the Relative Liver Weights

Group	Treatment	No. of rats examined	Body weight (g)	Liver weight (g)	Relative liver weight (g/100g body weight)
1	DMH alone	9	233.2 ± 12.8 ^a	10.6 ± 0.7	4.6 ± 0.1
2	DMH + 0.02% crude α-mangostin	9	236.9 ± 9.9	11.3 ± 0.6 ^b	4.8 ± 0.3
3	DMH + 0.05% crude α-mangostin	9	232.9 ± 6.2	10.4 ± 0.8	4.5 ± 0.3
4	0.05% crude α-mangostin	3	219.3 ± 23.2	9.9 ± 1.6	4.5 ± 0.3
5	CE-2 alone	3	238.0 ± 24.0	10.3 ± 1.2	4.3 ± 0.1 ^c

^a Mean ± SD ^{b,c} Significantly different from group 1 by Student's *t*-test $P < 0.05$ and $P < 0.01$, respectively

ACF induced by DMH.

Inhibitory Effect of Crude α-Mangostin on DF and BCAC

Total number of DF and mean number of BCAC/cm² colon are shown in Table 3. Representative histological features of DF and BCAC are shown in Figure 2. Treatment of rats with 0.05% crude α-mangostin caused a significant decrease of DF ($P < 0.05$) and BCAC ($P < 0.05$), when compared to the DMH-treated group (group 1). A decrease in number of DF and BCAC of rats treated with 0.02% crude α-mangostin was not statistically significant but there was a clear tendency that a decrease in number of DF and BCAC is dose dependent of crude α-mangostin (Table 3).

Inhibition of PCNA Labeling Index by Crude α-Mangostin

The PCNA labeling index in the colonic epithelial cells is shown in Table 4. In groups 2 and 3, treatment of rats with crude α-mangostin caused a significant decrease in labeling index of PCNA in a dose dependent manner, when compared to the DMH-treated group (group 1). The PCNA labeling index in ACF and BCAC of rats treated with crude α-mangostin was significantly lower than that of rats treated

with DMH alone (Table 5).

Discussion

The present studies provide the first detailed examination of the effects of the crude α-mangostin in GM on short-term colon carcinogenesis. In these studies, dried mangosteen pericarps were extracted with ethylacetate and the precipitated crude crystals were collected by filtration. The crude crystals in this study mainly contain α-mangostin. In the present study, we found that dietary administration of the crude α-mangostin significantly inhibited the occurrence of ACF, DF, and BCAC induced by a carcinogen DMH. We also found that the PCNA labeling index in the colonic epithelial cells, ACF and BCAC was inhibited in a dose-dependent manner by the treatment of rats with crude α-mangostin. In a previous study, it is demonstrated that GM includes xanthone derivatives, termed α, β, and γ-mangostins (Matsumoto et al., 2003). Of these, α-mangostin has been shown to inhibit cell growth in HL60 human leukemia cells (Matsumoto et al., 2003). Furthermore, we also found that α-mangostin inhibits the growth of several human carcinoma

Table 2. Inhibitory Effect of Crude α-Mangostin on ACF

Group	Treatment	No. of rat examined	Total no. of ACF/colon	Total no. of ACF containing 1-3 crypts /colon	Total no. of ACF containing more than 4 crypts/colon
1	DMH alone	9	174.4 ± 21.2 ^a	170.1 ± 22.3	4.3 ± 2.4
2	DMH + 0.02% crude α-mangostin	9	126.0 ± 45.9 ^b	123.2 ± 45.8 ^b	2.8 ± 1.2
3	DMH + 0.05% crude α-mangostin	9	94.6 ± 35.1 ^c	92.0 ± 34.6 ^c	2.6 ± 1.7
4	0.05% crude α-mangostin	3	0	0	0
5	CE-2 alone	3	0	0	0

^a Mean ± SD ^b Significantly different from group 1 by Welch's *t*-test ($P < 0.05$) ^c Significantly different from group 1 by Student's *t*-test ($P < 0.01$)

Table 3. Inhibitory Effect of Crude α-Mangostin on DF and BCAC

Group	Treatment	No. of rats examined	Total number of DF/half colon	Total number of DF containing more than 4 crypts	Mean no. of BCAC t _g /cm ² colon
1	DMH alone	9	7.1 ± 4.0 ^a	0.89 ± 0.93	1.05 ± 0.87
2	DMH + 0.02% crude α-mangostin	9	5.0 ± 2.3	0.33 ± 0.50	0.65 ± 0.50
3	DMH + 0.05% crude α-mangostin	9	2.4 ± 2.8 ^b	0	0.38 ± 0.34 ^c
4	0.05% crude α-mangostin	3	0	0	0
5	CE-2 alone	3	0	0	0

^a Mean ± SD ^b Significantly different from group 1 by Student's *t*-test ($P < 0.05$) ^c Significantly different from group 1 by Welch's *t*-test ($P < 0.05$)

Table 4. Inhibition of PCNA Labeling Index of Colonic Epithelium by Crude α -Mangostin

Group	Treatment	No. of rats examined	PCNA labeling index (%)
1	DMH alone	9	7.85 \pm 2.18 ^a
2	DMH + 0.02% crude α -mangostin	9	3.98 \pm 1.69 ^b
3	DMH + 0.05% crude α -mangostin	9	3.03 \pm 1.10 ^c
4	0.05% crude α -mangostin	3	2.91 \pm 1.40
5	CE-2 alone	3	2.99 \pm 0.97 ^d

^a Mean \pm SD^{b, d} Significantly different from group 1 by Student's *t*-test ($P < 0.01$).^c Significantly different from group 1 by Welch's *t*-test ($P < 0.01$).

cell lines including colon carcinoma cell lines (unpublished observation). Therefore, the results in the present study suggest that α -mangostin obtained from GM may be a valuable chemopreventive or chemotherapeutic agent.

ACF are putative preneoplastic lesions in the colonic mucosa of rats treated with chemical carcinogens including azoxymethane (AOM), methylazoxymethanol (MAM), and DMH (Mori et al., 1991; Chewonarin et al., 1999; Rodrigues et al., 2002; Morioka et al., 2004a). ACF are classified into two distinct fractions including histological ACF and DF. DF are characterized by paneth cell mataplasia, mitosis, or dyskaryosis in the nuclei (Yoshimi et al., 2004). In the rat colonic mucosa, focal lesions that display the accumulation of the β -catenin protein are termed BCAC (Yamada et al., 2003). ACF, DF, and BCAC have been used as useful biomarkers for short-term colon carcinogenesis bioassays and are also useful to examine chemopreventive effects of a wide variety of plant extracts (Hirose et al., 2003; Yoshimi et al., 2004). We can evaluate the proliferating activity in cells of rat colonic epithelia by calculating PCNA labeling index (Tanaka et al., 2000; Morioka et al., 2004a). For instance, we recently demonstrated that the herbs *Peucedanum japonicum* (Botanbofu) and *Terminalia catappa* (Momotamana) significantly inhibit the occurrence of both ACF and BCAC induced by AOM (Morioka et al., 2004a; Morioka et al., 2004b). These findings together with the results in the current study suggest that GM has a chemopreventive potential in a short-term colon carcinogenesis bioassay system. Thus, it is of interest to evaluate the potential of α -mangostin in GM for clinical

use. However, important consideration is whether or not, following oral administration, this compound exerts significant adverse side effects.

Chemical carcinogens including AOM, MAM, or DMH enhance growth in cells of rat colonic epithelia and also increase the vertical length of crypts and the number of cells constructing crypts in the rat colonic mucosa (Chewonarin et al., 1999). In general, cell proliferation in the ACF, BCAC, and colon tumors is more increased than in normal colonic mucosa (Tanaka et al., 2000). Thus, cell proliferation may be an important player in the development of ACF, BCAC and colon tumors. In the present study, we found that dietary administration of the crude α -mangostin significantly decreased the PCNA labeling index in a dose-dependent fashion in the crypts of rats treated with DMH. Thus, inhibitory effects of the crude α -mangostin in the occurrence of ACF, and BCAC may be associated with the inhibition of cell proliferation in these lesions. We recently demonstrated that selective cyclooxygenase-2 (COX2) inhibitor celecoxib reduces cell proliferation in ACF and BCAC (Yoshimi et al., 1997; Yamada et al., 2001a). It has also been reported that γ -mangostin inhibited the activities of COX2 (Nakatani et al., 2002) and that the crude extract of GM has an antioxidant activity and induces apoptosis in SKBR3 human breast carcinoma cell line (Williams et al., 1995; Mahabusarakam et al., 2000; Moongkarndi et al., 2004). The compound garcinone E extracted from GM has been shown to exert growth-inhibitory effects in several human hepatoma cell lines (Ho et al., 2002; Moongkarndi et al., 2004). In this study, we found that crude α -mangostin exhibits antiproliferative activity in the rat colonic mucosa, suggesting that GM contains more than one possible compound(s) that have an antiproliferative effect in short-term colon carcinogenesis. Crude mangosteen extracts contain γ -mangostin (Matsumoto et al., 2003) and this compound exhibits the biological activity (Nakatani et al., 2002). Thus, γ -mangostin may be effective in the present short-term bioassay system. In view of these considerations, possible active components are mangostins because these compounds are found to be one of the constituents of GM (Matsumoto et al., 2003) and some of them actually showed antiproliferative activity in the present study and in previous studies (Moongkarndi et al., 2004). To address these questions, further studies are in progress to determine the active component of GM that exerts anticancer activity.

Table 5. Inhibition of PCNA Labeling Index in ACF and BCAC by Crude α -Mangostin

Group	Treatment	PCNA-LI in ACF	PCNA-LI in BCAC (no. of crypts examined)
1	DMH alone	4.26 \pm 6.34 ^a (260)	8.75 \pm 6.46 (36)
2	DMH + 0.02% crude α -mangostin	1.97 \pm 4.01 ^b (221)	4.30 \pm 4.19 ^c (15)
3	DMH + 0.05% crude α -mangostin	0.81 \pm 1.96 ^b (166)	3.48 \pm 2.75 ^d (9)
4	0.05% crude α -mangostin	0	0
5	CE-2 alone	0	0

^a Mean \pm SD ^{b, c, d} Significantly different from group 1 by Welch's *t*-test ($P < 0.0001$, $P < 0.01$, and $P < 0.001$, respectively).

Acknowledgements

The authors thank Tetsuya Kunihiro, Reika Takamatsu, and Chinatsu Yonemori for their helpful technical assistance. This work was supported by a Grant-in-Aid from the Ministry of Health, Labor, and Welfare of Japan, and a Grant-in-Aid from the Ministry of Education, Culture, Sports, Science, and Technology of Japan.

References

- Asai F, Tisa H, Tanaka T, Inuma M (1995). "A xanthone from pericarps of *Garcinia mangostana*". *Phytochemistry*, **39**, 943-4.
- Bird RP (1987). Observation and quantification of aberrant crypts in the murine colon treated with a colon carcinogen: preliminary findings. *Cancer Lett*, **37**, 147-51.
- Bird RP, Good CK (2000). The significance of aberrant crypt foci in understanding the pathogenesis of colon cancer. *Toxicol Lett*, **112-113**, 395-402.
- Chewonarin T, Kinouchi T, Kataoka K, et al (1999). Effects of roselle (*Hibiscus sabdariffa* Linn.), a Thai medicinal plant, on the mutagenicity of various known mutagens in *Salmonella typhimurium* and on formation of aberrant crypt foci induced by the colon carcinogens azoxymethane and 2-amino-1-methyl-6-phenylimidazo[4,5-b]pyridine in F344 rats. *Food Chem Toxicol*, **37**, 591-601.
- Hirose Y, Kuno T, Yamada Y, et al (2003). Azoxymethane-induced beta-catenin-accumulated crypts in colonic mucosa of rodents as an intermediate biomarker for colon carcinogenesis. *Carcinogenesis*, **24**, 107-11.
- Ho CK, Huang YL, Chen CC (2002). Garcinone E, a xanthone derivative, has potent cytotoxic effect against hepatocellular carcinoma cell lines. *Planta Med*, **68**, 975-9.
- Likhitwitayawuid K, Chanmahasathien W, Ruangrunsi N, arT Krungkrai J (1998). Xanthones with antimalarial activity from *Garcinia dulcis*. *Planta Med*, **64**, 281-2.
- Mahabusarakam WIP, Taylor WC (1987). Chemical constituents of *Garcinia mangostana*. *J Nat Prod*, **50**, 474-8.
- Mahabusarakam W, Proudfoot J, Taylor W, Croft K (2000). Inhibition of lipoprotein oxidation by prenylated xanthones derived from mangostin. *Free Radic Res*, **33**, 643-59.
- Matsumoto K, Akao Y, Kobayashi E, et al (2003). Induction of apoptosis by xanthones from mangosteen in human leukemia cell lines. *J Nat Prod*, **66**, 1124-7.
- Moongkarndi P, Kosem N, Kaslungka S, et al (2004). Antiproliferation, antioxidation and induction of apoptosis by *Garcinia mangostana* (mangosteen) on SKBR3 human breast cancer cell line. *J Ethnopharmacol*, **90**, 161-6.
- Mori Y, Yoshimi N, Iwata H, Tanaka T, Mori H (1991). The synergistic effect of 1-hydroxyanthraquinone on methylazoxymethanol acetate-induced carcinogenesis in rats. *Carcinogenesis*, **12**, 335-8.
- Morioka T, Suzui M, Nabandith V, et al (2004a). The modifying effect of *Peucedanum japonicum*, a herb in the Ryukyu Islands, on azoxymethane-induced colon preneoplastic lesions in male F344 rats. *Cancer Lett*, **205**, 133-41.
- Morioka T, Suzui M, Nabandith V, et al (2004b). Modifying effects of *Terminalia Catappa* on azoxymethane-induced colon carcinogenesis in Hale F344 rats. *Eur J Cancer Prev*, in press.
- Nakatani K, Nakahata N, Arakawa T, Yasuda H, Ohizumi Y (2002). Inhibition of cyclooxygenase and prostaglandin E2 synthesis by gamma-mangostin, a xanthone derivative in mangosteen, in C6 rat glioma cells. *Biochem Pharmacol*, **63**, 73-9.
- Parkin DM, Bray F, Ferlay J, Pisani P (2001). Estimating the world cancer burden: Globocan 2000. *Int J Cancer*, **94**, 153-6.
- Rodrigues MA, Silva LA, Salvadori DM, et al (2002). Aberrant crypt foci and colon cancer: comparison between a short- and medium-term bioassay for colon carcinogenesis using dimethylhydrazine in Wistar rats. *Braz J Med Biol Res*, **35**, 351-5.
- Suzui M, Ushijima T, Dashwood RH, et al (1999). Frequent mutations of the rat beta-catenin gene in colon cancers induced by methylazoxymethanol acetate plus 1-hydroxyanthraquinone. *Mol Carcinog*, **24**, 232-7.
- Tagami K, Niwa K, Lian Z, et al (2004). Preventive effect of Juzen-taiho-to on endometrial carcinogenesis in mice is based on Shimotsu-to constituent. *Biol Pharm Bull*, **27**, 156-61.
- Tanaka T, Kohno H, Murakami M, et al (2000). Suppression of azoxymethane-induced colon carcinogenesis in male F344 rats by mandarin juices rich in beta-cryptoxanthin and hesperidin. *Int J Cancer*, **88**, 146-50.
- Williams P, Ongsakul M, Proudfoot J, Croft K, Beilin L (1995). Mangostin inhibits the oxidative modification of human low density lipoprotein. *Free Radic Res*, **23**, 175-84.
- Yamada Y, Oyama T, Hirose Y, et al (2003). beta-Catenin mutation is selected during malignant transformation in colon carcinogenesis. *Carcinogenesis*, **24**, 91-7.
- Yamada Y, Yoshimi N, Hirose Y, et al (2001a). Suppression of occurrence and advancement of beta-catenin-accumulated crypts, possible premalignant lesions of colon cancer, by selective cyclooxygenase-2 inhibitor, celecoxib. *Jpn J Cancer Res*, **92**, 617-23.
- Yamada Y, Yoshimi N, Hirose Y, et al (2001b). Sequential analysis of morphological and biological properties of beta-catenin-accumulated crypts, provable premalignant lesions independent of aberrant crypt foci in rat colon carcinogenesis. *Cancer Res*, **61**, 1874-8.
- Yoshimi N, Kawabata K, Hara A, et al (1997). Inhibitory effect of NS-398, a selective cyclooxygenase-2 inhibitor, on azoxymethane-induced aberrant crypt foci in colon carcinogenesis of F344 rats. *Jpn J Cancer Res*, **88**, 1044-51.
- Yoshimi N, Morioka T, Kinjo T, et al (2004). Histological and immunohistochemical observations of mucin-depleted foci (MDF) stained with alcian blue, in rat colon carcinogenesis induced by 1, 2-dimethylhydrazine dihydrochloride. *Cancer Sci*, in press.
- Yoshimi N, Wang A, Morishita Y, et al (1992). Modifying effects of fungal and herb metabolites on azoxymethane-induced intestinal carcinogenesis in rats. *Jpn J Cancer Res*, **83**, 1273-8.