

## RESEARCH COMMUNICATION

**Metaplastic Carcinoma of the Breast, an Intriguing Rarity**

Fozia Rauf, Naila Kiyani, Yasmin Bhurgri\*

**Abstract**

Metaplastic carcinoma breast is categorized as a rare heterogenous neoplasm generally characterized by a mixture of adenocarcinoma with dominant areas of spindle cell, squamous and/or other mesenchymal differentiation. To determine the epidemio-demographic and histopathologic characteristics of this rare entity a retrospective study was conducted to review all cases at the Aga Khan University Hospital (AKUH) Karachi, received during 1<sup>st</sup> January 2000 to 31<sup>st</sup> August 2005. Twenty-four patients were identified with a mean age at diagnosis of 46.4 ( $\pm$ SD 3.8) years, and an age range of 28-68 years. The mean tumor size was 7.9 cm, range 2.0–17.0 cms ( $\pm$ SD 4.77). The specimens were mostly obtained by modified radical mastectomy (54.2%) followed by biopsy (29.2%), lumpectomy (8.3%), and total mastectomy (4.2%). Skin ulceration was found in 37.5% cases. Component sub-categorization showed 13 (54.2%) cases of infiltrating ductal carcinoma with squamous metaplasia, followed by 2 (8.3 %) cases with heterologous elements, 4 (16.7%) cases with spindle cell component, 2 cases of matrix producing carcinoma and one case of squamous cell carcinoma. The malignancy was high grade, modified Bloom Richardson's grade III (54.2 %) and grade II (12.5%). Such grading was not applicable to 4 cases of spindle cell component and 1 case with extensive chondroid areas. Twelve patients had information available on the nodal status. Five (41.6%) were node-negative, four (33.33%) had 1-3 lymph node involvement positive, and three (12.5%) had more than 3 lymph nodes positive. The median 3 year Event Free Survival (EFS) was 10% and overall survival was 30%. MCB is an aggressive disease with a poor prognosis. This aspect appears bleaker in our population either due to the biological characteristic of the malignancy in a high risk group or the lack of availability and accessibility of health coverage, resulting in a delayed presentation. MCB is an uncommon breast malignancy and due to the lack of sufficiently large studies there is limited knowledge as to the pathogenesis, progress, best treatment protocols and prognosis. Collaborative studies are therefore recommended to allow for better understanding of this intriguing neoplasm.

**Key Words:** Metaplastic carcinoma breast - characteristics - Pakistan

*Asian Pacific J Cancer Prev*, 7, 667-671

**Introduction**

Benign and malignant tumors of the breast predominantly arise from glandular epithelium. In some cases, however, glandular epithelium differentiates into nonglandular mesenchymal tissue, a process termed metaplasia (Brenner et al., 1998). Pathogenesis of such diverse elements has been the subject of much controversy.

Metaplastic changes in the breast include squamous cell, spindle cell, and heterologous mesenchymal growth and occur in fewer than 5% of breast carcinomas (Wargotz and Norris, 1989a; 1989b; 1990a; 1990b; Wargotz et al., 1989; Pitts et al., 1991). Carcinosarcomas, a subgroup of metaplastic carcinomas, are the rarest primary malignancies of the breast, found in < 0.1% of cases (Feder et al., 1999). Wargotz and Norris (1989a; 1989b and 1990a) and Wargotz et al (1989) categorized metaplastic carcinoma breast (MCB) into four variants which included matrix-producing carcinoma, spindle cell carcinoma, squamous cell carcinoma,

and carcinosarcoma. Earlier, Oberman in 1987 had suggested that all such tumors be categorized as metaplastic carcinoma of the breast (MCB), de-emphasizing whether the metaplastic component is of mesenchymal or epithelial origin. Subsequently, after the advent of immunohistochemistry, it was generally accepted that metaplasia of the epithelial elements of a carcinoma gives MCB a pseudosarcomatous appearance. Hence the name is given to malignant breast neoplasms which show cytokeratin positivity in both epithelial and mesenchymal elements (Saxena et al., 2004). At present, MCB is considered a rare heterogeneous group of neoplasms ranging from tumors with a predominant component of overt carcinoma and focal mesenchymal differentiation to keratin-positive tumors with pure sarcomatoid morphology (Davis et al., 2005).

Morphologically, the malignancy is characterized by an intimate admixture of epithelial and mesenchymal elements in variable combinations. MCB encompasses epithelial only carcinoma (high grade adenosquamous carcinoma or pure

squamous cell carcinoma), biphasic epithelial and sarcomatoid carcinoma and monophasic spindle cell carcinoma (Tse, 2006). Largely, the predominant morphological pattern is adenocarcinoma with dominant areas of spindle cell, squamous and/or mesenchymal differentiation. Rarely osseous differentiation is also observed (Pollock et al., 2006).

MCB often manifests as a rapidly growing, palpable mass. The average age at presentation is approximately 55 years and the median size of malignancy at presentation is usually 3-4 cm. MCB is mostly negative for hormone receptors (HR) i.e. estrogen and progesterone receptors (ER; PR) and HER2/neu oncoprotein. Nodal metastasis is relatively uncommon. An aggressive form of breast cancer, it is associated with poor outcome, high incidence of local recurrence and pulmonary metastases. Tumor size has an important impact on outcome and prognosis (Al Sayed et al, 2006). Advanced stage and lymph node involvement are associated with a more aggressive course. The five year survival is less than that of infiltrating ductal carcinoma. Because MCB comprises a heterogeneous group of tumors, it has been difficult to reliably predict its biologic potential (Carter et al., 2006).

Matrix-producing carcinoma of breast displaying myoepithelial phenotype is a very aggressive lesion and differs from conventional myoepithelial carcinoma and from heterologous metaplastic carcinoma, where the matrix emanate from undifferentiated sarcomatous tissue. The spectrum of differential diagnosis includes benign mixed tumor, phylloides tumor, primary breast sarcoma and colloid carcinoma (Kinkor et al., 2004).

Considering MCB in the differential diagnosis of breast masses is important for the purpose of treatment and prognosis (Brenner et al., 1998; Wargotz et al., 1989). On mammography it can mimic benign lesions as it has a predominantly circumscribed, non-calcified appearance. The margins are more likely to be circumscribed, when the tumor is composed solely of spindle cells (Patterson, 1997). The distinction between MCB and sarcoma is preoperatively important because the surgical treatment, chemotherapy regimens and metastatic pathways are different. Typically, axillary lymph node involvement is rare in breast sarcoma even when the disease is diffusely disseminated, whereas lymph node metastases are reported in 25-30% of cases with metaplastic carcinomas (Brenner et al., 1998; Wargotz et al., 1989).

## Materials and Methods

This retrospective descriptive study was carried out at the Aga Khan University Hospital (AKUH) pathology department. All consecutive cases of MCB (ICD-O3 categories M-8575) diagnosed during the last decade (1<sup>st</sup> January 2000 to 31<sup>st</sup> August 2005) in the section of histopathology were reviewed for the study. This included cases primarily diagnosed at AKUH pathology department and also second opinion slides. Patients were identified

through the AKUH pathology archived data using SNOMED code.

Originally all specimens had been fixed in 10% buffered formalin, grossed and representative sections taken according to established protocols. The sections had been routinely processed under standardized conditions for paraffin embedding. The sections had been cut and stained with hematoxylin and eosin (H&E) using a standard format incorporating all the relevant parameters. The cases had been evaluated and diagnosed after consensus interpretation of slides. For the present study, archived microscopic slides were reviewed by a pathologist who was a breast pathology specialist. Immunohistochemical analysis was performed in 9 cases by employing the envision technique. The mixed cell origin of MCB was corroborated by histopathologic staining for mesenchymal cells (vimentin), epithelial cells (cytokeratin), and myoepithelial cells (S-100 protein, actin, and high-molecular-weight cytokeratin).

Clinical information, pathologic size, morphological findings, and lymph node status were obtained from the surgical pathology reports. Variables recorded were the hospital patient-number, date of incidence, name, age, sex, address, topography, morphology, grading and staging. All morphological and biological types were included; there were no exclusion criteria within the diagnosis of MCB. Cases were categorized by the age of the patient, morphological and biological presentation of the tumor. The information taken from archived reports was rechecked and survival status established. The data were analyzed using SPSS 13.0.

The pathology department of AKUH receives surgical specimens from AKUH, Karachi and through 84 pathology laboratory collection points in Pakistan. It covers a large geographical area, with collection points located in all major cities like Karachi, Hyderabad, Multan, Lahore, Quetta, Peshawar, Islamabad, Rawalpindi, Larkana and also many rural locations. Quality control for diagnostic pathology is maintained through internal and external quality checks. External quality assurances for diagnostic pathology are maintained by the College of American Pathologists (CAP) surveys. Internal quality assurances are maintained by the use of histochemical stains, immunohistochemical techniques. Biological markers are used for malignancies, which necessitates cellular typing and sub typing. The departmental consensus committee confirms diagnosis.

## Results

Twenty four cases of MCB received over a five year 8 month period were analyzed. All patients were women, with an age range of 28-68 years. The mean age at diagnosis was 46.4 ( $\pm$ SD 3.8) years and the median age was 49 years. The presenting complaint was a rapidly growing palpable breast mass. No patient reported a familial risk factor for breast cancer.

The surgical specimens were obtained for diagnostic assessment by modified radical mastectomy (MRM) in 13

(54.2%) cases, core biopsy in 7 (29.2%), breast conserving surgery in (BCS), lumpectomy in 2 (8.3%) and total mastectomy in 1 (4.2%). In the one (4.2%) second opinion case, the mode of surgery was not specified.

On gross examination skin was ulcerated in 9 (37.5%) cases, normal in 9 (37.5%) and in 6 (25.0%) skin was neither available as part of the specimen, nor clinical information available, so that skin involvement could not be commented on. The tumor was observed on the left side in 12 (50%) cases, on the right side in 5 (20.8%) cases. Laterality was not known in 7 (29.2%) cases. The exact size of the tumor was available in 16 cases with range of 2-17cms and a mean and standard deviation of  $7.9 \pm SD 4.77$ .

Component sub-categorization showed 14 (58.4%) cases of infiltrating ductal carcinoma with squamous metaplasia, 5 (20.8%) with spindle cell components, 2 (8.3%) with heterologous elements, 2 (8.3%) of matrix producing carcinoma, and one of squamous cell carcinoma (4.2%). Immunohistochemistry as a diagnostic tool was essential in 5 cases with spindle cell components, 2 with heterologous elements and 2 of matrix producing carcinoma. Vimentin and cytokeratin were positive in all 9 cases, S100 protein was positive in 2 of the 5 cases in which it was used and smooth muscle actin was positive in 1 out of the 6 cases in which it was used.

Modified Bloom Richardson grading was used to grade 16 cases. Thirteen (54.2%) cases were grade III and 3 (12.5%) cases were grade II. Modified Bloom Richardson grading was not possible in 8 high grade cases, 5 cases of vimentin positive spindle cell type (see Figure 1a), 2 cases of matrix producing carcinoma, and one case of squamous cell carcinoma. Lymph nodes were recovered in 12 of the 13 cases of MRM. In 5 (41.6%) cases lymph node metastasis was not present. In 4 (33.3%) cases 1-3 lymph nodes were involved (N1) and in 3 cases (25.0%) more than 3 lymph nodes were involved (N2).

The tumor margin was positive in 2 (14.2%) of the 14 cases of MRM and total mastectomy. The margin was close,

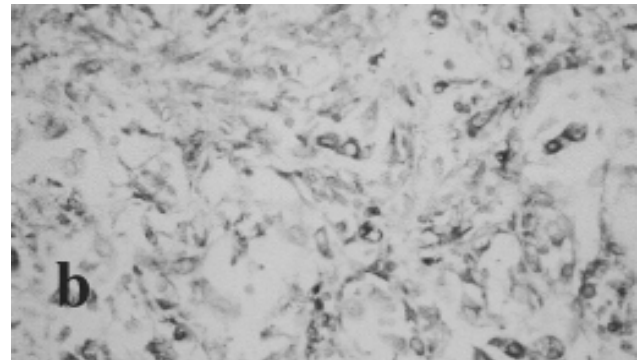
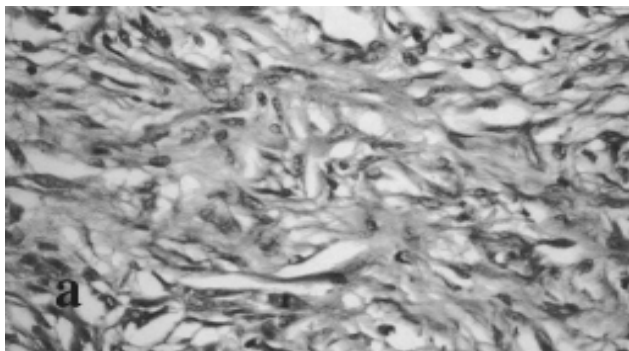
within or  $<5$  mm in 4 (28.57%) cases and free in 8 (57.1%) cases. Estrogen receptor studies were available in 10 (41.6%) cases which were all negative. Progesterone receptor studies were available in 7 (29.16%) cases and were negative in 6 (85.7%) cases. The median 3 year event free survival (EFS) was 10% and overall survival was 30%.

## Discussion

MCBs are regarded as ductal carcinomas that undergo metaplasia into a nonglandular growth pattern (Brenner et al., 1998; Wargotz et al., 1989). Due to the rarity of the disease, published work is limited to mostly single case reports (Alam et al., 2003; Greenberg et al., 2004) or a few small series (Al Sayed et al., 2006; Carter et al., 2006; Dave et al., 2006; Davis et al., 2005; Kuo et al., 2000; Chao et al., 1999) thus restricting comparisons. The prognostic criteria used to determine MCB aggressiveness are age of occurrence, stage of the disease, size of the lesion, lymph node status, histologic type and grade and the grade of the mesenchymal component. On the basis of these criteria of comparison, it is our observation that the MCB in the present study and largely in Asia is a more aggressive disease.

Most western studies cite an older age group involvement by MCB, which is reportedly more common in women above 50 years of age (Pitts et al., 1991; Wargotz and Norris, 1989; 1990; Oberman, 1987; Taylor et al., 1994). Carter et al in 2006 reviewed 29 cases of MCB in the United States. The patients in their series were older than in our series, with a median age of 68 years and a range of 40 to 96 years. In comparison MCB presents in a younger age group in Asians. In different Asian settings, the median age of presentation reported was 52.5 years in a series of 8 patients (Kuo et al, 2000), 50.5 years in a series of 14 cases (Chao et al, 1999), 48.0 years in a series of 19 patients (Al Sayed et al, 2006) and 49.0 years in the present series of 24 patients.

The size of the malignancy at diagnosis is a reflection of rapid growth and biological behaviour of the tumour, or a



**Figure 1. Spindle Cell Metaplastic Carcinoma of the Breast a) H&E, b) Vimentin Staining**

**Table 1. Comparison of Characteristics for Metaplastic Carcinoma of the Breast in Different Series**

	Current Pakistan 1996-2005	Al Sayed Saudi Arabia 1994-2004	Tse HK -	Rayson US 1976-1997	Carter US -	Hennessy US 1985-2001	Dave US 1987-2002
Number of cases	24	19	34	27	29	100	43
Duration of study; years	5(+8 months)	10	-	22	-	-	15
Age (median); years	49	48	-	59	68	-	-
Range	-	14-58	-	39-90	40-96	-	-
Size (median); cms	6.5	9.0	-	3.4	4.0	-	3.4
Range	2-17	3-18	-	.5-7.0	1.5-15	-	-
Lymph node status, +	7/12	-	-	3/23	-	34	25%
Distant metastases	-	-	-	-	-	6	-
Estrogen receptor +	0%	11%	9%	13%	-	-	9%
High MBRC grade	13/16	-	-	-	-	-	-
Stage II	-	8/19	-	-	-	-	-
Stage III	-	9/19	-	-	1	-	-
Stage IV	24	2/19	-	-	-	-	-
Median event free survival (EFS)	10% 3 years	15% 3 years	-	40% 3 year	27.6% 29.5 mths.	94% 74 mths.	-
Overall survival (OS)	20% 3 years	48% 3 years	-	71% 3 year	42% 11.5 mths.	-	-

late presentation, due to a lack of availability or accessibility of health facilities. All factors may be at play in our environment. A comparison of international studies is given in Table 1. MCB at presentation appears not only as a larger tumour in Asians but also exhibits a higher potential for metastasis. In the US, however a positive lymphnode status is less usual. MCBs are usually well-circumscribed lesions but 37.5% of our patients presented with an ulcerated mass which is an unusual finding, highlighting the late presentation of patients with breast malignancy in developing countries. This was also reported by Alam et al from India in 2003. The ER, PR and HER-2 status is overwhelmingly negative, which minimises the options for adjuvant treatment in patients with advanced disease (Leibl and Moinfar, 2005).

Grades are higher and survival is very much lower in Asian than in American patients. Unfortunately the survival in our cases is the lowest reported. This aspect appears bleaker in our population either due to the biological characteristic of the malignancy in a high risk group or the lack of availability and accessibility of health coverage, resulting in a delayed presentation. MCB is an uncommon breast malignancy and the lack of sufficiently large studies there is limited knowledge of the pathogenesis, progress, best treatment protocols and prognosis of the disease. Collaborative studies are therefore recommended to allow for better understanding of this intriguing rarity.

## References

- Alam K, Maheshwari V, Harris H and Mehdi G. (2003) An unusual case of metaplastic breast carcinoma (sarcomatoid variant). *Ind J Surg*, **65**, 377-8.
- Al Sayed AD, El Weshi AN, Tulbah AM, Rahal MM, Ezzat AA (2006). Metaplastic carcinoma of the breast. Clinical presentation, treatment results and prognostic factors. *Acta Oncol*, **45**, 188-95.
- Brenner RJ, Turner RR, Schiller V, Arndt RD, Giuliano A (1998). Metaplastic carcinoma of the breast: report of three cases. *Cancer*, **82**, 1082-7.
- Carter MR, Hornick JL, Lester S and Fletcher CD. (2006) Spindle cell (sarcomatoid) carcinoma of the breast: A clinicopathologic and immunohistochemical analysis of 29 cases. *Am J Surg Pathol*, **3**, 300-9.
- Chao TC, Wang CS, Chen SC, Chen MF (1999). Metaplastic carcinomas of the breast. *J Surg Oncol*, **71**, 220-5.
- Dave G, Cosmatos H, Do T, Lodin K, Varshney D (2006). Metaplastic carcinoma of the breast: A retrospective review. *Int J Radiat Oncol Biol Phys*, **64**, 771-5.
- Davis WG, Hennessy B, Babiera G, et al (2005). Metaplastic sarcomatoid carcinoma of the breast with absent or minimal overt invasive carcinomatous component: a misnomer. *Am J Surg Pathol*, **29**, 1456-63.
- Feder JM, de Paredes ES, Hogge JP, Wilken JJ (1999). Unusual breast lesions: radiologic—pathologic correlation. *RadioGraphics*, **19** (suppl), S11-26.
- Greenberg D, McIntyre H, Bierre T (2004). Metaplastic breast cancer. *Australas Radiol*, **48**, 243-7.
- Hennessy BT, Giordano S, Broglio K, et al. (2006) Biphasic metaplastic sarcomatoid carcinoma of the breast. *Ann Oncol*, **17**, 605-13.
- Kinkor Z, Boudova L, Ryska A, Kajo K, Svec A. (2004) Matrix-producing breast carcinoma with myoepithelial differentiation—description of 11 cases and review of literature aimed at histogenesis and differential diagnosis. *Ceska Gynecol*, **69**, 229-36.
- Kuo SH, Chen CL, Huang CS, Cheng AL (2000). Metaplastic carcinoma of the breast: analysis of eight Asian patients with special emphasis on two unusual cases presenting with inflammatory type breast cancer. *Anticancer Res*, **20**, 2219-22.
- Leibl S, Moinfar F (2005). Metaplastic breast carcinomas are

- negative for Her-2 but frequently express EGFR (Her-1): potential relevance to adjuvant treatment with EGFR tyrosine kinase inhibitors? *J Clin Pathol*, **58**, 700-4.
- Oberman HA (1987). Metaplastic carcinoma of the breast. *Am J Surg Pathol*, **11**, 918-29.
- Patterson SK, Tworek JA, Roubidoux MA, Helvie MA, Oberman HA (1997). Metaplastic carcinoma of the breast: mammographic appearance with pathologic correlation. *Am J Radiol*, **169**, 709-12.
- Pitts WC, Rojas VA, Gaffey MJ, et al (1991). Carcinomas with metaplasia and sarcomas of the breast. *Am J Clin Pathol*, **95**, 623-32.
- Pollock JM, Green A, Donnell C, Dyess DL, Tucker JA (2006). Metaplastic breast carcinoma with osseous differentiation: a case report. *South Med J*, **99**, 168-70.
- Rayson D, Adjei AA, Suman VJ, Wold LE, Ingle JN. (1999) Metaplastic breast cancer: Prognosis and response to systemic therapy. *Annals Oncol*, **10**, 413-9.
- Saxena S, Bansal A, Mohil RS, Bhatnagar D (2004). Metaplastic carcinoma of the breast--a rare breast tumour. *Ind J Pathol Microbiol*, **47**, 217-20.
- Taylor DB, Adamson R, Minchin DE, Reading L (1994). Carcinoma of the breast with sarcomatous metaplasia. *Australas Radiol*, **38**, 262-4.
- GM, Tan PH, Putti TC, et al (2006). Metaplastic carcinoma of the breast: a clinico-pathological review. *J Clin Pathol* [Epub ahead of print].
- Wargotz ES, Deos PH, Norris HJ (1989). Metaplastic carcinomas of the breast. II Spindle cell carcinoma. *Human Pathol*, **20**, 732-40.
- Wargotz ES, Norris HJ (1989a). Metaplastic carcinomas of the breast. I. Matrix-producing carcinoma. *Human Pathol*, **20**, 628-35.
- Wargotz ES, Norris HJ (1989b). Metaplastic carcinomas of the breast. III. Carcinosarcoma. *Cancer*, **64**, 1490-9.
- Wargotz ES, Norris HJ (1990a). Metaplastic carcinomas of the breast. IV. Squamous cell carcinoma of ductal origin. *Cancer*, **65**, 272-6.
- Wargotz ES, Norris HJ (1990b). Metaplastic carcinomas of the breast. V. Metaplastic carcinoma with osteoclastic giant cells. *Human Pathol*, **21**, 1142-50.
- World Health Organisation (2000). International Classification of Diseases for Oncology, 3rd Edition. WHO, Geneva.
- WHO (2003). Classification of Tumors. Tumors of breast and female genital organs, IARC press, Lyon, France, 37-41.