

RESEARCH ARTICLE

Effect of Mirtazapine on MNNG-Induced Gastric Adenocarcinoma in Rats

Mehmet Bilici^{1,2*}, Kerim Cayir^{1,2}, Salim Basol Tekin^{1,2}, Cemal Gundogdu^{1,3}, Abdulmecit Albayrak^{1,4}, Bahadir Suleyman^{1,4}, Bunyamin Ozogul^{1,5}, Burak Erdemci^{1,6}, Halis Suleyman^{1,4}

Abstract

Objective: In this study, anticancer effects of mirtazapine on rats were investigated in an adenocarcinoma model induced by N-methyl-N-nitro-N-nitrosoguanidine (MNNG) and compared with those of cisplatin. **Materials and Methods:** For this purpose, 10 mg/kg doses of mirtazapine were administered orally to one group of rats, while 1 mg/kg doses of cisplatin were administered intraperitoneally to another group. At 1 hour after administration, 200 mg/kg doses of MNNG were given orally to both groups. MNNG administration was repeated once every 10 days through 3 months, after which period, gastric tissue was taken and pathologically evaluated. **Results:** Mirtazapine prevented adenocarcinoma induction by MNNG in rats to a greater extent than cisplatin. Some of the rats receiving cisplatin demonstrated severe dysplasia in gastric samples and others exhibited mild dysplasia. Rats given mirtazapine were not observed to suffer severe dysplasia, only mild dysplasia being observed. **Conclusion:** For adenocarcinoma induced by MNNG on rats, mirtazapine was determined more effective than cisplatin. In order to make statement about mechanism of anticancer activity of mirtazapine, wider studies are required.

Keywords: Gastric cancer - rat - MNNG - mirtazapine - cisplatin - prevention

Asian Pacific J Cancer Prev, 13 (10), 4897-4900

Introduction

Gastric cancer is one of the most important causes of cancer-associated mortality all around the world (Chan et al., 2001). Adenocarcinomas account for about 90% of gastric cancers. Development of gastric cancer is a complex condition associated with multifactorial etiology (Crew et al., 2006). *H. pylori*, high-salt diet, smoking, obesity, exposure to radiation and Epstein-Barr virus are among factors which increase cancer risk (Tatematsu et al., 1975; Thompson et al., 1994; Levine et al., 1995; Chow et al., 1998; Hishida et al., 2010; Liu et al., 2012). In addition, life style and environmental factors have a considerable amount of contribution in etiology of cancer (Crew et al., 2006). Among these, the most frequently indicated factor in cancer patients is major depression. Major depression affects quality of life and treatment compliance of the patient; in time, it also affects severity, prognosis and treatment response of cancer (Berard, 2001). Studies show that risk of mortality is high in cancer patients with major depression (Onitilo et al., 2006). Therefore, treatment of major depression in cancer patients is crucial. Depression is not only seen in cancer disease; it's also seen during other diseases which are not associated with cancer, e.g.

depression associated with psychosomatic and somatic symptoms was seen in majority of patients with GIS diseases (Guldahl, 1977).

Tatsuta et al. (1989) reported that suppression of sympathetic nervous system inhibits carcinogenesis while stimulation of sympathetic nervous system activity increases carcinogenesis (Tatsuta et al., 1989; 1992). It's well known that main mechanism of action of antidepressant agents is oriented to increase noradrenergic, serotonergic and dopaminergic activity (Baldessarini, 2005). It's reported that nialamide, a monoamine oxidase inhibitor, increases incidence of cancer by causing an elevation in norepinephrine concentration of gastric wall (Tatsuta et al., 1989). It's known that norepinephrine and other catecholamines induce their effects through α and β adrenergic receptors (Baldessarini, 2005). Increase in incidence of gastric cancer was observed following long-term administration of α adrenoreceptor agonists (Iishi et al., 1998). Besides, it was determined that phenylephrine, an α receptor agonist, increases severity of gastric cancer induced by MNNG (Tatsuta et al., 1998). Data from literature indicates that administration of antidepressant activity through α adrenergic receptor blockade in combination with antidepressant therapy may

¹Ataturk University, Faculty of Medicine, ²Department of Internal Medicine, Division of Medical Oncology, ³Department of Pathology, ⁴Department of Pharmacology, ⁵Department of General Surgery, ⁶Department of Radiation Oncology, Erzurum, Turkey *For correspondence: memetbilici@mynet.com

be beneficial.

In due course, purpose of our trial is to investigate effect (if any) of mirtazapine, an antidepressant with α adrenergic receptor blocking activity, on MNNG-induced gastric adenocarcinoma in rats.

Materials and Methods

Experimental animals

Rats used in our trial were supplied by Ataturk University Experimental Medical Application and Research Center. Thirty male rats of albino wister species with weights between 110-120 grams were used during this experiment. During pre-trial period, rats were kept and fed in groups in the laboratory at room temperature (22° C).

Chemicals

N-methyl-N0-nitro-N-nitrosoguanidine (MNNG), thiopental sodium, cisplatin and mirtazapine for this trial were obtained from ABRC (Germany), IE Ulagay (Turkey), Koçak Farma (Turkey) and Organon (Turkey), respectively.

Effect of Mirtazapine on MNNG-induced gastric adenocarcinoma in rats

In rats, N-methyl-n-nitrosoguanidine is utilized to induce gastric adenocarcinoma (Sugimura et al., 1998). In this trial, oral mirtazapine was given in doses of 10 mg/kg in one group of rats while intraperitoneal (IP) cisplatin in doses of 1 mg/kg was administered to another group. Distilled water was given to rats in control group as vehicle. One hour after administration of drugs, oral MNNG of 200 mg/kg was administered in all rat groups through a catheter. MNNG administration was repeated every 10 days for three months (Suleyman et al., 2010). Mirtazapine and cisplatin were administered daily, as indicated above, for three months. At the end of third month, rats were exterminated by high dose anesthetics (thiopental sodium 50 mg/kg) and stomachs were dissected. After initial macroscopic examination, histopathological (microscopic) examinations were performed on gastric samples. Gastric samples of drug-administered rat groups were compared with the control

group to evaluate anticancer activity.

Histopathological examination

Gastric tissue samples were fixated in 10% formaline solution for one day. On fixated gastrectomy materials, samples were obtained from areas where mucosa folds were flattened or irregular. These samples were dehydrated by alcohol solutions at various degrees and embedded in paraffine. Afterwards, cross-sections of 5 mm were obtained. These cross-sections were stained by H&E and examined under light microscope olympus Bx-51.

Results

In macroscopic examination, protuberant and firm thickening was seen in certain areas of gastrum (corpus, fundus) in control group who were fed MNNG only. Gastric tissue lost its elasticity; it was firm and thickened. No ulcerative defect was observed in gastric mucosa. Mild thickening in corpus and fundus were seen in mirtazapine-administered rats. Gastric tissue was more elastic as compared to control group. Among some rats in cisplatin group, thickening and protuberant in gastric tissue were more prominent, while it was less severe in others. Mildly protuberant and firm gastric tissues were more elastic as compared to other samples.

Microscopic examination

As seen in Figure 1A, atypical epithelial cells with large hyperchromatic nuclei, prominent nucleoli and enlarged eosinophilic cytoplasm with no polarity constituted gland-like structures in stomach of MNNG-administered control group rats. These findings (only in gastric tissue samples of MNNG-administered control group rats) were considered as gastric carcinoma in situ. Mild dysplasia was seen in gastric tissue samples of mirtazapine-administered rats (Figure 1B). In cisplatin group, severe dysplasia was determined in some rats while mild dysplasia was seen in others (Figure 1C).

Discussion

In our trial, effect of an antidepressant, mirtazapine, on MNNG-induced gastric adenocarcinoma in rats

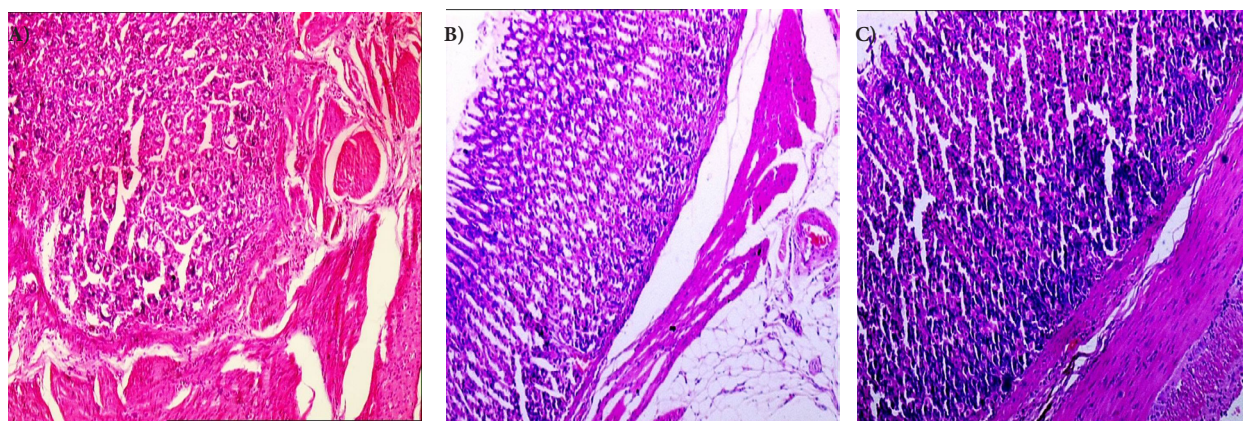


Figure 1. Light Microscopic Appearance of Stomach Sample from A) Control Group that Received MNNG Only, B) Rat Group that Received Mirtazapine and MNNG, C) Rat Group that Received Cisplatin and MNNG.

was investigated. Anticancer activity of mirtazapine was evaluated by comparison with cisplatin. Results showed that mirtazapine prevented MNNG-induced adenocarcinoma in rats. It was determined that suppression of development of adenocarcinoma was higher with mirtazapine as compared to cisplatin. In gastric samples of some of the cisplatin-administered rats, severe dysplasia was observed whereas in others, mild dysplasia was seen. No severe dysplasia was seen in gastric samples of mirtazapine-administered rats. In gastric samples of all mirtazapine-administered rats, only mild dysplasia was observed.

In the early 1980s, guidelines for the diagnosis and grading of GED were developed and a three-tiered classification of mild, moderate and severe dysplasia was proposed. Dysplasia was defined as "unequivocally neoplastic epithelium that may be associated with or give rise to invasive adenocarcinoma" (Morson et al., 1980; Ming et al., 1984; Ren et al., 2011). Gastric dysplasia is usually observed on the basis of long-term chronic irritation of mucosa. Extent of dysplasia is parallel to severity of chronic irritation (Owen, 1997). Gastric dysplasia is the gastric lesion most frequently associated with development of gastric carcinoma. In practice, it may be regarded as an atypical differentiation of gastric mucosa with a potential for malignancy (Fenoglio-Preiser, 2000; Carter, 2004). In classification of low, middle and high grade cases, it was determined that a great majority of low-grade dysplasia cases regress in time. This indicates that these lesions rather have a reactive nature. On the contrary, it was shown that only 5% of high-grade dysplasia cases regress while 80% progress to carcinoma (Bearzi et al., 1994).

In literature, it was suggested that increase in sympathetic nervous system activation may be associated with an increase in gastric carcinogenesis (Tatsuta et al., 1991). Diet low in calcium causes a considerable increase in incidence of gastric cancer by elevating norepinephrine concentration in the gastric wall (Tatsuta et al., 1993). Tyrosine methyl ester also produced a carcinogenic effect by increasing norepinephrine concentration in gastric wall, without affecting gastric pH or serum gastrin levels (Tatsuta et al., 1991). Severity of MNNG-induced cancer was found to be higher than animals in whom DOCA+NaCl was administered (Tatsuta et al., 1991). In DOCA+NaCl-administered animals, blood pressure was elevated and this elevation was associated with increase in catecholamine synthesis (Champlain et al., 1969). On the other hand, in some trials, it was shown that suppression of sympathetic system has no role in anticancer activity; e.g. it was found that clonidine, a sympatholytic agent, has no anticancer activity (Tatsuta et al., 1998). This, in turn indicates that sympatholytic effect is not important in terms of anticancer activity. Besides, it's well known that there is no association between antidepressant effect and sympathetic activity. This can be further explained by existence of antidepressant agents which increase noradrenergic and dopaminergic activity (amoxapine, reboxetine) and, on the other hand, by existence of agents which have no effect (trimipramin) or even agents which suppress this activity (tianeptin) (Baldessarini, 2005).

Anticancer activity of mirtazapine may not be due to its antidepressant effect because relevance of importance related to antidepressant activity seen in humans for animals is not known. It was suggested that use of antioxidants decreases risk of cancer. On the other hand, cancer can not be prevented by using natural or synthetic nutritive substances or drugs with antioxidant properties. Even though it was reported that antioxidants like vitamin C, E and carotene may decrease risk of gastric cancer (Crew et al., 2006), degree of efficacy against cancer is controversial.

In experimental animals, it was shown that mirtazapine suppresses oxidant parameters and increase antioxidant parameters in gastric tissues (Bilici et al., 2009). It was found that mirtazapine and a number of antidepressant agents have a preventive effect in gastrum (Bilici et al., 2009; Dursun et al., 2009; Suleyman et al., 2009). Nevertheless, this does not mean that gastroprotective properties are associated with antidepressant activity. This is further supported by the fact that certain antidepressant drugs from the same group do not have gastroprotective effects or even cause gastric damage (Suleyman et al., 2009). In this trial, we argue that mirtazapine possess anticancer activity in addition to antidepressant and α antagonistic properties. It was shown that mirtazapine is not a toxic agent and it even prevents (antagonizes) toxic effect of indomethacin on gastric tissue. On the other hand, drugs used in cancer therapy are known as cytotoxic agents (Chabner et al., 2006). In conclusion, it was found that prevention against MNNG-induced gastric adenocarcinoma model in rats is more prominent by mirtazapine, as compared to cisplatin. Further extensive studies are required in order to explain mechanism of action of mirtazapine related to anticancer activity.

References

- Baldessarini RJ (2005). Drug therapy of depression and anxiety disorders in 'goodman & gilman's the pharmacological basis of therapeutics'. Brunton LL, Lazo JS and Parker KL (eds). New-York, McGraw-Hill, **11**, 429-60.
- Bearzi I, Brancorsini D, Santinelli AD, et al (1994). Gastric dysplasia: a ten-year follow-up study. *Pathol Res Pract*, **190**, 61-8.
- Berard RM (2001). Depression and anxiety in oncology: the psychiatrist's perspective. *J Clin Psychiatry*, **62**, 58-61.
- Bilici M, Ozturk C, Dursun H, et al (2009). Protective effect of mirtazapine on indomethacin-induced ulcer in rats and its relationship with oxidant and antioxidant parameters. *Dig Dis Sci*, **54**, 1868-75.
- Chabner BA, Amrein PC, Druker B, et al (2006). Antineoplastic agents. in 'goodman and gilman's the pharmacological basis of therapeutics'. Brunton LL, Lazo JS and Parker KL (eds). New-York, McGraw-Hill. **11**, 1315-404.
- Chan AO, Wong BC, Lam SK (2001). Gastric cancer: past, present and future. *Can J Gastroenterol*, **15**, 469-74.
- Chow WH, Blot WJ, Vaughan TL, et al (1998). Body mass index and risk of adenocarcinomas of the esophagus and gastric cardia. *J Natl Cancer Inst*, **90**, 150-5.
- Crew KD, Neugut AI (2006). Epidemiology of gastric cancer. *World J Gastroenterol*, **12**, 354-62.
- De Champlain J, Mueller RA, Axelrod J (1969). Turnover and synthesis of norepinephrine in experimental hypertension

- in rats. *Circ Res*, **25**, 285-91.
- Dursun H, Bilici M, Albayrak F, et al (2009). Antiulcer activity of fluvoxamine in rats and its effect on oxidant and antioxidant parameters in stomach tissue. *BMC Gastroenterology*, **9**, 36.
- Fenoglio-Preiser C, Carnerio F, Correa P, et al (2000). Gastric carcinoma. In 'WHO classification of tumours, pathology and genetics tumours of the digestive system tumours of the stomach'. hamilton sr, altonen LA (eds). *IARC Press Lyon*, 39-52.
- Guldahl M (1977). The effect of trimipramine (Surmontil r) on masked depression in patients with duodenal ulcer. A double-blind study. *Scand J Gastroenterol*, **43**, 27-31.
- Hishida A, Matsuo K, Goto Y, et al (2010). Smoking behavior and risk of Helicobacter pylori infection, gastric atrophy and gastric cancer in Japanese. *Asian Pac J Cancer Prev*, **11**, 669-73.
- Iishi H, Tatsuta M, Baba M, et al (1998). Promotion by the alpha-adrenoceptor agonist phenylephrine, but not by the beta-adrenoceptor agonist isoproterenol, of gastric carcinogenesis induced by N-methyl-N'-nitro-N-nitrosoguanidine in Wistar rats. *Cancer Lett*, **122**, 61-5.
- Levine PH, Stemmermann G, Lennette ET, et al (1995). Elevated antibody titers to Epstein-Barr virus prior to the diagnosis of Epstein-Barr-virus-associated gastric adenocarcinoma. *Int J Cancer*, **60**, 642-4.
- Liu Z, Xu X, Chen L, et al (2012). Helicobacter pylori CagA inhibits the expression of RUNX3 via Src/MEK/ERK and p38 MAPK pathways in gastric epithelial cell. *J Cell Biochem*, **113**, 1080-6.
- Ming SC, Bajtai A, Correa P, et al (1984). Gastric dysplasia. Significance and pathologic criteria. *Cancer*, **54**, 1794-801.
- Morson BC, Sobin LH, Grundmann E, et al (1980). Precancerous conditions and epithelial dysplasia in the stomach. *J Clin Pathol*, **33**, 711-21.
- Onitilo AA, Nietert PJ, Egede LE (2006). Effect of depression on all-cause mortality in adults with cancer and differential effects by cancer site. *Gen Hosp Psychiatry*, **28**, 396-402.
- Owen DA (1997). Alimentary canal, stomach. In 'Histology for Pathologists'. Sternberg SS (ed). Philadelphia, *Lippincott Williams and Wilkins*, 481-95.
- Owen DA (2004). Alimentary canal and associated organs the stomach. in 'sternberg's diagnostic surgical pathology', Carter D, Greenson JK, Oberman HA, Reuter V, Stoler MH, Emills S, (eds). Philadelphia, *Lippincott Williams Wilkins*, 1435-75.
- Ren LL, Fang JY (2011). Should we sound the alarm? Dysplasia and colitis-associated colorectal cancer. *Asian Pac J Cancer Prev*, **12**, 1881-6.
- Sugimura, T, M Terada (1998). Experimental chemical carcinogenesis in the stomach and colon. *Jpn J Clin Oncol*, **28**, 163-7.
- Suleyman H, Cadirci E, Albayrak A, et al (2010). Occurrence of anticancer activity of prednisolone via adrenalectomy and inhibition of adrenaline in rats. *Int J Cancer*, **126**, 1740-8.
- Suleyman H, Cadirci E, Albayrak A, et al (2009). Comparative study on the gastroprotective potential of some antidepressants in indomethacin-induced ulcer in rats. *Chem Biol Interact*, **180**, 318-24.
- Tatematsu M, Takahashi M, Fukushima S, et al (1975). Effects in rats of sodium chloride on experimental gastric cancers induced by N-methyl-N'-nitro-N-nitrosoguanidine or 4-nitroquinoline-1-oxide. *J Natl Cancer Inst*, **55**, 101-6.
- Tatsuta M, Iishi H, Baba M, Taniguchi H (1989). Promotion by nialamide of gastric carcinogenesis induced by N-methyl-N'-nitro-N-nitrosoguanidine in Wistar rats. *Jpn J Cancer Res*, **80**, 521-5.
- Tatsuta M, Iishi H, Baba M, Taniguchi H (1991). Enhanced induction of gastric carcinogenesis by N-methyl-N'-nitro-N-nitrosoguanidine in deoxycorticosterone acetate-NaCl hypertensive rats and its inhibition by potassium chloride. *Cancer Res*, **51**, 2863-6.
- Tatsuta M, Iishi H, Baba M, Taniguchi H (1991). Enhancement by tyrosine methyl ester of gastric carcinogenesis induced by N-methyl-N'-nitro-N-nitrosoguanidine in Wistar rats. *Int J Cancer*, **48**, 785-8.
- Tatsuta M, Iishi H, Baba M, Taniguchi H (1992). Inhibition of azoxymethane-induced experimental colon carcinogenesis in Wistar rats by 6-hydroxydopamine. *Int J Cancer*, **50**, 298-301.
- Tatsuta M, Iishi H, Baba M, et al (1993). Enhancing effects of calcium-deficient diet on gastric carcinogenesis by N-methyl-N'-nitro-N-nitrosoguanidine in Wistar rats. *Jpn J Cancer Res*, **84**, 945-50.
- Tatsuta M, Iishi H, Baba M, et al (1998). Alpha1-adrenoceptor stimulation enhances experimental gastric carcinogenesis induced by N-methyl-N'-nitro-N-nitrosoguanidine in Wistar rats. *Int J Cancer*, **77**, 467-9.
- Thompson DE, Mabuchi K, Ron E, et al (1994). Cancer incidence in atomic bomb survivors. Part II: Solid tumors, 1958-1987. *Radiat Res*, **137**, 17-67.