

RESEARCH ARTICLE

Anti-Cell Proliferative Efficacy of Ferulic Acid Against 7, 12-dimethylbenz(a) Anthracene Induced Hamster Buccal Pouch Carcinogenesis

M Manoj Prabhakar¹, K Vasudevan², S Karthikeyan¹, N Baskaran¹, S Silvan¹, S Manoharan^{1*}

Abstract

The present study was designed to explore the anti-cell proliferative efficacy of ferulic acid by analysing the expression pattern of cell proliferative markers, proliferating cellular nuclear antigen (PCNA) and cyclin D1, in the buccal mucosa of golden Syrian hamsters treated with 7,12-dimethylbenz(a)anthracene (DMBA). Oral squamous cell carcinomas developed in the buccal pouch of hamsters using topical application of 0.5% DMBA three times a week for 14 weeks. Immunohistochemical (PCNA) and RT-PCR (Cyclin D1) analysis revealed over expression of PCNA and cyclin D1 in the buccal mucosa of hamsters treated with DMBA alone (tumor bearing hamsters). Oral administration of ferulic acid at a dose of 40 mg/kg bw to hamsters treated with DMBA not only completely prevented the tumor formation but also down regulated the expression of PCNA and cyclin D1. The results of the present study thus suggests that ferulic acid might have inhibited tumor formation in the buccal mucosa of hamsters treated with DMBA through its anti-cell proliferative potential as evidenced by decreased expression of PCNA and cyclin D1.

Keywords: Oral cancer - hamster buccal cavity - DMBA - ferulic acid - cyclin D1 - PCNA.

Asian Pacific J Cancer Prev, **13** (10), 5207-5211

Introduction

Malignant tumors are characterized by abnormal cell proliferation, invasion and metastasis (Misery et al., 2003). Worldwide, oral cancer is one of the most common malignancies and affects around 5,000,000 new cases every year (Sharma et al., 2010a). Oral cancer incidence is predominant in South East Asia and 62% of the total cases of oral cancers are reported from developing countries. In India, oral cancer is accounting for 40-50% of all cancers (Gaur et al., 2011). Tobacco smoking and chewing, betel quid chewing and alcohol abuse are the primary risk factors associated with pathogenesis of oral carcinogenesis (Radoi et al., 2012). Despite recent advancement in the treatment strategy, the five year survival rate of oral cancer patients is still disappointingly stable due to late diagnosis. Early diagnosis and appropriate treatment modalities at right time for oral cancer could help to markedly improve the survival rates of oral cancer patients (Pierce et al., 2012). Epidemiological and cohort studies also pointed out that oral cancer incidence can be minimized by avoiding the use of well known risk factors of oral cancer (Seoane et al., 2012).

7,12-dimethylbenz(a)anthracene (DMBA) is

commonly employed to develop oral carcinoma in the buccal mucosa of golden syrian hamsters (Palanimuthu et al., 2012). Repeated and regular interval of topical application of DMBA resulted in tumor formation in the buccal mucosa of golden syrian hamsters. DMBA mediates carcinogenesis in the buccal mucosa through induction of chronic inflammation and formation of DNA adducts as well as by causing reactive oxygen species mediated oxidative DNA damage (Silvan et al., 2011). Oral tumors that are developed in the hamster's buccal mucosa using DMBA mimics human oral tumors histologically, biochemically and at molecular level (Nagini, 2009). DMBA induced hamster buccal pouch carcinogenesis is thus considered as an ideal experimental model to study the anti-cell proliferative potential of natural products and synthetic entities.

Proliferating cell nuclear antigen (PCNA), an auxillary factor of DNA polymerase, is not only essential for eukaryotic replication but also plays pivotal role in several DNA damage responsive pathways (Gazy and Kupiec, 2012). PCNA is a well known marker for cell proliferation. It tends to accumulate in the late G1 and S-phase of the cell cycle (Tan et al., 2012). A monoclonal antibody against PCNA is now available to detect the expression

¹Department of Biochemistry and Biotechnology, ²Department of Zoology, Faculty of Science, Annamalai University, Annamalainagar Tamilnadu, India *For correspondence: rasmanshisak@gmail.com

of PCNA and it can react with paraffin-embedded tissue specimens. PCNA expression was found to be increased from hyperplastic epithelium to dysplastic epithelium and then to squamous cell carcinoma in oral carcinogenesis (Manoharan et al., 2011). Cyclin D1 is involved in the regulation of G1 to S phase transition in the cell cycle. Cyclin D1 over expression contributes to the malignant progression of various epithelial tumors (Li et al., 2012; Wang et al., 2012). Over expression of Cyclin D1 in normal cells results in a malignant phenotype whereas suppression of Cyclin D1 activity in malignant cells results in disappearance of the malignant phenotype (Lee et al., 2012).

Ferulic acid, a hydroxy cinnamic acid, is found in the seeds of coffee, apple, peanut and orange. This phenolic phytochemical is also found in rice, wheat, oats and pineapple (Zhao et al., 2008). Ferulic acid possesses multiple pharmacological and biological effects including anti-inflammatory, hepatoprotective, anticancer and antioxidant properties (Anselmi et al., 2004; Rukkumani et al., 2004). Ferulic acid supplementation inhibited melanin production in the process of skin whitening. *In vivo* and *in vitro* studies demonstrated the anti-tumor potential of ferulic acid against several cancers including oral carcinoma (Balakrishnan et al., 2010; Janicke et al., 2011). Previous studies from our laboratory demonstrated the chemopreventive and pro-apoptotic potential of ferulic acid in DMBA induced hamster buccal pouch carcinogenesis (Balakrishnan et al., 2008; 2010). The present study demonstrates the anti-cell proliferative effect of ferulic acid in the buccal mucosa of golden syrian hamsters treated with a potent carcinogen, DMBA.

Materials and Methods

Chemicals

7,12-dimethylbenz(a)anthracene, and ferulic acid were purchased from Sigma-Aldrich Chemical Pvt. Ltd., Bangalore, India. PCNA primary antibody was purchased from Dako, Carpinteria, CA, USA. Power Block™ reagent and secondary antibody conjugated with horseradish peroxidase were purchased from BioGenex, San Ramon, CA, USA. Trizol reagent was purchased from Invitrogen, CA, USA. cDNA reverse transcriptase kit and SYBR green fluorophore assay reagents were purchased from Applied Biosystems, Foster City, CA. Oligo nucleotide primers were purchased from Bangalore Genei.

Animals

Male golden Syrian hamsters, aged 8-10 weeks, weighing 80-120 g, were purchased from the National Institute of Nutrition, Hyderabad, India and were maintained in the Central Animal House, Rajah Muthaiah Medical College and Hospital, Annamalai University. The animals were housed five in a polypropylene cage and provided with a standard pellet diet (Agro Corporation Pvt. Ltd., Bangalore, India) and water *ad libitum*. The animals were maintained under controlled conditions of temperature (27±2°C) and humidity (55±5%) with a 12h light/dark cycle.

Experimental protocol

The local institutional animal ethics committee (Register number 160/1999/CPCSEA), Annamalai University, Annamalainagar, India, approved the experimental design. The animals were maintained as per the principles and guidelines of the ethical committee for animal care of Annamalai University in accordance with Indian National Law on animal care and use. A total number of 40 hamsters were randomized into four groups of ten hamsters in each. Group I hamsters served as control and were painted with liquid paraffin alone three times a week for 14 weeks on their left buccal pouches. Groups II and III hamsters were painted with 0.5% DMBA in liquid paraffin three times a week for 14 weeks on their left buccal pouches. Group II received no other treatment. Group III hamsters were orally given ferulic acid at a dose of 40 mg/kg body weight /day, starting one week before the exposure to the carcinogen and continued on days alternate to DMBA painting until the end of the experiment. Group IV hamsters received oral administration of ferulic acid alone throughout the experimental period. The experiment was terminated at the end of 16th week and all animals were sacrificed by cervical dislocation.

Immunohistochemical staining

Paraffin embedded tissue sections were dewaxed and rehydrated through graded ethanol to distilled water. Endogenous peroxidase was blocked by incubation with 3% H₂O₂ in methanol for 10 minutes. The antigen retrieval was achieved by microwave in citrate buffer solution (2.1 g citric acid/L.D.H₂O; 0.37g EDTA/L.D.H₂O; 0.2 g Trypsin) (pH 6.0) for 10 minutes, followed by washing step with Tris-buffered saline (8 g NaCl; 0.605 g Tris) (pH 7.6). The tissue section was then incubated with power Block™ reagent (BioGenex, San Ramon, CA, USA), universal proteinaceous blocking reagent, for 15 minutes at room temperature to block non-specific binding sites. The tissue sections were then incubated with the PCNA primary antibody (PCNA-Dako, Carpinteria, CA, USA) overnight at 4°C. The bound primary antibody was detected by incubation with the secondary antibody conjugated with horseradish peroxidase (BioGenex, San Ramon, CA, USA) for 30 minutes at room temperature. After rinsing with Tris-buffered saline, the antigen-antibody complex was detected using 3,3'-diaminobenzidine, the substrate of horseradish peroxidase. When acceptable color intensity was reached, the slides were washed, counter stained with hematoxylin and covered with a mounting medium. Each slide was microscopically analyzed and enumerated the percentage of the positively stained cells semi-quantitatively. The percentage of positive cells was scored according to the method of Nakagawa et al., (1994) as follows: 3+=strong staining, more than 50% of cells were stained; 2+=moderate staining, between 20 and 50% of cells were stained; 1+=weak staining, between 1 and 20% of cells were stained; 0=negative, less than 1% of cell staining.

Expression of Cyclin D1 using Real Time PCR

Total RNA from the buccal mucosa was extracted with Trizol reagent. The RNA integrity and concentration

was determined by electrophoresis on agarose gel and nanodrop analysis at 260 nm. Isolated total RNA (1 μ g) was reverse transcribed to cDNA with random primers from the High cDNA Reverse Transcriptase Kit. cDNA was amplified in duplicates using a thermal cycler (9700 HT RT-PCR, Applied Biosystem, UK) for the expression of Cyclin D1 and β -actin with SYBR green fluorophore following the manufacturer's recommended amplification procedure. List of primers used for Real-time PCR analysis was given in Table 1. The relative quantification of target gene expression was determined using the comparative CT method. The Δ Ct was calculated as the difference between the average Ct values of the endogenous control (β -actin) from the average Ct value of test gene. The $\Delta\Delta$ Ct was determined by subtracting the Δ Ct of the control from the Δ Ct of the test sample. Relative expression of the target gene was calculated by the formula, $2^{\Delta\Delta Ct}$, which was the amount of gene product, normalised to the endogenous control and relative to the control sample.

Statistical analysis

The data for Cyclin D1 is expressed as mean \pm standard deviation (S.D.) Statistical comparisons were performed by one-way analysis of variance followed by Duncan's Multiple Range Test. The statistical evaluation for the score of positively stained cells of PCNA was analyzed using Chi-square (χ^2) test. The results were considered statistically significant if the p values were less than 0.05.

Results

The immunoexpression pattern of cell proliferative (PCNA) marker and the score of positively stained cells in the control and experimental hamsters in each group are depicted in Figure 1 and Table 2 respectively. Over expression of PCNA was noticed in hamsters treated with DMBA alone. Oral administration of ferulic acid at a dose of 40 mg/kg bw to hamsters treated with DMBA significantly restored the expression of PCNA. Hamsters treated with ferulic acid alone revealed expression similar to that of control hamsters.

The primer melting curve and the fold increase in the Cyclin D1 mRNA expression pattern of control and experimental hamsters in each group is depicted in Figure 2 and Figure 3 respectively. The expression of Cyclin D1 was significantly higher in hamsters treated with DMBA alone as compared to control hamsters. Oral administration of ferulic acid to hamsters treated with DMBA suppressed the expression of Cyclin D1. Similar expression pattern of Cyclin D1 was observed in control hamsters and hamsters treated with ferulic acid alone.

Table 1. List of Primers Used for Real-Time PCR Analysis

Genes	Primers	Sequences
Cyclin D1	forward	5'-CGGAGGACAACAACAGATC-3';
	reverse	5'-GGGTGTGCAAGCCAGGTCCA-3'
β -actin	forward	5'-AACC CGGAGAAGATGACCCAGATCATGTTT-3'
	reverse	5'-AGCAGCCGTGGCCATCTCTTGCTCGAAGTC-3'

Table 2. The Score of Positively Stained Cells of PCNA in the Control and Experimental Hamsters in each Group

Groups / Markers	PCNA			
	0	1+	2+	3+
Control	10	0	0	0
DMBA	0	1	2	7 ^a
DMBA+Ferulic acid	0	6	3	1 ^b
Ferulic acid alone	9	1	0	0

*The percentage positive cells were scored as: 3+, strong staining; 2+, moderate staining; 1+, weak staining; and 0, negative. ^ap < 0.05 vs control hamsters and ^bp < 0.05 vs hamsters treated with DMBA alone (χ^2 test)

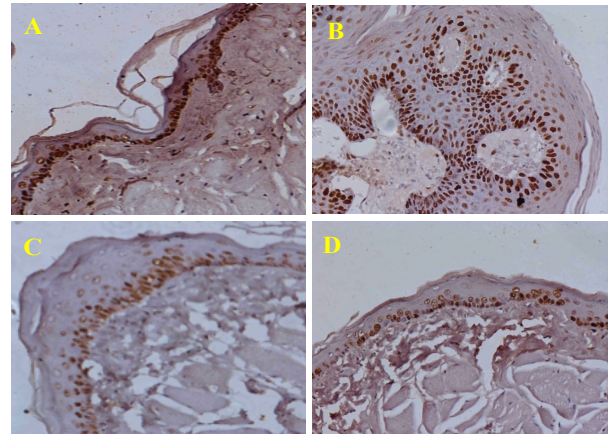


Figure 1. Immunoexpression Pattern of PCNA Protein in the Buccal Mucosa of Control and Experimental Hamsters in Each Group (40X). *A and D - Control and Ferulic acid alone (expression not detectable); B - DMBA alone (over expressed); C - DMBA+Ferulic acid (down regulated)

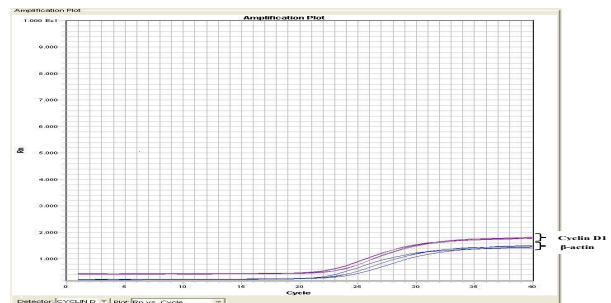


Figure 2. RT-PCR Primers Melting Curve for Cyclin D1 mRNA Expression Pattern of Control and Experimental Hamsters in Each Group

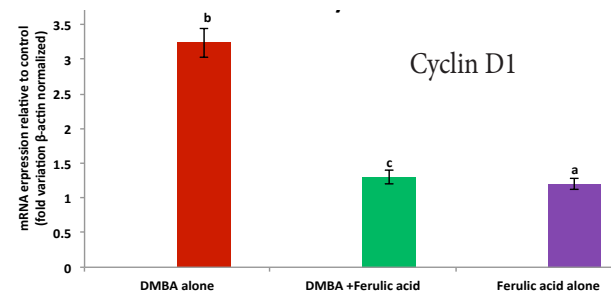


Figure 3. Fold Increase in the mRNA Expression Pattern for Cyclin D1 in Hamsters Treated with DMBA Alone, DMBA+Ferulic Acid and Ferulic Acid alone. Values are expressed as mean \pm SD for 10 hamsters in each group. * Values that do not share a common superscript letter between groups differ significantly at p < 0.05. (DMRT)

Discussion

The aim of the present study was to explore the anti-cell proliferative potential of ferulic acid by analyzing the expression pattern of cell proliferative markers PCNA and Cyclin D1 in DMBA induced hamster buccal pouch carcinogenesis. In the present study, 100% tumor formation was noticed in hamsters treated with DMBA alone. Oral administration of ferulic acid at a dose of 40 mg/kg bw completely prevented the tumor formation, which suggests that ferulic acid might have inhibited abnormal proliferation during DMBA induced hamster buccal pouch carcinogenesis. To validate its anti-cell proliferative potential PCNA and Cyclin D1 expression was utilized as markers of cell proliferation.

Carcinogenesis arises due to dysregulation of genes involved in cell differentiation and proliferation. The prognostic significance of various cancers is associated with the rate of cell proliferation (Botti et al., 2011). PCNA plays a pivotal role in cellular proliferation, DNA replication and repair (Tainer et al., 2010). The expression pattern of PCNA could be used as a putative marker to assess the tumor progression. A positive association between PCNA expression and prognosis has been reported (Stenner et al., 2012). Over expression of PCNA has been demonstrated in precancerous and cancerous lesions of the oral cavity (Kato et al, 2011). Our results corroborate the above findings. In the present study, immunohistochemical studies revealed overexpression of PCNA in hamsters treated with DMBA alone. The results of the present study thus suggests that DMBA induced abnormal cell proliferation in the buccal mucosa of the golden Syrian hamsters.

Cyclin D1 plays a prominent role as a critical effector of G1-S phase progression in the cell cycle (Shen et al., 2006). It has been pointed out that downregulation of Cyclin D1 leads to cell cycle arrest and suppression of cell proliferation. Cyclin D1 also plays pivotal role in the regulation of cell proliferation and differentiation (Jirawatnotai et al., 2012). Over expression of Cyclin D1 is a common phenomenon at early stages of oral carcinogenesis (Mineta et al., 2000). The Cyclin D1 oncogene is frequently amplified/over expressed in oral squamous cell carcinomas (Vinothkumar et al., 2012). Over expression of Cyclin D1 is associated with poor prognosis in head and neck cancers (Cao et al., 2012). Abnormal expression of Cyclin D1 has been reported both in human and experimental oral carcinogenesis (Cao et al., 2012; Manoharan et al., 2011). Our results are in line with these findings. In the present study, over expression of Cyclin D1 mRNA expression pattern was shown in hamsters treated with DMBA lone, which clearly indicates that DMBA induced abnormal cell proliferation in the buccal mucosa of golden syrian hamsters.

Natural products or synthetic chemical entities that prevent abnormal cellular proliferation by preventing the over expression of PCNA and Cyclin D1 will emerge as a novel antitumor agent (Sharma et al., 2010b; Manoharan et al., 2011). In the present study, oral administration of ferulic acid at a dose of 40 mg/ kg bw to hamsters treated with DMBA down regulated the expression pattern of

PCNA and Cyclin D1. The results of the present study thus suggest that ferulic acid might have inhibited the tumor formation in the buccal mucosa by markedly inhibiting the abnormal cell proliferation occurring in DMBA induced oral carcinogenesis. The present study thus concludes that ferulic acid can be used as a potent candidature or as adjuvant for inhibiting abnormal proliferation occurring in cancerous conditions.

Acknowledgements

Financial support from University Grants Commission, New Delhi is gratefully acknowledged.

References

- Anselmi C, Centini M, Andreassi M, et al, (2004). Conformational analysis: a tool for the elucidation of the antioxidant properties of ferulic acid derivatives in membrane models. *J Pharm Biomed Anal*, **35**, 1241-49.
- Balakrishnan S, Manoharan S, Alias LM, et al (2010). Effect of curcumin and ferulic acid on modulation of expression pattern of p53 and bcl-2 proteins in 7,12-dimethylbenz[a]anthracene-induced hamster buccal pouch carcinogenesis. *Indian J Biochem Biophys*. **47**, 7-12.
- Balakrishnan S, Menon VP, Manoharan S, et al (2008). Ferulic acid inhibits 7,12-dimethylbenz[a]anthracene induced hamster buccal pouch carcinogenesis. *J Med Food*, **11**, 693-700.
- Botti E, Spallone G, Moretti F, et al (2011). Developmental factor IRF6 exhibits tumor suppressor activity in squamous cell carcinomas. *Proc Natl Acad Sci U S A*, **108**, 13710-5.
- Cao W, Feng Z, Cui Z, et al (2012). Up-regulation of enhancer of zeste homolog 2 is associated positively with Cyclin D1 overexpression and poor clinical outcome in head and neck squamous cell carcinoma. *Cancer*, **118**, 2858-71.
- Gaur P, Mittal M, Mohanti BK, et al (2011). Functional genetic variants of TGF- β 1 and risk of tobacco-related oral carcinoma in high-risk Asian Indians. *Oral Oncol*, **47**, 1117-21.
- Gazy I, Kupiec M (2012). The importance of being modified: PCNA modification and DNA damage response. *Cell Cycle*, **11**, 2620-3.
- Janicke B, Hegardt C, Krogh M, et al (2011). The antiproliferative effect of dietary fiber phenolic compounds ferulic acid and p-coumaric acid on the cell cycle of Caco-2 cells. *Nutr Cancer*, **63**, 611-22.
- Jirawatnotai S, Hu Y, Livingston DM, et al (2012). Proteomic identification of a direct role for Cyclin d1 in DNA damage repair. *Cancer Res*, **72**, 4289-93.
- Kato K, Kawashiri S, Yoshizawa K, et al (2011). Expression form of p53 and PCNA at the invasive front in oral squamous cell carcinoma: correlation with clinicopathological features and prognosis. *J Oral Pathol Med*, 10.1111/j.1600-0714.2011.01032.x. ??????
- Lee CH, Ali RH, Rouzbahman M, et al (2012). Cyclin D1 as a diagnostic immunomarker for endometrial stromal sarcoma with YWHAЕ-FAM22 rearrangement. *Am J Surg Pathol*, **36**, 1562-70.
- Li Y, Zhang S, Geng JX, et al (2012). Effects of the Cyclin D1 Polymorphism on Lung Cancer Risk - a Meta-analysis. *Asian Pac J Cancer Prev*, **13**, 2325-8.
- Manoharan S, Sindhu G, Nirmal MR, et al (2011). Protective effect of berberine on expression pattern of apoptotic, cell proliferative, inflammatory and angiogenic markers during

- 7,12-dimethylbenz(a)anthracene induced hamster buccal pouch carcinogenesis. *Pak J Biol Sci*, **14**, 918-32.
- Mineta H, Miura K, Takebayashi S, et al (2000). Cyclin D1 overexpression correlates with poor prognosis in patients with tongue squamous cell carcinoma. *Oral Oncol*, **36**, 194-8.
- Misery L, Godard W, Hamzeh H, et al (2003). Malignant Langerhans cell tumor: a case with a favorable outcome associated with the absence of blood dendritic cell proliferation. *J Am Acad Dermatol*, **49**, 527-9.
- Nagini S (2009). Of humans and hamsters: the hamster buccal pouch carcinogenesis model as a paradigm for oral oncogenesis and chemoprevention. *Anticancer Agents Med Chem*, **9**, 843-52.
- Nakagawa K, Yamamura K, Maeda S, et al (1994). Bcl-2 expression in epidermal keratinocytic diseases. *Cancer*, **74**, 1720-4.
- Palanimuthu D, Baskaran N, Silvan S, et al (2012). Lupeol, a bioactive triterpene, prevents tumor formation during 7,12-Dimethylbenz(a)anthracene induced oral carcinogenesis. *Pathol Oncol Res*, **18**, 1029-37.
- Pierce MC, Schwarz RA, Bhattar VS, et al (2012). Accuracy of in vivo multimodal optical imaging for detection of oral neoplasia. *Cancer Prev Res (Phila)*, **5**, 801-9.
- Radoi L, Luce D (2012). A review of risk factors for oral cavity cancer: the importance of a standardized case definition. *Community Dent Oral Epidemiol*, doi: 10.1111/j.1600-0528.2012.00710.x.???
- Rukkumani R, Aruna K, Varma P S, et al (2004). Influence of ferulic acid on circulatory prooxidant anti-oxidant status during alcohol and PUFA induced toxicity. *J Physiol Pharmacol*, **55**, 551-561.
- Seoane J, Varela-Centelles P, Tomás I, et al (2012). Continuing education in oral cancer prevention for dentists in Spain. *J Dent Educ*, **76**, 1234-40.
- Sharma P, Saxena S, Aggarwal P (2010a). Trends in the epidemiology of oral squamous cell carcinoma in Western UP: an institutional study. *Indian J Dent Res*, **21**, 316-9.
- Sharma SD, Katiyar SK (2010b). Dietary grape seed proanthocyanidins inhibit UVB-induced cyclooxygenase-2 expression and other inflammatory mediators in UVB-exposed skin and skin tumors of SKH-1 hairless mice. *Pharm Res*, **27**, 1092-102.
- Shen G, Xu C, Chen C, et al (2006). p53-independent G1 cell cycle arrest of human colon carcinoma cells HT-29 by sulforaphane is associated with induction of p21CIP1 and inhibition of expression of Cyclin D1. *Cancer Chemother Pharmacol*, **57**, 317-27.
- Silvan S, Manoharan S, Baskaran S, et al (2011). Chemopreventive potential of apigenin in 7,12-dimethylbenz(a)anthracene induced experimental oral carcinogenesis. *Eur J Pharm*, **670**, 571-7.
- Stenner M, Demgensky A, Molls C, et al (2012). Prognostic value of proliferating cell nuclear antigen in parotid gland cancer. *Eur Arch Otorhinolaryngol*, **269**, 1225-32.
- Tainer JA, McCammon JA, Ivanov I (2010). Recognition of the ring-opened state of proliferating cell nuclear antigen by replication factor C promotes eukaryotic clamp-loading. *J Am Chem Soc*, **132**, 7372-8.
- Tan Z, Wortman M, Dillehay KL, et al (2012). Small-molecule targeting of proliferating cell nuclear antigen chromatin association inhibits tumor cell growth. *Mol Pharmacol*, **81**, 811-9.
- Vinothkumar V, Manoharan S, Sindhu G, et al (2012). Geraniol modulates cell proliferation, apoptosis, inflammation, and angiogenesis during 7,12-dimethylbenz[a]anthracene-induced hamster buccal pouch carcinogenesis. *Mol Cell*
- Wang Y, Rao VK, Kok WK, et al (2012). SUMO Modification of str13 is required for repression of cyclin D1 Expression and cellular growth arrest. *PLoS One*, **7**, e43137.
- Zhao Z, Moghadasian M H (2008). Chemistry, natural sources, dietary intake and pharmacokinetic properties of ferulic acid: a review. *Food Chem*, **10**, 691-702.