

RESEARCH ARTICLE

Anti-tumor Initiating Potential of Andrographolide in 7,12-dimethylbenz[a]anthracene Induced Hamster Buccal Pouch Carcinogenesis

S Manoharan^{1*}, Arjun Kumar Singh¹, K Suresh¹, K Vasudevan², R Subhasini¹, N Baskaran¹

Abstract

The aim of the study was to investigate the chemopreventive potential of andrographolide in 7,12-dimethylbenz(a)anthracene (DMBA)-induced hamster buccal pouch carcinogenesis. Oral tumors developed in the buccal pouch of golden Syrian hamsters at a 100% incidence on painting with 0.5% DMBA in liquid paraffin three times a week for 14 weeks. Marked abnormalities in the status of detoxification enzymes, lipid peroxidation and antioxidants were noticed in hamsters treated with DMBA alone. Oral administration of andrographolide at a dose of 50 mg/kg bw to hamsters treated with DMBA not only completely prevented the tumor formation but also restored the status of the above mentioned biomarkers. The present study thus demonstrates the chemopreventive potential of andrographolide in DMBA-induced hamster buccal pouch carcinogenesis, which is probably due to its antioxidant potential as well as modulating effect on xenobiotic metabolising enzymes during DMBA-induced oral carcinogenesis.

Keywords: Andrographolide - antioxidants - detoxification enzymes - oral cancer

Asian Pacific J Cancer Prev, 13 (11), 5701-5708

Introduction

Oral cancer, one of the most common malignant neoplasms worldwide, is responsible for significant morbidity and mortality of human populations. It affects more than 500,000 new cases each year worldwide. The highest incidence rates of oral cancer are reported every year in developing countries particularly in India, where 40-50% of all malignancies are formed in the oral cavity. Tobacco chewing, smoking, betel quid chewing and alcohol consumption are associated with the highest incidence and pathogenesis of oral carcinogenesis in India. Despite advanced therapeutic approaches with surgery and radiation therapy, the mortality and morbidity of oral cancer patients have remained unchanged over the past few decades (Mocellin et al., 2006; Muwonge et al., 2008; Warnakulasuriya, 2009).

A well established experimental animal model is a prerequisite for the investigation of new chemopreventive agents and to understand the mechanisms of actions of chemopreventive agents during carcinogenesis. 7,12-dimethylbenz(a)anthracene (DMBA)-induced hamster buccal pouch carcinogenesis is the most commonly accepted model to study the biochemical alterations in oral carcinogenesis as well as to study the chemopreventive potential of natural products and synthetic agents. DMBA induced oral carcinogenesis

is preceded by sequential precancerous lesions such as hyperkeratosis, hyperplasia and dysplasia (6-8 weeks), which eventually turn into malignant tumors (10-14 weeks). DMBA induced oral tumor in hamsters mimics human oral tumor, morphologically, histopathologically and at molecular level (Nagini, 2009). DMBA, due to its procarcinogenic nature, is metabolized by phase I enzymes such as cytochrome P₄₅₀ to its ultimate carcinogenic metabolite, dihydrodiol epoxide, which binds to and damage DNA, contributing to mutation and carcinogenesis (Silvan et al., 2011). Reactive oxygen species (ROS) that are excessively generated during the metabolic activation of DMBA also contributes to the pathogenesis of cancer (Priyadarsini and Nagini, 2012).

Liver, the versatile organ involved in drug metabolism, metabolizes several toxic substances including mutagens and carcinogens. A chemical carcinogen mediates carcinogenesis by impairing the activities of drug metabolizing phase I (cytochrome P₄₅₀ and b₅) and II enzymes [glutathione-S-transferase (GST), glutathione reductase (GR)] and by generating excess reactive oxygen species. The carcinogenic metabolites that are generated during phase I reactions, are further detoxified or excreted by phase II enzymes by conjugating them with reduced glutathione (GSH) or glucuronic acid (Anusuya and Manoharan, 2011). It has been reported that an individual susceptibility to oral cancer may partly depend on the

¹Department of Biochemistry and Biotechnology, ²Department of Zoology, Faculty of Science, Annamalai University, Annamalai Nagar, Tamil Nadu, India *For correspondence: rasmanshisak@gmail.com

metabolic balance between phase I and phase II drug metabolizing enzymes (Murugan et al., 2008).

ROS, the by-products of several metabolic pathways, are formed by sequential reduction of molecular oxygen. ROS at physiological concentrations play crucial role in cell signaling pathways and phagocytosis. Over production of ROS within the cell can cause DNA base modification and lipid peroxidation, contributing to carcinogenesis (Klaunig et al., 2011). Mammalian cells are however endowed with sophisticated and comprehensive array of non-enzymatic (GSH, vitamin E) and enzymatic [superoxide dismutase (SOD), catalase (CAT) and glutathione peroxidase (GPx)] antioxidants to combat the deleterious effects of ROS. Vitamin E protects unsaturated lipid bilayers of cellular and subcellular membranes against ROS mediated oxidative stress (Letchoumy et al., 2007). Vitamin E and GSH inhibited the formation of oral tumors in experimental animals (Elango et al., 2006; Szumilo et al., 2012). Altered status of lipid peroxidation and antioxidants has been shown in oral carcinogenesis (Balakrishnan et al., 2008).

Michael Sporn as first coined the term 'chemoprevention' in 1976 to describe the inhibition, prevention or reversal of carcinogenesis by using natural products or synthetic entities. The goal of chemoprevention is to arrest or delay the tumor development rather than treating the existing tumor. *Andrographis paniculata*, a traditional medicinal herb, is used to treat several disorders including inflammation, hepatotoxicity and HIV in India, China, and other South Eastern Asian countries. Andrographolide, natural bicyclic diterpenoid lactones, is an active constituent of *Andrographis paniculata*. Experimental studies demonstrated diverse pharmacological effects of andrographolide including anti-inflammatory, antihyperglycemic, hepatoprotective and anticancer properties (Lin et al., 2009; Zhang et al., 2009). Previous studies from our laboratory demonstrated the antigenotoxic, pro-apoptotic and anti-inflammatory potential of andrographolide in experimental animal models (Manoharan et al., 2011; Shanmugam et al., 2012). Wang et al. (2011) demonstrated that andrographolide inhibited DMBA induced oral carcinogenesis through NF- κ B inactivation. The present study has investigated the chemopreventive potential of andrographolide by utilizing the status of lipid peroxidation, antioxidants and phase I and II detoxification enzymes as biochemical end points in DMBA-induced hamster buccal pouch carcinogenesis.

Materials and Methods

Chemicals

The carcinogen, DMBA and andrographolide were obtained from Sigma-Aldrich Chemical Pvt. Ltd., Bangalore, India. All other chemicals used were of analytical grade, purchased from Hi-media Laboratories, Mumbai, India.

Dose dependent study

Different doses of andrographolide (25, 50 and 75 mg/kg bw) were assessed to find out the chemopreventive effect of andrographolide in DMBA-induced hamster

buccal pouch carcinogenesis. A dose of 50 and 75 mg/kg bw andrographolide have shown potent chemopreventive potential in DMBA-treated hamsters as compared to the rest of the doses. Therefore, 50 mg/kg bw (low dose) was chosen for further chemoprevention study.

Experimental protocol

The local institutional animal ethics committee (Register number 160/1999/CPCSEA), Annamalai University, Annamalainagar, India, approved the experimental design. The animals were maintained as per the principles and guidelines of the ethical committee for animal care of Annamalai University in accordance with Indian National Law on animal care and use.

A total of 40 hamsters were randomized into four groups of ten hamsters in each. Group I hamsters served as control and were painted with liquid paraffin alone three times a week for 14 weeks on their left buccal pouches. Groups II and III hamsters were painted with 0.5% DMBA in liquid paraffin three times a week for 14 weeks on their left buccal pouches. Group II animals received no further treatment. Group III animals were orally given andrographolide at a dose of 50 mg/kg body weight/day, starting one week before exposure to the carcinogen and continued on days alternate to DMBA painting, until the end of the experiment. Group IV hamsters received oral administration of andrographolide alone throughout the experimental period. The experiment was terminated at the end of 16th week and all hamsters were sacrificed by cervical dislocation. Biochemical studies were conducted on plasma, liver and buccal mucosa of control and experimental hamsters in each group. For histopathological studies, buccal mucosa tissues were fixed in 10% formalin and routinely processed and embedded with paraffin, 2-3 μ m sections were cut in a rotary microtome and stained with haematoxylin and eosin.

Biochemical analysis

Estimation of lipid peroxidation by-products:

Thiobarbituric acid reactive substances (TBARS) in plasma and buccal mucosa were determined by the methods of Yagi (1970) and Ohkawa et al. (1979), respectively. Briefly, plasma and buccal mucosa samples were reacted with thiobarbituric acid, then the pink color formed were measured at 530 and 532 nm, respectively. The absorbance was directly proportional to TBARS level.

Determination of enzymatic and non enzymatic

antioxidants: SOD activity in plasma and buccal mucosa was assayed by the method of Kakkar et al. (1984). The enzyme assay was based on the 50% inhibition of formation of Nicotinamide adenine dinucleotide - phenazine methosulphate nitroblue tetrazolium formation and the color developed was read at 520 nm. One unit of enzyme activity was taken as the amount of enzyme required to give 50% inhibition of nitroblue tetrazolium reduction. The activity of CAT in plasma and buccal mucosa was assayed by the method of Sinha, (1972). The enzyme assay was based on the utilization of H₂O₂ by the enzyme and the color developed was read at 620 nm. One unit of the enzyme was expressed as micromoles of

H₂O₂ utilized per minute. The activity of GPx in plasma and buccal mucosa was determined using the method of Rotruck et al. (1973). The GSH level in plasma and buccal mucosa was determined by the method of Beutler and Kelly, (1963). The yellow derivative obtained by the reaction of erythrocytes, liver and skin tissues with 5,5-dithiobis-2-nitrobenzoic acid was measured at 412 nm. The absorbance was directly proportional to the GSH level. The oxidised glutathione (GSSG) level in the buccal mucosa was determined by the method of Tietze, (1969). The GSSG content in the buccal mucosa was measured enzymically using GR and reduced nicotinamide adenine dinucleotide phosphate. The vitamin E level in the plasma was determined colorimetrically using the method described by Desai, (1984). Vitamin E presents in the lipid residue forms a pink colored complex with bathophenanthroline-phosphoric acid reagent, which was measured at 536 nm. Buccal mucosa vitamin E was measured using the fluorimetric method described by Palan et al. (1991). The lipid extracts were dried under nitrogen and the residues were suspended in 66% ethanol, followed by the addition of 4ml of hexane and 0.6 ml of 60% sulphuric acid. The tubes were vortexed and centrifuged. The upper hexane phase was removed and its fluorescence intensity was measured at an excitation of 295nm and emission of 320 nm, with α -tocopherol used to determine the standard curve.

Determination of phase I and phase II xenobiotic metabolising enzymes: The levels of cytochrome P₄₅₀ and b₅ in liver and buccal mucosa were determined according to the method of Omura and Sato (1964). Cytochrome P₄₅₀ was measured by the formation of pigment on reaction between reduced cytochrome P₄₅₀ and carbon monoxide. The pigment was read with an absorbance maximum at 450 nm. The difference spectrum between reduced and oxidized cytochrome was used as an index to measure the level of cytochrome b₅. The activity of GST in liver and buccal mucosa was assayed by the method of Habig et al. (1974). The enzyme assay was based on the formation of 1-chloro-2,4 dinitrobenzene-reduced glutathione conjugate, which was measured at 540 nm. GR activity in liver and buccal mucosa was assayed by the method of Carlberg and Mannervik (1985). The enzyme activity was assayed at 340nm by measuring the formation of GSH, when the GSSG was reduced by reduced nicotinamide adenine dinucleotide phosphate.

Protein determination: The protein content was determined by the method of Lowry et al. (1951). The peptide bonds (–CONH–) in polypeptide chain react with copper sulphate in an alkaline medium to give a blue colored complex. In addition, tyrosine and tryptophan residues of proteins cause reduction of the phosphomolybdate and phosphotungstate components of the Folin–Ciocalteu reagent to give bluish products read at 640 nm, which contribute towards enhancing the sensitivity of this method.

Statistical analysis

The data is expressed as mean \pm standard deviation (S.D.) Statistical comparisons for biochemical parameters were performed by one-way analysis of variance followed

by Duncan's Multiple Range Test. The results were considered statistically significant if the P values were less than 0.05.

Results

Table 1 shows the tumor incidence and histopathological changes in control and experimental hamsters in each group. We observed 100% tumor formation with mean tumor volume (375.91 mm³) and tumor burden (1240.50 mm³) in hamsters treated with DMBA alone and the tumors were histopathologically confirmed as well differentiated squamous cell carcinoma. Also, we noticed hyperkeratosis, hyperplasia and dysplasia in hamsters treated with DMBA alone (Figure. 1b). Oral administration of andrographolide at a dose of 50 mg/kg bw completely prevented the tumor incidence and also reduced the severity of histopathological changes in

Table 1. Incidence of Oral Neoplasm and Histopathological Changes in Control and Experimental Hamsters in Each Group (n=10)

Parameter	Group			
	I	II	III	V
Tumor incidence (oral squamous cell carcinoma)	0	100%	0	0
Total number of tumour /animals	0	33/10	0	0
Tumour volume (mm ³)/animals	0	375.91 \pm 42.63	0	0
Tumour burden (mm ³)/animals	0	1240.50 \pm 110.71	0	0
Hyperplasia	-	Severe	Mild	-
Hyperkeratosis	-	Severe	Mild	-
Dysplasia	-	Severe	Mild	-

*Group I Control, Group II DMBA alone, Group III (DMBA+andrographolide) and Group V (Andrographolide alone).

**Tumor volume was measured using the formula, $v=(4/3)\pi(D_1/2)(D_2/2)(D_3/2)$ where D₁, D₂ and D₃ are the three diameters (mm) of the tumor. Tumor burden was calculated by multiplying tumor volume and the number of tumors/animal

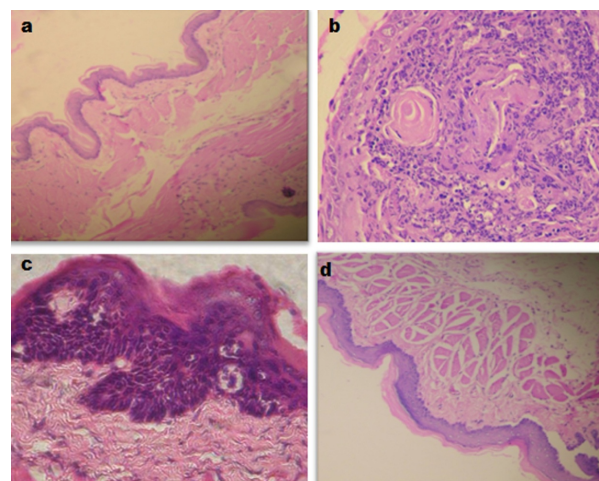


Figure 1. Histopathological Changes in the Buccal Mucosa of Control and Experimental Hamsters in Each Group. (a and d): Photomicrographs showing well-defined buccal pouch epithelium from control and andrographolide alone treated hamsters respectively (H and E, 40X). (b): Photomicrographs showing well-differentiated squamous cell carcinoma with keratin pearls in hamsters treated with DMBA alone (H and E, 40X). (c): Photomicrographs showing hyperplastic and mild dysplastic epithelium in hamsters treated with DMBA+andrographolide (H and E, 40X)

hamsters treated with DMBA (Figure 1c). A well defined intact epithelium was noticed in hamsters treated with andrographolide alone (Figure 1d) and control hamsters (Figure 1a).

Figure 2 shows the status of plasma TBARS and antioxidants (SOD, CAT, GPx, GSH and vitamin E) in control and experimental hamsters in each group. The concentration of TBARS was increased whereas antioxidants activities were decreased in DMBA treated hamsters as compared to control hamsters. Oral administration of andrographolide at a dose of 50 mg/kg bw restored the concentration of TBARS and antioxidants to near normal range in DMBA treated hamsters. Hamsters treated with andrographolide alone showed no significant difference in TBARS and antioxidants status as compared to control hamsters.

Figure 3 shows the status of buccal mucosa TBARS and antioxidants (SOD, CAT, GPx, GSH and vitamin E) in control and experimental hamsters in each group. The concentration of TBARS and activities of SOD and CAT were decreased whereas the status of GPx, GSH and vitamin E were increased in DMBA treated hamsters as compared to control hamsters. Oral administration of

andrographolide at a dose of 50 mg/kg bw restored the concentration of TBARS and antioxidants in DMBA treated hamsters to near normal range. Hamsters treated with andrographolide alone showed no significant difference in TBARS and antioxidants status as compared to control hamsters.

Figure 4 shows the status of phase I (cytochrome P₄₅₀ and b₅) and phase II (GR, GST and GSH) detoxification agents in the liver of control and experimental hamsters in each group. The status of phase I detoxification agents was significantly increased whereas phase II enzymes were decreased in the liver of DMBA treated hamsters as compared to control hamsters. Oral administration of andrographolide to DMBA treated hamsters brought back the status of phase I and phase II detoxification agents to near normal range in the liver. Oral administration of andrographolide alone showed no significant difference in the status of phase I and II detoxification agents as compared to control hamsters.

Figure 5 shows the status of phase I and phase II detoxification agents in the buccal mucosa of control and experimental hamsters in each group. The status of phase I (cytochrome P₄₅₀ and b₅) and phase II detoxification agents

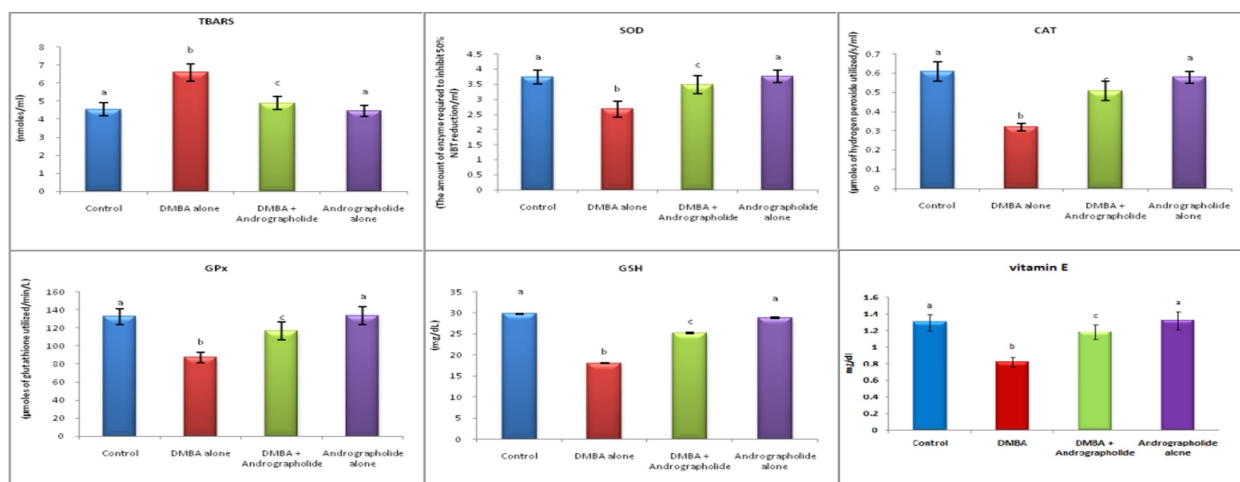


Figure 2. Status of TBARS and Antioxidants in the Plasma of Control and Experimental Hamsters in Each Group. Values are expressed as mean \pm SD for 10 hamsters in each group. Values that do not share a common superscript between groups differ significantly at $p < 0.05$. (DMRT)

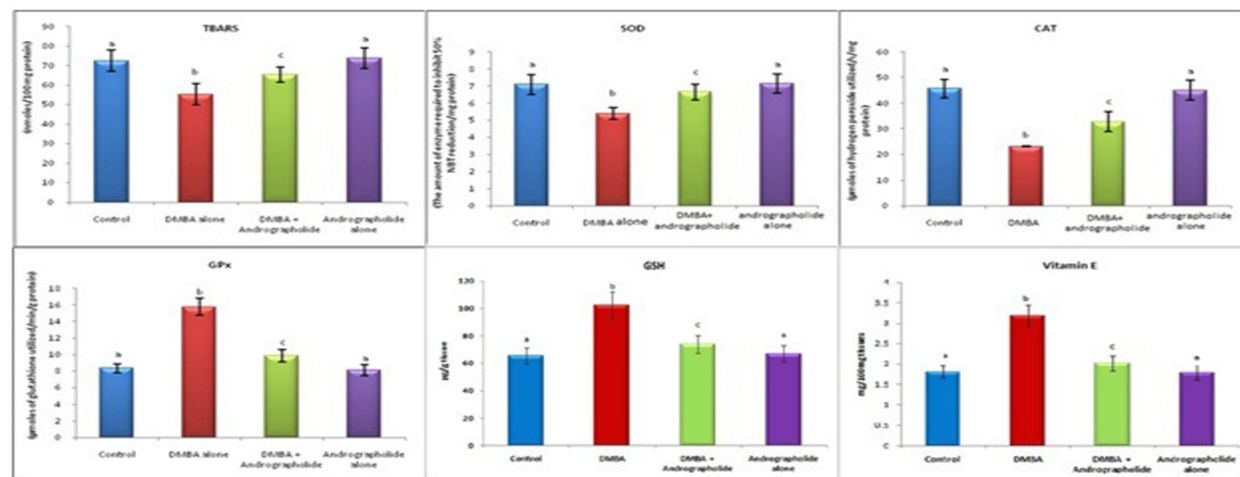


Figure 3. Status of TBARS and Antioxidants in the Buccal mucosa of Control and Experimental Hamsters in Each Group. Values are expressed as mean \pm SD for 10 hamsters in each group. Values that do not share a common superscript between groups differ significantly at $p < 0.05$. (DMRT)

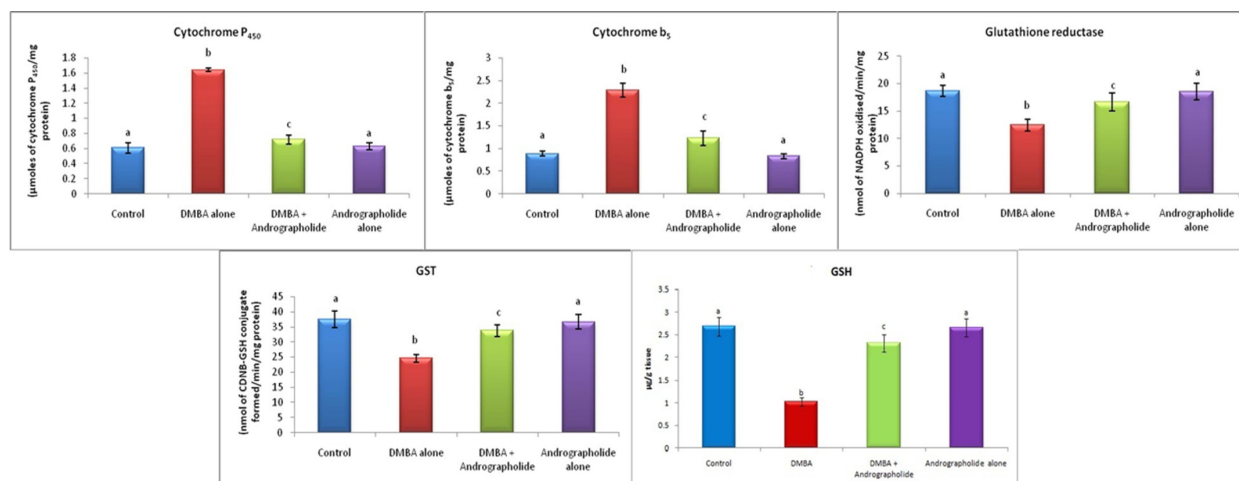


Figure 4. Status of Phase I and Phase II Enzymes in the Liver of Control and Experimental Hamsters in Each Group. Values are expressed as mean±SD for 10 hamsters in each group. Values that do not share a common superscript between groups differ significantly at $p < 0.05$. (DMRT)

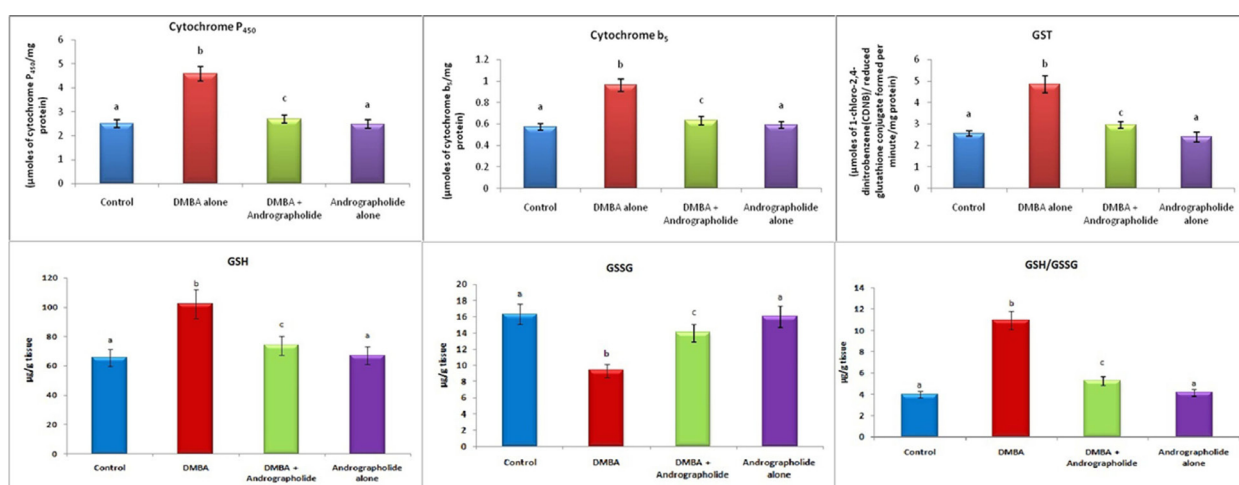


Figure 5. Status of Phase I and Phase II Enzymes in the Buccal Mucosa of Control and Experimental Hamsters in Each Group. Values are expressed as mean±SD for 10 hamsters in each group. Values that do not share a common superscript between groups differ significantly at $p < 0.05$. (DMRT)

(GST and GSH) were significantly increased whereas GSSG content was decreased in tumor-bearing hamsters as compared to control hamsters. Oral administration of andrographolide to DMBA treated hamsters significantly brought back the status of GSH, GSSG and GST to near normal range. Hamsters treated with andrographolide alone showed no significant difference in the status of GSH, GSSG and GST as compared to control hamsters.

Discussion

Agents that showed antioxidant potential are considered to have significant chemopreventive effect against chemical induced carcinogenesis. In the present study, 100% tumor formation with severe histopathological changes (hyperplasia, hyperkeratosis and dysplasia) was noticed in hamsters treated with DMBA alone. Oral administration of andrographolide at a dose of 50 mg/kg bw to hamsters treated with DMBA, not only completely prevented the tumor formation but also significantly reduced the severity of precancerous lesions such as hyperplasia and dysplasia. Andrographolide protected normal cells against chemical induced toxicity (Ye et al.,

2011). Andrographolide induced G0/G1 cell cycle arrest in various types of cancer cells (Jada et al., 2008). The cytotoxic activity of andrographolide is probably due to intact U-butyrolactone ring, the double bonds between C-12 and C-13, C-8 and C-17 and hydroxyl group at C-14 present in the chemical structure of andrographolide (Varma et al., 2009; Sirion et al., 2012). The results of the present study thus suggest that andrographolide might have inhibited abnormal cell proliferation during DMBA-induced oral carcinogenesis.

Oxidative stress, an imbalance in oxidant and antioxidant status, has been implicated in the pathogenesis of several disorders including oral carcinogenesis (Manoharan et al., 2010). Impaired antioxidant potential in the cells make them more prone to oxidative stress, contributing to neoplastic transformation (Anusuya and Manoharan, 2011). Plasma TBARS serves as a reliable marker to assess ROS mediated oxidative damage. Extensive studies reported an inverse association between TBARS and antioxidants in the plasma of tumor bearing animals (Manoharan et al., 2006; Baskaran et al., 2010). Increase in plasma TBARS could be either due to poor antioxidant defense system or due to overproduction of

ROS in the body with subsequent leakage into plasma during cancerous conditions. Enzymatic antioxidants (SOD, CAT and GPx) and non-enzymatic antioxidants (GSH and vitamin E) play prominent role in the protection of tissues against ROS mediated oxidative damage. Diminished activities of plasma GPx, SOD and CAT and plasma GSH and vitamin E levels were reported in various forms of cancers including oral cancer (Thanusu et al., 2010; Silvan et al., 2011). Our results corroborate these observations.

Decrease in TBARS and disturbed activities of enzymatic and non-enzymatic antioxidants were reported in oral tumor tissues (Zengin et al., 2009). At lower concentrations, ROS can induce mitogenic response (Vurusaner et al., 2012). Low levels of buccal mucosa TBARS were reported in highly proliferating tumor cells (Manoharan et al., 2012). Low levels of TBARS in oral tumor tissues are due to low PUFA content (Krishnakumar et al., 2009). An inverse relationship between lipid peroxidation and rate of cell proliferation has been shown (Kumaraguruparan et al., 2002). Lowered TBARS in tumor tissues are therefore due to rapid cell proliferation occurring in DMBA-induced oral carcinogenesis.

Glutathione has putative role in the regulation of redox status, metabolism of xenobiotics and cellular signaling. Reduced glutathione, a major intracellular antioxidant, scavenges directly several ROS including superoxide anion and hydroxyl radical. The oxidative stress of an organism can be measured using the ratio of GSH/GSSG. Increased content of GSSG has been shown in several tumor cells (Balasenthil et al., 2000). GSH and GPx have pivotal role in the regulations of cell proliferation. Increase in GPx activity and GSH and vitamin E content in tumor tissues could account for lowered lipid peroxidation. SOD and CAT are regarded as markers of malignant transformation. Extensive studies documented lowered activities of SOD and CAT in oral cancer tissues (Subapriya et al., 2003; Balakrishnan et al., 2008). The results of the present study corroborate these observations. Oral administration of andrographolide restored the status of TBARS and antioxidants in the plasma and buccal mucosa of hamsters treated with DMBA, which indicate the free radical scavenging and antioxidant potential of andrographolide during DMBA-induced oral carcinogenesis. The antioxidant potential of andrographolide is probably due to its glucoside or hydroxyl moieties, which can directly react with the chain carrying radicals.

Extensive studies pointed out that chemopreventive agents protect cells or tissues against carcinogenic intermediates by inducing the activities of phase II detoxification enzymes particularly GST and inhibiting the activities of phase I enzymes (Kalpana et al., 2011; Manoharan et al., 2012). Increase in phase I enzymes in the liver of DMBA treated hamsters is due to metabolic activation of DMBA to generate its ultimate carcinogenic metabolites. Decrease in phase II enzymes in DMBA treated hamsters suggests that the activities of these enzymes were impaired due to accumulation of carcinogenic intermediates in the liver. Extensive investigations reported that the activities of phase I and

II drug metabolizing enzymes were over expressed in tumor tissues (Vidaya et al., 2008; Vinothini et al., 2009). Increase in phase I and II enzymes in the buccal mucosa of tumor bearing hamsters is probably due to repeated topical application of DMBA. Oral administration of andrographolide to hamsters treated with DMBA restored the status of phase I and II enzymes in the liver and buccal mucosa. The results of the present study suggest that andrographolide might have modulated the activities of phase I and II enzymes in favor of the excretion of carcinogenic metabolites of DMBA.

In conclusion, the present study thus demonstrates the anti-tumor initiating potential of andrographolide in DMBA-induced hamster buccal pouch carcinogenesis. The chemopreventive potential of andrographolide is attributed to its antioxidant potential as well as modulating effect on phase I and II xenobiotic metabolising enzymes in favor of the excretion of carcinogenic metabolites during DMBA-induced oral carcinogenesis.

Acknowledgements

Financial assistance from Council of Scientific and Industrial Research (CSIR), New Delhi, is gratefully acknowledged.

References

- Anusuya C, Manoharan S (2011). Antitumor initiating potential of rosmarinic acid in 7,12-dimethylbenz(a)anthracene-induced hamster buccal pouch carcinogenesis. *J Environ Pathol Toxicol Oncol*, **30**, 199-211.
- Balakrishnan S, Menon VP, Manoharan S (2008). Ferulic acid inhibits 7,12-dimethylbenz[a]anthracene-induced hamster buccal pouch carcinogenesis. *J Med Food*, **11**, 693-700.
- Balasenthil S, Saroja M, Ramachandran CR, Nagini S (2000). Of humans and hamsters: comparative analysis of lipid peroxidation, glutathione, and glutathione-dependent enzymes during oral carcinogenesis. *Br J Oral Maxillofac Surg*, **38**, 267-70.
- Baskaran N, Manoharan S, Balakrishnan S, Pugalandhi P (2010). Chemopreventive potential of ferulic acid in 7,12-dimethylbenz[a]anthracene-induced mammary carcinogenesis in Sprague-Dawley rats. *Eur J Pharmacol*, **637**, 22-9.
- Beutler E, Kelly BM (1963). The effect of sodium nitrite on red cell GSH. *Experientia*, **19**, 96-7.
- Carlberg I, Mannervik B (1985). Glutathione reductase. *Methods Enzymol*, **113**, 484-90.
- Desai ID (1984). Vitamin E analysis methods for animal tissues. *Methods Enzymol*, **105**, 138-47.
- Elango N, Samuel S, Chinnakkannu P (2006). Enzymatic and non-enzymatic antioxidant status in stage (III) human oral squamous cell carcinoma and treated with radical radio therapy: influence of selenium supplementation. *Clin Chim Acta*, **373**, 92-8.
- Habig WH, Pabst MJ, Jakoby WBC (1974). Glutathione-S-transferases: the first enzymatic step in mercapturic acid formation. *J Biol Chem*, **249**, 7130-9.
- Jada SR, Matthews C, Saad MS, et al (2008). Benzylidene derivatives of andrographolide inhibit growth of breast and colon cancer cells in vitro by inducing G(1) arrest and apoptosis. *Br J Pharmacol*, **155**, 641-54.
- Kakkar P, Das B, Viswanathan PN (1984). A modified

- spectrophotometric assay of superoxide dismutase. *Indian J Biochem Biophys*, **21**, 130-2.
- Kalpana Deepa PD, Gayathri R, Sakthisekaran D (2011). Role of sulforaphane in the anti-initiating mechanism of lung carcinogenesis in vivo by modulating the metabolic activation and detoxification of benzo(a)pyrene. *Biomed Pharmacother*, **65**, 9-16.
- Klaunig JE, Wang Z, Pu X, Zhou S (2011). Oxidative stress and oxidative damage in chemical carcinogenesis. *Toxicol Appl Pharmacol*, **254**, 86-99.
- Krishnakumar N, Manoharan S, Palaniappan PR, et al (2009). Chemopreventive efficacy of piperine in 7,12-dimethyl benz [a] anthracene (DMBA)-induced hamster buccal pouch carcinogenesis: an FT-IR study. *Food Chem Toxicol*, **47**, 2813-20.
- Kumaraguruparan R, Subapriya R, Viswanathan P, Nagini S (2002). Tissue lipid peroxidation and antioxidant status in patients with adenocarcinoma of the breast. *Clin Chim Acta*, **325**, 165-70.
- Letchoumy PV, Subapriya R, Nagini S, Abraham SK (2007). Protective effect of black tea polyphenols against 7,12-dimethylbenz[a]anthracene-induced genotoxicity and oxidative stress during hamster buccal pouch carcinogenesis. *Toxicol Mech Methods*, **17**, 93-100.
- Lin FL, Wu SJ, Lee SC, Ng LT (2009). Antioxidant, antioedema and analgesic activities of *Andrographis paniculata* extracts and their active constituent andrographolide. *Phytother Res*, **23**, 958-64.
- Lowry OH, Rosebrough NJ, Farr AL, Randall RJ (1951). Protein measurement with Folin phenol reagent. *J Biol Chem*, **193**, 265-75.
- Manoharan S, Kavitha K, Senthil N, Renju GL (2006). Evaluation of anticarcinogenic effects of Clerodendron inerme on 7,12-dimethylbenz(a)anthracene-induced hamster buccal pouch carcinogenesis. Singapore. *Med J*, **47**, 1038-43.
- Manoharan S, Sindhu G, Vinothkumar V, Kowsalya R (2012). Berberine prevents 7,12-dimethylbenz[a]anthracene-induced hamster buccal pouch carcinogenesis: a biochemical approach. *Eur J Cancer Prev*, **21**, 182-92.
- Manoharan S, Singh AK, Suresh K, et al (2011). Protective efficacy of andrographolide on 7,12-dimethylbenz(a) anthracene induced genotoxicity in bone marrow cells of golden Syrian hamsters. *J Cell Tissue Res*, **11**, 2751-8.
- Manoharan S, Vasanthaselvan M, Silvan S, et al (2010). Carnosic acid: a potent chemopreventive agent against oral carcinogenesis. *Chem Biol Interact*, **188**, 616-22.
- Mocellin S, Rossi CR, Brandes A, Nitti D (2006). Adult soft tissue sarcomas: conventional therapies and molecularly targeted approaches. *Cancer Treat Rev*, **32**, 9-27.
- Murugan RS, Uchida K, Hara Y, et al (2008). Black tea polyphenols modulate xenobiotic-metabolizing enzymes, oxidative stress and adduct formation in a rat hepatocarcinogenesis model. *Free Radic Res*, **42**, 873-84.
- Muwonge R, Ramadas K, Sankila R, et al (2008). Role of tobacco smoking, chewing and alcohol drinking in the risk of oral cancer in Trivandrum, India: a nested case-control design using incident cancer cases. *Oral Oncol*, **44**, 446-54.
- Nagini S (2009). Of humans and hamsters: the hamster buccal pouch carcinogenesis model as a paradigm for oral oncogenesis and chemoprevention. *Anticancer Agents Med Chem*, **9**, 843-52.
- Ohkawa H, Ohishi N, Yagi K (1979). Assay for lipid peroxides in animal tissues by thiobarbituric acid reaction. *Anal Biochem*, **95**, 351-8.
- Omura T, Sato R (1964). The carbon monoxide binding pigment of liver microsomes. *J Biol Chem*, **239**, 2370-8.
- Palan PR, Mikhail MS, Basu J, Romney SL (1991). Plasma levels of antioxidant beta-carotene and alpha-tocopherol in uterine cervix dysplasias and cancer. *Nutr Cancer*, **15**, 13-20.
- Priyadarsini RV, Nagini S (2012). Quercetin suppresses cytochrome P₄₅₀ mediated ROS generation and NF- κ B activation to inhibit the development of 7,12-dimethylbenz[a] anthracene (DMBA) induced hamster buccal pouch carcinomas. *Free Radic Res*, **46**, 41-9.
- Rotruck JT, Pope AL, Ganther HE, et al (1973). Selenium: biochemical role as a component of glutathione peroxidase. *Science*, **179**, 588-90.
- Shanmugam M, Singh AK, Nagarethinam B, Sekar K (2012). Pro-apoptotic and anti-inflammatory potential of andrographolide during 7,12-dimethylbenz[a]anthracene induced hamster buccal pouch carcinogenesis. *J Exp Integr Med*, **10**, 039.
- Silvan S, Manoharan S, Baskaran N, et al (2011). Chemopreventive potential of apigenin in 7,12-dimethylbenz(a)anthracene induced experimental oral carcinogenesis. *Eur J Pharmacol*, **670**, 571-7.
- Sinha AK (1972). Colorimetric assay of catalase. *Anal Biochem*, **47**, 389-94.
- Sirion U, Kasemsook S, Suksen K, et al (2012). New substituted C-19-andrographolide analogues with potent cytotoxic activities. *Bioorg Med Chem Lett*, **22**, 49-52.
- Subapriya R, Kumaraguruparan R, Nagini S, Thangavelu A (2003). Oxidant-antioxidant status in oral precancer and oral cancer patients. *Toxicol Mech Methods*, **13**, 77-81.
- Szumilo J, Podlowska J, Podlowski W, et al (2012). Chemoprevention of oral cancer--clinical and experimental studies. *Pol Merkuri Lekarski*, **32**, 138-42.
- Thanusu J, Kanagarajan V, Nagini S, Gopalakrishnan M (2010). Chemopreventive potential of 3-[2,6-bis(4-fluorophenyl)-3-methylpiperidin-4-ylideneamino]-2-thioxoimidazolidin-4-one on 7,12-dimethylbenz[a]anthracene (DMBA) induced hamster buccal pouch carcinogenesis. *J Enzyme Inhib Med Chem*, **25**, 836-43.
- Tietze F (1969). Enzymic method for quantitative determination of nanogram amounts of total and oxidized glutathione: applications to mammalian blood and other tissues. *Anal Biochem*, **27**, 502-22.
- Varma A, Padh H, Shrivastava N (2009). Andrographolide: a new plant-derived antineoplastic entity on horizon. *Evid Based Complement Alternat Med*, **10**, 135.
- Vidhya LP, Chandra Mohan KV, Stegeman JJ, et al (2008). Pretreatment with black tea polyphenols modulates xenobiotic-metabolizing enzymes in an experimental oral carcinogenesis model. *Oncol Res*, **17**, 75-85.
- Vinothini G, Manikandan P, Anandan R, Nagini S (2009). Chemoprevention of rat mammary carcinogenesis by *Azadirachta indica* leaf fractions: modulation of hormone status, xenobiotic-metabolizing enzymes, oxidative stress, cell proliferation and apoptosis. *Food Chem Toxicol*, **47**, 1852-63.
- Vurusaner B, Poli G, Basaga H (2012). Tumor suppressor genes and ROS: complex networks of interactions. *Free Radic Biol Med*, **52**, 7-18.
- Wang LJ, Zhou X, Wang W, et al (2011). Andrographolide inhibits oral squamous cell carcinogenesis through NF- κ B inactivation. *J Dent Res*, **90**, 1246-52.
- Warnakulasuriya S (2009). Global epidemiology of oral and oropharyngeal cancer. *Oral Oncol*, **45**, 309-16.
- Yagi K (1970). Lipid peroxides and human diseases. *Chem Phys Lipids*, **45**, 337-51.
- Ye JF, Zhu H, Zhou ZF, et al (2011). Protective mechanism of andrographolide against carbon tetrachloride-induced acute liver injury in mice. *Biol Pharm Bull*, **34**, 1666-70.
- Zengin E, Atukeren P, Kokoglu E, et al (2009). Alterations in

lipid peroxidation and antioxidant status in different types of intracranial tumors within their relative peritumoral tissues.

Clin Neurol Neurosurg, **111**, 345-51.

Zhang Z, Jiang J, Yu P, Zeng X, et al (2009). Hypoglycemic and beta cell protective effects of andrographolide analogue for diabetes treatment. *J Transl Med*, **7**, 62.