

RESEARCH ARTICLE

Barrett's Esophagus and β -carotene Therapy: Symptomatic Improvement in GERD and Enhanced HSP70 Expression in Esophageal Mucosa

Sudhir K Dutta^{1,2*}, Kireet Agrawal³, Mohit Girotra^{2,4}, A Steven Fleisher⁵, Mahnaz Motevalli⁶, Mitchell A Mah'moud⁷, Padmanabhan P Nair⁸

Abstract

Introduction: Epidemiological studies suggest a protective role for β -carotene with several malignancies. Esophageal adenocarcinoma frequently arises from Barrett's esophagus (BE). We postulated that β -carotene therapy maybe protective in BE. **Materials and Method:** We conducted a prospective study in which 25 mg of β -carotene was administered daily for six-months to six patients. Each patient underwent upper endoscopy before and after therapy and multiple mucosal biopsies were obtained. Additionally, patients completed a gastroesophageal reflux disease (GERD) symptoms questionnaire before and after therapy and severity score was calculated. To study the effect of β -carotene at molecular level, tissue extracts of the esophageal mucosal biopsy were subjected to assessment of heat-shock protein 70 (HSP70). **Results:** A significant ($p < 0.05$) reduction in mean GERD symptoms severity score from 7.0 ± 2.4 to 2.7 ± 1.7 following β -carotene therapy was noted. Measurement of Barrett's segment also revealed a significant reduction in mean length after therapy. In fact, two patients had complete disappearance of intestinal metaplasia. Furthermore, marked enhancement of HSP70 expression was demonstrated in biopsy specimens from Barrett's epithelium in four cases that were tested. **Conclusions:** Long-term β -carotene therapy realizes amelioration of GERD symptoms along with restitution of the histological and molecular changes in esophageal mucosa of patients with BE, associated with concurrent increase in mucosal HSP70 expression.

Keywords: β -carotene - HSP70 - Barrett's esophagus - GERD

Asian Pacific J Cancer Prev, 13 (12), 6011-6016

Introduction

Barrett's esophagus is well recognized as a pre-malignant condition leading to higher incidence of esophageal adenocarcinoma than the general population (Cameron, 1995; Katz, 1998; Solaymani-Dodaran, 2004). The risk of esophageal adenocarcinoma is approximately 30 times greater in patients with Barrett's esophagus as compared with the general population (Solaymani-Dodaran, 2004). Barrett's esophagus usually develops as a result of chronic gastroesophageal reflux disease (GERD) and is characterized by the presence of columnar epithelium with intestinal metaplasia in the distal esophagus (Cameron, 1995; Katz, 1998; Solaymani-Dodaran, 2004). Esophageal adenocarcinoma has been rising in incidence over the past few decades (Yang, 1988; Blot, 1991; Devesa, 1998) and GERD has been assumed to be a major factor in the development of Barrett's esophagus and esophageal adenocarcinoma (Lagergren,

1999; Shirvani, 2000; Souza, 2002). In a population-based study reported by Bytzer et al. (1999), more than 98% of esophageal adenocarcinoma was detected in patients with previously undiagnosed Barrett's esophagus. It has been postulated that intensive long-term treatment of GERD by anti-reflux therapies in patients with Barrett's esophagus may lower the incidence of esophageal adenocarcinoma (Hillman, 2004; Cooper, 2006; Nguyen et al., 2009).

β -carotene, a naturally occurring phytochemical, is the primary dietary source of pro-vitamin A. There is extensive evidence that β -carotene can produce major changes in immune cellular marker expression in vivo in humans (Prabhala, 1991), and has in fact been studied as a chemopreventive agent in the treatment of several precancerous lesions like oral leukoplakia, cervical dysplasia, breast carcinoma and esophageal adenocarcinoma (Cameron, 1995; Katz, 1998; Terry, 2000; Mayne, 2001; Bosetti, 2004; Nkondjock, 2004; Solaymani-Dodaran, 2004). Regression of oral leukoplakia and gastric

¹Department of Medicine, University of Maryland School of Medicine and Division Director of Gastroenterology, ²Department of Medicine, Johns Hopkins University/Sinai Hospital Program in Internal Medicine, Baltimore, ³Department of Internal Medicine, John Stroger Hospital of Cook County, Chicago, ⁴Division of Gastroenterology, University of Arkansas for Medical Sciences (UAMS), Little Rock, ⁵Division of Gastroenterology, Franklin Square Hospital, Baltimore, ⁶Research Co-ordinator, Division of Gastroenterology, Sinai Hospital of Baltimore, ⁷Duke University School of Medicine, Durham, NC, ⁸Johns Hopkins Bloomberg School of Public Health, Baltimore, USA *For correspondence: sdutta@lifebridgehealth.org

dysplasia with β -carotene therapy has been demonstrated in several clinical trials (Stich, 1988; Sankaranarayanan, 1997; Garewal, 1999; Correa, 2000). In addition, several animal studies have demonstrated evidence for inhibition of hepatic and pancreatic carcinogenesis by β -carotene therapy (Tsuda, 1994; Sarkar, 1995; Appel, 1996; Dagli, 1998; Majima, 1998). Recent studies by Clements (2005) and Kobo (2008) have demonstrated that patients with Barrett's esophagus are deficient in certain antioxidants, including carotenoids.

With the chemo-protective effects of β -carotene therapy already known in several pre-cancer conditions, we postulated that β -carotene therapy may alter the esophageal mucosa in patients with Barrett's esophagus. To test our hypothesis, patients with Barrett's esophagus (without dysplasia) were placed on β -carotene therapy for six months and alterations in GERD symptoms, endoscopic appearance, histological and molecular changes were examined.

Materials and Methods

Ethics statement

The present study was approved by the Institutional Review Board of Sinai Hospital of Baltimore, where patients were enrolled from outpatient clinic and written informed consent was obtained from each patient for their participation in the study.

Our study was a prospective, open-labeled study of β -carotene therapy, in which ten patients with documented Barrett's esophagus (age range: 37-72 years) were enrolled. All these patients had endoscopically visible Barrett's segment and histological evidence of intestinal metaplasia in the distal tubular esophagus. None of the patients had any dysplasia on mucosal biopsy.

The study consisted of a 2-week washout period during which time dietary information (5-day food record) was obtained, and a questionnaire pertaining to GERD symptoms was administered. This gave us the baseline GERD symptom severity score for the patients. Further, during this period, all subjects underwent baseline bloodwork and upper endoscopy for esophageal mucosal biopsies for HSP70 determination. β -carotene (25 mg/day) was administered orally to all patients during the six-month study period. Medical anti-reflux therapy (proton pump inhibitors and/or H_2 -receptor blockers) was continued during the course of our study. Random plasma samples were obtained to measure β -carotene levels and assess compliance with the therapy.

Evaluation of symptoms

A previously validated questionnaire relating to the symptoms associated with GERD was applied to evaluate the influence of β -carotene therapy (Triadafilopoulos, 1997; Gerson, 2001). GERD symptoms including difficulty in swallowing solids and liquids, heartburn, chest pain and coughing or wheezing with lying down or at night were recorded. All the symptoms were scored using the following scale: 0 for no occurrence of the symptom; 1 for mild symptom or symptom occurring 25-50% of the time; 2 for moderate symptom or symptom

occurring 50-75% of the time and 3 for severe symptom or symptom occurring 75-100% of the time. Overall symptom severity was calculated by adding the individual scores for the above symptoms. Information gathered from the questionnaire was used to evaluate a change in symptoms severity score. Symptom scores were analyzed for significance by standardized statistical analysis.

Endoscopic and histologic evaluation

Upper GI endoscopy was performed on each patient upon enrolment into the study (before β -carotene therapy) and repeated after 6 months of β -carotene therapy. The distance from the upper incisor teeth was measured to three specific areas: 1) the most proximal projection of Barrett's epithelium, 2) the area denoting proximal tubular involvement of the entire circumference of the esophagus with Barrett's segment, and 3) the diaphragmatic pinch. Four quadrant mucosal biopsies were obtained from the Barrett's esophagus at 2-cm intervals starting from the esophago-gastric junction to 2-cm above the Z-line. The type of epithelium as well as the presence or absence of dysplasia in the biopsy specimen was documented. Histological changes in mucosal biopsies were analyzed by blinded histopathologists. Histological improvement was defined as reduction in Barrett's esophagus by regression of length of columnar epithelium and the disappearance of intestinal metaplasia in the post β -carotene therapy mucosal biopsy specimens. All measurements were carried out by one endoscopist (S.K. Dutta) who performed the procedure before and after the therapy.

SDS-PAGE electrophoresis

Mucosal biopsy samples of Barrett's mucosa from four patients were subjected to SDS-PAGE electrophoresis before and after β -carotene therapy. The frozen tissue samples were thawed, 5-6 mg tissue specimens were sonicated briefly (about 20 seconds) in Tris-HCl buffer containing Sodium metavanadate, Sodium azide and protease inhibitors (Aprotinin, Leupeptin, Pepstatin A and Phenylmethylsulfonyl fluoride). The sonicated samples were centrifuged and the supernatant was used for all further analyses. Total protein in the samples was determined by Bio Rad DC protein assay kit (Bio Rad laboratories, Hercules, CA).

Approximately 15 μ g of protein (each sample) was loaded onto precast Tris-HCl gels (Bio Rad laboratories, Hercules, CA) and 4-20% Sodium dodecyl sulfate-polyacrylamide gel electrophoresis (SDS-PAGE) was performed for 90 minutes at 150 volts. Gels were run in duplicate. One gel was stained with Coomassie blue and scanned by a densitometer to identify different protein bands. The other gel was utilized for Western blotting with HSP-70 antibody (Sigma Chemicals, St. Louis, MO).

Western blot analysis and amino acid sequencing

Proteins resolved by SDS-PAGE were transblotted onto polyvinylidene difluoride (PVDF) membrane (Millipore, UK) by electroblotting using Electroblot apparatus from Bio rad. A marked increase in the protein band of the 70-90 KD region was seen in the tissue samples obtained after six months of β -carotene therapy. This

protein band was cut, dried and subjected to amino acid sequencing. Amino acid sequencing suggested that this protein had a greater than 90% homology with HSP70. Immunoblotting with monoclonal antibodies against HSP70 (Sigma Chemicals) at 40 C, overnight was then performed to confirm this finding. The blots were subsequently washed and incubated with anti-mouse horse radish peroxidase conjugated antibody (Amersham Life Sciences Inc, Arlington Heights, IL) for 3 hours. The blots were washed again and the immunoreactive protein bands were visualized by chemiluminescence using ECL-kit (Amersham Life sciences Inc, Arlington Heights, IL). The immunoreactive protein bands were analyzed and the level of HSP70 expression was quantified using the Stratagene Eagle Eye II documentation system.

Results

Out of ten enrolled patients (six males and four females), four failed to satisfactorily complete the questionnaire and/or did not remain compliant with the β -carotene treatment offered to them. That left us with six patients into our final analysis.

Improvement of gastroesophageal reflux (GERD) symptoms after β -carotene therapy

A significant ($p < 0.05$) reduction in the symptom severity score was observed after six months of β -carotene therapy. The average score (mean \pm 2SE) prior to use of β -carotene was 7.1 ± 2.4 which decreased to 2.7 ± 1.7 following β -carotene therapy ($p < 0.05$) (Figure 1). All the six patients noticed a reduction in the frequency of GERD symptoms (Table 1). No patient reported increase in GERD symptoms. In three patients, there was reduced requirement of anti-reflux medication and one patient was able to completely discontinue anti-reflux medication. Five patients decided to remain on β -carotene therapy due to marked improvement in GERD symptoms even after completion of the study.

Endoscopic findings

In five out of 6 patients, endoscopically measurable regression of Barrett's segment was observed after β -carotene therapy (Figure 2). A reduction in the mean length of projection of Barrett's segment was observed, from 2.4 ± 1.4 cm at baseline to 1.1 ± 1.4 cm after β -carotene therapy. This change was found to be statistically significant ($p < 0.05$).

Histological findings

Disappearance of specialized intestinal metaplasia was noted in the biopsy specimens from the esophageal mucosa of two patients (33.3%) of Barrett's esophagus after six months of β -carotene therapy. No dysplasia was noted in any of the samples before or after β -carotene therapy.

Increased expression of HSP-70 in esophageal mucosa after β -carotene therapy

β -carotene therapy was associated with marked increase in the expression of a 70 KD protein. Amino acid sequencing revealed that this protein was homologous

Table 1. Effect of Beta-carotene Therapy on the Frequency of Gastroesophageal Reflux-related Symptoms

Symptom frequency	Number of patients	
	Before beta-carotene therapy	After beta-carotene therapy
More than once a day	4	1
Once a day	1	0
Once a week	1	4
Once a month or less	0	1

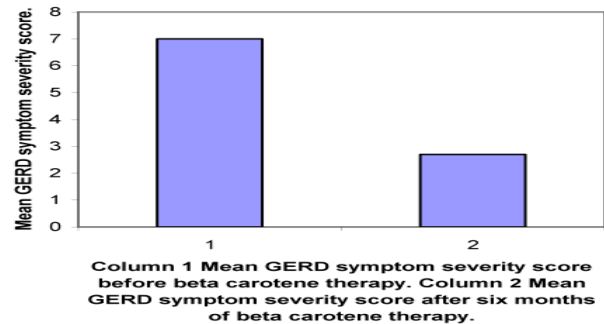


Figure 1. The Effect of β -carotene Therapy on the Mean GERD Symptom Score of the Six Patients Enrolled in the Current Study. Column 1 represents the mean GERD symptom score at the time of enrollment in the study and column 2 represents the mean GERD symptom score after six months of β -carotene therapy

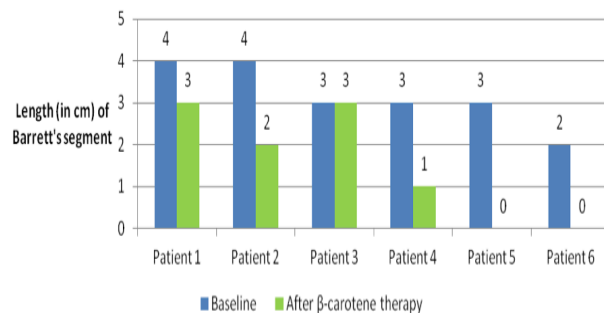


Figure 2. Effect of β -carotene Therapy on Lengths in Barrett's Esophagus. There is a statistically significant ($p < 0.05$) reduction in mean length of Barrett's segments from baseline of 2.4 ± 1.4 cm to 1.1 ± 1.4 cm after β -carotene therapy

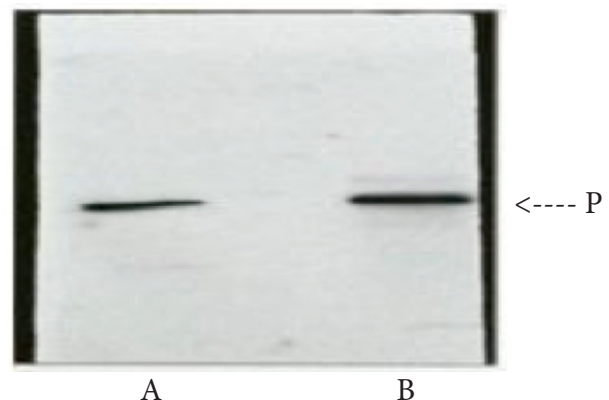


Figure 3. Western Blot Analysis of the Tissue Protein was Performed and the Proteins were Incubated with Monoclonal Antibodies Against HSP-70. Increased expression of HSP-70 was noted in the samples obtained after 6 months of β -carotene therapy (B). This was not seen in samples obtained before starting β -carotene therapy (A)

to heat shock protein (HSP70). Immunoblotting with monoclonal antibodies against HSP70 further confirmed this finding (Figure 3).

Discussion

Several lines of evidence suggest that reflux of gastric acid into the distal esophagus causes increased oxidative stress, which may play a critical role in the pathogenesis of reflux esophagitis and development of Barrett's esophagus (Wetscher, 1995; Chen, 2000; Lee, 2001; Oh, 2001; Sihvo, 2002). Wetscher et al. (1995) assessed oxidative stress by measuring chemiluminescence, lipid peroxidation and superoxide dismutase (SOD) in the esophageal biopsy samples of GERD patients and controls. These investigators observed that highest levels of free radicals and lipid peroxidation, and the lowest levels of SOD were present in patients with Barrett's esophagus. In addition, Chen et al. (2000) also suggested that oxidative damage may have an important role in the formation of esophageal adenocarcinoma based on rat esophagoduodenal anastomosis model. In Chen model, the investigators demonstrated that pre-malignant columnar epithelial cells over expressed the oxidative stress-responsive genes, heme-oxygenase 1 and metallothionein. Dietary antioxidants such as vitamin C, vitamin E, selenium, and carotenoids (β -carotene) are well known to have the potential to reduce tissue and/or DNA damage by scavenging reactive oxygen species and enhancing apoptosis (Clarkson, 2000). Thus, a lack of these nutrients may increase cancer risk through enhanced oxidative stress, DNA damage, and cell proliferation (Klaunig, 2004). Consequently, antioxidants have been proposed as potential therapeutic agents which may be important in treatment of chronic GERD symptoms. These observations have provided groundwork for clinical application of β -carotene, which is a well-recognized antioxidant and has proven benefits in other precancerous lesions (Cameron, 1995; Katz, 1998; Terry, 2000; Mayne, 2001; Bosetti, 2004; Nkondjock, 2004; Solaymani-Dodaran, 2004).

In our study, β -carotene therapy successfully reduced symptoms of GERD in all six patients (Table 1). Furthermore, three out of six (50%) patients had decreased requirement of anti-reflux medication and one patient was able to completely discontinue the anti-reflux therapy. This symptom assessment was done with a questionnaire earlier validated for GERD (Gerson, 2000). There was a drastic decrease in symptoms after therapy with β -carotene (2.7 ± 1.7 as compared to 7.0 ± 2.4 before therapy; $p < 0.05$). Additionally, there was significant reduction in the mean length of Barrett's segment, measurable endoscopically. Furthermore, disappearance of specialized intestinal metaplasia was noted in the biopsy specimens from the esophageal mucosa of two patients of Barrett's esophagus after six months of β -carotene therapy. This histological improvement supported disappearance and/or alleviation of symptoms in these patients. Our finding is in contrast to earlier case-control reports by Kubo et al. (2008) and Murphy et al. (2010) where the intake of antioxidant supplements assessed by food-frequency

questionnaire did not appear to influence the risk of Barrett's esophagus. Kubo reported dietary intake of β -carotene was inversely associated with the risk of BE (adjusted OR=0.48 and 95%CI=0.26-0.90), while no association was observed for supplement intake (Kubo, 2008). In contrast to this epidemiological study, in our study a specific amount of β -carotene was administered for six-months and endoscopic, histological markers of Barrett's were objectively measured. Kubo et al. (2010) and Pal et al. (2012) have acknowledged in a review that there exists a strong epidemiological evidence for an inverse relationship between β -carotene and Barrett's esophagus/Adenocarcinoma and further cohort studies are needed. Our study in fact provides that critical evidence.

An interesting observation in our study was the demonstration of HSP70 in the mucosal biopsy samples of patients with Barrett's esophagus after six months of β -carotene therapy. Heat shock proteins are stress proteins, which are protective against a variety of cytotoxic stresses, as seen in various diseases (Saluja, 2008; Joly, 2010). The esophageal epithelium is routinely exposed to acid reflux and thermal stress and these epithelial cells have presumably, evolved protective mechanisms to withstand environmental insults and repair damaged cells (Hopwood, 1997; Yagui-Beltran, 2001). In-vitro studies by Yagui-Beltran et al. (2001) have noted that human esophageal squamous epithelium exhibits an atypical stress response and characterized by downregulation of HSP70 expression is under stress. This atypical stress response may represent the evolutionary adaptation of epithelial cells in esophagus in order to survive in an unusual microenvironment exposed to chemical, thermal and acid reflux stresses. In our study, the initial mucosal biopsy samples from the Barrett's segments (chronic acid stress state) demonstrated minimal HSP70 expression. However, after 6 months of β -carotene therapy, increased HSP70 expression was seen in the mucosal biopsy samples of the Barrett's epithelium. This observation clearly demonstrates a cellular response to β -carotene therapy in patients with GERD/Barrett's esophagus. Previous studies have confirmed that HSP70 induction by β -carotene therapy is associated with inhibition of cell growth in culture studies (Schwartz, 1990, Toba, 1997). Schwartz et al. (1990) reported inhibition of proliferation of cultured human squamous cell assays (SK-MES lung carcinoma and SCC-25 oral carcinoma) and appearance of HSP70 within 1-2 hours of exposure to β -carotene. Likewise, Toba et al. (1997) have demonstrated HSP70 induction by β -carotene in cervical dysplasia cells (CICCN-4 cells) associated with concentration-dependent suppression of cell growth through apoptosis. These authors have suggested that induction of HSP70 by β -carotene may be essential for inhibition of pre-malignant and malignant cell growth in cervical dysplasia (Toba, 1997). Mechanistically, the resolution of Barrett's esophagus by β -carotene therapy points to a possible genomic reprogramming of the aberrant cells in the direction of normal differentiation. This restitution is a highly likely scenario, since retinol (vitamin A) derived from β -carotene through the mediation of a specific epithelial dioxygenase is known for its activity in maintaining normal cellular

integrity during growth and differentiation.

In summary, our results demonstrate a marked clinical improvement in gastroesophageal reflux symptoms, along with alteration in endoscopic appearance and histology of Barrett's esophagus after treatment with β -carotene. There is also an increased HSP70 expression noted at the molecular level after β -carotene therapy, which might be cytoprotective against the acid damage and chemoprotective against early carcinogenic changes (Schwartz, 1990, Toba, 1997). Controlled double blinded clinical studies in larger number of patients are needed to confirm the efficacy of long-term β -carotene therapy in patients with Barrett's esophagus with dysplasia.

References

- Appel MJ, Woutersen RA (1996) Effects of dietary β -carotene and selenium on initiation and promotion of pancreatic carcinogenesis in azaserine-treated rats. *Carcinogenesis*, **17**, 1411-6.
- Avidan B, Sonnenberg A, Schnell TG, et al (2002). Hiatal hernia size, Barrett's length, and severity of acid reflux are all risk factors for esophageal adenocarcinoma. *Am J Gastroenterol*, **97**, 1930-6.
- Bosetti C, Talamini R, Montella M (2004). Retinol, carotenoids and the risk of prostate cancer: a case control study from Italy. *Int J Cancer*, **112**, 689-92.
- Blot WJ, Devesa SS, Kneller RW, Fraumeni JF Jr (1991). Rising incidence of adenocarcinoma of the esophagus and gastric cardia. *JAMA*, **265**, 1287-9.
- Bytzer P, Christensen PB, Damkier P, Vinding K, Seersholm N (1999). Adenocarcinoma of the esophagus and Barrett's esophagus: a population-based study. *Am J Gastroenterol*, **94**, 86-91.
- Cameron AJ, Lomboy CT, Pera M, Carpenter HA (1995). Adenocarcinoma of the esophagogastric junction and Barrett's esophagus. *Gastroenterology*, **109**, 1541-6.
- Chen X, Ding YW, Yang G, et al (2000). Oxidative damage in an esophageal adenocarcinoma model with rats. *Carcinogenesis*, **21**, 257-63.
- Clarkson PM, Thompson HS (2000). Antioxidants: what role do they play in physical activity and health? *Am J Clin Nutr*, **72**, 637-46.
- Clements DM, Oleesky DA, Smith SC, et al (2005). A study to determine plasma antioxidant concentrations in patients with Barrett's esophagus. *J Clin Pathol*, **58**, 490-2.
- Cooper BT, Chapman W, Neumann CS, Gearty JC (2006). Continuous treatment of Barrett's oesophagus patients with proton pump inhibitors up to 13 years: observations on regression and cancer incidence. *Aliment Pharmacol Ther*, **23**, 727-33.
- Correa P, Fontham ET, Bravo JC, et al (2000). Chemoprevention of gastric dysplasia: randomized trial of antioxidant supplements and anti-helicobacter pylori therapy. *J Natl Cancer Inst*, **92**, 1881-8.
- Dagli ML, Guerra JL, Sinhorini IL, et al (1998). Beta-carotene reduces the ductal (oval) cell reaction in the liver of Wistar rats submitted to the resistant hepatocyte model of carcinogenesis. *Pathology*, **30**, 259-66.
- Devesa SS, Blot WJ, Fraumeni JF Jr (1998). Changing patterns in the incidence of esophageal and gastric carcinoma in the United States. *Cancer*, **83**, 2049-53.
- Garewal HS, Katz RV, Meyskens F, et al (1999). β -carotene produces sustained remissions in patients with oral leukoplakia: results of a multicenter prospective trial. *Arch*
- Gerson LB, Edson R, Lavori PW, Triadafilopoulos G (2001). Use of a simple symptom questionnaire to predict Barrett's esophagus in patients with symptoms of gastroesophageal reflux. *Am J Gastroenterol*, **96**, 2005-12.
- Hillman LC, Chiragakis L, Shadbolt B, Kaye GL, Clarke AC (2004). Proton-pump inhibitor therapy and the development of dysplasia in patients with Barrett's oesophagus. *Med J Aust*, **180**, 387-91.
- Hopwood D, Moitra S, Vojtesek B, et al (1997). Biochemical analysis of the stress protein response in human oesophageal epithelium. *Gut*, **41**, 156-63.
- Joly AL, Wettstein G, Mignot G, Ghiringhelli F, Garrido C (2010). Dual role of heat shock proteins as regulators of apoptosis and innate immunity. *J Innate Immun*, **2**, 238-47.
- Katz D, Rothstein R, Schned A, et al (1998). The development of dysplasia and adenocarcinoma during endoscopic surveillance of Barrett's esophagus. *Am J Gastroenterol*, **93**, 536-41.
- Klaunig JE, Kamendulis LM (2004). The role of oxidative stress in carcinogenesis. *Annu Rev Pharmacol Toxicol*, **44**, 239-67.
- Kubo A, Levin TR, Block G, et al (2008). Dietary antioxidants, fruits and vegetables and the risk of Barrett's esophagus. *Am J Gastroenterol*, **103**, 1614-23.
- Kubo A, Corley DA, Jensen CD, Kaur R (2010). Dietary factors and the risks of oesophageal adenocarcinoma and Barrett's oesophagus. *Nutr Res Rev*, **23**, 230-46.
- Lagergren J, Bergstrom R, Lindgren A, Nyren O (1999). Symptomatic gastroesophageal reflux as a risk factor for esophageal adenocarcinoma. *N Engl J Med*, **340**, 825-31.
- Lee JS, Oh TY, Ahn BO, et al (2001). Involvement of oxidative stress in experimentally induced reflux esophagitis: clue for the chemoprevention of esophageal carcinoma by antioxidants. *Mutat Res*, **480**, 189-200.
- Majima T, Tsutsumi M, Nishino H, Tsunoda T, Konishi Y (1998). Inhibitory effects of β -carotene, palm carotene, and green tea polyphenols on pancreatic arcinogenesis initiated by N-nitrosobis(2-oxoprpyl)amine in Syrian golden hamsters. *Pancreas*, **16**, 13-8.
- Mayne ST, Risch HA, Dubrow R, et al (2001). Nutrient intake and risk of subtypes of esophageal and gastric cancer. *Cancer Epidemiol Biomarkers Prev*, **10**, 1055-62.
- Murphy SJ, Anderson LA, Ferguson HR, et al (2010). Dietary antioxidant and mineral intake in humans is associated with reduced risk of esophageal adenocarcinoma but not reflux esophagitis or Barrett's esophagus. *J Nutr*, **140**, 1757-63.
- Nguyen DM, El-Serag HB, Henderson L, et al (2009). Medication usage and the risk of neoplasia in patients with Barrett's esophagus. *Clin Gastroenterol Hepatol*, **7**, 1299-304.
- Nkondjock A, Ghadirian P (2004). Intake of specific carotenoids and essential fatty acids and breast cancer risk in Montreal, Canada. *Am J Clin Nutr*, **79**, 857-64.
- Oh TY, Lee JS, Ahn BO, et al (2001). Oxidative stress is more important than acid in the pathogenesis of reflux esophagitis in rats. *Gut*, **49**, 364-71.
- Pal D, Banerjee S, Ghosh AK (2012). Dietary-induced cancer prevention: an expanding research arena of emerging diet related to healthcare system. *J Adv Pharm Technol Res*, **3**, 16-24.
- Prabhala RH, Garewal HS, Hicks MJ, Sampliner RE, Watson RR (1991). The effects of 13-cis-retinoic acid and β -carotene on cellular immunity in humans. *Cancer*, **67**, 1556-60.
- Saluja A, Dudeja V (2008). Heat shock proteins in pancreatic diseases. *J Gastroenterol Hepatol*, **23**, 42-5
- Sankaranarayanan R, Mathew B, Varghese C, et al (1997). Chemoprevention of oral leukoplakia with vitamin A and

- β -carotene: an assessment. *Oral Oncol*, **33**, 231-6.
- Sarkar A, Bishayee A, Chatterjee M (1995). Beta-carotene prevents lipid peroxidation and red blood cell membrane protein damage in experimental hepatocarcinogenesis. *Cancer Biochem Biophys*, **15**, 111-25.
- Schwartz JL, Singh RP, Teicher B, et al (1990). Induction of a 70 kD protein associated with the selective cytotoxicity of β -carotene in human epidermal carcinoma. *Biochem Biophys Res Commun*, **169**, 941-6.
- Shirvani VN, Outu-Lascar R, Kaur BS, Omary B, Triadafilopoulos G (2000). Cyclooxygenase 2 expression in Barrett's esophagus and adenocarcinoma: ex vivo induction by bile salts and acid exposure. *Gastroenterology*, **118**, 487-96.
- Sihvo EI, Salminen JT, Rantanen TK, et al (2002). Oxidative stress has a role in malignant transformation in Barrett's esophagus. *Int J Cancer*, **102**, 551-5.
- Solaymani-Dodaran M, Logan RF, West J, Card T, Coupland C (2004). Risk of extra-oesophageal malignancies and colorectal cancer in Barrett's oesophagus and gastro-oesophageal reflux. *Scand J Gastroenterol*, **39**, 680-5.
- Souza RF, Shewmake K, Terada LS, Spechler SJ (2002). Acid exposure activates the mitogen-activated protein kinase pathways in Barrett's esophagus. *Gastroenterology*, **122**, 299-307.
- Stich HF, Hornby AP, Mathew B, Sankaranarayanan R, Nair MK (1998). Response of oral leukoplakias to the administration of vitamin A. *Cancer Lett*, **40**, 93-101.
- Terry P, Lagergren J, Ye W, Nyren O, Wolk A (2000). Antioxidants and cancers of the esophagus and gastric cardia. *Int J Cancer*, **87**, 750-4.
- Toba T, Shidoji Y, Fujii J, et al (1997). Growth suppression and induction of heat-shock protein-70 by 9-cis β -carotene in cervical dysplasia-derived cells. *Life Sci*, **61**, 839-45.
- Triadafilopoulos G, Sharma R (1997). Features of symptomatic gastroesophageal reflux disease in elderly patients. *Am J Gastroenterol*, **92**, 2007-11.
- Tsuda H, Uehara N, Iwahori Y, et al (1994). Chemoprotective effect of β -carotene, alpha-tocopherol and five naturally occurring antioxidants on initiation of hepatocarcinogenesis by 2-amino,3-methylimidazo (4,5-f)quinoline in the rat. *Jpn J Cancer Res*, **85**, 1214-9.
- Wetscher GJ, Hinder PR, Bagchi D, et al (1995). Reflux esophagitis in humans is mediated by oxygen-derived free radicals. *Am J Surg*, **170**, 552-6.
- Yagui-Beltran A, Craig AL, Lawrie L, et al (2001). The human oesophageal squamous epithelium exhibits a novel type of heat shock protein response. *Eur J Biochem*, **268**, 5343-55.
- Yang PC, Davis S (1988). Incidence of cancer of the esophagus in the US by histologic type. *Cancer*, **61**, 612-7.