

RESEARCH ARTICLE

Ultrasound Score to Select Subcentimeter-sized Thyroid Nodules Requiring Ultrasound-guided Fine Needle Aspiration Biopsy in Eastern China

Pu Cheng^{1&}, En-Dong Chen^{1&}, Hua-Min Zheng², Qiu-Xiang He³, Quan Li^{1*}

Abstract

Ultrasound-guided fine needle aspiration biopsy (FNAB) is a costly diagnostic item with a low yield in identifying the tiny proportion of nodules that actually represent malignant disease. Our aim through this study was to obtain an ultrasound (US) score for selecting subcentimeter-sized thyroid nodules requiring FNAB in eastern China. Some 248 patients for a total of 270 thyroid nodules less than 1 cm in diameter underwent FNAB and subsequent surgery from January 2006 to March 2012 at our hospital. The clinicopathological and US data from all the nodules were analyzed retrospectively. An US score was developed on the basis of independent predictive factors for malignancy. Irregular shape, hypoechogenicity, no well-defined margin, presence of calcifications and ratio between antero-posterior and transversal diameters (AP/TR) ≥ 1 were independent predictive factors for malignancy on logistic regression analysis. US score were statistically significant, with ≤ 2 favoring benignancy with an 80.3% sensitivity and a 72.7% specificity. US score is useful for differentiating between malignant and benign subcentimeter-sized thyroid nodules. We suggest FNAB for nodules when the US score is higher than 2.

Keywords: Thyroid nodule - thyroid cancer - ultrasonography - fine needle aspiration

Asian Pac J Cancer Prev, **14** (8), 4689-4692

Introduction

As the widespread use of routine ultrasound survey during physical examination, the number of patients with thyroid cancer has been rising steeply during recent years in eastern China (Xiang et al., 2010). Up to now, ultrasound-guided FNAB is the least invasive preoperative modality for discriminating benign from malignant thyroid nodules (Nixon et al., 2013). However, only a small proportion of thyroid nodules turn out to be malignant (Hegedüs, 2004). The practical problem arises as ultrasound-guided FNAB being a costly diagnostic item with a low yield in identifying the tiny proportion of nodules that actually represent malignant disease (Iannuccilli et al., 2004). Several US features have been reported as predictors of malignancy (Iannuccilli et al., 2004; Kang et al., 2004; Kim et al., 2008; Lee et al., 2011; Vinayak et al., 2012; Kim et al., 2013a; Kim et al., 2013b). But currently there is no acknowledged guideline of selecting which thyroid nodules for biopsy, especially for the subcentimeter-sized ones (Iannuccilli et al., 2004; Moon et al., 2012; Grani et al., 2013; Kim et al., 2013a; Nixon et al., 2013). Our aim was to obtain an ultrasound (US) score for selecting thyroid nodules ≤ 10 mm in size requiring ultrasound-guided FNAB in eastern China.

Materials and Methods

Between January 2006 and March 2012, 622 patients underwent ultrasound-guided FNAB for a total of 665 thyroid nodules ≤ 10 mm in size at our hospital. A maximum of three suspicious nodules were examined for a single patient when multiple nodules were found.

All nodules were evaluated by US using an Acuson Sequoia and 128XP sonographic scanners (Siemens Medical Solutions, Mountain View, CA) equipped with commercially available 8- to 13- MHz linear probes. Ultrasound images were reviewed by the same experienced ultrasound radiologist who was blinded to clinical and pathologic data. The US variables recorded were nodule size, the presence of multiple nodules, nodule location, shape, composition, echogenicity, echogenic density, margin, calcification, posterior shadowing, capsule, vascularization pattern and the ratio between antero-posterior and transversal diameters (AP/TR).

Specimens obtained from ultrasound-guided FNAB were smeared on a slide, immediately fixed in 95% ethanol and stained by the HE method. Two senior pathologists interpreted cytology in blind. Final cytological diagnoses were divided into five groups: 1. non-diagnostic; 2. benign; 3. follicular lesion; 4. suspicious of malignancy;

¹Department of Surgical Oncology, ²Department of Diagnostic Ultrasound, ³Department of Pathology, The First Affiliated Hospital of Wenzhou Medical University, Wenzhou, China &Equal contributors *For correspondence: lqsky1106@126.com

Table 1. Clinical and US Characteristics According to Pathological Result

Characteristics	Pathological result		P value	Characteristics	Pathological result		P value
	Benign	Malignant			Benign	Malignant	
Total number	143	127		Echogenic density			0.01
Age at diagnosis (year)	47.2±11.1	45.5±10.8	0.202	Heterogeneous	133(93)	126(99.2)	
Nodule size (mm)	7.2±2.0	7.3±1.9	0.93	Homogeneous	10(7.0)	1(0.8)	
Sex			0.004	Margin			<0.001
Female	135(94.4)	106(83.5)		Well-defined	120(83.9)	76(59.8)	
Male	8(5.6)	21(16.5)		No well-defined	23(16.1)	51(40.2)	
No. of nodules			0.006	Calcification			<0.001
Single	34(23.8)	50(39.4)		Absence	90(62.9)	32(25.2)	
Multiple	109(76.2)	77(60.6)		Microcalcification	32(22.4)	77(60.6)	
Nodule location			0.557	Other calcification	21(14.7)	18(14.2)	
Upper	22(15.4)	27(21.3)		Capsule			<0.001
Middle	59(41.2)	48(37.8)		Complete	136(95.1)	82(64.6)	
Lower	51(35.7)	40(31.5)		Absence/incomplete	7(4.9)	45(35.4)	
Isthmus	11(7.7)	12(9.4)		Vascularization pattern			0.044
Shape			<0.001	Normal	134(93.7)	108(85.1)	
Regular	135(94.4)	95(74.8)		Increased peripherally	4(2.8)	5(3.9)	
Irregular	8(5.6)	32(25.2)		Increased centrally	5(3.5)	14(11.0)	
Echogenicity			<0.001	Posterior shadowing			0.01
Hyper/iso	19(13.3)	1(0.8)		Normal	141(98.6)	117(92.1)	
Hypo	124(86.7)	126(99.2)		Absence/degenerate	2(1.4)	10(7.9)	
Composition			<0.001	Taller than wide			<0.001
Solid	122(85.3)	127(1)		Yes	21(14.7)	62(48.8)	
Cystic/mixed	21(14.7)	0(0)		No	122(85.3)	65(51.2)	

Table 2. Multivariate Analysis of Association Between US Features and Malignancy

Characteristics	P value	OR	95%CI	
			Lower	Upper
Irregular shape	0.000	8.362	2.925	23.905
Hypoechoogenicity	0.014	0.061	0.007	0.570
Absence/incomplete capsule	0.000	0.115	0.042	0.311
Calcification	0.000			
Other calcification	0.000	0.119	0.056	0.257
Microcalcification	0.392	0.662	0.258	1.700
AP/TR ≥1	0.000	4.308	2.050	9.052

5. malignancy. At last, 270 nodules resected by subsequent surgery with complete pathological results were enrolled. The frequency distribution of malignant nodule in different groups of clinical and US characteristics was compared by χ^2 test or Fisher's exact test. Continuous variables like patient age and nodule size were compared by independent two-sample t test. Logistic regression analysis was fitted to data to assess independent associations of malignancy with all variables above. The differences were considered statistically significant with *P*-value < 0.05. Independent predictors according to multiple logistic regression analysis were given different points for constructing a scoring system. Moreover, the receiver-operating characteristic curves (ROC curves) was used to identify the optimal point with high sensitivity and low false-negative rate (1-specificity).

Results

Amongst 622 patients that underwent ultrasound-guided FNAB, 126 were male and 496 were female. The mean age of patients at diagnosis was 46.2 (range 16-85, SD 11.1). The mean diameter of nodules was 7.1 mm

Table 3. US Index Points

US parameters	Characteristic	US score
Shape	Regular	0
	Irregular	1
Echogenicity	Hyper or Iso	0
	Hypo	1
Intact capsule	Yes	0
	No	1
Calcifications	Absent	0
	Other calcifications	1
	Microcalcifications	2
Taller than wide	No	0
	Yes	1

(range 2-10 mm, SD 2.0). Cytological results revealed 139 non-diagnostic nodules (20.9%), 387 benign cases (58.2%), 4 follicular lesions (0.6%), 48 suspicious of malignancy (7.2%) and 87 malignant nodules (13.1%).

There were 270 nodules removed surgically, including 143 benign nodules and 127 malignant lesions according to the pathological results which consisted with the cytological findings in 232 nodules (85.9%) and disagreed in 38 (14.1%).

Comparison was made to evaluate the clinical and US differences between benign and malignant nodules in Table 1. Irregular shape, hypoechoogenicity, solid composition, no well-defined margin, absence/incomplete capsule, calcifications and the AP/TR ratio ≥ 1 were strongly significant with malignant (*P* < 0.001). Male (*P*=0.004), single nodule (*P*=0.006), heterogeneous echo (*P*=0.01), absence/degenerate posterior shadowing (*P*=0.01) and vascularization pattern (*P*=0.044) were also significant variables. Age, nodule size and location were not statistically significant.

Logistic regression analysis showed a significant predictive role for Irregular shape *P* < 0.001),

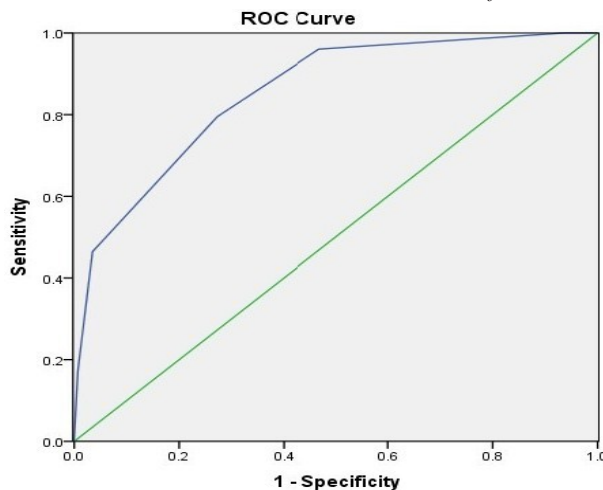


Figure 1. ROC Curves for Malignant Thyroid Nodules. US score > 2 was the optimal point for distinguishing between benign and malignant lesions. The sensitivity and specificity of US score > 2 reached 80.3% and 72.7%, respectively, while the positive and negative predictive values were 72.3% and 80.6%

hypoechoogenicity ($P=0.014$), absence/incomplete capsule ($P < 0.001$), the presence of calcifications ($P < 0.001$) and AP/TR ratio ≥ 1 ($P < 0.001$) as in Table 2.

We then graded the nodules by giving an index score to variables that were significantly associated with malignant outcome. Table 3 shows the index score for each US feature. Mean US score was 1.7 ± 1.0 in benign group and 3.4 ± 1.1 in malignant group, which was statistically significant ($P < 0.001$). By using ROC curves, we found US score > 2 was the optimal point for distinguishing between benign and malignant lesions (Figure 1). The sensitivity and specificity of US score > 2 reached 80.3% and 72.7%, respectively, while the positive and negative predictive values were 72.3% and 80.6%.

Discussion

Due to the prevalence of thyroid nodules, it is clinically important to predict the risk of malignancy of a given nodule (Yang et al., 2011). Ultrasound-guided FNAB is the least invasive preoperative method for the differential diagnosis of thyroid nodules (Nixon et al., 2013). However, it is blatantly inappropriate to conduct ultrasound-guided FNAB for all thyroid nodules since the ratio of malignancy is relatively low (Hegedüs., 2004; Iannuccilli et al., 2004). US is commonly used as an effective noninvasive technique for the diagnosis of benign and malignant thyroid nodules. Many scholars have focused on the valuable role of US features as predictors of malignancy (Iannuccilli et al., 2004; Kang et al., 2004; Kim et al., 2008; Lee et al., 2011; Vinayak et al., 2012; Kim et al., 2013a; Kim et al., 2013b). Currently, there is no internationally acknowledged guideline of selecting which thyroid nodules for biopsy, especially for the subcentimeter-sized ones (Iannuccilli et al., 2004; Grani et al., 2013; Kim et al., 2013a; Nixon et al., 2013). Many institutions now apply ultrasound-guided FNAB just on nodules larger than 1 cm in diameter. This occurs as a result of the popular recognition that the mortality rate of thyroid microcarcinoma (defined as ≤ 1 cm in maximum

diameter) is fairly low (Giordano et al., 2010). However, there is still a vital significance for differential diagnosis of benign and malignant subcentimeter-sized thyroid nodules, as cases with regional lymph nodes and distant metastases have been well documented in the literature.

In this study, we attempted to determine whether US features could be utilized to select subcentimeter-sized thyroid nodules for ultrasound-guided FNAB. For nodules < 1 cm in our hospital, ultrasound-guided FNAB was performed only if there were suspicious US features for malignancy. This led to the high proportion of malignancy and suspicious of malignancy (20.3%) compared with other reports (Cavaliere et al., 2009). It has been reported that thyroid nodules with a diameter < 10 mm were more frequently non-diagnostic (Grani et al., 2013). In view of this, the number of non-diagnostic nodules in our study (20.9%) was receivable.

Irregular shape, hypoechoogenicity, solid composition, no well-defined margin, absence/incomplete capsule, calcifications, the AP/TR ratio ≥ 1 , male, single nodule, heterogeneous echo, absence/degenerate posterior shadowing and vascularization pattern were significant characteristics of malignancy on univariate analysis in our study. The result is generally similar to several earlier studies (Kang et al., 2004; Kim et al., 2008; Cavaliere et al., 2009; Vinayak and Sande., 2012; Wang et al., 2012; Kim et al., 2013a; Kim et al., 2013c). However, there was little standardization among authors of the vascularization pattern, which was statistically significant in present result. Multivariate analysis showed that irregular shape, hypoechoogenicity, absence/incomplete capsule, the presence of calcifications and AP/TR ratio ≥ 1 were independent predictors for malignant pathology. In some articles solitary nodule showed a strong predictive value for positive cytology (Cavaliere et al., 2009; Petrone et al., 2012) which was inconsistent in our paper. Similar situation was observed on vascularization pattern (Vinayak et al., 2012; Lingam et al., 2013). This could be explained by the small sample size and possible collinearity between variables.

As the poor discriminative efficiency of using US independently, we made a US scoring system on the basis of multiple logistic regression analysis. The area under the ROC curves was of high value (0.85, 95%CI: 0.81-0.90) in predicting the final pathological findings. We identified the US index points > 2 as the best cut-off for distinguishing between benign and malignant lesions with a sensitivity of 80.3%, specificity of 72.7%, positive predictive value of 72.3% and negative predictive value of 80.6%. According to our result, we suggest FNAB for nodules when the US score is higher than 2. For nodules with US score lower than 2, observation of disease and regular follow-up were recommended.

Ultrasound-guided FNAB is the most accurate method available to distinguish benign from malignant thyroid nodules (Cooper et al., 2009). And there is a clear need to select nodules for ultrasound-guided FNAB to maximize benefits and minimize cost. US carries important implication in the treatment of thyroid diseases as an important means to help make a judgment on FNAB guidance. Up to now, the guideline of selecting

which thyroid nodules for biopsy, especially for the subcentimeter-sized ones, is still controversial. Our study was designed to build and assess an ultrasound (US) score system for selecting thyroid nodules ≤ 10 mm in size requiring ultrasound-guided FNAB.

Our US scoring system may allow surgeons to diagnose thyroid diseases more accurately, decrease patients' financial burden and enhance the utilization ratio of health resources. However, it should be noted that any good technique could be more effective with the help of others. Therefore, independently of the US score, clinical judgment is always recommended for patients run the risk of malignancy.

Acknowledgements

This reaserch is supported by Wenzhou Science and Technology Planning Project (No. Y20120190). The author(s) declare that they have no competing interests.

References

- Cavaliere A, Colella R, Puxeddu E, et al (2009). A useful ultrasound score to select thyroid nodules requiring fine needle aspiration in an iodine-deficient area. *J Endocrinol Invest*, **32**, 440-4.
- Cooper DS, Doherty GM, Haugen BR, et al (2009). Revised American Thyroid Association management guidelines for patients with thyroid nodules and differentiated thyroid cancer. *Thyroid*, **19**, 1167-214.
- Giordano D, Gradoni P, Oretti G, Molina E, Ferri T (2010). Treatment and prognostic factors of papillary thyroid microcarcinoma. *Clin Otolaryngol*, **35**, 118-24.
- Grani G, Calvanese A, Carbotta G, et al (2013). Intrinsic factors affecting adequacy of thyroid nodule fine-needle aspiration cytology. *Clin Endocrinol (Oxf)*, **78**, 141-4.
- Hegedüs L (2004). Clinical practice. The thyroid nodule. *N Engl J Med*, **351**, 1764-71.
- Iannuccilli JD, Cronan JJ, Monchik JM (2004). Risk for malignancy of thyroid nodules as assessed by sonographic criteria: the need for biopsy. *J Ultrasound Med*, **23**, 1455-64.
- Kang HW, No JH, Chung JH, et al (2004). Prevalence, clinical and ultrasonographic characteristics of thyroid incidentalomas. *Thyroid*, **14**, 29-33.
- Kim GR, Kim MH, Moon HJ, et al (2013b). Sonographic characteristics suggesting papillary thyroid carcinoma according to nodule size. *Ann Surg Oncol*, **20**, 906-13.
- Kim JY, Kim SY, Yang KR (2013a). Ultrasonographic criteria for fine needle aspiration of nonpalpable thyroid nodules 1-2 cm in diameter. *Eur J Radiol*, **82**, 321-6.
- Kim JY, Lee CH, Kim SY, et al (2008). Radiologic and pathologic findings of nonpalpable thyroid carcinomas detected by ultrasonography in a medical screening center. *J Ultrasound Med*, **27**, 215-23.
- Kim KM, Park JB, Kang SJ, Bae KS (2013c). Ultrasonographic guideline for thyroid nodules cytology: single institute experience. *J Korean Surg Soc*, **84**, 73-9.
- Lee MJ, Hong SW, Chung WY, et al (2011). Cytological results of ultrasound-guided fine-needle aspiration cytology for thyroid nodules: emphasis on correlation with sonographic findings. *Yonsei Med J*, **52**, 838-44.
- Lingam RK, Qarib MH, Tolley NS (2013). Evaluating thyroid nodules: predicting and selecting malignant nodules for fine-needle aspiration (FNA) cytology. *Insights Imaging*, **4**, 617-24.
- Moon HJ, Son E, Kim EK, Yoon JH, Kwak JY (2012). The diagnostic values of ultrasound and ultrasound-guided fine needle aspiration in subcentimeter-sized thyroid nodules. *Ann Surg Oncol*, **19**, 52-9.
- Nixon IJ, Ganly I, Hann LE, et al (2013). Nomogram for selecting thyroid nodules for ultrasound-guided fine-needle aspiration biopsy based on a quantification of risk of malignancy. *Head Neck*, **35**, 1022-5.
- Petrone L, Mannucci E, De Feo ML, et al (2012). A simple ultrasound score for the identification of candidates to fine needle aspiration of thyroid nodules. *J Endocrinol Invest*, **35**, 720-4.
- Vinayak S, Sande JA (2012). Avoiding unnecessary fine-needle aspiration cytology by accurately predicting the benign nature of thyroid nodules using ultrasound. *J Clin Imaging Sci*, **2**, 23.
- Wang Y, Li L, Wang YX, et al (2012). Ultrasound findings of papillary thyroid microcarcinoma: a review of 113 consecutive cases with histopathologic correlation. *Ultrasound Med Boils*, **38**, 1681-8.
- Xiang J, Wu Y, Li DS, et al (2010). New clinical features of thyroid cancer in eastern China. *J Visc Surg*, **147**, e53-6.
- Yang Y, Li Q, Guo L, et al (2011). A retrospective analysis of thyroid cancer in China. *Asian Pac J Cancer Prev*, **12**, 2245-9.