

RESEARCH ARTICLE

Prognostic Value of Osteopontin in Patients Treated with Primary Radiotherapy for Head and Neck Cancer

Durmus Etiz^{1*}, Fulya Colak Ataizi¹, Evrim Bayman¹, Melek Akcay¹, Mustafa Fuat Acikalin², Ertugrul Colak³, Evrim Ciftci²

Abstract

Background: The prognostic value of tumor osteopontin (OPN) in patients with squamous-cell head and neck cancer (SCHNC) was investigated. **Materials and Methods:** OPN expression was assessed by immunohistochemical methods in 50 patients, who were treated with primary radiotherapy (RT) for locally advanced SCHNC. The effects of OPN on clinical parameters, local-regional control after RT and metastasis-free survival, was assessed. **Results:** The rate of OPN expression in tumor tissue was 76%. OPN positive cases had lower Hb levels ($p=0.088$). Mean time to local recurrence was 53.8 months (SE 3.9) in OPN-negative cases and 39.1 months (SE 4.7) in OPN-positive cases ($p=0.047$). OPN increased the risk of local recurrence 5.9 times ($p=0.085$). It had no effect on metastasis-free ($p=0.116$) or overall survival ($p=0.123$). OPN was positive in 12 of 19 cases that developed grade 3-4 acute radiation dermatitis ($p=0.096$). **Conclusions:** OPN expression is associated with an increase in local recurrence in patients who were treated with primary RT for locally advanced SCHNC.

Keywords: Head and neck cancer - local control - osteopontin - radiotherapy - side effect

Asian Pac J Cancer Prev, 14 (9), 5175-5178

Introduction

Prior to radiotherapy (RT), pathological parameters such as histopathological type, location, grade and stage of the tumor, and clinical parameters including patient performance and gender are being investigated, but less attention is paid to the biological characteristics of the tumor. Identification of potential predictive factors for response to RT prior to treatment would prevent the application of same treatment modality in each patient.

Tumor hypoxia is seen most frequently in cervical cancer and squamous cell head and neck cancer (SCHNC) (Vaupel et al., 1998; Nordsmak et al., 2005; Hoogsteen et al., 2007). Tumor hypoxia can be evaluated by several methods. Exogenous markers such as “Eppendorf oxygen-sensitive electrode” and “pimonidazole” have not been put into routine use, as they are invasive tests with low sensitivity (Toustrup et al., 2012). Alternatively, studies on endogenous hypoxia markers that can be measured from tumor or plasma are ongoing (Leo et al., 2004).

Osteopontin (OPN) gene is located on chromosome 4, and OPN is a calcium binding glycoprotein present in many normal tissues (Giachelli et al., 2000). Le et al. demonstrated von Hippel-Lindau (VHL) gene expression and increased levels of plasma OPN in hypoxic tumors (Le et al., 2003). In vitro studies reported that, OPN levels are 90 times higher in anoxic cervical cancer cells versus normoxic cells, and that OPN indicates chronic hypoxia more accurately than hypoxic markers such as “carbonic anhydrase IX”, (CA9), “glucose transporter

1” (GLUT1) and “lactate dehydrogenase A” (LDHA), therefore, should be used as a marker of severe hypoxia (Sorenson et al., 2005; Huan et al., 2012).

The present study investigated the effects of OPN, detected by immunohistochemical methods in tumor cells of locally advanced SCHNC cases that had been treated with primary RT, on local-regional control, and metastasis-free and overall survival.

Materials and Methods

The present study retrospectively investigated 50 SCHNC cases that had been treated in the Radiation Oncology Department of Eskişehir Osmangazi University Medical Faculty between January 2006 and November 2010. Immunohistochemical staining scores of SCHNC was determined in paraffin-embedded tumor blocks.

Study population and treatment

A total of 50 cases with locally advanced SCHNC, who had not undergone surgery but received primary curative RT, were investigated. Of the cases, 36 had laryngeal carcinoma, 5 had hypopharyngeal cancer, 3 had tongue cancer, 2 had tonsil cancer, 2 had oral cavity cancer and 2 had maxillary sinus cancer. Three-dimensional conformal RT had been planned for all patients. Gross tumor volume, including the primary tumor and lymph nodes with short-axis diameter greater than 1.5 cm, was contoured on computed tomography (CT) and PET-CT, according to the International Commission on Radiation

¹Department of Radiation Oncology, ²Department of Pathology, ³Department of Biostatistics, Eskişehir Osmangazi University Faculty of Medicine, Eskişehir, Turkey *For correspondence: detiz@ogu.edu.tr

Units and Measurements Report 62 (ICRU 62) guidelines. Irradiation was performed with linear accelerator equipment (Precise-Elekta™) with 6 MV X-rays. The median total dose was 70 Gy (64-70Gy) (2 Gy/day, 5days/week). Cisplatin at a dose of 80mg/m² was simultaneously administered in 37 (74%) cases on the 1st, 22nd and 43rd days of RT. RT was interrupted for a median of 4 days (0-14 days) due to toxicity. Patients receiving concurrent chemo-RT and patients with decreased oral intake were hospitalized, hydrated, given enteral nutritional support and analgesics. The study was approved from the local ethics committee of Eskişehir Osmangazi University

Immunohistochemical assessment of osteopontin

Immunohistochemical staining was performed on formalin-fixed, paraffin-embedded tissue sections using the avidin-biotin-peroxidase technique. Tissue sections were deparaffinized, rehydrated and then underwent antigen retrieval. Endogenous peroxidase activity was inhibited by incubation with 3% hydrogen peroxidase for 10 minutes. After non-specific binding was blocked using Ultra V Block (Thermo Scientific, Fremont; CA, USA) for 5 minutes, sections were incubated overnight at 4°C with mouse monoclonal antibody against OPN (clone OP3N, Leica Biosystems, Novocastra, Newcastle Upon Tyne, UK; dilution at 1:100). The sections were then incubated with biotinylated goat anti-polyvalent (Thermo Scientific) for 10 minutes followed by exposure to streptavidin-peroxidase (Thermo Scientific) for 10 minutes. 3-Amino-9-Ethylcarbazole (AEC) was used as chromogen, and the sections were counterstained with hematoxylin.

All slides were reviewed by two pathologists (MFA, EÇ) who were blinded to patient outcomes. OPN expression levels were classified according to the staining percentage. Samples with staining in at least 10% of the tumor cells were scored as positive for OPN in Figure 1.

Statistical analysis

Statistical analysis was performed using the IBM Statistical Package for the Social Sciences (SPSS) Statistics (SPSS Inc., Chicago IL, USA) program version

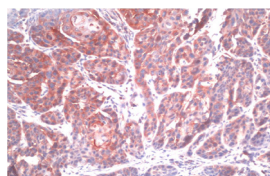


Figure 1. Diffuse and Strong Cytoplasmic Positivity for Osteopontin in Tumor Cells (×200)

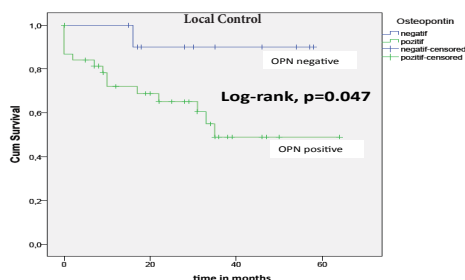


Figure 2. Kaplan Meier Analysis of Local Control by Osteopontin Staining

20.0. Numerical variables were analyzed by the chi-square test, Fisher’s exact test or unpaired t-test. Kaplan-Meier method was used to estimate overall and metastasis-free survival and local control (local and regional) and log-rank test was used to compare the survival curves. Cox regression model was used for univariate analysis. The duration of local control and survival were calculated from the first day of RT. A p value <0.05 was considered statistically significant.

Results

The relationship between osteopontin expression and clinical parameters

Table 1 illustrates the relation between OPN expression and clinical parameters (gender, age, location of tumor, T stage, N stage, and anemia). Hb levels were less than 12.5 g/dL in only 2 (16.6%) of 12 OPN-negative cases and in 19 (50%) of 38 OPN-positive cases (p=0.088).

Osteopontin expression and tumor controls analysis

The median follow-up duration of cases was 28 months (range, 8-64). The mean 2-year survival rate was 60.6%. OPN expression was positive in 15 (93.7%) of 16 cases with local recurrence (p=0.097). OPN expression increased the risk of local recurrence by 5.9 times (RR 5.9, 95%CI 0.78-45.11) (p=0.085). The mean time to local recurrence was 53.8 months (SE 3.9) in OPN-negative cases and 39.1 months (SE 4.7) in OPN-positive cases (p=0.047) (Figure 2).

During the follow-up period, regional recurrence occurred in 13 cases, of which 12 were OPN-positive (p=0.221). The mean time to regional recurrence was 53.1 months (SE 4.6) in OPN-negative cases and 42.9 months (SE 4.8) in OPN-positive cases (p=0.111). No association was observed between distant metastasis and OPN expression (p=0.116). However, it is intriguing that all of 10 cases that developed distant metastasis (6 lung, 2 liver, 1 brain, and 1 bone metastasis) were OPN-positive. During the follow-up period, 24 cases (3 OPN-negative and 21 OPN-positive cases) died due to disease. We failed

Table 1. The Relationship between Osteopontin Expression and the Clinical and Pathological Characteristics of Patients with Squamous-cell Head and Neck Cancer

			OPN	OPN	p
		n (%)	Negative	Positive	
			n (%)	n (%)	
Total		50 (100)	12 (24)	38 (76)	
Gender	Female	8 (16)	1 (2)	7 (14)	0.406
	Male	42 (84)	11 (22)	31 (62)	
Age (years)	<60	23 (46)	4 (8)	19 (38)	0.313
	≥60	27 (54)	8 (16)	19 (38)	
Diagnosis	Larynx Cancer	36 (72)	10 (20)	26 (52)	0.316
	Other	14 (28)	2 (4)	12 (24)	
T stage	1-2	7 (14)	2 (4)	5 (10)	0.76
	3-4	43 (86)	10 (20)	33 (66)	
N stage	0	20 (40)	6 (12)	14 (28)	0.506
	1-3	30 (60)	6 (12)	24 (48)	
Pre-RT Hb (g/dL)	<12.5	21 (42)	2 (4)	19 (38)	0.088
	≥12.5	29 (58)	10 (20)	19 (38)	

*OPN: Osteopontin; RT: Radiotherapy; Hb: Hemoglobin

Table 2. The Relationship between Osteopontin Expression and Acute Side Effects of Radiotherapy in Patients with Squamous-cell Head and Neck Cancer

Acute side effect (Grade)		OPN			p
		n (%)	Negative n (%)	Positive n (%)	
Neutropenia	0-2	44 (88)	12 (24)	32 (64)	0.338
	3-4	6 (12)	-	6 (12)	
Thrombocytopenia	0	48 (96)	12 (24)	36 (72)	0.417
	1-2	2 (4)	-	2 (4)	
Mucositis	1-2	40 (80)	9 (18)	31 (62)	0.619
	3-4	10 (20)	3 (6)	7 (14)	
Dermatitis	1-2	31 (62)	5 (10)	26 (52)	0.096
	3-4	19 (38)	7 (14)	12 (24)	

to elucidate the effect of OPN expression on survival (p=0.123).

Osteopontin expression and acute side effects

Grade 3-4 neutropenia was not detected in any of 12 OPN-negative cases, whereas 6 (15.7%) of 38 OPN-positive cases had Grade 3-4 neutropenia (p=0.338). Only two cases developed thrombocytopenia (Grade 1-2) and these cases were OPN-positive (p=0.417). Seven of 10 cases that developed Grade 3-4 mucositis had positive OPN expression (p=0.619). Of the 19 cases that developed Grade 3-4 radiation dermatitis, 12 were OPN-positive (p=0.096) (Table 2). OPN expression was positive in 7 of 8 cases, in which RT was interrupted for 7 days or longer due to toxicity (p=0.406).

Discussion

Routinely used biomarkers (HER-2 and hormone receptors for breast cancer, KRAS mutation in colorectal cancer) for decision making in medical oncology should also be assessed before RT and used routinely in clinical practice. Identifying the predictive biomarkers of response before RT will indicate the patients who will benefit from "hypoxia-targeted therapy" (Yaromina et al., 2012).

Increased OPN expression is responsible for shorter survival in breast, prostate and gastric cancers (Bramwell et al., 2006; Wu et al., 2007; Vergis et al., 2008). However, the number of clinical studies investigating the efficacy of OPN in SCHNC cases is limited (Lu et al., 2011). In the present study, patients with OPN-positive tumors had a mortality rate of 55.2%, whereas those without OPN expression had a mortality rate of 25% (p=0.123). In a case series involving 69 patients, reported a shorter survival in cases with a plasma OPN level higher than 82.1 ng/mL before RT (p=0.001) (Snitcovsky et al., 2009). Relapse rate was higher (p=0.005) and survival duration was shorter (p=0.0006) in 54 SCHNC cases reported from Stanford (Le et al., 2003). Contrarily, however, in a study including 578 SCHNC patients, high levels of OPN was reported to have no effect on overall survival (Lim et al., 2012). Besides tumors, serum/plasma OPN level is increased by stress, cytokines, growth factors and hormones (Denhardt et al., 2003). Different methods used in measuring OPN levels led to different results concerning the relation between OPN and survival.

The rate of OPN expression was 76% in the present

series. OPN expression was found to be 58% by Coppola et al. (2004) 67% by Devoll (1999) and 93% by Celetti et al. (2005). These rates indicate that OPN is a marker frequently expressed in SCHNC. Using [¹⁸F]-fluoromisonidazole positron emission tomography, tumor hypoxia was detected in 71% of cases with locally advanced SCHNC (Rischin et al., 2006). The literature demonstrates a positive correlation between hypoxia and rate of OPN expression. In a case series of 34 SCHNC patients, Bache et al. found the median Hb level to be less than 12.7 g/dL in OPN-positive cases (Bache et al., 2006). In the present series, OPN expression was positive in 90.4% of the cases who had anemia (Hb<12.5 g/dL) (n=21) before RT (p=0.088). In brief, our results corroborates these findings. In 2007, the relationship of tumor tissue partial oxygen pressure (pO₂) with CA9, BNIP3L, connective tissue growth factor, OPN, ephrin A1, hypoxia inducible gene-2, dihydrofolate reductase, galectin-1, IκB kinase β, and lysyl oxidase" markers was investigated in 104 SCHNC cases. Among the markers investigated, only OPN correlated with tumor tissue pO₂ (Le et al., 2007). Whilst median pO₂ was 28.7 mmHg in OPN-negative cases, it was found to be 13.2 mmHg in those strongly positive for OPN (p=0.04). There is an association between OPN expression, hypoxia and anemia. However, an explanation stating that low Hb levels are directly responsible for low oxygen pressures would be simple and inconclusive (Hoogsteen et al., 2007). Cause and effect relationships in this process require further studies.

DAHANCA 5 study, in which 320 head and neck cancer cases were investigated, reported that local recurrence rate was 2.85 times higher (RR 2.85, 95% CI 1.32-61.5) in those with high OPN levels (Overgaard et al., 2005). In a case series of 52 patients reported from Brazil, OPN levels were found to be lower in patients with complete response to chemotherapy (42%) (p=0.005) (Snitcovsky et al., 2009). In the present series as well, tumor OPN positivity was a factor increasing the local recurrence rate.

When the relationship of acute side effects of RT with OPN was assessed, it was observed that tumor OPN expression was detected in 63.1% (12/19) of the cases that developed severe radiation dermatitis (p=0.096). A review of the medical literature in English revealed no study that examined the relationship between OPN and radiation dermatitis. Only a study from Japan reported that high levels of OPN was released from T cells in chronic allergic dermatitis, and commented that anti-OPN antibodies might reduce such skin reactions (Seier et al., 2010). The relatively high incidence of side effects in patients with high OPN levels suggests that not only hypoxia but also other factors make additional contribution to poor tumor prognosis (Tuck et al., 1999).

The present study investigated OPN expression in tumor samples obtained before RT. However, tumor oxygenation is a dynamic process including oxygen consumption and oxygen supply. The measurement of hypoxia markers in biopsy tissue allowed taking only a snapshot within this long process but failed to demonstrate the changes in hypoxia during the treatment period.

In conclusion, it has been detected that tumor OPN positivity is an important prognostic factor that reduces local control after RT. As there are various non-tumor factors including bone mineralization, atherosclerosis, wound healing, tissue injury, rheumatoid arthritis, acute hepatic dysfunction, that affect plasma OPN levels immunohistochemical staining of OPN in tumor cells might have allowed us to get more realistic results (Denhardt et al., 2001). As SCHNC patients with OPN expression have more tumors that are hypoxic, and decreased local control, hypoxia should be corrected in such cases. Tirapazamine, accelerated RT with carbogen and nicotinamide (ARCON) and/or gene therapy or small molecule inhibitors targeting OPN, should be considered to be included in the treatment during RT.

Acknowledgements

The authors would like to thank Prof. Dr. Karel Geboes, Prof. Dr. Wim Ceelen.

References

- Bache M, Reddemann R, Said HM, et al (2006). Immunohistochemical detection of osteopontin in advanced head-and-neck cancer: prognostic role and correlation with oxygen electrode measurements, hypoxia-inducible-factor-1alpha-related markers, and hemoglobin levels. *Int J Radiat Oncol Biol Phys*, **66**, 1481-7.
- Bramwell VH, Doig GS, Tuck AB, et al (2006). Serial plasma osteopontin levels have prognostic value in metastatic breast cancer. *Clin Cancer Res*, **12**, 3337-43.
- Celetti A, Testa D, Staibano S, et al (2005). Overexpression of the cytokine osteopontin identifies aggressive laryngeal squamous cell carcinomas and enhances carcinoma cell proliferation and invasiveness. *Clin Cancer Res*, **11**, 8019-27.
- Coppola D, Szabo M, Boulware D, et al (2004). Correlation of osteopontin protein expression and pathological stage across a wide variety of tumor histologies. *Clin Cancer Res*, **10**, 184-90.
- Denhardt DT, Noda M, O'Regan AW, Pavlin D, Berman JS (2001). Osteopontin as a means to cope with environmental insults: regulation of inflammation, tissue remodeling, and cell survival. *J Clin Invest*, **107**, 1055-61.
- Denhardt DT, Mistretta D, Chambers AF, et al (2003). Transcriptional regulation of osteopontin and the metastatic phenotype: evidence for a Ras-activated enhancer in the human OPN promoter. *Clin Exp Metastasis*, **20**, 77-84.
- Devoll RE, Li W, Woods KV, et al (1999). Osteopontin (OPN) distribution in premalignant and malignant lesions of oral epithelium and expression in cell lines derived from squamous cell carcinoma of the oral cavity. *J Oral Pathol Med*, **28**, 97-101.
- Giachelli CM, Steitz S (2000). Osteopontin: a versatile regulator of inflammation and biomineralization. *Matrix Biol*, **19**, 615-22.
- Hoogsteen IJ, Marres HA, Bussink J, van der Kogel AJ, Kaanders JH (2007). Tumor microenvironment in head and neck squamous cell carcinomas: predictive value and clinical relevance of hypoxic markers. A review. *Head Neck*, **29**, 591-604.
- Huan JL, Xing L, Qin XJ, et al (2012). Expression and clinical significance of osteopontin in calcified breast tissue. *Asian Pac J Cancer Prev*, **13**, 5219-23.
- Le QT, Sutphin PD, Raychaudhuri S, et al (2003). Identification of osteopontin as a prognostic plasma marker for head and neck squamous cell carcinomas. *Clin Cancer Res*, **9**, 59-67.
- Le QT, Kong C, Lavori PW, et al (2007). Expression and prognostic significance of a panel of tissue hypoxia markers in head-and-neck squamous cell carcinomas. *Int J Radiat Oncol Biol Phys*, **69**, 167-75.
- Leo C, Giaccia AJ, Denko NC (2004). The hypoxic tumor microenvironment and gene expression. *Semin Radiat Oncol*, **14**, 207-14.
- Lim AM, Rischin D, Fisher R, et al (2012). Prognostic significance of plasma osteopontin in patients with locoregionally advanced head and neck squamous cell carcinoma treated on TROG 02.02 phase III trial. *Clin Cancer Res*, **18**, 301-7.
- Lu JG, Li Y, Li L, Kan X (2011). Overexpression of osteopontin and integrin α v in laryngeal and hypopharyngeal carcinomas associated with differentiation and metastasis. *J Cancer Res Clin Oncol*, **137**, 1613-8.
- Nordmark M, Bentzen SM, Rudat V, et al (2005). Prognostic value of tumor oxygenation in 397 head and neck tumors after primary radiation therapy. An international multi-center study. *Radiother Oncol*, **77**, 18-24.
- Overgaard J, Eriksen JG, Nordmark M, et al (2005). Plasma osteopontin, hypoxia, and response to the hypoxia sensitizer nimorazole in radiotherapy of head and neck cancer: results from the DAHANCA 5 randomized double-blind placebo-controlled trial. *Lancet Oncol*, **6**, 757-64.
- Rischin D, Hicks RJ, Fisher R et al (2006). Prognostic significance of [18F]-misonidazole positron emission tomography-detected tumor hypoxia in patients with advanced head and neck cancer randomly assigned to chemoradiation with or without tirapazamine: a substudy of Trans-Tasman Radiation Oncology Group Study 98.02. *J Clin Oncol*, **24**, 2098-104.
- Seier AM, Renkl AC, Schulz G, et al (2010). Antigen-specific induction of osteopontin contributes to the chronification of allergic contact dermatitis. *Am J Pathol*, **176**, 246-58.
- Snitcovsky I, Leitao GM, Pasini FS, et al (2009). Plasma osteopontin levels in patients with head and neck cancer undergoing chemoradiotherapy. *Arch Otolaryngol Head Neck Surg*, **135**, 807-11.
- Sorensen BS, Hao J, Overgaard J, et al (2005). Influence of oxygen concentration and pH on expression of hypoxia induced genes. *Radiother Oncol*, **76**, 187-93.
- Toustrup K, Sorensen BS, Alsner J, Overgaard J (2012). Hypoxia gene expression signatures as prognostic and predictive markers in head and neck radiotherapy. *Semin Radiat Oncol*, **22**, 119-27.
- Tuck AB, Arsenault DM, O'Malley FP, et al (1999). Osteopontin induces increased invasiveness and plasminogen activator expression of human mammary epithelial cells. *Oncogene*, **18**, 4237-46.
- Vaupel P, Höckel M (1998). Oxygenation of human tumors. In: Molls M, Vaupel P (Eds): Medical radiology: blood perfusion and microenvironment of human tumors. pp 63-72.
- Vergis R, Corbishley CM, Norman AR, et al (2008). Intrinsic markers of tumour hypoxia and angiogenesis in localised prostate cancer and outcome of radical treatment: a retrospective analysis of two randomized radiotherapy trials in a done surgical cohort study. *Lancet Oncol*, **9**, 342-51.
- Wu CY, Wu MS, Chiang EP, et al (2007). Elevated plasma osteopontin associated with gastric cancer development, invasion and survival. *Gut*, **56**, 782-9.
- Yaromina A, Krause M, Baumann M (2012). Individualization of cancer treatment from radiotherapy perspective. *Mol Oncol*, **6**, 211-21.