

RESEARCH ARTICLE

Ovarian Sex Cord Stromal Tumours in Children and Young Girls - A More Than Two Decade Clinicopathological Experience in a Developing Country, Pakistan

Saroon Haroon^{1*}, Romana Idrees¹, Aleena Zia², Aisha Memon¹, Saira Fatima¹, Naila Kayani¹

Abstract

Background: Ovarian sex-cord stromal tumours (SCST) are rare, and relatively infrequent in children. These have to be distinguished from more common germ cell tumors in children and also from benign epithelial neoplasms. **Objectives:** The purpose of our study was to report the clinical and pathological findings in young patients with these tumours in our population. **Material and Methods:** The present observational cross-sectional study included all subjects <21 years of age diagnosed with ovarian SCST, in Aga Khan University Hospital Histopathology Laboratory, Karachi, Pakistan, from January 1992 till July 2013. **Results:** Of the total of 513 SCSTs presented during the study period, 39 fulfilled inclusion criteria and were assessed. The age range was 4-250 months. Most of the tumours presented at stage-1 and an abdominal mass was the most common presenting symptom, along with menstrual disturbance. The left side ovary was slightly more affected (53.5%). Of the total, 15 were juvenile granulosa cell tumours (JGCT), 11 sclerosing stromal tumours (SST), 10 of the fibrothecomas spectrum, 2 Sertoli leydig cell tumours (SLCT) and one a sex cord tumour with annular tubules (SCTAT). Detailed immunohistochemical analyses were performed in 33 cases. Recurrence/metastasis was noted in 4/21 cases with follow-up data. **Conclusions:** Ovarian sex cord stromal tumours are very rare in young age in our population, and usually present at an early stage. Most common among these are juvenile granulosa cell tumours, although surprisingly sclerosing stromal tumours were also common. Clinical symptoms due to hormone secretion in premenstrual girls and menstrual disturbance in menstruating girls are common presenting features.

Keywords: Ovarian mass - sex cord stromal tumour - pediatric tumour

Asian Pac J Cancer Prev, **15** (3), 1351-1355

Introduction

Gynecologic tumors in children are infrequent and comprise of less than 5% of all pediatric neoplasms. Paediatric ovarian and testicular sex cord-stromal tumours are distinct from germ cell neoplasms and ovarian SCST are exceedingly rare in paediatric age group (Schneider et al., 2003a; 2003b). A wide range of histopathologic tumour subtypes occur in this group, and their clinical features and treatment vary accordingly. Due to their unique nature, these should be kept in mind by clinicians as the signs and symptoms can go unappreciated (Chin et al., 2012; Virgone et al., 2012). If a parent reports a combination of abnormal uterine bleeding with other sex hormone abnormalities, an ovarian SCST tumor should always be considered (Chin et al., 2012). In Pakistan, very few studies have been done on overall perspective ovarian tumours in younger age group and even fewer related to specific sub-category i.e. Sex cord stromal tumours. In this study, we reviewed our experience with ovarian

SCST in children and evaluated their clinical presentation, histopathology, immunohistochemical analyses and outcome where available.

Materials and Methods

The study included patients of ≤ 21 years of age. Clinical information was available from histopathology reports, which were available on Integrated Laboratory Management System in our laboratory. The Aga Khan University being one of the largest set ups of surgical pathology in Pakistan with over 50,000 specimens per annum from more than 200 collection points all over the country. The therapeutic information was assessed through medical records and via telephone from physicians in charge and/or patient's guardian. Patients' records were given special codes which were known only to two authors (SH and AZ).

Ethical concerns were addressed according to Helsinki's declaration, patients' privacy was fully

¹Histopathology section, Dept of Pathology and Microbiology, ²Medical Student, The Aga Khan University, Karachi, Pakistan *For correspondence: saroonakm@yahoo.com

maintained and no patient identifiable material was used. Hemotoxylin/eosin sections and immunostaining (IHC) were reviewed. Following high laboratorial quality control systems, 5-micrometer thick sections were used for the immunohistochemical studies. The tissue samples were processed, fixed in 10% formalin and embedded in paraffin according to conventional methods. Staging for ovarian sex cord-stromal tumors is based on the International Federation of Gynaecology and Obstetrics classification (FIGO). Special stains periodic acid Schiff (PAS), PAS with digestion and Alcian Blue stain were used when needed. Immunohistochemical assessment was carried out using the avidin-biotin immunoperoxidase technique. The primary antibodies used in the study were Anti-inhibin (Dako, clone R1, 1:50 dilution); Vimentin (Dako; clone 3_4, 1:100 dilution), Alpha Smooth Muscle Actin (Dako; clone 1A4, 1:250 dilution), Desmin (Dako; clone D33, dilution 1:150), CD 99 (Dako; clone 12E7, pre-diluted), Cytokeratin Cam 5.2 (Becton, Dickson and Company, prediluted), Cytokeratin (AE1-AE3, Dako; 1:50 dilution), and EMA (Dako; clone E29; dilution 1:50).

Results

Total 513 cases of SCSTs were retrieved during the study period, all of these were diagnosed according to defined histological and immunohistochemical criteria. Out of these 39 tumours (7.6%) were present in patients with age of <21 years.

Clinical features

Median age was 162 months and age range was 4-250 months. 9 patients were in pre-pubertal group. The signs and symptoms varied according to age, with pseudo-precocious puberty and excess sex hormone symptoms like hirsutism and hoarsening of voice, being more common in premenstrual group. 77% of the pre-pubertal patients had signs and symptoms of isosexual pseudo-precocity. The post-pubertal patients presented with abdominal mass with discomfort (21/30) and abnormal uterine bleeding more frequently. Left ovary was a little more affected (n=18) than right one. Information regarding laterality was missing in 6 cases. All of the cases presented at FIGO Stage I except two cases which were extending beyond ovaries making the FIGO stage higher i.e. Stage II.

Table 1. Major Clinical Presentations of the Patients

Sign and symptom	No. of patients (%age)
Abdominal pain and/or discomfort	15 (38.4%)*
Abdominal mass or distention	9 (27%)
Nausea and vomiting	7 (21%)*
Precocious puberty	6 (18%)
Abnormal uterine bleeding	3 (9%)

*Overlapping of these symptoms was present in 5 patients

Table 2. Salient Clinical Features of Common Tumors

Type of tumour (n)	Median age in months	Mean Size (Range) in cm	Most common presenting symptom
Juvenile granulosa cell tumour (15)	168	16.2 (10-22)	Virilisation
Sclerosing stromal tumour (11)	199	10.7 (6.5-17)	Abdominal mass
Fibroma-thecoma group (10)	170	11.4 (4-17)	Abdominal mass

Histopathological features

Histological and special stain slides and the biopsy reports were available for all the 39 cases examined. The most common specimen type was unilateral salpingo-oophorectomy (n=20) and ovarian cystectomy (n=14). Other specimen types included, total abdominal hysterectomy with bilateral salpingo-oophorectomy (n=1) and ovarian mass biopsy (n=4). Mean size+SD was 11.2+4.6 cm.

Juvenile granulosa cell tumour

Of the various tumour types, JGCT comprised the bulk with more than 1/3rd of the cases i.e. 15 cases (38.4%). Patient's age ranged widely from 4-212 months. In premenstrual females, majority were of this type (6/9, 66.6%). Size was large in most of cases with mean of 16.2 cm (Range=10-22 cm). On gross examination, most of the cases showed cystic areas (10/15) along with solid haemorrhagic and yellowish areas. Mitotic activity was towards higher side in most of the cases (Range: 2-28 mitoses per 10 HPF). Most of cases showed strong positivity for Inhibin (n=9), while other showed weak positivity.

Sclerosing stromal tumour

Surprisingly SSTs were the second most common tumour, total 11 in no., which in literature have been reported to be Sertoli Leydig cell tumour. Mitoses were largely absent. Size range was 6.5-17 cm. Mean age was 192 months. All the cases were negative for immunostains Cytokeratin Cam 5.2 and EMA, but two cases showed focal positivity for Cytokeratin AE1/AE3. Special stain PAS-alcian blue was applied in all of cases, showed mucin negativity, these two tests differentiated from most important and common differential metastatic signet ring cell adenocarcinoma (Krukenberg tumor), in this age group.

Fibroma-thecoma group

10 cases of fibrothecoma spectrum with 5 fibrothecoma, 4 fibromas and 1 case of thecoma were found. Fibrothecomas were whitish-yellow solid tumors. Right sided ovary was the affected side in all the cases. The size ranged from 4-17 cm. one of the fibroma showed mitoses and cellularity, with the diagnosis of mitotically active cellular fibroma. Mitoses were absent in rest of cases.

Sertoli leydig cell tumour

Only two cases of Sertoli Leydig cell tumour were

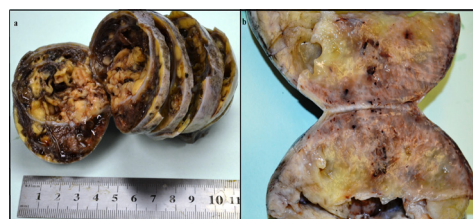


Figure 1. The Gross Specimens of JGCT (a) and SST (b) Showing Solid and Cystic Areas in Both Along with Prominent Haemorrhagic Areas in JGCT

Table 3. Detailed immunohistochemical Features of JGCT

Tumor no.	Age in months	Side of ovary	Immunohistochemical features							
			Inhibin	CK Cam 5.2	CK AE1/AE3	Mic-2	Calretinin	ASMA	EMA	Vim
1	4	Left	+	-	+	+	+	NA	-	+
2	8	---	+	Focal +	NA	+	-	-	-	+
3	24	Left	+	-	-	-	+	NA	NA	+
4	36	Left	+	-	+	+	+	NA	-	+
5	72	Right	+	-	+	+	+	NA	-	+
6	156	---	+	-	-	NA	NA	-	NA	+
7	168	Right	+	NA	-	+	+	NA	NA	NA
8	180	Right	+	-	-	NA	NA	-	NA	NA
9	187	Left	+	-	+	+	+	NA	-	+
10	190	Left	+	Focal +	-	NA	NA	-	-	+
11	193	Left	+	NA	-	+	+	NA	NA	+
12	194	Left	+	NA	-	+	NA	NA	NA	NA
13	202	Left	+	-	NA	+	NA	NA	NA	NA
14	211	Left	+	-	+	+	-	-	-	+
15	212	Left	+	-	-	NA	+	-	NA	+

*Abbreviations: CK, Cytokeratin; ASMA, alpha smooth muscle actin; Vim, Vimentin; EMA, Epithelial Membrane Antigen

Table 4. Detailed Immunohistochemical Features of SST

Tumor no.	Age in months	Side of ovary	Immunohistochemical features							
			Inhibin	CK Cam 5.2	CK AE1/AE3	Mic-2	Calretinin	ASMA	EMA	Vim
1	120	Right	+	-	-	NA	+	NA	NA	NA
2	188	Left	-	-	-	+	+	-	NA	+
3	188	Right	+	-	-	-	+	+	-	NA
4	192	Left	+	-	-	+	+	+	NA	+
5	196	Left	Focal +	-	-	NA	+	+	NA	NA
6	198	Right	-	-	Focal +	+	NA	+	-	+
7	206	Left	+	-	-	+	+	NA	NA	+
8	210	Right	+	-	-	NA	NA	-	NA	NA
9	216	Right	+	-	-	+	NA	-	-	+
10	216	Left	+	-	-	+	+	-	-	+

*Abbreviations: CK, Cytokeratin; ASMA, alpha smooth muscle actin; Vim, Vimentin; EMA, Epithelial Membrane Antigen

encountered in this age group, out of 39 cases diagnosed overall during this study period. Both of these had intermediate differentiation. One case recurred and other lost to follow up.

Sex cord tumour with annular tubules

One case of a very rare tumour SCTAT was also found. Size of the tumour was 7 cm and patient's age was 14.3 yrs.

Immunohistochemical studies

Detailed immunohistochemical analysis was done in most of the cases i.e. 33 cases. Focal Cytokeratin Cam 5.2 positivity was seen in two cases of JGCT only. EMA was negative in all the cases, where applied. Its negativity played important diagnostic role in differentiating SST from Krukenberg tumour, which has a very simulating histology. CD-10 was negative in fibromas. Inhibin, Calretinin, and CD99 (mic-2) were frequently strong positive in all the varieties of SCST.

Follow-up:

Recurrence was noted in 2 cases with follow-up data. Both the cases were of juvenile granulosa cell tumour and in both cases the recurrent tumour material was diagnosed at our own hospital. One case was strange to have metastasis of JGCT in skin of arm.

Cisplatinium-based chemotherapy was the most common regimen which was used in cases of incomplete excision. In most of the cases with stage I disease having

intact capsule, the patients remained healthy without any evidence of recurrence and/or metastasis without any adjuvant chemo or radiotherapy.

Discussion

Even though, Ovarian cancer is the most common paediatric gynaecologic malignancy, ovarian SCSTs are rare and infrequent finding when ovarian masses are dealt with histologically (Paternoster et al., 2011; Metwalley et al., 2012; Olivier et al., 2012). These non germinative tumours are heterogeneous morphologically, being rarer in children in which either benign epithelial tumours or germ cell tumours of ovarian origin are found (Cecchetto et al., 2011; Park et al., 2011). In our centre at Aga Khan University Hospital, the laboratory processes over 50,000 surgical specimens per year and out of these, quite a few are from children and adolescents. When present in children, ovarian tumors exhibit distinctive challenges for diagnosis and further management. These tumors must be considered in the differential diagnosis of germ cell tumors in young patients specifically when hormonal signs are not present. Here, we review the spectrum of these tumours found in young women and girls in our set up.

SCSTs comprise of sex cord or stromal cells of ovary i.e. Granulosa/theca cells, Sertoli cells, or Leydig cells represent approximately 7-10% of all ovarian neoplasms. It although affects all age groups, are somewhat less frequent in younger age group (Leyva-Carmona et al., 2009; Chu et al., 2010). In our study, only 7.6% of all the

SCSTs diagnosed over a period of 20 years were present in children. These tumors may present with palpable mass or signs of hormone production. In literature about 40% have been reported to produce male hormones, causing virilisation, which may be used as clinical markers (Young 2005).

However they are of interest especially because of their hormonal nature. In our experience also, pseudo precocious puberty was the most common presentation in premenstrual girls. Although only 1% of all cases of precocity in pre-pubertal girls are due to granulosa-theca cell tumours, these tumours should be kept in mind when dealing with such cases (Schultz et al., 2006; Spitzer et al., 2007; Arhan et al., 2008). This feature is due to the derivation of SCST from cells which involved in the production of steroid hormones. However, benign ovarian cysts, as described in literature, can also be associated with specific estrogen-induced findings. In adolescents and post pubertal girls, other manifestations abnormal uterine bleeding and abdominal discomfort were common as shown in Table 1.

The patients' median age was post-pubertal i.e. 16 years. The youngest patient was only 4 months old and no case of this tumour in newborn was encountered. All the patients <6 years of age had JGCT (n=6). 30 patients were in post pubertal group. In contrast to other types of ovarian tumours in children, where the symptoms are insidious and usually the tumor is quite large by the time of surgery, the signs and symptoms due to sex hormone excess, these tumours had relatively smaller size. Concerning the clinical characteristics, the most common symptom in our series was abdominal pain with or without abdominal mass, which is in consensus with internationally published data. Also the endocrinological symptoms were more common in younger and pre-pubertal females, in agreement with other reports. For SLCT, these data was lower than expected. Only one SST and two Fibromas were encountered in premenstrual females. In post pubertal patients, 9 cases each of JGCT and SST were found as depicted in Table 2, while in literature Sertoli Leydig cell tumour are more common in this group (Schneider et al., 2003; Cecchetto et al., 2011).

Left ovary was a little more affected than right one. Most of the tumours were clinically and radiologically stage-I at time of diagnosis as reported in other studies (Arisaka et al., 1992; Till and Schmidt, 2005; Ferrari et al., 2007), however two were FIGO stage II. On gross examination, the JGCT and SST were frequently cystic as shown in the figure; however other types were predominantly solid masses. So enlargement and persistence of ovarian cysts should prompt clinician for further investigations and rule out chances of neoplasms.

As expected, JGCTs were the most frequent type of tumour comprising of 15 cases. These are considered to be benign subgroup of ovarian sex cord-stromal tumors, however two of the cases recurred and one showed metastasis to forearm skin. They have ability to secrete steroid hormones, our findings also conforming to previous reports of common presentations of JGCT. As Seckel also reported quite a few number i.e. 31 cases of ovarian GCT with sexual precocity (Young, 2005).

Adult type granulosa cell tumors (AGCT), as depicted by name, occur in older women but can also be found in girls. However we did not come across a case of AGCT.

Sertoli Leydig cell tumours, which have been reported in literature, as second most common group were very rare (Schneider et al., 2003; Pastore et al., 2009). Only 2 cases of SLCT were present in our study population and both having morphology of intermediate differentiation. In most of previous studies reported, fibrothecoma group comprised of one of common neoplasms among SCST in younger age, we also had 10 cases of tumours of this spectrum, and all of these behaved as benign tumours (Cecchetto et al., 2011).

One case of a very rare tumour SCTAT was also found. It proved to be a benign case, as majority of this subtype are.

As established in literature, majority i.e. >90% of JGCT are diagnosed at stage 1 and have a favourable outcome (Isguven et al., 2003; King et al., 2003; Chan et al., 2004). Fertility sparing surgery with unilateral oophorectomy/cystectomy is sufficient at this stage, as also proven by our findings, with limited follow-up although. Most of patients showed androgen excess signs and symptoms in our series too. Juvenile granulosa cell tumors are usually confined to the ovary and do not have metastatic potential (Toppari et al., 1998; Borer et al. 2000) however a very interesting finding was of metastasis of JGCT in subcutaneous tissue of patient's arm, after 2 ½ years of initial diagnosis. This patient was under treatment in other hospital and was lost to follow-up soon after the diagnosis of recurrence.

Fibrothecomas are benign tumors and very uncommon in children. The clinical similarities with other SCSTs make the histological evaluation necessary keeping in view the benignancy of the disease. However one of our cases had mitotic rate of 5/10 HPF and areas with moderate nuclear atypia. No significant pleomorphism or necrosis was appreciated in extensively sampled tissue, rendering a diagnosis of keep this purpose very difficult to achieve.

We came across only two cases of Sertoli-Leydig cell tumour, which in previous studies is bit more common among spectrum of ovarian SCST in children. May be this finding point towards lesser frequency in our region however this needs to be confirmed in future larger longitudinal studies. Both of the cases were of intermediate differentiation. These tumours are large and have a more aggressive behavior as compared to other types of SCST (Calaminus et al., 1997; Gwin K, Marino-Enriquez et al., 2008). One of our cases also had recurrence after 27 months of initial diagnosis.

The extension of the surgical excision for ovarian SCSTs is still debatable. We are unable to comment on this in detail due to little number of follow-ups (Moyle et al., 1995; Silverman et al., 1996). But limited fertility sparing surgery, in those cases where follow ups were available, was curative enough for the tumors with restricted ovarian involvement.

The diagnosis of SCST depends on morphological evaluation but immunohistochemistry also plays an important role particularly in simulating tumours. The histological diagnosis of SCST may be difficult,

especially for those SLCTs which can display a wide morphologic variation. In our experience, immunostains were helpful to exclude other diagnoses. The details of Immunohistochemical results in two most common tumours JGCTs and SST are presented in Table 3 and Table 4 respectively. In particular all juvenile granulosa cell tumors were Inhibin and Vimentin positive, whereas Pancytokeratin was focally or even diffusely positive in quite a large number of cases.

As in SST, the differential of metastatic carcinoma is largely impossible without special stains and immunohistochemistry. As previously reported, Inhibin was expressed in the vast majority of cases, except for few cases in fibrothecoma group.

One of the limitations of our study was unavailability of complete follow up data in all of cases, which could have added to the clinical behaviour of these tumours in this part of world.

In conclusion, SCST are very rare in young girls, mostly comprising of JGCT and SST in our population. Hormonal signs made the early diagnosis possible. In our experience, with limited follow up though, an initial complete excision was therapeutic in patients who have lone ovarian involvement and intact ovarian capsule.

Acknowledgements

We acknowledge Mr. Karim Bhojani for his assistance in slide and blocks' retrieval.

References

Arhan E, Cetinkaya E, Aycan Z, et al (2008). A very rare cause of virilization in childhood: ovarian Leydig cell tumor. *J Pediatr Endocrinol Metab*, **21**, 181-3.

Arisaka O, Matsumoto T, Hosaka A, et al (1992). Cystic adult granulosa cell tumor causing precocious pseudopuberty in a six-year-old girl. *Acta Paediatr*, **81**, 1061-4.

Borer JG, Tan PE, Diamond DA (2000). The spectrum of Sertoli cell tumors in children. *Urol Clin North Am*, **27**, 529-41.

Calaminus G, Wessalowski R, Harms D, Gobel U (1997). Juvenile granulosa cell tumors of the ovary in children and adolescents: results from 33 patients registered in a prospective cooperative study. *Gynecol Oncol*, **65**, 447-52.

Cecchetto G, Ferrari A, Bernini G, et al (2011). Sex cord stromal tumors of the ovary in children: a clinicopathological report from the Italian TREP project. *Pediatr Blood Cancer*, **56**, 1062-7.

Chan LF, Storr HL, Scheimberg I, et al (2004). Pseudo-precocious puberty caused by a juvenile granulosa cell tumour secreting androstenedione, inhibin and insulin-like growth factor-I. *J Pediatr Endocrinol Metab*, **17**, 679-84.

Chin VL, Sheffer-Babila S, Lee TA, Tanaka K, Zhou P (2012). A case of complete androgen insensitivity syndrome with a novel androgen receptor mutation. *J Pediatr Endocrinol Metab*, **25**, 1145-51.

Chu SM, Ming YC, Chao HC, et al (2010). Ovarian tumors in the pediatric age group: 37 cases treated over an 8-year period. *Chang Gung Med J*, **33**, 152-6.

Ferrari A, Bisogno G, De Salvo GL, et al (2007). The challenge of very rare tumors in childhood: the Italian TREP Project. *Eur J Cancer*, **43**, 654-9.

Gwin K, Marino-Enriquez A, Martel M, Reyes-Múgica M (2008). Sclerosing stromal tumors: an important differential

diagnosis of ovarian neoplasm in childhood and adolescence. *Pediatr Dev Pathol*, **12**, 1.

Isguven P, Yoruk A, Adal E, et al (2003). Adult type granulosa cell tumor causing precocious pseudopuberty in a 6 year-old girl. *J Pediatr Endocrinol Metab*, **16**, 571-3.

King DW, Steinmetz R, Wagoner HA, et al (2003). Differential expression of GRK isoforms in nonmalignant and malignant human granulosa cells. *Endocrine*, **22**, 135-42.

Leyva-Carmona M, Vázquez-López MA, Lendinez-Molinos F (2009). Ovarian juvenile granulosa cell tumors in infants. *J Pediatr Hematol Oncol*, **31**, 304-6.

Metwalley KA, Eلسers DA, Farghaly HS, Abdel-Lateif H, Abdel-Kader M (2012). Precocious puberty secondary to a mixed germ cell-sex cord-stromal tumor associated with an ovarian yolk sac tumor: a case report. *J Med Case Rep*, **6**, 162.

Moyles K, Chan YF, Hamill J, Massey R (1995). Ovarian Sertoli-Leydig cell tumor with retiform pattern. *Pathology*, **27**, 371-3.

Olivier P, Simoneau-Roy J, Francoeur D, et al (2012). Leydig cell tumors in children: contrasting clinical, hormonal, anatomical, and molecular characteristics in boys and girls. *J Pediatr*, **161**, 1147-52.

Park SM, Kim YN, Woo YJ, et al (2011). A sclerosing stromal tumor of the ovary with masculinization in a premenarchal girl. *Korean J Pediatr*, **54**, 224-7.

Pastore G, De Salvo GL, Bisogno G, et al (2009). Evaluating Access to Pediatric Cancer Care Centers of Children and Adolescents with Rare Tumors in Italy: the TREP Project. *Pediatr Blood Cancer*, **53**, 152-5.

Paternoster M, Graziano V, Settimi A, et al (2011). Medico-legal observations concerning a mortal case of granulosa cell tumor of the ovary in an 8-month-old infant. *J Pediatr Surg*, **46**, 1679-82.

Schneider DT, Calaminus G, Wessalowski R, et al (2003). Ovarian sex cord stromal tumors in children and adolescents. *J Clin Oncol*, **21**, 2357-63.

Schneider DT, Ute J, Calaminus G, Gobel U, Harms D (2003). Ovarian sex cord stromal tumors-A clinicopathological study of 72 cases from the Kiel Pediatric Tumor Registry. *Virchows Arch*, **443**, 549-60.

Schultz KA, Ness KK, Nagarajan R, Steiner ME (2006). Adnexal masses in infancy and childhood. *Clin Obstet Gynecol*, **49**, 464-79.

Silverman LA, Gitelman SE (1996). Immunoreactive inhibin, müllerian inhibitory substance, and activin as biochemical markers for juvenile granulosa cell tumors. *J Pediatr*, **129**, 918-21.

Spitzer RF, Wherrett D, Chitayat D, et al (2007). Maternal luteoma of pregnancy presenting with virilization of the female infant. *J Obstet Gynaecol Can*, **29**, 835-40.

Till H, Schmidt H (2005). Juvenile granulosa cell tumour (JGCT) of the ovary in a 6-year-old girl: laparoscopic resection achieves long-term oncological success. *Eur J Pediatr Surg*, **15**, 292-4.

Toppiari J, Kaipia A, Kaleva M, Laato M, et al (1998). Inhibin gene expression in a large cell calcifying Sertoli cell tumour and serum inhibin and activin levels. *APMIS*, **106**, 101-13.

Virgone C, Cecchetto G, Ferrari A, et al (2012). GATA-4 and FOG-2 expression in pediatric ovarian sex cord-stromal tumors replicates embryonal gonadal phenotype: results from the TREP project. *PLoS One*, **7**, 45914.

Young RH (2005). Sex cord-stromal tumors of the ovary and testis: their similarities and differences with consideration of selected problems. *Mod Pathol*, **18**, 81-98.