

RESEARCH ARTICLE

Expression of Annexin A3 in Gastric Cancer and its Correlation with Proliferation and Apoptosis

Jing-Ming Zhai^{1&}, Shi-Jun Sun^{3&}, Wei Wang¹, Chao Zeng^{2*}

Abstract

Annexin A3 has been identified as a novel biomarker in different types of cancers. However, little is known about its clinical significances and biological roles in gastric cancer. In this study, we assessed annexin A3 expression in 80 patients with gastric cancer and explore its correlation with prognosis. Moreover, correlations with Ki-67, Bcl-2 and Bax were also investigated. Expression of annexin A3 was increased in gastric cancer compared with that in normal gastric tissues. Annexin A3 expression was significantly associated with tumor volume and TNM stage ($p < 0.05$), and inversely correlation with prognosis of patients. More interestingly, expression of annexin A3 was positive correlated with Ki-67 and Bcl-2 expression. Our study showed annexin A3 might be a potential prognostic marker for gastric cancer and involved in tumorigenesis by regulating apoptosis and proliferation.

Keywords: Annexin A3 - gastric cancer - apoptosis - proliferation

Asian Pac J Cancer Prev, **15** (7), 3001-3004

Introduction

Gastric cancer is one of the most frequent digestive malignancies in the world (Vogelaar et al., 2012). In China, gastric cancer is the second cause of mortality related with cancer and constitutes approximately 30% of all worldwide gastric cancer new cases. Lots of gastric cancer patients are diagnosed at advanced stage and have high rates of lymph node metastasis. Despite some improvements are acquired in treatment of gastric cancer, prognosis is still unfavourable for patients. Thus there is an urgent need for finding effective molecular markers to improve the survival time of gastric cancer patients.

Annexin A3 is a member of a calcium-binding protein family that includes five groups (A-E) (Gerke et al., 2002; Gerke et al., 2005). As Ca^{2+} -dependent phospholipid-binding proteins, Annexin A-E possesses a variety of biological activities, such as regulating ion channels, mediating inflammatory response, participating in membrane trafficking (Raynal et al., 1994; Caohuy et al., 1996; Perretti et al., 2003). Recently, Annexin A3 was identified as a novel biomarker in different types of cancers, including prostate cancer (Wozny et al., 2007; Kollermann et al., 2008; Schostak et al., 2009), lung cancer (Liu et al., 2009) and colorectal cancer (Xie et al., 2013). However little is known about the effects of Annexin A3 in gastric cancer. The aim of our study was to explore Annexin A3 expression in gastric cancer samples and its

potential value as a prognostic marker for gastric cancer.

Interestingly, Annexin A3 could inhibit apoptosis of ovarian cancer cells (Yan et al., 2010). Moreover, down-regulated Annexin A3 expression promoted apoptosis and restrain proliferation of gallbladder cancer cells (Tan et al., 2010). Taking into account the few data concerning role of Annexin A3 in proliferation and apoptosis of gastric cancer, we initiated study the correlation of Annexin A3 with Ki-67, Bcl-2 and Bax. Therefore, Annexin A3 expression patterns and its roles in tumorigenesis of gastric cancer was thoroughly analyzed in the present study.

Materials and Methods

Patients and tissue samples

Gastric cancer specimens were collected from the Department of Pathology, the First Affiliated Hospital Henan University of Science and Technology between 2007 and 2008. For immunohistochemistry assay, gastric cancer cases included 80 paraffin-embedded samples, with mean age of 56 years (range, 45-70 years). Clinicopathologic features including age, gender, differentiation degree, tumor volume, invasion depth, TNM stage and lymph node metastasis were detailed in Table 1. The informed consent on collection of samples was obtained by each patient. The study was approved by the Medical Ethics Committee of the first affiliated hospital of Henan University of Science and Technology.

¹Departments of General Surgery, The First Affiliated Hospital Henan University of Science and Technology, Luoyang, ²Department of Pathology, Guangdong Medical College, Dongguan, ³Department of Pathology, People's Hospital of Zhongshan City, Zhongshan, China [&]Equal contributors *For correspondence: zengchaosysu@aliyun.com

Tissue microarray and immunohistochemistry

Tissue microarrays (TMAs) were constructed as the method described previously (Xie et al., 2003). Briefly, paraffin-embedded tissue blocks and the corresponding H&E-stained slides were overlaid for TMA sampling. Triplicate cylindrical tissues with 0.6-mm diameter were punched from selected tumor areas of individual donor tissue and re-embedded into a recipient paraffin block at the designated place. 4- μ m sections were cut from the TMAs deparaffinized by routine techniques. The slides were microwaved. The slides were microwaved in citrate buffer for 5 min for antigen retrieval.

4- μ m sections were cut from the TMAs deparaffinized by routine techniques. The slides were microwaved in citrate buffer for 8 min for antigen retrieval. Annexin A3 (SC-101885, Santa Cruz Biotechnology, CA, USA) was applied as primary antibody (1:100 dilution). Ki-67 (GT209401), Bcl-2 (GM088701) and Bax (A353302) were purchased from Gene Biotechnology (Shanghai, China). Labeling was detected by adding biotinylated secondary antibodies (Maxim-Bio, Fuzhou, China), avidin-biotin complex (Maxim-Bio), and stained with DAB (Maxim-Bio). Finally, the slides were counterstained with Hematoxylin.

Evaluation of Annexin A3, Ki-67, Bcl-2 and Bax expression

Annexin A3, Bcl-2 and Bax were scored according to the intensity (0, no staining; 1, weak staining; 2, moderate staining; 3, strong staining) and the percentage (extent staining) of tumor cells that were stained (0, no positive cells; 1, >10% of cancer cells stained; 2, 10%-50% of cancer cells stained; 3, >50% of cancer cells stained; 4, >75% of cancer cells staining positive). If the product of multiplication between staining intensity and the percentage of positive cells is ≥ 2 , it is thought as immunoreaction positive (+). Ki-67 was scored according to the positive number of 100 gastric cancer cells at high magnification. Serum was performed as negative control for the primary antibody.

Statistical analysis

All statistical analyses were performed by using SPSS 13.0 for Windows (SPSS, Inc, Chicago, IL). The correlation between Annexin A3 and clinicopathologic factors was evaluated by Fisher's exact test. Multivariate analysis was done by using Cox proportional hazards regression. Overall survival curves were generated according to the Kaplan-Meier method. A result was considered significant when the *p* value is <0.05 .

Results*Annexin A3 expression in gastric cancer tissues*

Annexin A3 was detected by immunohistochemistry in 80 gastric cancer cases. Immunohistochemical results were confirmed by two sophisticated pathologists. Annexin A3 immunoreactivity was found in 49 of the 80 (61.3%) cases. However, Annexin A3 staining in gastric tissues adjacent to cancer was negative. More importantly, as shown in Figure 1, Annexin A3 expression was only present in the cytoplasm of gastric cancer cells. In all

80 gastric cancer cases, Annexin A3 expression was scored positively in 49 cases and 18 of them had strong immunoreexpression.

Correlation between Annexin A3 and clinicopathological factors in gastric cancers

To better elucidate the clinical significance of Annexin A3 in gastric cancer, the association between Annexin A3 expression and the clinicopathologic factors was evaluated. Positive Annexin A3 expression was found in 31 of 42 (73.8%) cases with larger tumor volume, whereas only 18 of 38 (47.4%) smaller cases showed positive Annexin A3 staining. Therefore, our data indicated enhanced Annexin A3 expression was associated with tumor size. Additionally, 30 of 37 III and IV stage cases showed high Annexin A3 expression, however, 19 of 43 tumors positive Annexin A3 expression was only present in I and II stage cases,

Table 1. Correlation between Annexin A3 Expression and Clinicopathological Factors of Gastric Cancer Patients

Variable		Cases	Annexin A3 expression		<i>p</i>
			Negative	Positive	
Gender	Male	38	18	20	0.17
	Female	42	13	29	
Age	≥ 60	45	22	23	0.062
	<60	35	9	26	
Tumor size	≥ 6 cm	42	11	31	0.022*
	<6 cm	38	20	18	
Differentiation degree	Well/Moderately	54	24	30	0.15
	Poorly	26	7	19	
Invasion Depth	T1+T2	48	16	32	0.249
	T3+T4	32	15	17	
Lymph node metastasis	Yes	34	9	25	0.065
	No	46	22	24	
TNM stage	I+II	43	24	19	0.001*
	III+IV	37	7	30	

**p* <0.05

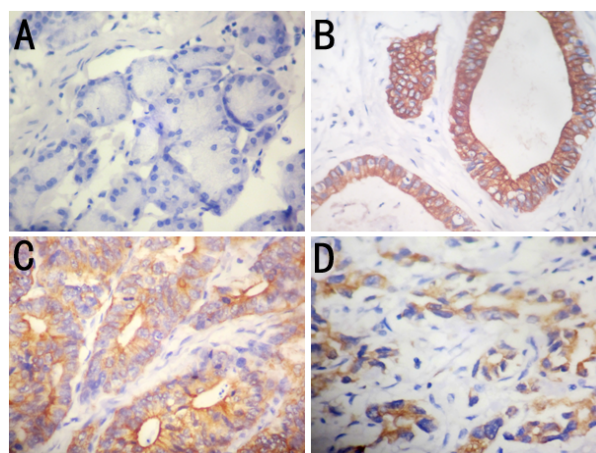


Figure 1. Expression Pattern of Annexin A3 in Gastric Cancer Tissues. (A) Normal gastric tissues showed no immunoreactivity of Annexin A3. (B) High Annexin A3 expression was detected in the well-differentiated gastric cancer ($\times 200$). (C) Annexin A3 expression was shown in moderately-differentiated gastric cancer. (D) Annexin A3 expression was shown in poorly-differentiated gastric cancer ($\times 200$)

indicating Annexin A3 might participate in advancement of gastric cancer. As shown in Table 1, positive expression of Annexin A3 was significantly correlated with tumor size ($p=0.022$) and TNM stage ($p=0.001$). Moreover, there was no association between Annexin A3 expression and the other clinicopathologic parameters, such as gender, age, differentiation degree, depth of invasion and lymph node metastasis ($p>0.05$).

Annexin A3 is an independent prognostic biomarker for poor outcome of gastric cancer patients

To better clarify the role of Annexin A3 in prognosis of gastric cancer, Kaplan-Meier survival curves was employed to evaluate overall survival time of patients. Patients with positive Annexin A3 expression had worse prognosis compared with those with negative expression (Figure 2) ($p<0.05$). Univariate and multivariate analyses were used to assess the influence of Annexin A3 expression and other clinicopathological factors on the prognosis of gastric cancer patients. Univariate Cox regression analysis indicated high Annexin A3 expression, lymph node metastasis, TNM stage, invasion depth was significantly correlated with overall survival of patients (Table 2). By multivariate analyses, TNM stage, lymph node metastasis and Annexin A3 expression were associated with poor overall survival. Hence, Annexin A3 expression is an indicator of a poor prognosis for gastric cancer patients. In all clinicopathologic parameters, lymph node metastasis was the most independent factor as a prognostic biomarker ($p=0.011$) (Table 2). In accordance with our results, previous study found TNM and lymph node metastasis are all independent prognostic factors affecting the survival of patients with gastric cancer (Cao et al., 2013).

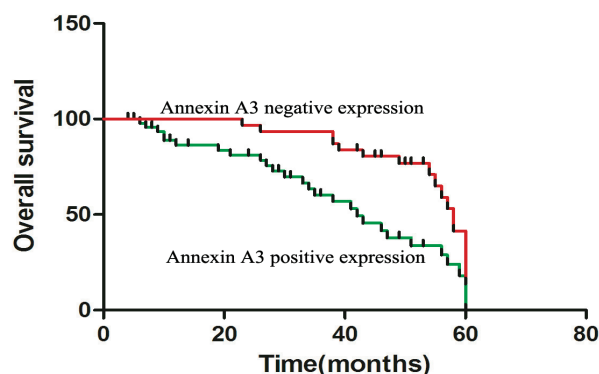


Figure 2. The Gastric Cancer Patients with Positive Annexin A3 Expression had Worse Prognosis than Those with Negative Expression of Annexin A3 by Using Kaplan-Meier Survival Analysis

Table 2. Univariate and Multivariate Analysis of Overall Survival of Patients with Gastric Cancer

Factor	Univariate analysis			Multivariate analysis		
	Hazard ratio	95%CI	p value	Hazard ratio	95%CI	p value
Gender	1.793	0.913-2.916	0.351			
Age (year)	1.205	0.899-1.362	0.498			
Invasion Depth	4.981	3.687-11.497	0.002	2.874	0.675-5.981	0.062
Differentiation degree	0.954	0.293-2.765	0.695			
Tumor size	1.232	0.342-3.892	0.896			
TNM stage	0.113	0.043-0.479	0.003	0.18	0.038-0.698	0.024
Lymph node metastasis	5.907	3.245-16.542	0.002	3.976	1.591-8.765	0.011
Annexin A3 expression	4.799	2.731-15.683	0.004	4.127	2.014-9.807	0.021

Association between Annexin A3 and proliferation index (PI)

To investigate the effect of Annexin A3 on proliferation of gastric cancer, we study the association between Annexin A3 and proliferation index. In the present study, proliferation index was reflected by means of Ki-67. As shown in Figure 3, PI in the positive Annexin A3 expression group was significantly higher (59.2 ± 7.8) compared with that in the negative Annexin A3 expression group (20.9 ± 6.3) (Table 3; $p<0.01$). These results indicated Annexin A3 might be involved in proliferation of gastric cancer cells.

Correlation between Annexin A3 and Bcl-2, Bax

In all gastric cancer specimens, 35 among 49 Annexin A3-stained cases showed Bcl-2 immunoreactivity. As shown in Figure 3, Bcl-2 expression was located in the cytoplasm of gastric cancer cells. Moreover, among 31 cases with Annexin A3 negative expression, 21 cases had not detected Bcl-2 staining. However, apart from 7 positive expression cases, the other samples showed no Bax immunoreactivity (Figure 3).

Discussion

Recently, more attention has been focused on Annexin A3 as its key roles in tumorigenesis of different tumors. Some studies reported that Annexin A3 expression was

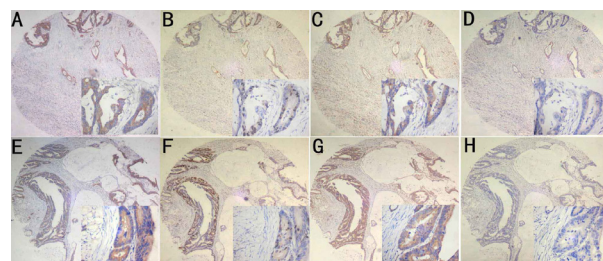


Figure 3. Immunohistochemical Staining of Annexin A3, Ki-67, Bcl-2 and Bax in Gastric Cancers. (A, E) Positive expression of Annexin A3 in gastric cancer. (B, F) Ki-67 expression in gastric cancer. (C, G) Bcl-2 expression in gastric cancer. (D, H) No-staining of Bax in gastric cancer

Table 3. Correlation Between Annexin A3, Bcl-2, and PI

Annexin A3	n	Bcl-2*		PI**
		+	-	
+	49	35	14	59.2±7.8
-	31	10	21	20.9±6.3

* $p<0.05$; ** $p<0.01$

up-regulated in lung (Wu et al., 2013), breast (Zeng et al., 2013) and colorectal cancer (Xie et al., 2013). Furthermore, increased expression of Annexin A3 was correlated with lymph node metastasis and poor survival rate in lung cancer. However, Annexin A3 protein expression was essentially reduced and it could be an independent adverse prognostic factor in renal-cell (Bianchi et al., 2010) and papillary thyroid cancer (Jung et al., 2010). Faced with two apparently contradictory statements, it raised our interest to investigate the functions of Annexin A3 protein in conjunction with clinical outcome of the patients with gastric cancer.

This study is the first one that systematically explored the Annexin A3 expression in gastric cancers. In our study, Annexin A3 expression was significantly stronger in gastric cancer tissues compared with their normal counterpart. Immunohistochemistry assay demonstrated that cases with positive Annexin A3 expression had bigger tumor volume, which might indicated Annexin A3, to some extent, involved in proliferation of gastric cancer cells. Moreover, Annexin A3 expression was associated with the TNM stage. Consequently, Annexin A3 overexpression may suggest that patients have a worse prognosis. The following results confirmed that Annexin A3 was an independent prognostic marker for gastric cancer by Kaplan-Meier log rank analysis and multivariate analyses.

Previous study found Annexin A3 expression was associated with tumor volume. Hence, the correlation between Annexin A3 and proliferation, apoptosis of gastric cancer was investigated. Experimental results demonstrated Annexin A3 was associated with Ki-67, indicating Annexin A3 might be participated in proliferation of gastric cancer. In the Bcl-2 protein family, proapoptotic member Bax and antiapoptotic member Bcl-2 are the active effectors and regulators (Li et al., 2013). Taking into account the important role of Bcl-2 and Bax in determining apoptosis of cancer cells, the association between Annexin A3 and Bcl-2, Bax was needs to be explored. Further study found the positive rate of Bcl-2 in Annexin A3-positive cases was significantly higher compared with that in Annexin A3-negative cases. It is worthwhile to note that only 7 cases have Bax immunoreactivity, suggesting Bax expression is irrelevant to Annexin A3. Therefore, Annexin A3 might be involved in tumorigenesis of gastric cancer by regulating the proliferation and apoptosis of gastric cancer cells.

In conclusion, annexin A3 is an independent prognostic factor for gastric cancer and it will be a potentially new target in gastric cancer therapy. More importantly, Annexin A3 has vital effects on proliferation and apoptosis of gastric cancer cells. The precise molecular mechanisms of Annexin A3 participate in tumorigenesis of gastric cancer need further investigation.

References

- Bianchi C, Bombelli S, Raimondo F, et al (2010). Primary cell cultures from human renal cortex and renal-cell carcinoma evidence a differential expression of two spliced isoforms of Annexin A3. *Am J Pathol*, **176**, 1660-70.
- Cao F, Hu YW, Li P, et al (2013). Lymphangiogenic and angiogenic microvessel density in chinese patients with gastric carcinoma: correlation with clinicopathologic parameters and prognosis. *Asian Pac J Cancer Prev*, **14**, 4549-52.
- Caohuy H, Srivastava M, Pollard HB (1996). Membrane fusion protein synexin (annexin VII) as a Ca^{2+} /GTP sensor in exocytotic secretion, *Proc Natl Acad Sci USA*, **93**, 10797-802.
- Gerke V, Moss SE (2002). Annexins: from structure to function. *Physiological Reviews*, **82**, 331-71.
- Gerke V, Creutz CE, Moss SE (2005). Annexins: linking Ca^{2+} signalling to membrane dynamics. *Nature Reviews Molecular Cell Biology*, **6**, 449-61.
- Jung EJ, Moon HG, Park ST, et al (2010). Decreased annexin A3 expression correlates with tumor progression in papillary thyroid cancer. *Proteomics Clin Appl*, **4**, 528-37.
- Kollermann J, Schlomm T, Bang H, et al (2008). Expression and prognostic relevance of annexin A3 in prostate cancer. *Eur Urol*, **54**, 1314-23.
- Li Y, Zhang S, Geng JX, et al (2013). Curcumin inhibits human non-small cell lung cancer A549 cell proliferation through regulation of Bcl-2/Bax and cytochrome C. *Asian Pac J Cancer Prev*, **14**: 4599-602.
- Liu YF, Xiao ZQ, Li MX, et al (2009). Quantitative proteome analysis reveals annexin A3 as a novel biomarker in lung adenocarcinoma. *J Pathol*, **217**, 54-64.
- Perretti M, Gavins FN (2003). Annexin 1: an endogenous anti-inflammation protein. *News Physiol Sci*, **18**, 60-64.
- Raynal P, Pollard HB (1994). Annexins: the problem of assessing the biological role for a gene family of multifunctional calcium- and phospholipid-binding proteins. *Biochim Biophys Acta*, **1197**, 63-93.
- Schostak M, Schwall GP, Poznanovic S, et al (2009). Annexin A3 in urine: a highly specific noninvasive marker for prostate cancer early detection. *J Urol*, **181**, 343-53.
- Tan Y, Meng HP, Wu Q, et al (2010). Proteomic study of gallbladder cancer, with special reference on the expression and significance of annexin A3. *Chin J Pathol*, **39**, 382-6.
- Vogelaar IP, van der Post RS, Bisseling TM, et al (2012). Familial gastric cancer: detection of a hereditary cause helps to understand its etiology. *Hered Cancer Clin Pract*, **10**, 18.
- Wozny W, Schroer K, Schwall GP, et al (2007). Differential radioactive quantification of protein abundance ratios between benign and malignant prostate tissues: cancer association of annexin A3. *Proteomics*, **7**, 313-22.
- Wu N, Liu S, Guo C, et al (2013). The role of annexin A3 playing in cancers. *Clin Transl Oncol*, **15**, 106-10.
- Xie YQ, Fu D, He ZH, et al (2013). Prognostic value of Annexin A3 in human colorectal cancer and its correlation with hypoxia-inducible factor-1 α . *Oncol Lett*, **6**, 1631-5.
- Xie D, Sham JS, Zeng WF, et al (2003). Heterogeneous expression and association of beta-catenin, p16 and c-myc in multistage colorectal tumorigenesis and progression detected by tissue microarray. *Int J Cancer*, **107**, 896-902.
- Yan X, Yin J, Yao H, et al (2010). Increased expression of annexin A3 is a mechanism of platinum resistance in ovarian cancer. *Cancer Res*, **70**, 1616-24.
- Zeng C, Ke Z, Song Y, et al (2013). Annexin A3 is associated with a poor prognosis in breast cancer and participates in the modulation of apoptosis in vitro by affecting the Bcl-2/Bax balance. *Exp Mol Pathol*, **95**, 23-31.