

## RESEARCH ARTICLE

# Accuracy of Magnetic Resonance Imaging in Pretreatment Lymph Node Assessment for Gynecological Malignancies

Saira Naz Sufian\*, Imrana Masroor, Waseem Mirza, Zainab Hussain, Saima Hafeez, Zafar Sajjad

### Abstract

**Objective:** To determine the accuracy of magnetic resonance imaging (MRI) in detection of metastasis in pelvic and para-aortic lymph nodes from different gynecological malignancies. **Materials and Methods:** This retrospective cross sectional analytic study was conducted at the Department of Diagnostic Radiology, Aga Khan University Hospital Karachi Pakistan from January 2011 to December 2012. A sample of 48 women, age range between 20-79 years, fulfilling inclusion criteria were included. All patients had histopathologically proven gynecological malignancies in the cervix, endometrium or ovary and presented for a pretreatment MRI to our radiology department. **Results:** MRI was 100% sensitive and had a 100% positive predictive value to detect lymph node metastasis in lymph nodes with spiculated margins and 100% sensitive with a 75% positive predictive value to detect lymph node metastasis in a lymph node with lobulated margins. The sensitivity and positive predictive value of MRI to detect heterogeneous nodal enhancement were 100% and 75% respectively. **Conclusions:** Our study results reinforce that MRI should be used as a modality of choice in the pretreatment assessment of lymph nodes in proven gynaecological malignancies in order to determine the line of patient management, distinguishing surgical from non-surgical cases.

**Keywords:** MRI - lymph nodes - gynecological malignancies - staging - metastasis

*Asian Pac J Cancer Prev*, 15 (11), 4705-4709

### Introduction

Gynecological malignancies contribute substantially to female mortality and morbidity. According to a study in 2006 uterine malignancies accounted for 41,200 newly diagnosed cases, ovarian malignancies for 20,180 and cervical malignancies for 9,710 cases. (Bankhead et al., 2008).

There is paucity of local data for the prevalence of endometrial malignancy however according to Karachi Cancer Registry statistics, female genital tract malignancies including ovaries, cervix and endometrium contributes 13% of all types of cancers in females. (Yasmin et al., 2006). In the advanced nations carcinoma of endometrium is the most common cancer of female genital organs. Most of these cancers detected while restricted to the uterus and usually presented with post-menopausal per vaginal hemorrhagic discharge or frank bleeding. (Wanitcharand Mongkol, 2012).

Ovarian malignancy causes more deaths than any other gynecological cancers and is the leading cause of death from cancer of female reproductive system. (Jelovac et al., 2011). In the United States, ovarian malignancy is the seventh most common cancer and accounting for 6% of deaths from malignancy in females. At the time of

diagnosis more than two thirds of females have progressive malignancy. Ovarian malignancy has the highest fatality-to-case ratio of all the cancers of female genital tract. (Bandit, 2013). In 1998 an estimated 25200 new cases of ovarian cancer and 14500 demises were documented in United States. (Li-Na et al., 2013). According to National Cancer Registry Programme of Indian Council Medical Research, proportion of ovarian malignancy had a range from 1.7% to 8.7% of all malignancies related to female genital tract in all populations including pastoral and metropolitan people. (Nandagudi et al., 2009).

The cervical malignancy is a gradual and slow growing tumor and PAP smear and HPV DNA test are the screening tools. (JV Joshi et al., 2011). Cervical infection by HPV 16 AND 18 is the main etiological factor of cervical malignancy. (Nabiha et al., 2010). Globally, the great prevalence of cervical malignancy is related to the deficiency of cervical cancer screening and lost follow up of cervical diseases. (Muhammad et al., 2009).

Metastatic involvement of lymph nodes from gynecological malignancies is a poor prognostic sign like in cervical malignancies metastatic involvement of para-aortic lymph node is an indication of bad prognosis ( Tanaka et al., 1984; Takeshima et al., 1999). In such cases nodal resection before commencing the radiotherapy

results in a better survival rate. (Potish et al., 1985; Downey et al., 1989).

The accurate assessment of metastatic involvement of lymph nodes is one of the most significant challenges in cancer imaging today. Pretreatment assessment of metastatic lymph nodes determines the line of patient's management, basically distinguishing surgical from non-surgical cases. (Morch et al., 2012).

Advanced stages of gynecological malignancies with a bulk of primary tumor have greater chances to have metastatic lymph nodes. (Melin et al., 2007) Rate of recurrence and overall survival are directly related to the nodal spread of the disease. Magnetic resonance imaging (MRI) is an excellent modality in identification of pelvic lymph nodes, their location and detection of their possible involvement by the primary disease. Lymph node size, shape and post contrast enhancement are a useful criteria for MRI assessment of lymph nodes. A lymph node should be regarded as enlarged on MRI if it is more than 8 mm in maximum short axis diameter (MSAD). (Barentsz et al., 1999).

In table1, according to two recent studies, normal MSAD of lymph node on MRI is given. (Vinnicombe et al., 1995; Grubnic et al., 2002).

According to several studies, rounded lymph nodes are more likely to be malignant (Potish et al., 1985) and ill-defined and irregular nodal margins are features suggestive of malignancy.

Bondt et al. has well described the morphological criteria of lymph nodes on MRI (Figure. 1). Smooth lymph node has well defined and smooth walls without any irregularity or lobulation. Lobulated lymph nodes are smooth walled but has lobulated margins. Spiculated lymph nodes are nodes having irregular margins with spikes or vegetation. Indistinct lymph nodes are nodes with margins which are difficult to appreciate. (R. B. J. de Bondt et al., 2009; Goro et al., 2013). In this study we used lymph node margins and enhancement pattern as the criteria.

## Materials and Methods

The data was collected retrospectively from patient's medical records. The study was conducted at the Department of Diagnostic Radiology Aga Khan Hospital University. The study duration was from January 2011 to December 2012, the age range was from 20 to 79 years (mean age 55 years).

### *Inclusion criteria*

Patients with histopathologically proven carcinoma endometrium, cervix and ovary with complete medical record were included in the study. All patient had pre-operative MRI of pelvis and lower abdomen.

### *Exclusion criteria*

Patients were excluded, who had evidence of distance metastasis or had contraindication to surgical procedure (i.e. unfit for surgery or anesthesia due to any reason), were also excluded if the patients were not to undergo laproscopic dissection of lymph nodes.

### *MRI protocol*

Before commencing the MRI scanning, an informed consent was taken. MRI pelvis was done on the Siemen's 1.5 T system using a torso phased - array coil for the abdominal scan and pelvic array coil for the pelvic scan.

T1-T2 sagittal, axial and coronal images were obtained with slice thickness of 4 mm, Intravenous Gadolinium was given in a dose of 0.2 mmol/kg. Images were taken from symphysis pubis upwards to the level of iliac blades in axial sections; however in coronal scanning para-aortic region was included up to the level of renal hilum.

According to anatomical landmark lymph nodes were classified in 7 groups: bilateral para aortic region, bilateral common iliac region, bilateral external iliac region, and bilateral internal iliac region and bilateral obturator region.

### *Surgical technique*

Pre operative bowel preparations and prophylactic antibiotics were given for 48 hours to all patients. During surgery, lymph nodes dissection of para aortic region and lymph nodes of pelvic region was done through laparotomy /laproscopic surgery.

### *Histopathological techniques and assessment of Lymph Node*

Histopathological evaluation of the lymph nodes was taken as a Gold Standard. Thin section of given lymph node were taken, each lymph node was sliced at 2 mm intervals All lymph nodes were stained with H & E, and assessed via microscope by a pathologist with 5 years of experience.

### *MRI analysis*

During MRI analysis, two consultant radiologists with at least 5 years of experience in female imaging, evaluated all the scans. They were unaware of the histopathological diagnosis of lymph nodes.

All visible lymph nodes were thoroughly inspected. Lymph nodes identified on MRI were recorded in terms of following features: *i*) Short - axis diameter. *ii*) Shape (rounded, oval, elongated). *iii*) Margins (smooth, lobulated, spiculated). *iv*). Post contrast enhancement pattern(homogenous, heterogeneous)

Axial T2 weighted fast spin echo sequences were used to assess the short axis diameter, shape and margins of lymph nodes. PACS (Picture Archiving and Communication System) monitor with electronic calipers were used for lymph node diameter measurements. Post contrast enhancement patterns either homogenous or heterogeneous were investigated on Gadolinium enhanced axial and coronal T1 weighted turbo spin echo sequences.

During short axis diameter evaluation, shape, margins and contrast enhancement pattern on MRI, it was difficult to assess the individual lymph node involved by the metastases on histopathology, as it was not possible to catch particular lymph node on MRI which one was malignant on histopathology. This limitation could be due to motion artifact and particular lymph node on MRI can be missed even with slice thickness of 4mm. We used number of positive or negative lymph nodes in MRI in each particular location and compared it with number of

positive or negative lymph node in this location of each patient.

### Statistics

Data was recorded on Performa for every patient. Sensitivity, specificity, positive predictive value and diagnostic accuracies were calculated using SPSS version 19. The Pearson's chi square test was used to compare the post contrast enhancement pattern and lymph node margins. A p value of less than 0.05 was considered to indicate a statistically significant difference.

## Results

Histopathological examination confirmed metastatic lymph nodes in 3 (6.25%) of the 48 patients. Total of 196 lymph nodes were identified on MRI and histopathology of all lymph nodes were obtained, only 26 were found to be malignant on histopathology. MRI showed in total 196 lymph nodes, the mean short axis diameter of metastatic lymph node was larger (6.16 +/- 3.0 mm, n= 26) than that of non- metastatic lymph node (4.40 +/-3.0 mm, n= 180) p=0.027. The number of lymph nodes sampled in each patient during surgery ranged from 1-37. Oval shaped and elongated lymph nodes are more likely to be non-metastatic however rounded nodes having equal chances to be metastatic and non-metastatic (p=0.001) (Table 2)

Lymph node with a lobulated margins (n=12) out of 196 detectable lymph nodes on M.R.I showed sensitivity and positive predictive values of 100% and 75% respectively, lymph node with spiculations (n= 3) showed both sensitivity and positive predictive value of 100% so they are reliable indicators of lymph node metastasis (p=0.000) Table2.

MRI with Gadolinium- enhanced T1 weighted images was performed on all patients. As heterogeneous

**Table 1. Normal lymph Node Size on MRI 95<sup>th</sup> Percentile value-5% FP Rate**

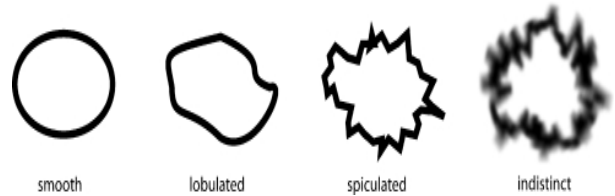
SITE	MSAD in mm
Common iliac	4
External iliac	5
Obturator	4
Internal iliac	5

**Table 2. Lymph Nodes Characteristics on MRI**

MRI findings	No (%) of lymph nodes			p
	Total	Metastatic	Non-metastatic	
Shape				0.001
Rounded	55(28)	4(2.0)	5(2.55)	
Oval	18(9.1)	4(2.0)	14(7.14)	
Elongated	124(63.2)	1(0.5)	123(62.7)	
Margins				0.000
Smooth	183(93)	6(3.06)	177(90.3)	
Lobulated	12(6.1)	9(4.6)	3(1.5)	
Speculated	3(1.5)	3(1.5)	0(0)	
Enhancement				0.000
Homogenous	187(95)	8(4.08)	179(91.3)	
Heterogenous	8(4)	6(3.06)	2(1.02)	

**Table 3. Accuracy Profile of Morphological Criterion**

MRI findings	Sensitivity	Specificity	PPV	Accuracy
Lobulated margins	100%	98%	75%	98%
Speculated Margins	100%	100%	100%	100%
Homogenous enhancement	100%	4%	4%	8%
Heterogenous enhancement	100%	98%	75%	98%



**Figure 1. Morphological Features of Lymph Nodes (R. B. J. de Bondt et al., 2009)**

enhancement was more commonly seen in metastatic lymph nodes (6/14 {42%}) than in non-metastatic lymph nodes (2/181 {1.1%}) and this difference was found to be statistically significant (0.000) (Table 2). The sensitivity and positive predictive value of heterogeneous enhancement were 100% and 75% respectively.

## Discussion

The application of advanced radiological modalities including MRI has been growing since 1980s and supplanting the other interventional imaging and invasive procedures. These advanced imaging modalities are necessary for accurate pretreatment staging as they are more informative than physical examination and provide details of lymph nodes metastases apart from tumor size and local invasion. (Janjira et al., 2012).

According to few studies, lymph nodes evaluation by MRI is still not an easy task, Study by Bipat et al showed that, for identifying nodal metastasis radiological tools including MRI and CT scan are not sufficiently accurate and that's why evaluation of nodal metastases remains a challenge. (Bipat et al., 2004).

Another study by Lambregts et al showed that MRI has an advantage of high tissue contrast but still for evaluation of nodal metastases it showed under staging up to 16%. (Lambregts et al., 2011). Furthermore, a few of these advanced modalities are still inaccessible in developing areas like China. (Chun et al., 2013).

However according another large group of studies, the accuracy and sensitivity rates for MRI are higher, i.e.between 76 and 100% and 36% and 89.5% respectively. (Togashi et al., 1986; Waggenspack et al., 1988; Togashi et al., 1989; Outwater et al., 1992; Kim et al., 1994; Yu et al., 1998; Yang et al., 2000; Choi et al., 2004).

'Lymph node positive' on MRI or histopathology means lymph node is suspicious to have metastases and confirm to have metastases respectively. 'Lymph node negative' on MRI or histopathology means lymph node is benign looking and confirm to have no metastases respectively.

Our results showed that lymph nodes with greater short axis diameter were malignant than lymph nodes with lesser short axis diameter (p=0.027), which is identical to the

study done by Takeshima et al. and elongated and oval shaped lymph nodes were non malignant and rounded lymph nodes were equally metastatic and non metastatic in our study ( $p=0.001$ ) and it is more consistent than a study by Takeshima et al which showed  $p=0.0263$ . (Yasmin et al., 2006).

A study by Bipat et al showed higher sensitivity of MRI for lymph nodes assessment and almost similar specificity to CT scan, but these results were influenced by short axis diameter criterion of lymph nodes. (Bipat et al., 2003; Janjira et al., 2012).

In our study, lymph nodes with lobulated margins on M.R.I showed sensitivity and positive predictive values of 100% and 75% respectively, lymph node with spiculations both sensitivity and positive predictive value of 100% so they are reliable indicators of lymph node metastasis ( $p=0.000$ ) this is more consistent than a study done by Takeshima et al, which showed sensitivity and positive predictive value on MRI to detect lymph node metastasis was 33.9% and 56.8%, respectively, this difference was probably due to size criteria which we did not apply but Takeshima et al. have applied both of these criteria that is, a short-axis diameter of 9 mm for the upper limit of a normal lymph node and spiculated/ lobulated margin. (Yasmin et al., 2006).

In our study, lymph nodes with lobulated margins on M.R.I showed sensitivity and positive predictive values of 100% and 75% respectively, lymph node with spiculations both sensitivity and positive predictive value of 100% so they are reliable indicators of lymph node metastasis ( $p=0.000$ ), our study showed higher accuracy of MRI than a study done by Choi et al. he reported MRI sensitivity and positive predictive values of 21.0% and 46.4%, respectively, ( $p=0.044$ ) for lobulated and spiculated lymph nodes. (Choi et al., 2006).

In our study heterogeneous enhancement was more commonly seen in metastatic lymph nodes and this difference was found to be statistically significant ( $p=0.000$ ), sensitivity and positive predictive value of heterogeneous enhancement were 100% and 75% respectively. It is more significant than a study done by Choi et al. (2006) in which post contrast heterogeneous lymph node enhancement was also more commonly noted in metastatic lymph nodes but this difference was not found to be statistically significant ( $p=0.076$ ). The sensitivity and positive predictive value of this criterion were 24.6% and 44.7%, respectively. Our study showed that postcontrast enhancement is the sensitive criterion in metastatic involvement evaluation of lymph nodes. This could be due to application of short axis diameter along with contrast enhancement criterion by Choi et al and we were unable to apply the short axis diameter along with enhancement criterion.

In the present study we found that on MRI, lymph node margins either spiculated or lobulated were strong indicators of metastatic involvement of lymph nodes, although desmoplastic reaction or tumor infiltration into perinodal fat could be the cause of spiculations and lobulations of lymph nodes margins (Yang et al., 2000; Toita et al., 2010).

In the present study, MRI is 100% sensitive and has

100% positive predictive value to detect lymph node metastasis with a spiculated margin node and MRI is 100% sensitive and has 75% positive predictive value to detect lymph node metastasis with a lobulated margin node (Table 3)

In this study, application of the enhancement pattern criterion was helpful to distinguish metastasis from non-metastatic nodes as the sensitivity and positive predictive value of heterogeneous enhancement were 100% and 75% respectively.

In this study, application of the long to short axis diameter ratio i.e shape criterion and maximum short axis diameter criterion resulted in low accuracy. This is most likely due to limited evaluation of the maximum cross section of lymph node on axial MRI and limitations of histopathological evaluation of a particular lymph node which was identified on M.R.I.

A limitation of the current study was the node by node comparison, which was also not possible in our set up, as obtaining the histology of individual lymph node identified on cross-sectional images is likely to remain exigent.

In conclusion, we found that margin lobulations, spiculations and heterogeneous post contrast enhancement of lymph node is correlated with lymph node metastasis in patient of gynecological malignancy. Address correspondence to Saira Naz Sufian.

## References

- Bankhead CR, Collins C, Stokes-Lampard H, et al (2008). Identifying symptoms of ovarian cancer: a qualitative and quantitative study. *BJOG*, **115**, 1008-14.
- Barentsz JO, Engelbrecht MRW, Witjes JAM, et al (1999). MR imaging of the male pelvis. *EurRadiol*, **9**, 1722-36.
- Bipat S, Glas AS, Van der Velden J, et al (2003). Computed tomography and magnetic resonance imaging in staging of uterine cervical carcinoma: a systematic review. *Gynecol Oncol*, **91**, 59-66.
- Bipat S, Glas AS, Slors FJ, et al (2004). Rectal cancer: local staging and assessment of lymph node involvement with endoluminal US, CT, and MR imaging--a meta-analysis. *Radiology*, **232**, 773-83.
- Choi SH, Kim SH, Choi HJ, Park BK, Lee HJ (2004). Preoperative magnetic resonance imaging staging of uterine cervical carcinoma: results of prospective study. *J Comput Assist Tomogr*, **28**, 620-7.
- Choi HJ, Kim SH, San-Soo, et al (2006). MRI for Pretreatment Lymph Node Staging in Uterine Cervical Cancer. *AJR*, **187**, 538-43.
- Chumworathayi B (2013). Personalized cancer treatment for ovarian cancer. *Asian Pac J Cancer Prev*, **14**, 1661-4.
- de Bondt RBJ, Nelemans PJ, Bakers F, et al (2009). Morphological MRI criteria improve the detection of lymph node metastases in head and neck squamous cell carcinoma: multivariate logistic regression analysis of MRI features of cervical lymph nodes. *EurRadiol*, **19**, 626-33.
- Downey GO, Potish RA, Adcock LL, Prem KA, Twiggs LB (1989). Pretreatment surgical staging in cervical carcinoma: therapeutic efficacy of pelvic lymph node resection. *Am J Obstet Gynecol*, **160**, 1055-61.
- Gao C, Li -T, Fang L, et al (2013). Pre-operative predictive factors for intra-operative pathological lymph node metastasis in rectal cancers. *Asian Pac J Cancer Prev*, **14**, 6293-9.

- Grubnic S, Vinnicombe SJ, Norman A, Husband JE (2002). MR evaluation of normal retroperitoneal and pelvic lymph nodes. *Clin Radiol*, **57**, 193-200.
- Hoque M, Ibekwe CM, Ntuli-Ngcobo B (2009). Screening and perceived severity of cervical cancer among women attending Mahalapye district hospital, Botswana. *Asian Pac J Cancer Prev*, **10**, 1095-100.
- Jelovac D, Armstrong DK (2011). Recent progress in the diagnosis and treatment of ovarian cancer. *CA Cancer J Clin*, **61**, 183-203.
- Joshi JV, Paradkar PH, Jagtap SS, et al (2011). Chemopreventive potential and safety profile of a *Curcuma longa* extract in women with cervical low-grade squamous intraepithelial neoplasia. *Asian Pac J Cancer Prev*, **12**, 3305-11.
- Kasuya G, Toita T, Furutani K, et al (2013). Distribution patterns of metastatic pelvic lymph nodes assessed by CT/MRI in patients with uterine cervical cancer. *Radiat Oncol*, 8-139.
- Kim SH, Kim SC, Choi BI, Han MC (1994). Uterine cervical carcinoma: evaluation of pelvic lymph node metastasis with MR imaging. *Radiology*, **190**, 807-11.
- Lambrechts DM, Beets GL, Maas M, et al (2011). Accuracy of gadofosveset-enhanced MRI for nodal staging and restaging in rectal cancer. *Ann Surg*, **253**, 539-45.
- Li-Na Li, Xin Zhou, Yang Gu, Jun Yan (2013). Prognostic value of MMP-9 in ovarian cancer: a meta-analysis. *Asian Pac J Cancer Prev*, **14**, 4107-13.
- Melin A, Sparen P, Bergqvist A (2007). The risk of cancer and the role of parity among women with endometriosis. *Hum Reprod*, **22**, 3021-6.
- Missaoui N, Hmissa S, Dante R, Frappart L (2010). Global DNA methylation in precancerous and cancerous lesions of the uterine cervix. *Asian Pac J Cancer Prev*, **11**, 1741-4.
- Morch LS, Lokkegaard E, Andreasen AH, et al (2012) Hormone therapy and different ovarian cancers: a national cohort study. *Am J Epidemiol*, **175**, 1234-42.
- Murthy NS, et al (2009). Changing trends in incidence of ovarian cancer - the indian scenario. *Asian Pac J Cancer Prev*, **10**, 1025-30.
- Outwater E, Kressel HY (1992). Evaluation of gynecologic malignancy by magnetic resonance imaging. *Radiol Clin North Am*, **30**, 789-806.
- Pecorelli S (2009). Revised FIGO staging for carcinoma of the vulva, cervix, and endometrium. *Int J Gynaecol Obstet*, **105**, 103-4.
- Petsuksiri J, Jaishuen A, Pattaranutaporn P, Chansilpa Y (2012). Advanced imaging applications for locally advanced cervical cancer. *Asian Pac J Cancer Prev*, **13**, 1713-8.
- Potish RA, Twigg LB, Okagaki T, Prem KA, Addcock LL (1985). Therapeutic implications of the natural history of advanced cervical cancer as defined by pretreatment surgical staging. *Cancer*, **56**, 956-60.
- Takeshima N, Yanoh K, Tabata T, et al (1999). Assessment of the revised international federation of gynecology and obstetrics staging for early invasive squamous cervical cancer. *Gynecol Oncol*, **74**, 165-9.
- Tanaka Y, Sawada S, Murata T (1984). Relationship between lymph node metastases and prognosis in patients irradiated postoperatively for carcinoma of the uterine cervix. *Acta Radiol Oncol*, **23**, 455-9.
- Togashi K, Nishimura K, Itoh K, et al (1986). Uterine cervical cancer: assessment with high-field MR imaging. *Radiology*, **160**, 431-5.
- Togashi K, Nishimura K, Sagoh T, et al (1989). Carcinoma of cervix: staging with MR imaging. *Radiology*, **171**, 245-51.
- Toita T, Ohno T, Kaneyasu Y, et al (2010). A consensus-based guideline defining the clinical target volume for pelvic lymph nodes in external beam radiotherapy for uterine cervical cancer. *Jpn J Clin Oncol*, **40**, 456-63.
- Vinnicombe S, Norman A, Husband J, Nicolson V (1995). Normal pelvic lymph nodes: documentation by CT scanning after bipedal lymphangiography. *Radiology*, **194**, 349-55.
- Waggenspack GA, Amparo EG, Hanninan EV (1998). MR imaging of uterine cervical carcinoma. *J Comput Assist Tomogr*, **12**, 409-14.
- Wanitchar Wilairat, Mongkol Benjapibal (2012). Presence of anemia and poor prognostic factors in patients with endometrial carcinoma. *Asian Pac J Cancer Prev*, **13**, 3187-90.
- Yang WT, Lam WW, Yu MY, Cheung TH, Metreweli C (2000). Comparison of dynamic helical CT and dynamic MR imaging in the evaluation of pelvic lymph nodes in cervical carcinoma. *AJR*, **175**, 759-66.
- Yasmin B, Bhurgri A, Sania N, et al (2006). Pakistan - Country profile of cancer and cancer control 1995-2004. *J Pak Med Assoc*, **56**, 124-30.
- Yu KK, Hricak H, Subak LL, Zaloudek CJ, Powell CB (1998). Preoperative staging of cervical carcinoma: phased array coil fast spin-echo versus body coil spin-echo T2-weighted MR imaging. *AJR*, **171**, 707-11.