

RESEARCH ARTICLE

Internal-External Percutaneous Transhepatic Biliary Drainage for Patients with Malignant Obstructive Jaundice

Chuan Xu¹, Peng-Hua Lv¹, Xin-En Huang^{2*}, Ling Sun¹, Shu-Xiang Wang¹, Fu-An Wang¹

Abstract

Purpose: To evaluate the effect of internal-external percutaneous transhepatic biliary drainage (IEPTBD) for patients with malignant obstructive jaundice. **Methods:** During the period of January 2008 and July 2013, internal-external drainage was performed in 42 patients with malignant obstructive jaundice. During the procedure, if the guide wire could pass through the occlusion and into the duodenum, IEPTBD was performed. External drainage biliary catheter was placed if the occlusion was not crossed. Newly onset of infection, degree of bilirubin decrease and the survival time of patients were selected as parameters to evaluate the effect of IEPTBD. **Results:** Twenty newly onset of infection were recorded after procedure and new infectious rate was 47.6%. Sixteen patients with infection (3 before, 13 after drainage) were uncontrolled after procedure, 12 of them (3 before, 9 after drainage) died within 1 month. The mean TBIL levels declined from 299.53 umol/L before drainage to 257.62 umol/L after drainage, while uninfected group decline from 274.86 umol/L to 132.34 umol/Lp ($P < 0.5$). The median survival time for uninfected group was 107 days, and for infection group was 43 days ($P < 0.05$). **Conclusions:** The IEPTBD drainage may increase the chance of biliary infection, reduce bile drainage efficiency and decrease the long-term prognosis, and the external drainage is a better choice for patients with malignant obstructive jaundice need to biliary drainage.

Keywords: Internal-external drainage - infection - malignant obstructive jaundice

Asian Pac J Cancer Prev, 15 (21), 9391-9394

Introduction

Percutaneous transhepatic biliary drainage is becoming more and more useful as a palliative treatment for patients with malignant obstructive jaundice, which could not only significantly reduce bilirubin levels, improve liver function and prolong survival time, but also be used as a preoperative drainage, provide the conditions for subsequent treatment (Boursier et al., 2009; Herzog et al., 2012; Kaya et al., 2012; Zhu et al., 2012). In our center, if the guide wire could pass through the occlusion and into the duodenum, we prefer to use internal-external drainage, while the occlusion is not crossed, external drainage biliary catheter is placed. We think that internal-external drainage in the treatment of malignant obstructive jaundice not only could lead bile flow into intestine, maintain the physical channel of bile drainage, also decline bilirubin level quickly which is beneficial to the recovery of liver function and reduce the gastrointestinal complications caused by lack of bile. In order to evaluate the efficacy of this kind of treatment, we collect patients with malignant obstructive jaundice receiving this procedure in 2008-2013.

Materials and Methods

We retrospectively analyzed 42 patients (man 27; women 15; mean age 59 ± 15 years) with malignant obstructive jaundice receiving internal-external drainage from January 2008 to July 2013. All patients with infection received blood and bile bacteriological cultivation before, during and, after drainage (Table 1). All patients provided written, informed consent for the procedure, and institutional review board approved the retrospective review of medical and imaging records of all patients. Internal-external drainage was performed in the Interventional Diagnosis and Treatment Center, with

Table 1. Bacteria of Infection

Bacterias	Preprocedure infection	Postprocedure infection
Escherichia coli	2	7
Enterobacter cloacae		5
Enterococcus faecalis	1	3
Klebsiella pneumoniae		2
Pseudomonas aeruginosa	1	1
Staphylococcus aureus		2

¹Department of Interventional Radiology, Subei People's Hospital of Jiangsu Province, Clinical Hospital of Yangzhou University, Yangzhou, ²Department of Chemotherapy, Jiangsu Cancer Hospital, Nanjing Medical University, Nanjing, Jiangsu, China *For correspondence: huangxinen06@aliyun.com

Table 2. TBIL Changes

	TBIL (umol/L)		P value
	Before procedure	After procedure	
Infected group	299.53±143.19	277.62±147.91	0.086
Uninfected group	274.86±132.34	132.34±102.34	0.031

Table 3. Effect Evaluation

	Infected group	Uninfected group	P value
TBIL changes (umol/L)	-20.12±38.88	-152.51±106.93	0.0022
Survival time (days)	22.00±123.12	107.50±184.32	0.0004

*TBIL change values: postprocedure values minus preprocedure values, compared two groups of the change of value

the patient under local anesthesia by two interventional radiologists, using continuous fluoroscopy. Intravenous prophylactic antibiotic was given before all procedures using a second-generation cephalosporin or according to the recommendations from oncologists. Biliary puncture were carried out using a 21G Chiba needle through the ninth or tenth intercostal space at the right hemiclavicular line level for the right-lobe bile duct access or by the left anterior subxiphoid access for left-lobe bile ducts. After bile duct contrastation, a coaxial system (NPAS-100; Cook, Bjæverskov, Denmark) was introduced and a 0.035-in. angled-tip hydrophilic guidewire (Glidewire; Terumo, Tokyo, Japan) was used to cross the stenotic/obstructive area. During the procedure, if the guide wire could pass through the occlusion and into the duodenum, we prefer to use internal-external drainage. External drainage biliary catheter was placed if the occlusion was not crossed.

Patients with biliary tract infection diagnostic criteria: chills, high fever, with or without abdominal pain, have jaundice, peripheral blood WBC > 10.0×10⁹/L and neutrophils ratio > 75%, combined with blood and bile bacteria culture result, and exclude other causes of infection. We collect TBIL values one day before procedure and one week after procedure. Overall survival was defined as the time from the transhepatic biliary drainage to death for any cause. Overall survival was estimated by Kaplan–Meier. Prognostic factors were evaluated by t test and χ^2 or Fisher's exact test, and considered as statistically significant if the *P* value was under 0.05. All statistical analyses were done using stata10.0.

Results

Forty two patients are all successfully treated with internal-external drainage in our department, no major complications occurred during the procedure. Four patients were diagnosed with infection before drainage and 1 patient with infection was controlled after drainage. Twenty patients were detected with new infection after drainage and 7 were controlled.

Prophylactic antibiotic therapy was undertaken before culture results come out. Sixteen patients with infection were not well controlled after the procedure, 12 of them (3 patients before drainage, 9 patients after drainage) died

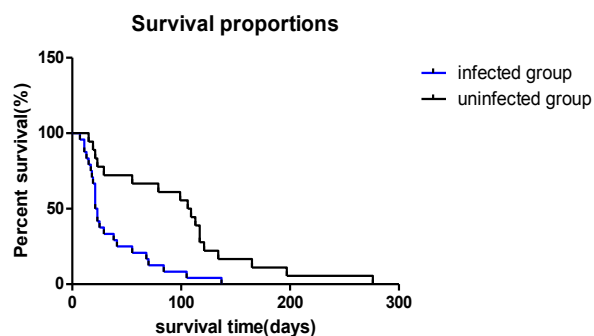


Figure 1. Cumulative Survival Rate in Patients with Infected Group and Uninfected Group. Date were obtained with the Kaplan Meier method

within 1 month, mainly caused by septic shock or multiple organ function failure. For other 4 patients whose infection was not well controlled, their survival time are 38 days, 41 days, 55 days and 68 days respectively.

For patients in infection group, the mean TBIL levels declined from 299.53 umol/L before drainage to 277.62 umol/L after drainage; while for patients in uninfected group, declined from 274.86 umol/L to 132.34 umol/L (Table 2). The TBIL levels in patients with uninfected group was significantly lower compared with those in infected group (*P* < 0.5) (Table 3). The median survival time in uninfected group was 107 days, and in infection group was 22 days (*P* < 0.05) (Figure 1).

Discussion

Percutaneous transhepatic biliary drainage is becoming more and more useful as a palliative treatment for patients with malignant obstructive jaundice, which could not only significantly reduce bilirubin levels, improve liver function and prolong survival time, but also be used as a preoperative drainage, provide conditions for subsequent treatment (Dambraukas et al., 2003).

Biliary infection is one of the most common complications in patients with malignant obstructive jaundice, and is also the major cause of death perioperation (Namiyas et al., 2005). As previous report, the incidence of infection after drainage in malignant obstructive jaundice is 14% - 47% (De et al., 2013), cholestasis caused by biliary obstruction is advantageous to the bacteria breeding, and high bilirubin levels is easy leading to intestinal flora, intestinal mucosa barrier damage and bacterial translocation (Englesbe et al., 2005; Ozden et al., 2005). The rate of newly onset of infection after drainage reached 47.6% in our study, this infection rate is high. It is generally believed that there are three possible ways cause infection after internal-external drainage. The first is bacteria from out of body vitro drainage tube into the bile duct; the second is from intestinal flora retrograde into the bile duct; the third is from blood spread to biliary tract. In our study, we consider that the infection mainly related to retrograde intestinal juice because most of the bacteria come from the intestinal flora according to the result of culture. On the one hand, this may relate to the guide wire enter into the intestinal during procedure and take the intestinal bacteria into the biliary tract when withdraw

the wire. On the other hand, intestinal juice may flow into the biliary tract tube when drainage the bile due to the external drainage bag pressure is lower than the pressure in the intestine, which cause infection. And patients with malignant obstructive jaundice generally have weak status, the immune system function is lower, and increases the risk when take a further invasive treatment.

The most obvious biochemical index is high bilirubin in patients with malignant obstructive jaundice. High bilirubin level for patients with obstructive jaundice not only damage the liver cells and reduce the liver synthetic ability, but also inhibit the cardiovascular system and lead to renal insufficiency, which could cause serious respiratory failure (Todoroki et al., 2000; Xu et al., 2014). Some literatures point out that the biliary infection can reduce the patients' biliary drainage resulting in a no obvious decline in bilirubin level, also some patients' bilirubin levels may with higher than before (Shin et al., 2013; Simmons et al., 2006; Westwood et al., 2010). High bilirubin can stimulate cell toxicity, further reduce the defense reaction of cells, which increase the infection and affect the patient's further treatment. Therefore, it is important to relieve biliary obstruction, drainage of bile, reduce the bilirubin level (Jong et al., 2013). Yu et al analysis think that the recovery of liver function, bilirubin decreased in the infection group significantly less than the uninfected group (Yu et al., 2010). Our study shows that the mean TBIL level decreased significantly in patients with uninfected group compared to the infection group. Patients with biliary tract infection could affect the decline of bilirubin, which is consistent with previous study.

Our analysis shows that patients' mortality rates as high as 30% in a month after receiving internal-external drainage. Other literatures also conform that patients' mortality who receiving internal-external drainage significantly higher than the external drainage or biliary stenting treatment (Ho et al., 2013; Lofts et al., 1997; Manwong et al., 2013). But the internal-external drainage has no related to be beneficial for the physiological drainage and could achieve good prognosis as we previous thought. Internal-external drainage is not reducing patients' one month mortality rate, and high infection rate affected the long-term prognosis. Our study shows that the median survival time of infected group significantly lower compared to the uninfected group. We analyze this phenomenon may related to the structure of the internal-external drainage design. Some bile flow into the intestine and also there were some bile flow into to the drainage bag at the same time because we did not shut three-way cock when drainage, this inevitably cause intestinal juice reflux, which greatly increases the chances of intestinal retrograde infection, as most of the bacteria from the intestinal which is consistent with the culture results. Therefore, this treatment has defects and needs to be improved. Such as, we could shut three-way cock when internal drainage, which could greatly reduce the intestinal juice reflux and decrease the retrograde infection. Some scholars suggested that considering the general condition of patients with malignant obstructive jaundice is poorer and their survival time is short. The internal-external drainage increases the chances of infection which is one of the important cause in

perioperative patients died and also reduces the decline of bilirubin, so the external drainage is a good choice to treat the malignant obstructive jaundice, especially combined with patients with preoperative infection, which could significantly reduce the chance of biliary infection caused by bacteria retrograde.

To sum up, although the internal-external drainage seems to satisfy physiological drainage, the higher infection and mortality rate after drainage affect the long-term prognosis. We believe that patients with malignant obstructive jaundice need to biliary drainage, the external drainage is a good choice, especially combined with patients with preoperative infection, which could significantly reduce the chance of biliary infection caused by bacteria retrograde, increase bile drainage efficiency and improve the long-term prognosis.

References

- Ahn S, Lee YS, Lim KS, Lee JL (2013). Malignant biliary obstructions can we predict immediate postprocedural cholangitis after percutaneous biliary drainage? *Support Care Cancer*, **21**, 2321-6.
- Boursier J, Cesbron E, Tropet AL, et al (2009). Comparison and improvement of MELD and Child-Pugh score accuracies for the prediction of 6-month mortality in cirrhotic patients. *J Clin Gastroenterol*, **43**, 580-5.
- Dambrauskas Z, Paskauskas S, Lizdenis P, et al (2003). Percutaneous transhepatic biliary stenting: the first experience and results of the Hospital of Kaunas University of Medicine. *Med (Kaunas)*, **44**, 969-76.
- De Jong E.A, Moelker A, Leertouwer T, et al (2013). Percutaneous Transhepatic Biliary Drainage in Patients with Postsurgical Bile Leakage and Nondilated Intrahepatic Bile Ducts. *Dig Surg*, **30**, 444-50.
- Englesbe MJ, Dawes LG (2005). Resistant pathogen in biliary obstruction: importance of cultures to guide antibiotic therapy. *HPB*, **7**, 144-8.
- Jong Kyoung Choi, Ji Kon Kyu, Sang Hyub Lee, et al (2013). Palliative treatment of unresectable hepatocellular carcinoma with obstructive jaundice using biliary drainage with subsequent transarterial chemoembolization. *J Palliat Med*, **16**, 1026-33.
- Herzog T, Belyaev O, Hessam S, et al (2012). Bacteribilia with resistant microorganisms after preoperative biliary drainage the influence of bacteria on postoperative outcome. *Scand J Gastroenterol*, **47**, 827-35.
- Ho CS, Warkentin AE (2013). Evidence-based decompression in malignant biliary obstruction. *Korean J Radiol*, **13**, S56-61.
- Kaya M, Bestas R, Bacalan F, et al (2012). Microbial profile and antibiotic sensitivity pattern in bile cultures from endoscopic retrograde cholangiography patients. *World J Gastroenterol*, **18**, 3585-9.
- Lofts FJ, Evans TR, Mansi JL, Glees JP, Knight MJ (1997). Bile duct stents: is there an increased rate of complications in patients receiving chemotherapy? *Eur J Cancer*, **33**, 209-13.
- Manwong M, Songserm N, Promthet S et al (2013). Risk factors for cholangiocarcinoma in the lower part of Northeast Thailand: a hospital-based case-control study. *Asian Pac J Prev*, **14**, 5953-6.
- Namias N, Demoya M, Sleeman D, et al (2005). Risk of postoperative infection in patients with bacteribilia undergoing surgery for obstructive jaundice. *Surg Infect*, **6**, 323-8.
- Ozden I, Tekant Y, Bilge O, et al (2005). Endoscopic and radiologic interventions as the leading causes of severe cholangitis in a tertiary referral center. *Am J Surg*, **189**, 702-6.

- Simmons DT, Baron TH, Petersen BT, et al (2006). A novel endoscopic approach to brachytherapy in the management of Hilar cholangiocarcinoma. *Am J Gastroenterol*, **64**, 1792-6.
- Todoroki T (2000). Chemotherapy for bile duct carcinoma in the light of adjuvant chemotherapy to surgery. *Hepatogastroenterology*, **47**, 644-9.
- Westwood DA, Fernando C, Connor S, et al (2010). External percutaneous transhepatic biliary drainage for malignant biliary obstruction: a retrospective analysis. *J Med Imag Rad Oncol*, **54**, 108-10.
- Xu C, Huang XE, Lv PH, et al (2014). Analysis of different ways of drainage for obstructive jaundice caused by hilar cholangiocarcinoma. *Asian Pac J Cancer Prev*, **15**, 5617-20.
- Yu Li sol, Chang Won Kim, et al (2010). Early infectious complications of percutaneous metallic stent insertion for malignant biliary obstruction. *AJR Am J Roentgenol*, **194**, 261-5.
- Zhu HD, Guo JH, Teng GJ, et al (2012). A novel biliary loaded 125 I seeds in patients with malignant biliary obstruction: Preliminary results versus a conventional biliary stent. *J Hepatol*, **56**, 1104-11.