

RESEARCH ARTICLE

Elastography for Breast Cancer Diagnosis: a Useful Tool for Small and BI-RADS 4 Lesions

Xue-Jing Liu, Ying Zhu, Pei-Fang Liu*, Yi-Lin Xu

Abstract

The present study aimed at evaluating and comparing the diagnostic performance of B-mode ultrasound (US), elastography score (ES), and strain ratio (SR) for the differentiation of breast lesions. This retrospective study enrolled 431 lesions from 417 in-hospital patients. All patients were examined with both conventional ultrasound and elastography. Two experienced radiologists reviewed ultrasound and elasticity images. The histopathologic result obtained from ultrasound-guided core biopsy or operation excisions were used as the reference standard. Pathologic examination revealed 276 malignant lesions (64%) and 155 benign lesions (36%). A cut-off point of 4.15 (area under the curve, 0.891) allowed significant differentiation of malignant and benign lesions. ROC (receiver-operating characteristic) curves showed a higher value for combination of B-mode ultrasound and elastography for the diagnosis of breast lesions. Conventional ultrasound combined elastography showed high sensitivity, specificity, and accuracy for group II lesions (10mm < lesion diameter ≤ 20mm). Elastography combined with conventional ultrasound show high specificity and accuracy for differentiation of benign and malignant breast lesions. Elastography is particularly important for the diagnosis of BI-RADS 4 and small breast lesions.

Keywords: Ultrasound - elastography - breast lesions - strain ratio

Asian Pac J Cancer Prev, **15** (24), 10739-10743

Introduction

Breast cancer is a common form of malignant cancer in women. According to the WHO data, approximately 502,000 women world-wide die from breast cancer every year (Brenner et al., 2007; Leung et al., 2012). In recent years, the incidence of breast cancer has increased in China, and has been observed even in younger generations (Jing et al., 2014). The problem lies in the early detection of breast lesions so as to ensure a timely and effective treatment. The uses of ultrasonography have expanded from differentiating between cysts and solid masses to screening of breast cancer. This technique clearly displays the layers of tissues within the breast according to the acoustic impedance, which in turn aids in recording the difference in tumor edge, shape, and other characteristics. However, the sonographic features of benign and malignant lesions have been shown to have a substantial overlap with each other (Jackson et al., 1995; Rahbar et al., 1999).

Several other techniques are currently being investigated to find the most reliable and consistent solution for diagnosis of breast lesions, with lower user dependency and higher reproducibility in different clinical applications. Quantitative techniques and semi-

quantitative packages have been recently added to provide the user with objective data and measurements for an effective interpretation and comparison. Elastography is a non-invasive technique in which stiffness or strain images are used to detect or classify anatomical areas with different elasticity patterns. It has been shown to be useful in differentiating healthy tissue from a tissue that is undergoing change, such as tumor. This technique helps in differential diagnosis of the benign and malignant breast lesions, based on tissue stiffness (Moon et al., 2011). The applications of elastography ultrasound have grown over the past 10 years since its initial use in breast lesion assessment, and have recently extended to many other clinical uses. Today, elastography is regarded as a fundamental adjunct diagnostics tool for ultrasound imaging. The present study identified specific elastography characteristics that may be useful in differentiating benign from the malignant breast lesions in women with an indication for breast biopsy. A difference in the size of tumor between the B-mode and elastography imaging and the differential color patterns showing different grayscale distribution in the elastography image appear to be the new characteristics that allow distinguishing benign and malignant lesions (Adamietz et al., 2011).

The classification by the Breast Imaging Reporting and

*Department of Breast Imaging, Tianjin Medical University Cancer Institute and Hospital, National Clinical Research Center for Cancer. Key Laboratory of Cancer Prevention and Therapy; Key Laboratory of Breast Cancer Prevention and Therapy, Tianjin Medical University, Ministry of Education, Tianjin, China *For correspondence: cjr.liupeifang@vip.163.com*

Data System (BI-RADS) is commonly used to identify breast lesions as malignant or benign (Warner et al., 2001). In particular, in BI-RADS category 4 approximately 15% of the findings prove to be histologically malignant, while a much larger proportion of patients undergo invasive diagnostic procedures that might not be necessary if better imaging methods were available for accurate diagnosis. Presently, biopsy is used to supplement other diagnostic methods in the evaluation of breast lesions, but the rates of cancer detection in biopsies are only 10-30% (Chiou et al., 2006). Ultrasound elastography can identify benign and malignant breast lesions based on their tissue elasticity, which conventional ultrasound methods cannot obtain; thus, improving the accuracy of diagnosis of breast cancer, and reducing the unnecessary biopsy of BI-RADS 4 breast lesion.

Materials and Methods

Patients

This retrospective study was approved by our institutional review board. The requirement for informed consent was waived. All patients were examined by the same radiologists (specialists in radiology and medical imaging with 25 years of experience in breast imaging). Patients without any pathologic confirmation and elastography video data, and patients who presented with cystoid lesions seen on B-mode ultrasound were excluded from this study. Thus, we retrospectively analyzed 431 breast lesions from 417 in-patient women examined in the Breast Imaging Department of Tianjin Medical University Cancer Institute and Hospital, Tianjin, China, during the period from August, 2010 to January, 2013. Eight patients with two lesions in one side of breast, and six patients with one lesion in each side of the breast, with their age ranging from 20 to 71 years (mean of 44 ± 13 years) were chosen for the present study. The size of lesions ranged from 7mm to 70mm, with a mean size of 22 ± 1 mm. We divided all the lesions into 5 groups according to their size: group I, diameter ≤ 10 mm; group II, $20\text{mm} \geq \text{diameter} > 10$ mm; group III, $30\text{mm} \geq \text{diameter} > 20$ mm; group IV, $40\text{mm} \geq \text{diameter} > 30$ mm; group V, diameter > 40 mm. The patients with breast lesions confirmed by an ultrasound-guided core biopsy and removed within two weeks were eligible for this study.

Elastography and analysis

The lesions were evaluated by conventional ultrasound (B-mode), color Doppler ultrasound, and ultrasound elastography; all the 431 lesions were examined using the ultrasound machine Legiq E9 (General Electric Co., USA) with 6-15 MHz linear transducer. The characteristics were analyzed on a grey-scale sonogram (including shape, size, margin, boundary, internal echo, and back echo), color Doppler sonogram (containing RI, PSV, and CDFI), and sonoelastogram. The elastography study was performed with the patients lying in the same position as in conventional breast ultrasound. Real-time elastography images were then saved as video files for later review. The strain ratio (SR) was measured in all breast masses on a representative static image, including the coupled B-mode

and elastography images. For reference, the region of interest was drawn in the lateral subcutaneous fat tissue on the coupled elastography image, regardless of the depth of lesions. The SR was automatically calculated by the ultrasound scanner.

Two experienced radiologists independently analyzed the B-mode images according to the classification of the American College of Radiology BI-RADS system (2003), while the elastography video files were scored according to the elasticity scoring classification system proposed by Itoh et al. (2006). until a consensus was reached and the strain ratios were reviewed. We assigned the BI-RADS lesion category ≥ 4 as malignant. Elastography images were attributed to one of five elasticity scores: 1, the entire lesion was evenly shaded in green (an even strain across the entire hypoechoic lesion); 2, the hypoechoic lesion had a mosaic pattern of green and blue (strain in most of the hypoechoic lesion, with some areas of no strain); 3, the peripheral part of the lesion was green, and the central part was blue (strain at the periphery of the hypoechoic lesion, sparing its center); 4, the entire lesion was blue, but its surrounding area was not included (no strain in the entire hypoechoic lesion); 5, both the entire hypoechoic lesion and its surrounding area were blue (no strain in the entire hypoechoic lesion or in the surrounding area). When the score was above 3, the lesion was suspected to be malignant.

Statistical analysis

Spss 17.0 was used for statistical analyses. The sensitivity, specificity, and accuracy of the data were assessed. We calculated the cut-off points for the elasticity strain ratio. To summarize the overall performance of each method, areas under the receiver-operating characteristic (ROC) curves (Az) were estimated and compared. Adjusted odds ratios and 95% confidence intervals (CI) were also assessed. *p*-values < 0.05 were considered to be significant.

Results

In the present study, a retrospective analysis of 431 breast lesions from 417 in-hospital patients was undertaken, with their age ranging from 20 to 71 years (mean of 44 ± 13 years). There were eight patients with two lesions in one side of breast, and six patients having one lesion in each side of the breast. The size of the lesions ranged from 7 mm to 70 mm, with a mean size of 22 ± 1 mm. Pathologic examination revealed 64% carcinomas (276/431) and 36% benign lesions (155/431). The detailed pathologic diagnoses of all cases are presented in Table 1.

Conventional ultrasound diagnostic sensitivity, specificity, and accuracy were observed to be 87.0%, 79.2%, and 81.9%, respectively; while for elastography, the diagnostic sensitivity, specificity, and accuracy were 81.9%, 83.2%, and 82.4%, respectively. Using pathologic diagnosis as the gold standard, 1-specificity of different cut-off points of strain ratios as the abscissa, and sensitivity as the vertical axis, the ROC curve was plotted; a cut-off point of 4.15 allowed significant differentiation of malignant and benign lesions. Strain ratio showed

a sensitivity of 92.2%, a specificity of 72.5%, and an accuracy of 86.1%. The Az values were estimated to be 0.889 for ultrasound, 0.875 for elasticity score (ES), and 0.891 for SR. For the diagnosis of breast lesions, ROC curves showed a higher value for SR than for ES and ultrasound ($p < 0.05$) (Figure 1).

We combined the B-mode ultrasound and elastography (including ES and SR). When a lesion was diagnosed as malignant by two or more of traditional ultrasounds, ES, and SR, the diagnosis was confirmed as malignant; otherwise the lesion was categorized as benign. The sensitivity, specificity, and accuracy for the combined use of ultrasound and elastography were 81.2%, 91.6%, and 87%, respectively, while the Az value was 0.913. ROC curves yielded higher value for the combination of B-mode ultrasound and elastography, used for the diagnosis of breast lesions ($p < 0.05$) (Figure 2).

Out of the 92 lesions classified as BI-RADS category 4 by conventional ultrasounds, 71 were found to be malignant and 21 were benign. Among these 92 BI-RADS 4 breast lesions, 25 lesions were characterized as benign owing to their elasticity performance, out of which 18 were proved to be benign. The elastography diagnostic sensitivity, specificity, and accuracy were 90.1%, 85.7%, and 89.1%, respectively (Table 2).

Conventional ultrasound combined with the elastography diagnostic method revealed the following

Table 1. Pathologic Diagnosis of 431 Breast Lesions

Pathologic Diagnosis	No. of Lesions
Malignant lesions	276
Invasive ductal carcinoma nonscirrhous	244
Invasive lobular carcinoma	1
Invasive cribriform carcinoma	1
Ductal carcinoma in situ	13
Mucinous carcinoma	5
Intraductal papillary carcinoma	7
Tubular carcinoma	3
Secretory carcinoma	2
Benign lesions	155
Fibroadenoma	97
Papilloma	23
Atypical ductal hyperplasia	7
Chronic inflammation	14
Cystosarcoma phylloides	5
Lipoma	4
Lobular hyperplasia	4
Radial scar	1

Table 2. Elastography of BI-RADS 4 Breast Lesions

Elastography	Benign		Malignant	
	No. of lesions	%	No. of lesions	%
Benign	18	85.7	7	9.9
Malignant	3	14.3	64	90.1
Total	21		71	

Table 3. Size of the Lesions Diagnosed by Conventional Ultrasound Combined with Elastography

Group	I	II	III	IV	V
Sensitivity (%)	85.7	92.60	83.9	77.8	75
Specificity (%)	76.90	86.40	75	85.7	76.9
Accuracy (%)	80.00	90.1	80.6	79.4	76.2

values for sensitivity, specificity, and accuracy: group I: 85.7% (12/14), 76.9% (20/26), and 80.0% (32/40); group II: 92.6% (112/121), 86.4% (70/81), and 90.1% (182/202); group III: 83.0% (78/94), 75.0% (30/40), and 80.6% (108/134); group IV: 77.8% (21/27), 85.7% (6/7), and 79.4% (27/34); group V: 75.0% (6/8), 76.9% (10/13), and 76.2% (16/21); respectively (Table 3).

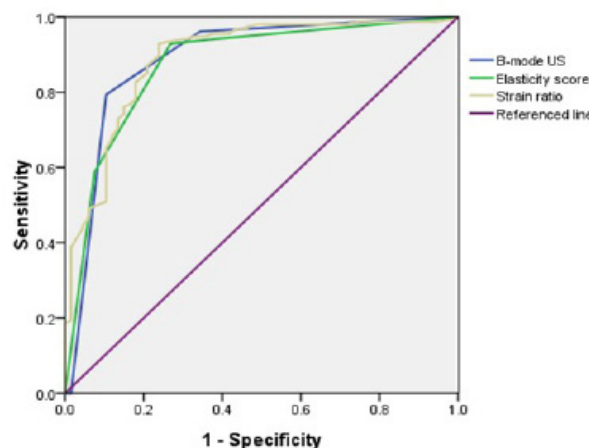


Figure 1. Receiver-operating Characteristic (ROC) Curves for B-mode (US), Elasticity Score (ES) and Strain Ratio (SR). The Areas Under the ROC Curves Differed Significantly between ES (0.875) and both B-mode ultrasound (0.889) and combination (0.913). p -values were less than 0.05.

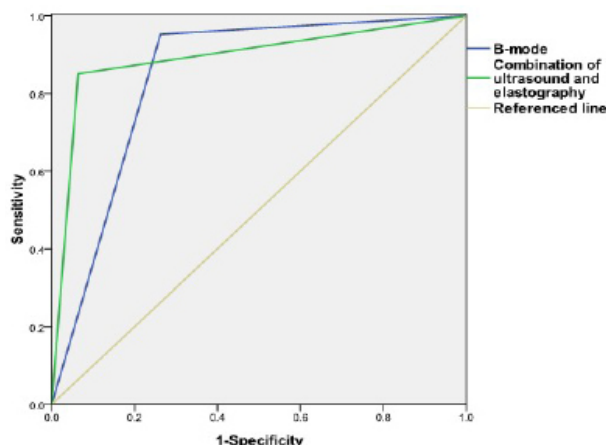


Figure 2. Receiver-operating Characteristic (ROC) Curves for B-mode Ultrasound. Combination of ultrasound and elastography. The areas under ROC curves differed significantly for both B-mode ultrasound (0.889) and combination (0.913). p -values were less than 0.05

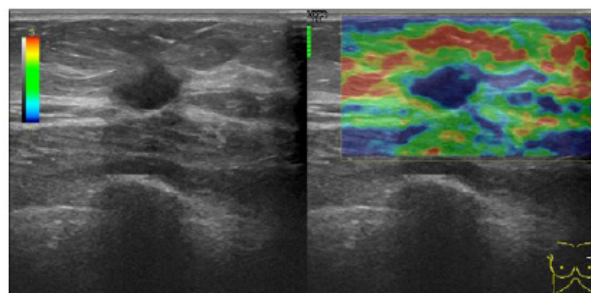


Figure 3. Invasive Ductal Carcinoma: 49-year-old women. On elasticity image, the lesion and the surrounding tissue were colored blue. On conventional B-mode US the hypoechoic lesion was classified BI-RADS 5, diameter 12mm \times 10mm

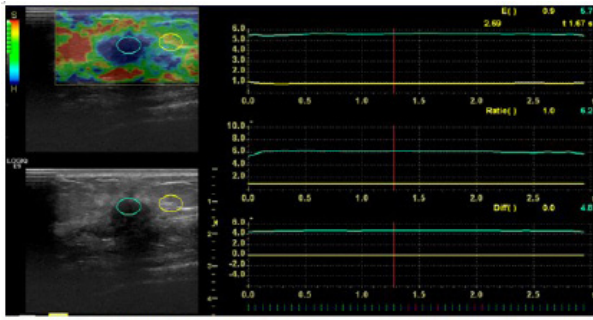


Figure 4. Invasive Ductal Carcinoma, with Elasticity Score of 5: 40-year-old women. On elasticity image the lesion and surrounding tissue were covered with blue. The strain ratio was 6.2. On conventional BI-RADS image, lesion was classified as BI-RADS 5. Diameter of the lesion 10mm × 7mm

Discussion

The elasticity pattern may reflect the histology of a tumor. Most malignant breast lesions are characterized by dense interstitial fibrosis; the cancer cells in the fibrous stroma infiltrate the lesion caused by nearby construction activity, thus reducing adhesion and decreasing elasticity. Benign lesions, such as fibroadenomas show hyperplasia of the glandular epithelial cells and the stromal cells, which are rich in mucopolysaccharides, therefore imparting a relatively loose texture (Zhang et al., 2014). Our results are in agreement with the observations made by Krouskop et al. (1998), which showed that the levels of elastic stiffness varied with different breast tissues; the invasive carcinoma showed the lowest elasticity, followed by noninvasive carcinoma, fibrous tissue in the breast, normal glandular breast tissue, and breast fat tissue. Elastography involves the use of the elastic properties of malignant or benign lesions in relation to the normal glands; this technique shows the potential to differentiate benign and malignant breast lesions, thus providing a new basis for their diagnosis (Kumm et al., 2010; Regin et al., 2010). The present findings revealed that a higher elasticity proportion was more likely to be found in benign lesions. Other studies have emphasized that an inelastic pattern occurs significantly more often in malignant lesions than in benign lesions. In addition, it was reported that an elastic appearance could not be detected in malignant tumors (Itoh et al., 2006; Cho et al., 2008.). However, Zhi et al. (2007) found an overlap in elasticity between benign and malignant lesions. 10% of malignant lesions showed elastic behavior and were misdiagnosed, a proportion similar to that in the present study.

Elasticity score (ES) and strain ratio (SR) were the two types of elastography interpretation parameters analyzed in our study. While ES was useful in distinguishing benign lesions from malignant tumors, SR significantly differentiated between the two (Gong et al., 2011). The cut-off point value of the SR was found to be 4.15, which is comparable to the best reported SR cut-off points of 2.24 to 2.45 (Cho et al., 2010; Thomas et al., 2010). We used ROC curves to compare the diagnostic performance of ultrasound, ES, and SR. Strain ratio diagnostic performance was estimated to be better than that of elasticity score and ultrasound. SR was, therefore,

more efficient in quantifying tissue stiffness (Figure 3).

This study indicated that using elastography alone to make a diagnosis does not provide a competitive advantage. However, the combination of B-mode ultrasound and elastography can effectively improve the diagnostic performance with the conventional ultrasound needed to identify the lesions first (Lee and Meier-Metitinger et al., 2011; Cho et al., 2012). This result was further supported by the higher values of specificity and accuracy obtained when conventional ultrasound and elastography were combined, than when these methods were used individually, and this result is correlated with (Parajuly et al., 2010).

In our opinion, the clinical value of elastography depends on its ability to minimize false-negative-results (Farrokh et al., 2013). Based on the categories described by BI-RADS, the breast lesions under investigation were classified as: category 3 or lower, probably belonging to benign lesions; category 4, characteristic of suspicious abnormality (from 3 percent to 94 percent probability of cancer); and category 5, highly suggestive of malignancy. Needle biopsy can provide a cytologic of histologic diagnosis. However, some BI-RADS 4 lesions histologically proved to be benign lesions. Our study showed that out of 21 benign lesions, the elastic performance of 18 lesions were found to be benign. Combined use of these diagnostic standard would have reduced the biopsy rate (18/91) in our study. A larger prospective study with these standard could place subjects into short-term follow-up with reasonable safety and low risk for non-assessment of malignancy (Kumm et al., 2010).

The study was the first to examine the usefulness of elastography for diagnosis of patients with different sized breast lesions. The size of lesions limits the diagnostic performance of B-mode ultrasound. Elastography provides more evidence to diagnosing small breast lesions as shown by the higher specificity and accuracy values in group II (10mm < lesion diameter ≤ 20mm) as compared to other groups. (Figure 4) When the tumor volume is small, the difference in hardness between the benign lesions and normal breast tissue is less, due to which the elastic strain is also small; hence, the elasticity image is green (Fu et al., 2011). In case of small malignant lesions, necrosis does not appear in the internal component, and the hardness of the lesions is relatively homogeneous; consequently, the elasticity image shows blue. Therefore, the false negative rate is lower using elastography (Engelken et al., 2012). On analyzing the misdiagnosed cases on elastogram, we found that calcification, fibrosis, and necrosis within the lesion were important factors that could alter the texture of lesions and cause misdiagnosis. When size of the breast lesions is large, these factors may be present within the area resulting in uneven hardness in the lesions. In such cases, the elasticity images are manifested in blue and green, but an elasticity score of 2-5 points may lead to false negative results.

Our study had several shortcomings. First, meticulous quantification of tissue stiffness such as shear wave elastography or tumor vascularity by using spectral analysis was not performed. We only carried out a

qualitative analysis, using the elasticity score and strain ratio. Second, we did not assess inter-observer or intra-observer variability with regard to performing and interpreting elastography data. This issue may prove challenging, especially in a practice setting with different levels of experience. Finally, performance of elastography was not always straightforward because it depended on multiple factors such as breast size, density, depth, and proximity of a lesion to the nipple/areola, making it difficult to achieve a consistent optimal image quality in all cases.

In conclusion, ultrasound elastography is a valuable tool for early diagnosis of small breast lesions. For tumors with coarse calcification, fibrosis or necrosis, the results may not be reliable. Our results were concordant with the findings of other researchers that elastography combined with conventional ultrasound may potentially increase our level of confidence regarding the final assessment of the breast lesion and help avoid biopsy recommendations for lesions, which may have a very high probability of being benign.

Acknowledgements

This research is supported by the Science and Technology Project of Anticancer, Tianjin, China (12ZCDZSY16000), Changjiang Scholars and Innovative Research Team in University in China (IRT1076), Tianjin 300060, China for financial support.

References

Adamietz BR, Meier-Meiting M, Fasching P, et al (2011). New diagnostic criteria in real-time elastography for the assessment of breast lesions. *Ultraschall Med*, **32**, 67-73.

American College of Radiology (2003). Breast Imaging Reporting and Data System (Bi-Rads) Ultrasound. Reston, Va: American College of Radiology.

Brenner H, Gondos A, Arndt V (2007). Recent major progress in long-term cancer patient survival disclosed by modeled period analysis. *J Clin Oncol*, **25**, 3274-80.

Chiou SY, Chou YH, Chiou HJ, et al (2006). Sonographic features of nonpalpable breast cancer: a study based on ultrasound-guided wire-localized surgical biopsies. *Ultrasound Med Biol*, **32**, 1299-306.

Cho N, Moon WK, Park JS, et al (2008). Nonpalpable breast masses: evaluation by US elastography. *Korean J Radiol*, **9**, 111-8.

Cho N, Moon WK, Kim HY, et al (2010). Sonoelastographic strain index for differentiation of benign and malignant nonpalpable breast masses. *J Ultrasound Med*, **29**, 1-7.

Cho N, Jang MJ, Lyou CY, et al (2012). Distinguishing benign from malignant masses at breast US: Combined US elastography and color Doppler US-influence on radiologist accuracy. *Radiology*, **262**, 80-90.

Engelken FJ, Sack I, Klatt D, et al (2012). Evaluation of tomosynthesis elastography in a breast-mimicking phantom. *Eur J Radiol*, **81**, 2169-73.

Farrok A, Wojcinski S, Degenhardt F (2013). Evaluation of real-time tissue sono-elastography in the assessment of 214 breast lesions: limitations of this method resulting from different histologic subtypes, tumor size and tumor localization. *Ultrasound Med Bio*, **39**, 2264-71.

Fu LN, Wang Y, Wang Y, et al (2011). Value of ultrasound elastography in detecting small breast tumors. *Chin Med J*, **124**, 2384-6.

Gong X, Xu QH, Xu ZL, et al (2011). Real-time elastography for the differentiation of benign and malignant breast lesions: a meta-analysis. *Breast Cancer Res Treat*, **130**, 11-8.

Itoh A, Ueno E, Tohno E, et al (2006). Breast disease: clinical application of US elastography for diagnosis. *Radiology*, **239**, 341-50.

Jackson VP (1995). The current role of ultrasonography in breast imaging. *Radiol Clin North Am*, **33**, 1161-70.

Krouskop TA, Wheller TM, Kallel F, et al (1998). Elastic moduli of breast and prostate tissue under compression. *Ultrason Imaging*, **20**, 260-74.

Kumm TR, Szabunio MM (2010). Elastography for the characterization of breast lesions: initial clinical experience. *Cancer Control*, **17**, 156-61.

Lee JH, Kim SH, Kang BJ, et al (2011). Role and clinical usefulness of elastography in small masses. *Acad Radiol*, **18**, 74-80.

Leung DY, Leung AY, Chi I (2012). Breast and colorectal cancer screening and associated correlates among Chinese older women. *Asian Pac J Cancer Prev*, **13**, 283-7.

Liu J, Liu P-F, Li J-N, et al (2014). Analysis of mammographic breast density in a group of screening Chinese women and breast cancer patients. *Asian Pac J Cancer Prev*, **15**, 6411-4.

Meier-Meiting M, Haberle L, Fasching PA, et al (2011). Assessment of breast cancer tumor size using six different methods. *Eur Radiol*, **21**, 1180-7.

Moon WK, Chang SC, Huang CS, et al (2011). Breast tumor classification using fuzzy clustering for breast elastography. *Ultrasound Med Bio*, **37**, 700-8.

Parajuly SS, Lan PY, Yan L, et al (2010). Breast elastography: a hospital-based preliminary study in China. *Asian Pac J Cancer Prev*, **11**, 809-14.

Rahbar G, Sie AC, Hansen GC, et al (1999). Benign versus malignant solid breast masses: US differentiation. *Radiology*, **213**, 889-94.

Regini E, Bagnera S, Tota D, et al (2010). Role of sonoelastography in characterising breast nodules. Preliminary experience with 120 lesions. *Radiol Med*, **115**, 551-62.

Thomas A, Degenhardt F, Farrok A, et al (2010). Significant differentiation of focal breast lesions calculation of strain ratio in breast sonoelastography. *Acad Radiol*, **17**, 558-63.

Warner E, Plewes DB, Shumak RS, et al (2001). Comparison of breast magnetic resonance imaging, mammography, and ultrasound for surveillance of women at high risk for hereditary breast cancer. *J Clin Oncol*, **19**, 3524-31.

Zhang L, Liu YJ, Jiang SQ, et al (2014). Ultrasound utility for predicting biological behavior of invasive ductal breast cancers. *Asian Pac J Cancer Prev*, **15**, 8057-62.

Zhi H, Ou B, Luo BM, et al (2007). Comparison of ultrasound elastography, mammography, and sonography in the diagnosis of solid breast lesions. *J Ultrasound Med*, **26**, 807-15.