

## RESEARCH ARTICLE

# Malignant Transformation Rate and P53, and P16 Expression in Teratomatous Skin of Ovarian Mature Cystic Teratoma

Hai-Li Zhu<sup>1,2&</sup>, Zhen-Ning Zou<sup>1,2&</sup>, Pei-Xin Lin<sup>1,2</sup>, Wen-Xia Li<sup>1,2</sup>, Ye-En Huang<sup>1,2</sup>, Xiao-Xin Shi<sup>1,2</sup>, Hong Shen<sup>1,2\*</sup>

## Abstract

**Objective:** To investigate the incidence of malignant transformation and P53 and P16 expression in teratomatous skin of ovarian mature cystic teratoma. **Materials and Methods:** Data on ovarian teratoma specimens in nearly 10 years were reviewed. P53 and P16 expression were detected by immunohistochemistry in 25 cases of teratomatous skin of ovarian mature cystic teratoma, 20 cases of squamous cell carcinoma and 2 cases of squamous cell carcinoma originated from teratomatous skin. **Results:** Of 1913 cases of ovarian mature cystic teratoma in nearly 10 years, only two cases of squamous cell carcinoma were found in teratomatous skin, with malignant transformation rate of 0.1045%. P53 expression was detected in 2 cases squamous cell carcinoma originated from teratomatous skin and P16 overexpression in one. There were no expressions of P53 and P16 in 25 cases of teratomatous skin of ovarian mature cystic teratoma. Of 20 cases of squamous cell carcinoma P53 overexpression (positive rate of 55%) was detected in 11 cases, P16 overexpression (positive rate of 35%) in 7 cases. The positive rates of P53 and P16 expression in squamous cell carcinomas were significantly higher than that in the teratomatous skins ( $p < 0.001$ ,  $p = 0.002$ ). **Conclusions:** There was low risk of malignant transformation in teratomatous skin of ovarian mature cystic teratoma which can be explained by lower P53 and P16 expression in teratomas than that in squamous cell carcinoma.

**Keywords:** Teratoma-malignant transformation- p53-p16- immunohistochemistry- squamous cell carcinoma

*Asian Pac J Cancer Prev*, 16 (3), 1165-1168

## Introduction

Teratoma is one of embryonal tumors, derived from the ectoderm, mesoderm and endoderm. The tumor often occurs in the gonads and the body axis such as sites near the body axis, including ovaries and testicles, as well as mediastinum, retroperitoneum, mesenterium, sacrococcygeal region, neck, and pineal gland etc. About 80% teratomas were benign. Benign teratoma called mature teratoma. It is also known as mature cystic teratoma because most of them are cystic. Mature cystic teratoma, (95% of ovarian teratomas), is the most common benign ovarian tumors, accounting for about 58% of benign ovarian tumors (Dos et al., 2007). The stratified squamous epithelium, sebaceous glands, hair follicles and hair etc can be seen in the skin-like tissues of ovarian teratoma (referred to teratomatous skin of ovarian teratoma), which are similar to normal skin tissue. The teratomatous skin may occur malignant transformation. However, the incidence of malignant transformation has not been reported in the literature. Previous studies showed that abnormal P53 and P16 expression in a variety of tumors including ovarian cancers and squamous cell

carcinoma of the skin. It was reported that abnormal P53 and P16 expression can be found in teratomatous skin with malignant transformation. This study was conducted to detect and analyze the P53 and P16 expression in the teratomatous skin of ovarian mature teratoma, squamous cell carcinoma of the skin and squamous cell carcinoma originated from the teratomatous skin.

## Materials and Methods

### Clinical specimens Information

The data on ovarian teratoma cases from January 2004 to December 2013 in Nanfang Hospital were collected and statistically analyzed. All cases were diagnosed by two clinical pathologists. Specimens of 25 cases of teratomas were from patients underwent surgical resection from March 2013 to January 2014 in Nanfang Hospital, Southern Medical University, aged 17 to 48 years, mean 30 years. Other specimens included 20 cases of squamous cell carcinoma and 2 cases of squamous cell carcinoma originated from the teratomatous skin.

### Main reagents

<sup>1</sup>Department of Pathology, Nanfang Hospital, Southern Medical University, <sup>2</sup>Department of Pathology, School of Basic Medical Sciences, Southern Medical University, Guangzhou, China \*Equal contributors \*For correspondence: shenhong2010166@163.com

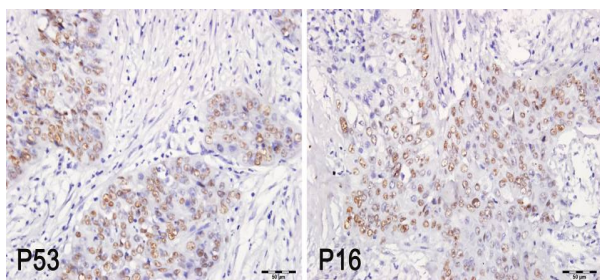
P16 mouse anti-human monoclonal antibody (purchased from Guangzhou An Biping (LBP) Pharmaceutical Co., Ltd.); P53 mouse anti-human monoclonal antibody, Universal PV9000 immunohistochemistry kit, repair solution of citric acid, phosphate buffer and DAB chromogenic reagent as well as antibody dilution were purchased from Beijing Zhongshan Golden Bridge biotechnology Co., Ltd.

#### Immunohistochemistry

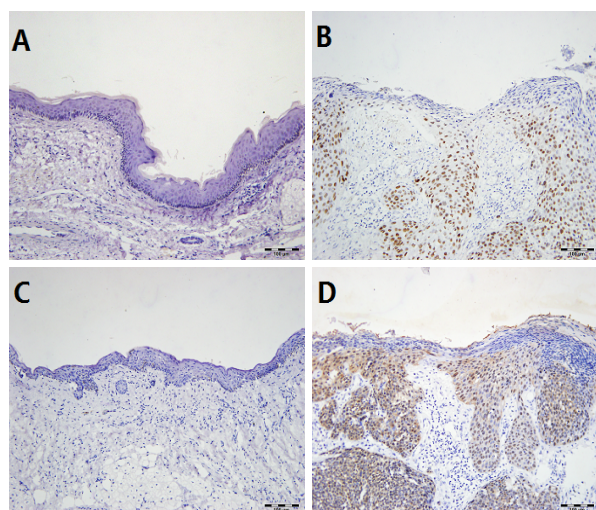
A 3  $\mu$ m serial section of paraffin-embedded tissue was performed continuously. The section was attached to a clean slide with coated APES, and then placed in an oven with 65°C for 3h to 5h. P53 and P16 immunohistochemical

**Table 1. Expression of P53 and P16 in the Teratomatous Skin and Cutaneous Squamous Cell Carcinoma**

Groups	P53			P16		
	-	+	P	-	+	P
Teratomatous skin (n= 25)	25	0	<0.001	25	0	0.002
Squamous cell carcinoma of skin(n= 20)	9	11		13	7	



**Figure 1. Expression of P53 and P16 in Squamous Cell Carcinoma of Teratomas (Obj. 20x)**



**Figure 2. Expression of P53 and P16 in the Teratomatous Skin and Cutaneous Squamous Cell Carcinoma (Obj. 10x)** A: Negative expression of P53 in the teratomatous skin; B: Positive expression of P53 in the cutaneous squamous cell carcinoma ; C: Negative expression of P16 in the teratomatous skin ; D: Positive expression of P16 in the cutaneous squamous cell carcinoma

staining was performed. The specific steps referred to related literature (Li et al., 2011). Both dilution of P53 and P16 antibody was 1: 100. The known positive tissue was used as a positive control and PBS instead of primary antibody as a negative control. Any staining with suspicious results must be repeated.

#### Staining judgment

P53 protein overexpression criteria: P53 positive staining showed brown granules, located in the nucleus. P53 with  $\geq 10\%$  of tumor cells was determined positive (Oda et al., 2000). P16 protein expression criteria referred to reference (Hodges et al., 2002). The staining of normal skin keratinizing epithelium was served as a negative control.

#### Statistical Methods

Statistical analysis was used with SPSS 13.0 software. The positive rate of two independent samples was used to compare  $\chi^2$  test or Fish exact probability. The comparison between the two sample mean was used with independent sample t test;  $P < 0.05$  was considered statistically significant.

## Results

i) The malignant transformation rate and P53 and P16 expressions in squamous cell carcinoma originated from the teratomatous skin

Of 1913 cases of ovarian mature cystic teratoma in nearly 10 years, only two cases of squamous cell carcinoma were found in teratomatous skin, with malignant transformation rate of 0.1045%. Immunohistochemistry results showed that P53 expression was detected in two and P16 overexpression in one (Figure 1).

ii) P53, and P16 protein expressions in the teratomatous skin and squamous cell carcinomas of the skin

There were no expressions of P53 and P16 in 25 cases of ovarian mature cystic teratoma. Of 20 cases of squamous cell carcinoma, P53 overexpression (positive rate of 55%) in 11 cases, P16 overexpression (positive rate of 35%) in 7 cases (Figure 2). The positive rates of P53 and P16 expressions in squamous cell carcinomas were significantly higher than that in the teratomatous skins ( $P < 0.001$ ,  $P = 0.002$ , Table 1).

## Discussion

Mature cystic teratoma is the most common germ cell tumor, accounting for approximately 10% to 20% of all ovarian tumors (Ayhan et al., 2000). Most teratomas are common in women of reproductive age (Ulbright et al., 2005). Mature cystic teratoma consists of three germ layers (Outwater et al., 2001; Rha et al., 2004). The majority of patients with no clinical symptoms are diagnosed with this disease during pelvic examination or imaging studies (Peterson et al., 1957). About 2% of patients may present clinical symptoms and complications, such as abdominal pain, caused by torsion, rupture and infection, and abdominal distention caused by enlarging mass (Hackethal et al., 2008).

Malignant transformation is the most serious complications of mature teratomas. Once the complications occurs, patients often has poor prognosis (Chang et al., 2011; Park et al., 2008). Any component of teratoma can turn malignant with the incidence rate of approximately 1% to 2% (Hirakawa et al., 1989). The most common malignant transformation originates from ectoderm and the common histological types are squamous cell carcinoma (Stamp et al., 1983) and adenocarcinoma (Muramatsu et al., 2011). Other types contain small cell lung cancer (Ikota et al., 2012), sarcoma cancer (Cabibi et al., 2006), chondrosarcoma (Climie et al., 1968), sebaceous carcinoma (Ribeiro-Silva et al., 2003), angiosarcoma (Takahashi et al., 2012), clear cell carcinoma (Guney et al., 2009), melanoma, and carcinoid tumors (Hyun et al., 2013) etc. There are two hypotheses about malignant transformation of squamous epithelium. The first hypothesis is that the majority of squamous cell carcinomas are originated from squamous metaplasia of airway epithelium (Fox et al., 1965). While another hypothesis suggests that the malignant transformation stems from the epidermis. This theory is supported by a report that Bowen's disease has been found in teratoma (Klionsky et al., 1972). The latter indicates that the skin in the teratoma can turn to squamous cell carcinoma, but the probability and the mechanisms of malignant transformation have not been elucidated.

Malignant transformation is a multi-stage process, involving many genetic and epigenetic change, mainly related to three types of gene (Fearon et al., 1990): (a) Oncogene, activation in dominant form; (b) Tumor suppressor gene, inactivation in recessive manner; (c) DNA repair genes, which can cause genetic instability by inactivation. These types of changes can affect cell function, forming the main characteristics of tumor cells: self-sufficiency in growth signals, not sensitive to anti-growth signals, apoptosis avoidance, limitless replicative potential, sustained angiogenesis and tissue invasion and metastasis (Hanahan et al., 2000). The etiological actors causing malignant transformation remain unknown. Few relevant researches have been published. Previous reports have demonstrated that complex chromosome aberrations (Yoshioka et al., 1998), alterations in the P53 gene (Fujii et al., 1995) and expression of cyclooxygenase-2 play important roles in the malignant transformation (Sumi et al., 2001). P53 is a tumor suppressor gene that control cells enter to S phase, inhibit cell growth and induce apoptosis. Alteration of the P53 gene is one of the most common genomic alterations in human malignant tumors, and it's abnormal expression has been found in many malignant tumors (Weber et al., 2002). Mutant P53 protein which can be detected as overexpressed on immunohistochemistry has a much longer half-life than the wild-type protein. Previous studies have showed overexpression of the P53 protein was detected in 40-55% of epithelial ovarian carcinomas (Palazzo et al., 2000) and P53 gene mutations in 38-57% (Kappes et al., 1995). In this study, Overexpression of P53 protein was found in 2 cases of teratoma with malignant transformation, indicating that P53 gene may play a key role in malignant transformation. There was no mutant P53 protein in mature cystic teratoma

tissues by immunohistochemical study, suggesting it was not common event of malignant transformation of skin in mature cystic teratoma. P16 gene is located in 9p21, contains three exons, and encodes a protein about 16 KD. CDK4 binds to cyclin D and phosphorylates Rb, releasing E2F and stimulating G1/S phase transition. P16 acts as a negative regulator of cell proliferation by inhibiting CDK4/cyclin D activity, preventing Rb phosphorylation, and inducing G1 arrest (Sherr et al., 1993). The abnormal P16 expression correlates with tumor progression and a poor survival rate. In the present study, there was no expression of P16 protein in teratomous skins, while 7 cases of squamous cell carcinomas had expression. In addition, one teratoma with malignant transformation showed the expression of P16, indicating that there may be no have no obvious abnormalities in the P16-Rb pathways and the risk of squamous cell carcinoma originated from the teratomous skin is very low.

In this study, of 1913 cases of teratoma, only two cases presented squamous cell carcinoma, with malignant transformation rate of about 0.1%. In addition, there were no abnormal expressions of P53 and P16 in mature teratomous skin, while there was relatively higher positive rate in squamous cell carcinoma of skin. So, we believe that there is low risk of malignant transformation of teratoma. Lower expression rates of P53 and P16 may explain the reason.

## Acknowledgements

This study was supported by a grant from the National Natural Science Foundation of China (No. 81271729).

## References

- Ayhan A, Bukulmez O, Genc C, et al (2000). Mature cystic teratomas of the ovary: case series from one institution over 34 years. *Eur J Obstet Gynecol Reprod Biol*, **88**,153-7.
- Chang SD, Yen CF, Lo LM, et al (2011). Surgical intervention for maternal ovarian torsion in pregnancy. *Taiwan J Obstet Gynecol*, **50**, 458-62.
- Climie AR, Heath LP (1968). Malignant degeneration of benign cystic teratomas of the ovary. Review of the literature and report of a chondrosarcoma and carcinoid tumor. *Cancer*, **22**, 824-32.
- Cabibi D, Martorana A, Cappello F, et al (2006). Carcinosarcoma of monoclonal origin arising in a dermoid cyst of ovary: a case report. *BMC Cancer*, **1**, 46-47.
- Dos Santos L, Mok E, Iasonos A, et al (2007). Squamous cell carcinoma arising in mature cystic teratoma of the ovary: a case series and review of the literature. *Gynecol Oncol*, **105**, 321-4.
- Fearon ER, Vogelstein B (1990). A genetic model for colorectal tumorigenesis. *Cell*, **61**, 759-67.
- Guney N, Sayilgan T, Derin D, et al (2009). Primary carcinoid tumor arising in a mature cystic teratoma of the ovary: a case report. *Eur J Gynaecol Oncol*, **30**, 223-5.
- Fox H (1965). Bronchial carcinoma in an ovarian cystic teratoma (dermoid). *J Clin Pathol*, 1965, 18, 164-6.
- Fujii T, Oguni S, Kikuchi M, et al (1995). p53 mutation in carcinomas arising in ovarian cystic teratomas. *Pathol Int*, 1995, 45, 649-54.
- Hodges A, Smoller BR (2002). Immunohistochemical



- Comparison of P16 Expression in Actinic Keratoses and Squamous Cell Carcinomas of the Skin. *Mod Pathol*, **15**, 1121-5.
- Hackethal A, Brueggmann D, Bohlmann MK, et al (2008). Squamous-cell carcinoma in mature cystic teratoma of the ovary: systematic review and analysis of published data. *Lancet Oncology*, **9**, 1173-80.
- Hirakawa T, Tsuneyoshi M, Enjoji M (1989). Squamous cell carcinoma arising in mature cystic teratoma of the ovary. *Am J Surg Pathol*, **13**, 397-405.
- Hyun HS, Mun ST (2013). Primary malignant melanoma arising in a cystic teratoma. *Obstet Gynecol Sci*, **56**, 201-4.
- Hanahan D, Weinberg RA (2000). The hallmarks of cancer. *Cell*, **100**, 57-70.
- Ikota H, Kaneko K, Takahashi S, et al (2012). Malignant transformation of ovarian mature cystic teratoma with a predominant pulmonary type small cell carcinoma component. *Pathol Int*, **62**, 276-80.
- Klionsky BL, Nickens OJ, Amortegui AJ (1972). Squamous cell carcinoma in situ arising in adult cystic teratoma of the ovary. *Arch. Pathol*, **93**, 161-3.
- Kappes S, Milde-Langosch K, Kressin P, et al (1995). p53 mutations in ovarian tumors, detected by temperature-gradient gel electrophoresis, direct sequencing and immunohistochemistry. *Int J Cancer*, **64**, 52-9.
- Li YM, Wan LY, Shen H (2011). Wood grain redyeing effects on quantitative analysis of immunohistochemical staining density. *J Tropical Med*, **11**, 553-5.
- Muramatsu T, Nishii T, Ohmori K, et al (2011). Mature cystic teratoma with malignant transformation to adenocarcinoma. *Ann Thorac Surg*, **91**, 1971-3.
- Oda Y, Sakamoto A, Saito T, et al (2000). Molecular abnormalities of p53, MDM2, and H-ras in synovial sarcoma. *Mod Pathol*, **13**, 994-1004.
- Outwater EK, Siegelman ES, Hunt JL (2001). Ovarian teratomas, tumor types and imaging characteristics. *Radiographics*, **21**, 475-490.
- Peterson WF (1957). Malignant degeneration of benign cystic teratomas of the ovary: a collective review of the literature. *Obstet Gynecol Surv*, **12**, 793-830.
- Park JY, Kim DY, Kim JH, et al (2008). Malignant transformation of mature cystic teratoma of the ovary: experience at a single institution. *Eur J Obstet Gynecol Reprod Biol*, **141**, 173-8.
- Palazzo JP, Monzon F, Burke M, et al (2000). Overexpression of p21WAF1/CIP1 and MDM2 characterizes serous borderline ovarian tumors. *Hum Pathol*, **31**, 698-704.
- Ribeiro-Silva A, Chang D, Bisson FW, et al (2003). Clinicopathological and immunohistochemical features of a sebaceous carcinoma arising within a benign dermoid cyst of the ovary. *Virchows Arch*, **443**, 574-8.
- Rha SE, Byun JY, Jung SE, et al (2004). Atypical CT and MRI manifestations of mature ovarian cystic teratomas. *AJR Am J Roentgenol*, **183**, 743-50.
- Stamp GW, McConnell EM (1983). Malignancy arising in cystic ovarian teratomas. A report of 24 cases. *Br J Obstet Gynaecol*, **90**, 671-5.
- Sumi T, Ishiko O, Yoshida H, et al (2001). Expression of cyclooxygenase-2 in ovarian mature cystic teratomas with malignant transformation. *Int J Mol Med*, **8**, 495-8.
- Sherr CJ (1993). Mammalian G1 cyclins. *Cell*, **73**, 1059-65.
- Takahashi H, Chaopotong P, Kajita S, et al (2012). Mixed angiosarcoma, clear cell adenocarcinoma and mature teratoma elements in an ovarian tumor: A case report and literature review. *Pathol Int*, **62**, 538-42.
- Ulbricht TM (2005). Germ cell tumors of the gonads: a selective review emphasizing problems in differential diagnosis, newly appreciated, and controversial issues. *Mod Pathol*, **18**, 61-79.
- Weber A, Bellmann U, Bootz F (2002). INK4a-ARF alterations and p53 mutations in primary and consecutive squamous cell carcinoma of the head and neck. *Virchows Arch*, **441**, 133-142.
- Yoshioka T, Tanaka T (1998). Immunohistochemical and molecular studies on malignant transformation in mature cystic teratoma of the ovary. *J Obstet Gynaecol Res*, **24**, 83-90.