

RESEARCH ARTICLE

Organ-sparing Surgery in Treating Patients with Liposarcoma of the Spermatic Cord: Institutional Experience and Pooled Analysis

Ming-Xin Cao^{1&}, Jie Chen^{2&}, Jun-Long Zhang¹, Xin Wei³, Yue-You Liang^{1*}

Abstract

Background: Liposarcoma of the spermatic cord is rare and frequently misdiagnosed. The standard therapeutic approach has been radical inguinal orchiectomy with wide local resection of surrounding soft tissues. The current trend of organ preservation in the treatment of several cancers has started to evolve. Herein we present our testis-sparing surgery experience in the treatment of spermatic cord liposarcoma and a pooled analysis on this topic. **Materials and Methods:** Clinical information from patient receiving organ-sparing surgery was described. Clinical studies evaluating this issue were identified by using a predefined search strategy, e.g., Pubmed database with no restriction on date of published papers. The literature search used the following terms: epidemiology, surgery, chemotherapy, radiotherapy, testis sparing surgery, spermatic cord sarcomas/liposarcomas. **Results:** Patient received a complete excision of the lesion, preserving the spermatic cord and the testis. The final pathological report showed a well differentiated liposarcoma with negative surgical margins and no signs of local invasion. After 2-year of follow-up, there was no evidence of local recurrence. Since the first case reported in 1952, a total of about 200 well-documented spermatic cord liposarcoma cases have been published in English literature. Among these patients, only three instances were reported to have received an organ-sparing surgery in the treatment of spermatic cord liposarcoma. **Conclusions:** Radical inguinal orchiectomy and resection of the tumor with a negative microscopic margin is the recommended treatment for liposarcoma of the spermatic cord. But for small, especially well-differentiated, lesions, testis-sparing surgery might be a good option if an adequate negative surgical margin is assured.

Keywords: Liposarcoma - orchiectomy - organ - sparing surgery - spermatic cord

Asian Pac J Cancer Prev, 16 (8), 3419-3423

Introduction

Liposarcoma presenting as a paratesticular mass with spermatic cord involvement is rare and frequently misdiagnosed (Coleman et al., 2003). Investigation of spermatic cord liposarcoma has been difficult because of its rarity. The current standard therapeutic approach for spermatic cord tumor has been radical inguinal orchiectomy with wide local resection of surrounding soft tissues (Rodriguez et al., 2014). Due to the improvement in oncologic outcome and growing attention devoted to functional issues of cancer survivorship, the current trend of organ preservation in the treatment of several cancers has started to evolve (Giannarini et al., 2010). However, to the best of our knowledge, only three instances of organ-sparing surgery in the treatment of spermatic cord liposarcoma have been reported (Manzia et al., 2010; Hsu et al., 2012; Peralta et al., 2013). In order to increase the experience in the treatment of spermatic cord liposarcoma, the present study reported an instance receiving organ-sparing surgery and reviewed related literature.

Materials and Methods

Case medical presentation

An 18-year-old man was admitted, in December 2012, to the Urology Department of the First Affiliated Hospital of Sun Yat-sen University, with symptoms of a mass located in his left hemiscrotum with 1 year of evolution. It presented as a painless soft tissue mass, with well-defined limits, showing a slow growth. A physical examination demonstrated a left intrascrotal swelling, around the left spermatic cord. The mass was oval-shaped, about 4 cm in maximum diameter, soft in consistency, with no pain and negative transillumination. It was movable with the left spermatic cord and the left testis was perceived distinctively from the mass with normal size and consistency.

An ultrasound was performed, revealing a 4.3 × 2.3 cm mass, with regular outer margins and a solid, heterogeneous echotexture with internal areas that were more echogenic than the adjacent testis (Figure1a). The mass was connected to the left spermatic cord. Blood

¹Department of Urology, the First Affiliated Hospital of Sun Yat-sen University, ²Department of Urology, the First Affiliated Hospital of Jinan University, ³Department of Pathology, the First Affiliated Hospital of Sun Yat-sen University, Guangzhou, China [&]Equal contributors *For correspondence: shutongxuan@126.com

vessels within the mass were seen on color Doppler (Figure 1b). This result suggested an adipose tissue mass, but a malignant neoplasm could not be excluded.

Literature search and data extraction

A comprehensive PubMed search was conducted. The following search terms were used: epidemiology , surgery , chemotherapy , radiotherapy , testis sparing surgery, spermatic cord sarcomas/liposarcomas. No restrictions were applied to the date of publication; however, this search was limited to papers in English language. Reports describing spermatic cord liposarcoma

Table 1. Characteristics and Treatment Details for Patients with Liposarcoma of the Spermatic Cord

	N	%
Age (years)	18-75	NA
Presentation		
Primary	168	86
Recurrent	32	14
Tumor location		
Left	118	59
Right	82	41
Tumor size, median (cm)	9 (0.4-20)	NA
Histology		
Well-differentiated liposarcoma	107	53
De-differentiated liposarcoma	67	34
myxoid liposarcoma	26	13
Radiotherapy or Chemotherapy		
Yes	80	40
No	120	60
Local recurrence		
Yes	44	22
No	156	78
Follow-up Duration (months)	6-144	NA
Status at last follow-up		
Alive without disease	144	72
Alive with disease	40	20
Dead without disease	6	3
Dead with disease	10	5

cases were considered. Furthermore, reference lists of included studies were hand-searched to identify relevant missing publications. Full text articles of eligible abstracts were reviewed. Information about patient demographics, histopathology (i.e. tumor size, histologic subtype), clinical features (i.e. presenting sign/symptoms, involved sides), treatment and follow-up were recorded for analysis.

Results

Clinical Treatment and Follow-up

Our patient agreed on scrotal exploration. A left inguinal approach was performed, with high clamping of the spermatic cord and a complete excision of the lesion (Figure 1), preserving the spermatic cord and the testis. The perioperative pathology analysis revealed a well-differentiated liposarcoma of the spermatic cord. The patient was advised to undergo radical orchiectomy with high cord ligation. However, he refused surgery. We then chose to preserve the ipsilateral testis (organ-sparing surgery). Postoperatively, the final pathology result was well differentiated liposarcoma of the spermatic cord with negative surgical margins and no signs of local invasion (Figure 2). After 2 years of follow-up, there was no evidence of local recurrence clinically. Scrotal ultrasound revealed no evidence of local recurrence or lymphadenopathy.

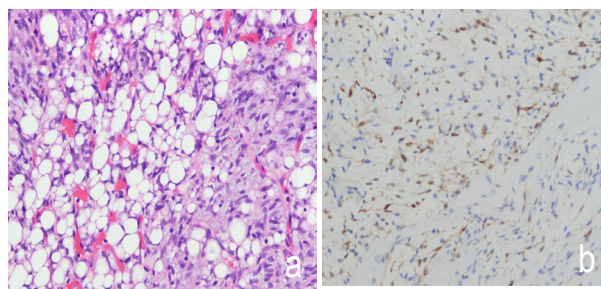


Figure 2. Well-defined Tumour. No invasion of the surrounding tissues. The lesion was completely excised, preserving the left spermatic cord and testis

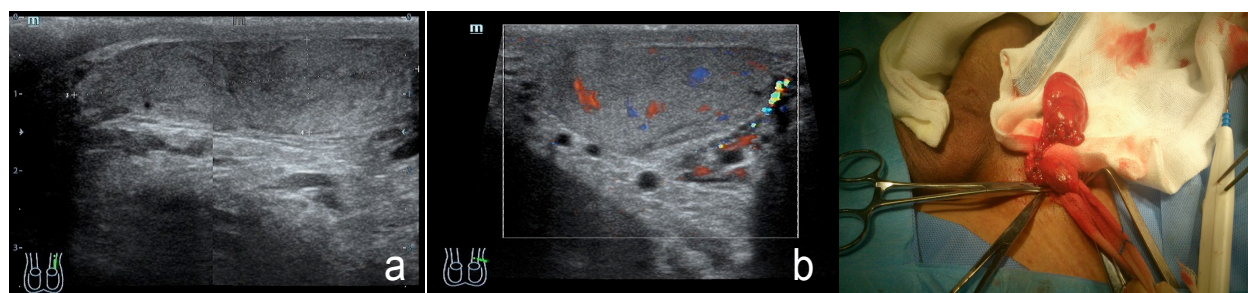


Figure 1. A) Sagittal Sonogram of the Left Hemiscrotum Showing a 4.9x1.2cm, Oval-shaped Mass (Arrows) with Regular Margins Located Superior to the Left testis and Separate from it. The lesion is solid and heterogeneous, with internal areas of hyperechogenicity. B) Color Doppler transverse sonogram of the palpable mass shows intralesional vascularity

Table 2. Clinical Findings and Histologic subtype of Patients with Liposarcoma of the Spermatic Cord who Received Organ-sparing Surgery

Case	Age (years)	Histologic Subtype	Tumor Size (cm)	Side	Follow-up Times (months)	Disease Outcome
1	53	well-differentiated	NA	Left	18	disease free
2	52	well-differentiated	0.4	Left	36	disease free
3	43	well-differentiated	5	Right	12	disease free

Pooled analysis of all published cases

Since the first case reported in 1952, a total of about 200 well-documented spermatic cord liposarcoma cases have been published in English literature. Demographic and clinical features of all cases are summarized in Table 1. Among these cases, only three instances were reported to have received an organ-sparing surgery in the treatment of spermatic cord liposarcoma (Table 2).

Discussion

Although cancer is a common disease in China (Ji et al., 2014; Cui et al., 2014; Huang et al., 2014), spermatic cord tumors are rare and the overall incidence was approximately 0.3 cases per million from 1973 to 2007 in the United States (Rodriguez et al., 2014). The most common neoplasms are benign and most of these are represented by lipomas (Guttilla et al., 2013). The most common malignant tumors are represented by sarcomas because of the mesodermic origin (Ballo et al., 2001). Spermatic cord sarcomas account for approximately 30% of all genitourinary sarcomas (Coleman et al., 2003). Liposarcoma is the most common histologic type of spermatic cord sarcomas, comprising 46-51% of all spermatic cord malignant tumors (Coleman et al., 2003; Rodriguez et al., 2014). Histologically liposarcomas are divided into well differentiated, dedifferentiated (high and low grade) and myxoid/round cell (Montgomery and Fisher, 2003). Most spermatic cord liposarcomas are well differentiated, low-grade malignancies with no or minimal tendency to metastasize but they may be locally invasive (Schwartz et al., 1995).

Patients with spermatic cord liposarcomas usually present in their fifties or sixties, mostly ranging from 16 to 87 years (Fitzgerald and MacLennan, 2009). Spermatic cord liposarcomas usually develop as a slow-growing paratesticular mass, presenting as a solid, irregular palpable mass of the inguinal canal or scrotum (Montgomery and Fisher, 2003). They are clearly distinct from the testis, and usually do not transilluminate light during physical exam evaluation. They may be accompanied by pain, a hydrocele, or symptoms secondary to metastasis (Ballo et al., 2001). However, for the most part the clinical manifestations are usually nonspecific, with a sensation of compression and heaviness due to local mass effect, which is diagnosed after a long evolution, since they are usually painless (Rodriguez and Olumi, 2012). These masses should be differentiated from inguinal hernia, hydrocele, lipoma, hematocele, tuberculosis epididymitis or orchiepididymitis, and malignant lesions of the testis such as carcinoma and mesothelioma (Folpe and Weiss, 2000).

Correctly diagnosing liposarcoma of the spermatic cord is difficult due to the anatomical location in which it presents and the appearance of the mass as fatty tissue on imaging studies (Peterson et al., 2003; Chintamani et al., 2010). Ultrasonography (US) is the primary imaging method for any cord or scrotal abnormalities; it has a sensitivity of 95–100% for distinguishing intratesticular from extratesticular lesions (Frates et al., 1997). The US examination is reliable in identifying and confirming the

location and consistency of the mass as well as determining the status of the cord and the testes. Liposarcomas are commonly bulky, heterogeneous tumors that have variable amounts of fat with hyperechoic areas (Akbar et al., 2003; Secil et al., 2004). Although the use of computed tomography (CT) and/or magnetic resonance image (MRI) scans is not widely reported, it has been found to be useful in narrowing the differential diagnosis by suggesting fat-containing neoplasms, such as liposarcomas (Cardenosa et al., 1990; Coleman et al., 2003). Demonstration of adipose tissue within tumor masses on CT and/or MRI can identify their fatty nature and detection of heterogeneous soft-tissue components helps to differentiate lipomas from liposarcomas (Cardenosa et al., 1990; Woodward et al., 2003). Detailed analysis of plain and enhanced CT images has the advantage of allowing a qualitative diagnosis as well as a preliminary prognostic evaluation (Lu et al., 2014). Nonetheless, both US and CT findings are often variable and nonspecific. No specific radiographic features of spermatic cord masses were useful for distinguishing benign from malignant lesions with absolute certainty (Frates et al., 1997), especially in smaller ones, as in the case we presented. It is generally accepted that surgery is the ultimate form to get a definitive diagnosis.

The rarity of spermatic cord liposarcomas leaves a problem for the best treatment. Surgery is widely considered to be the primary and only possible curative treatment for all spermatic cord sarcomas. The standard therapeutic approach for these tumors has been radical inguinal orchiectomy and resection of the tumor with negative microscopic margins (Rodriguez and Olumi, 2012; Guttilla et al., 2013; Radaelli et al., 2014; Rodriguez et al., 2014). These are also essential components of the current management of spermatic cord liposarcomas. However, sarcomas occurring in this anatomical region are rarely amenable to wide excision, and resection margins are almost invariably close. Thus, local recurrence is a major problem. Ballo and his colleagues reported a local recurrence rate of spermatic cord sarcomas after resection alone of 30% at 10 years and 42% at 15 years, with local recurrence (LR) being the most common pattern of failure (Ballo et al., 2001). Even in well-differentiated liposarcomas, LR is high (Peralta et al., 2013). So, in patients with liposarcomas, the status of surgical margins strongly influences outcome (Khandekar et al., 2013). Every attempt should therefore be made to obtain clear surgical margins in order to minimize the risk of LR. Wide excision of the tumor en bloc with radical orchidectomy, excision of the ipsilateral scrotum, high spermatic cord ligation, and resection of the adjacent soft tissue, including the spermatic vessels deep in the internal inguinal ring, is required to confidently obtain locoregional control. (Radaelli et al., 2014)

However, there are different opinions pertaining to surgical approach. It has been reported that spermatic cord liposarcomas LR did not significantly correlate with poor disease specific survival. (Rodriguez et al., 2014) Radaelli, S. reported none of the patients with well-differentiated liposarcoma developed distant metastasis within 5 years (Radaelli et al., 2014). This reflected the natural history of this indolent group of tumors, characterized by a very low

rate of LR if resected with macroscopically clear margins as well as by its inability to metastasize (Kooby et al., 2004). So, as for liposarcomas at spermatic cord, some authors reported that the simple complete tumour excision, if feasible, can be performed with the intent to preserve the testis (Peralta et al., 2013). After 1.5-3 years of follow up, all the cases receiving organ-sparing surgery did well with no signs of recurrence (Manzia et al., 2010; Hsu et al., 2012; Peralta et al., 2013). It was also suggested that other histological subtypes of sarcoma in the extremities or spermatic cord may be adequately managed with resection alone (Geer et al., 1992). Furthermore, there is growing awareness of the potential advantages of testis preservation over traditional extirpative surgery in terms of health-related quality-of-life issues, namely preservation of fertility, preservation of endocrine function thereby avoiding the risk of late-onset hypogonadism, and preservation of male body image (Giannarini et al., 2010). So in our opinion, for small spermatic cord liposarcoma, especially well-differentiated, testis-sparing surgery might be a viable therapy if an adequate negative surgical margins is assured, which was concluded in our case report.

In spite of the likelihood of recurrence, the prognosis was satisfactory. In a study of all histological types of spermatic cord sarcomas, the overall 5-year survival was 75%, with half of all patients experiencing tumor recurrence. Among these patients with spermatic cord liposarcomas, only 4% had metastases at the time of diagnosis (Coleman et al., 2003). Tumor size and absence of metastasis at diagnosis remained significant predictors of disease-specific survival (Dotan et al., 2006). Prognosis and survival also varied in relation to histopathological classification. Myxoid and well differentiated had better prognosis than round cell and pleomorphic liposarcoma (Alyousef et al., 2013). Since disease recurrence can occur years after surgery, long-term follow-up is recommended (Ballo et al., 2001; Rodriguez and Olumi, 2012).

In summary, liposarcomas of the spermatic cord are rare lesions that should be considered in the presentation of any noncystic scrotal masses. Ultrasonography, CT and MRI can provide useful information about the lipomatous nature of these masses preoperatively. When diagnosed or suspected preoperatively, radical inguinal orchiectomy and resection of the tumor with negative microscopic margins is the recommended treatment. The indolent natural history of spermatic cord liposarcoma and functional advantages, namely preservation of fertility, endocrine function, and male body image, represent a strong theoretical argument to support the use of organ-sparing surgery for the treatment of spermatic cord liposarcomas under appropriate conditions. In our opinion, for small spermatic cord liposarcomas, especially well-differentiated, testis-sparing surgery might be a viable therapy if an adequate negative surgical margins is assured. Regardless of initial therapy, long-term follow up is necessary.

Acknowledgements

We thanks Xuming for providing ultrasonography photographs.

References

- Akbar SA, Sayyed TA, Jafri SZ, et al (2003). Multimodality imaging of paratesticular neoplasms and their rare mimics. *Radiographics*, **23**, 1461-76.
- Alyousef H, Osman EM, Gomha MA (2013). Paratesticular liposarcoma: a case report and review of the literature. *Case Rep Urol*, **2013**, 806289.
- Ballo MT, Zagars GK, Pisters PW, et al (2001). Spermatic cord sarcoma: outcome, patterns of failure and management. *J Urol*, **166**, 1306-10.
- Cardenosa G, Papanicolaou N, Fung CY, et al (1990). Spermatic cord sarcomas: sonographic and CT features. *Urol Radiol*, **12**, 163-7.
- Chintamani, Tandon M, Khandelwal R, et al (2010). Liposarcoma of the spermatic cord: a diagnostic dilemma. *JRSM Short Rep*, **1**, 49.
- Coleman J, Brennan MF, Alektiar K, et al (2003). Adult spermatic cord sarcomas: management and results. *Ann Surg Oncol*, **10**, 669-75.
- Cui L, Liu XX, Jiang Y, et al (2014) Phase II study on dose escalating schedule of paclitaxel concurrent with radiotherapy in treating patients with locally advanced non-small cell lung cancer. *Asian Pac J Cancer Prev*, **15**, 1699-702.
- Dotan ZA, Tal R, Golijanin D, et al (2006). Adult genitourinary sarcoma: the 25-year Memorial Sloan-Kettering experience. *J Urol*, **176**, 2033-9.
- Fitzgerald S, MacLennan GT (2009). Paratesticular liposarcoma. *J Urol*, **181**, 331-2.
- Folpe AL, Weiss SW (2000). Paratesticular soft tissue neoplasms. *Semin Diagn Pathol*, **17**, 307-18.
- Frates MC, Benson CB, DiSalvo DN, et al (1997). Solid extratesticular masses evaluated with sonography: pathologic correlation. *Radiology*, **204**, 43-6.
- Geer RJ, Woodruff J, Casper ES, et al (1992). Management of small soft-tissue sarcoma of the extremity in adults. *Arch Surg*, **127**, 1285-9.
- Giannarini G, Dieckmann KP, Albers P, et al (2010) Organ-sparing surgery for adult testicular tumours: a systematic review of the literature. *Eur Urol*, **57**, 780-90.
- Guttilla A, Crestani A, Zattoni F, et al (2013) Spermatic cord sarcoma: our experience and review of the literature. *Urol Int*, **90**, 101-5.
- Hsu YF, Chou YY, Cheng YH (2012). Spermatic cord myxoid liposarcoma presenting as an incarcerated inguinal hernia: report of a case and review of literatures. *Hernia*, **16**, 719-22.
- Huang XE, Tian GY, Cao J, et al (2014). Pemetrexed as a component of first-, second- and third- line chemotherapy in treating patients with metastatic lung adenocarcinoma. *Asian Pac J Cancer Prev*, **14**, 6663-7.
- Ji ZQ, Huang XE, Wu XY, et al (2014). Safety of *Brucea javanica* and cantharidin combined with chemotherapy for treatment of NSCLC patients. *Asian Pac J Cancer Prev*, **15**, 8603-5.
- Khandekar MJ, Raut CP, Hornick JL, et al (2013). Paratesticular liposarcoma: unusual patterns of recurrence and importance of margins. *Ann Surg Oncol*, **20**, 2148-55.
- Kooby DA, Antonescu CR, Brennan MF, et al (2004). Atypical lipomatous tumor/well-differentiated liposarcoma of the extremity and trunk wall: importance of histological subtype with treatment recommendations. *Ann Surg Oncol*, **11**, 78-84.
- Lu J, Qin Q, Zhan LL, et al (2014). Computed tomography manifestations of histologic subtypes of retroperitoneal liposarcoma. *Asian Pac J Cancer Prev*, **15**, 6041-6.
- Manzia TM, Gravante G, Toti L, et al (2010) Management of spermatic cord liposarcoma in renal transplant recipients: case report. *Transplant Proc*, **42**, 1355-7.

- Montgomery E, Fisher C (2003). Paratesticular liposarcoma: a clinicopathologic study. *Am J Surg Pathol*, **27**, 40-7.
- Peralta JP, Godinho R, Rabaca C, et al (2013). Spermatic cord liposarcoma: organ-sparing surgery. *BMJ Case Rep*, 2013.
- Peterson JJ, Kransdorf MJ, Bancroft LW, et al (2003). Malignant fatty tumors: classification, clinical course, imaging appearance and treatment. *Skeletal Radiol*, **32**, 493-503.
- Radaelli S, Desai A, Hodson J, et al (2014). Prognostic factors and outcome of spermatic cord sarcoma. *Ann Surg Oncol*, **21**, 3557-63.
- Rodriguez D, Barrisford GW, Sanchez A, et al (2014). Primary spermatic cord tumors: disease characteristics, prognostic factors, and treatment outcomes. *Urol Oncol*, **32**, 19-52.
- Rodriguez D, Olumi AF (2012) Management of spermatic cord tumors: a rare urologic malignancy. *Ther Adv Urol*, **4**, 325-34.
- Schwartz SL, Swierzewski SR, Sondak VK, et al (1995). Liposarcoma of the spermatic cord: report of 6 cases and review of the literature. *J Urol*, **153**, 154-7.
- Secil M, Kefi A, Gulbahar F, et al (2004). Sonographic features of spermatic cord leiomyosarcoma. *J Ultrasound Med*, **23**, 973-6, 977-8.
- Woodward PJ, Schwab CM, Sesterhenn IA (2003). From the archives of the AFIP: extratesticular scrotal masses: radiologic-pathologic correlation. *Radiographics*, **23**, 215-40.