

RESEARCH ARTICLE

Significance and Application of Digital Breast Tomosynthesis for the BI-RADS Classification of Breast Cancer

Si-Qing Cai*, Jian-Xiang Yan, Qing-Shi Chen, Mei-Ling Huang, Dong-Lu Cai

Abstract

Background: Full-field digital mammography (FFDM) with dense breasts has a high rate of missed diagnosis, and digital breast tomosynthesis (DBT) could reduce organization overlapping and provide more reliable images for BI-RADS classification. This study aims to explore application of COMBO (FFDM+DBT) for effect and significance of BI-RADS classification of breast cancer. **Materials and Methods:** In this study, we selected 832 patients who had been treated from May 2013 to November 2013. Classify FFDM and COMBO examination according to BI-RADS separately and compare the differences for glands in the image of the same patient in judgment, mass characteristics display and indirect signs. Employ Paired Wilcoxon rank sum test was used in 79 breast cancer patients to find differences between two examine methods. **Results:** The results indicated that COMBO pattern is able to observe more details in distribution of glands when estimating content. Paired Wilcoxon rank sum test showed that overall classification level of COMBO is higher significantly compared to FFDM to BI-RADS diagnosis and classification of breast ($P < 0.05$). The area under FFDM ROC curve is 0.805, while that is 0.941 in COMBO pattern. COMBO shows relation of mass with the surrounding tissues, the calcification in the mass, and multiple foci clearly in breast cancer tissues. The optimal sensitivity of cut-off value in COMBO pattern is 82.9%, which is higher than that in FFDM (60%). They share the same specificity which is both 93.2%. **Conclusions:** Digital Breast Tomosynthesis (DBT) could be used for the BI-RADS classification in breast cancer in clinical.

Keywords: Digital Breast Tomosynthesis(DBT) - full-field digital mammography - COMBO mode - BI-RADS

Asian Pac J Cancer Prev, 16 (9), 4109-4114

Introduction

Recently, full-field digital mammography (FFDM) is the preferred method that has been accepted for examining breast cancer and other diseases (Ahn et al., 2014). However, among the women in China (especially in the southern districts), the breasts are relatively smaller in size and higher in density, which may limit the correct diagnostic rate of FFDM. Digital Breast Tomosynthesis (DBT) is a three-dimensional imaging technology, in which the images of breasts may be obtained from different angles in the short scanning process (Rao et al., 2005). And then these independent images are rebuilt into a series of tomographic images with high resolution, which may be displayed separately or dynamically in the form of continuous playback. Compared with the FFDM, the DBT, which reduces or eliminates the influences of the tissue overlap and structural noise of breasts, may improve the accuracy of diagnosis and screening effectively, reduce the recall rate and decrease the unnecessary biopsies.

We conducted an examination among 832 patients by both FFDM and COMBO (FFDM+DBT), in order to probe the influence and significance of DBT on BI-RADS classification.

Materials and Methods

Subjects

This study is a prospective case analysis. A total of 832 cases of patients (including breast cancer patients and other breast disease patients) were selected treated in our hospital between May 2013 and November 2013 (age ≥ 18 year and ≤ 77 year, mean age: 41.76 ± 8.75 years). Inclusion criteria: 1) palpable masses; 2) existence of lesions revealed by color Doppler ultrasound examination; 3) to inform the patients of the significance of the examinations and allow them to sign an informed consent form.

Equipments

Selenia Dimensions 3D system (Selenia[®] Dimensions[®]) produced by Hologic Company, U.S.A.

Examination methods

All the patients were examined by using X-ray at craniocaudal (CC) view and mediolateral oblique (MLO) view of the bilateral breasts. The X-ray tube rotated within 15 degree each time; the low dose exposure occurred one time with every rotation of 1 degree; the acquired 15 frames of images were rebuilt into a series of tomographic

Table 1. BI-RADS Classifying Diagnosis

Breasts	Classification	Positive signed-rank	Negative signed-rank	Mean signed-rank	Total	P values	Z values
Right	FFDM	99	2	731	832	<0.05	-8.59
	COMBO						
Left	FFDM	117	2	713	832	<0.05	-9.498
	COMBO						

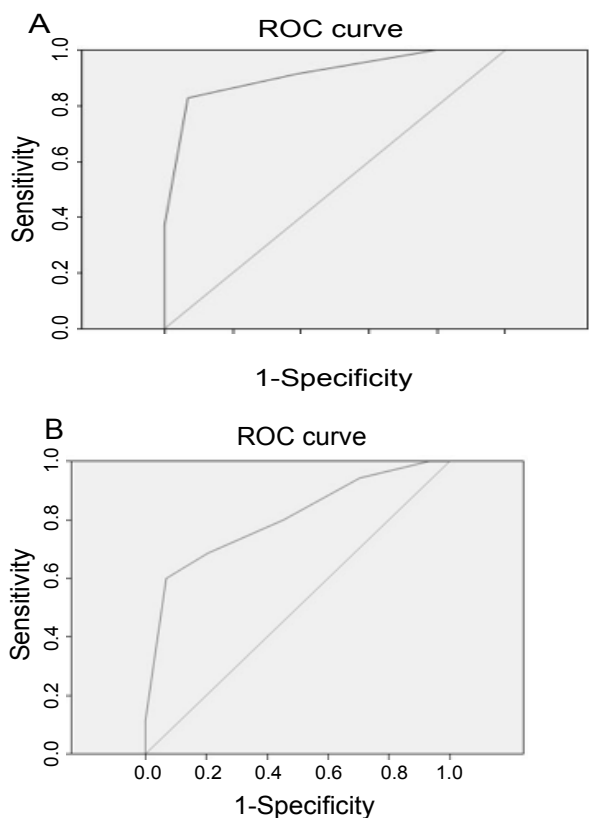


Figure 1. ROC Curve of COMBO and FFDM Model

images with high resolution. The images of FFDM and DBT were obtained at the same stress body position, i.e. COMBO model.

Evaluation methods

The results of FFDM and COMBO obtained in 832 patients were recorded, respectively. The differences in the distributions of breast lesions in BI-RADS classifying diagnosis were investigated using the standard of BI-RADS classifying diagnosis. The diagnostic efficiency obtained by the above-mentioned two examination methods respectively was evaluated in the 79 breast cancer cases with pathological results. A consistent conclusion was made for each case by reading X-ray films and group consultation by four doctors.

Statistical analysis

An analysis was made by using SPSS 18.0 statistical software. The differences between the two different examination methods in the distributions of breast lesions in BI-RADS classifying diagnosis were analyzed by using Wilcoxon matched-pairs signed-rank and test. The pathological results were used as a gold standard, the

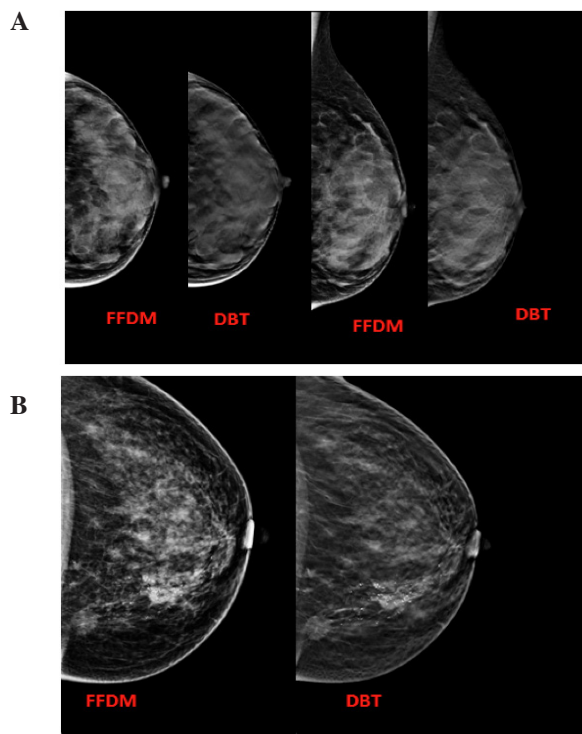


Figure 2. DBT Images for the Gland Contents and Tumor Edge. A) The DBT mage illustrating the gland contents. **B)** The DBT image illustrating the tumor edge. X-ray report for BI-RADS:5, the pathological report of invasive ductal carcinoma

evaluation of the efficiency of diagnosing breast lesions in breast cancer by FFDM and combination of FFDM with DBT was analyzed through receiver operator characteristic (ROC) curve. The difference was statistically significant with $p < 0.05$.

Results

BI-RADS classifying diagnosis by two methods

Statistical analysis of the differences in the distributions of breast lesions detected by two different examination methods (FFDM and COMBO) in BI-RADS classifying diagnosis (Wilcoxon matched-pairs signed-rank and test) was performed. The results were indicated in Table 1.

Pathological diagnosis

The pathological diagnosis was resulted as the followings: benign tumors, 48 sides (21 left sides and 27 right sides); invasive ductal carcinomas, 30 sides; fibroma, 16 sides; fibrocystic mastopathy with fibroma, 5 sides; fibrocystic mastopathy, 12 sides; intraductal papilloma, 4 sides; inflammation, 2 sides; benign leaf tumor, 1 side; senile cystic degeneration, 4 sides; hamartoma, 1 side; no

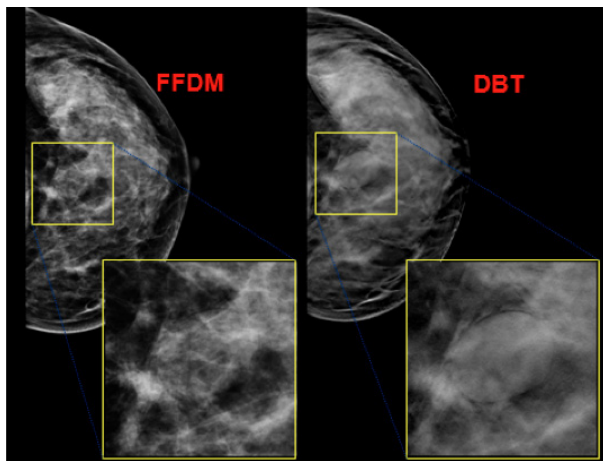


Figure 3. DBT Images for the Bright Ring Around the Mass. The figure report of X-ray demonstrated BI-RADS: 4A. The pathological report revealed fibroadenoma.

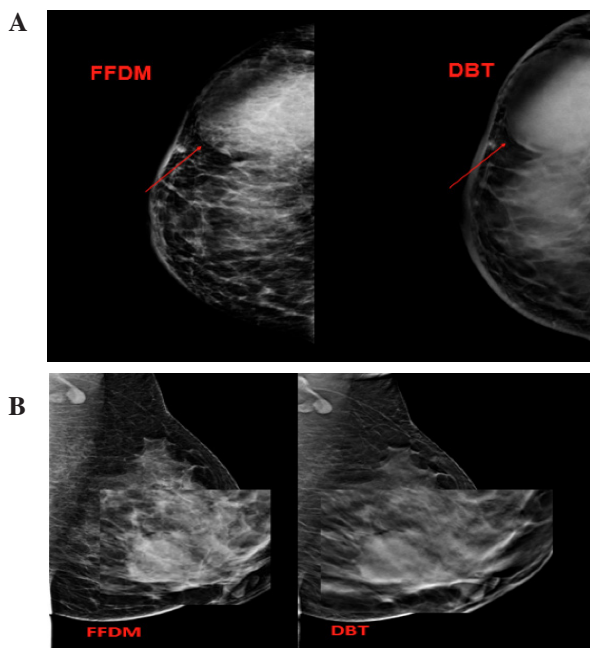


Figure 4. DBT Images for the Relation of the Mass with the Surrounding Tissues. A) The details of adhesion of the mass with skin. B) Relation of focus with nipple. These pathological results revealed in invasive ductal carcinoma

inflammation, 2 sides; malignant tumors, 36 sides (23 left sides and 13 right sides); papillary carcinomas, 2 sides; invasive carcinoma, 1 side; mucinous carcinomas, 2 sides; mixed ductal-tubular carcinoma, 1 side.

ROS curve of COMBO and FFDM

ROS curve for the results of COMBO and FFDM was drawn according to the gold standard of pathology. The results of COMBO model indicated that the area under ROC curve was 0.914. The COMBO measurement result of 6.5 was an optimal cut-off point value, in which sensitivity was 82.9%, and specificity 93.2% (Figure 1A). The results of FFDM indicated that the area under ROC curve was 0.805. The FFDM measurement result of 6.5 was an optimal cut-off point value, in which sensitivity was 60%, and specificity 93.2% (Figure 1B).

The above results indicate that the detection method of COMBO is better. First, a higher value would be better

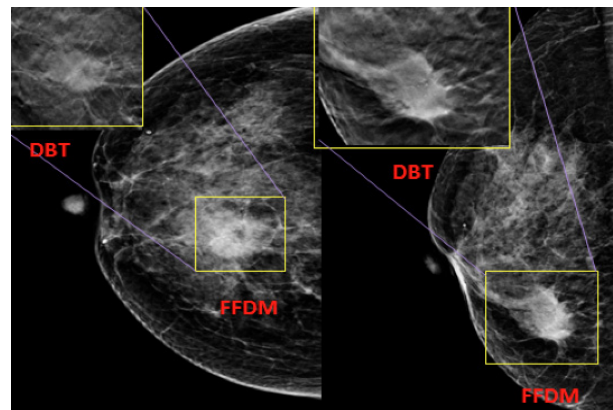


Figure 5. Calcification Illustration Images Detected by Using the FFDM and DBT Method

when the area under ROC curve is within the limits of 5.0-1.0; the area under ROC curve of FFDM measurement results is 0.805, and the area under ROC curve of COMBO measurement results 0.914. Secondly, the sensitivity of the optimal cut-off point value of COMBO measurement results (82.9%) is higher than that of FFDM measurement results (60%), and the specificity of both optimal cut-off point values is the same (93.2%).

DBT illustrates the gland contents and tumor edge

The DBT images can give a more accurate evaluation of the gland contents and display of gland distributions (Figure 2A) in the tumor tissues. COMBO showed the tumor edge more clearly (Figure 2B).

DBT shows the bright ring around the mass in tumor tissues

The mass with equal density in the rich glands tends to be shown unclearly in the images of FFDM. COMBO can show the mass clearly, with a smooth edge, clear borders and a visible linear bright ring around the mass in tumor tissues (Figure 3).

DBT shows the relation of mass with the surrounding tissues clearly in breast cancer

Figure 4A showed the details of adhesion of the mass with skin. The results indicated that DBT could show the relation of mass with the surrounding tissues more clearly in invasive ductal carcinoma tissues. Figure 4B showed the relation of focus with nipple. The pathological results revealed invasive ductal carcinoma. These pathological results revealed in invasive ductal carcinoma.

DBT shows calcification in the mass surrounding the tumor tissues

In order to explore the application of the DBT in the calcification diagnosis in tumor tissues, the FFDM and DBT methods were performed. The results indicated that the DBT method could show the calcification clearly surrounding the breast cancer tissues compared to the FFDM method (Figure 5).

DBT method avoids the negative image for the mass in breast cancer tissues

DBT may avoid a false negative result caused by the

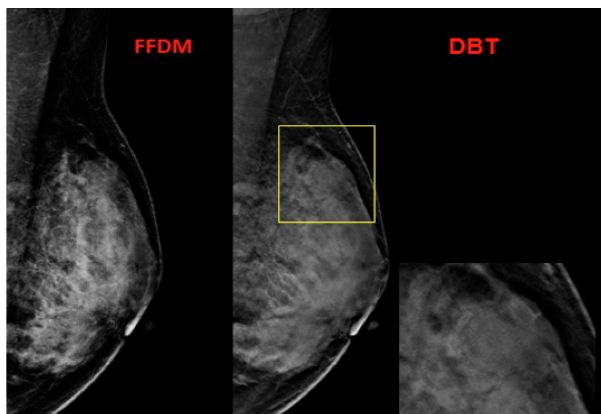


Figure 6. DBT Images Shows the Mass in Overlapped Tumor Tissues

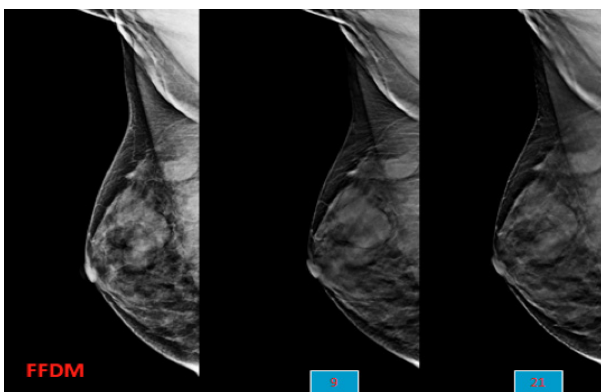


Figure 7. DBT Images Illustrates the Different Layers in the Layers 9 and 21

tissue overlap. As shown in Figure 6, FFDM does not reveal an obvious focus, however, the DBT shows a visible mass of breast tumor tissues with equal density.

DBT shows multiple foci more clearly in breast cancer tissues

For the breast cancer, the mass in the tumor tissues always be ignored because of the different layers. As shown in Figure 7, there are visible masses of different layers in the layers 9 and 21 of the tissues, respectively.

Sensitivity and specificity of COMBO

The optimal sensitivity of cut-off value in COMBO pattern is 82.9%, which is higher than that in FFDM (60%). However, they share the same specificity which is both 93.2%. Therefore, the COMBO is better compared to the FFDM model.

Discussion

Digital breast tomosynthesis (DBT) is a three-dimensional imaging technology, in which the images of breasts may be obtained from different angles in the short scanning process. And then these independent images are rebuilt into a series of tomographic images with high resolution, which may be displayed separately or dynamically in the form of continuous playback. The rebuilt three-dimensional tomographic images, which reduces or eliminates the problems caused by the tissue overlap and structural noise in a two-dimensional breast

mammography, may reduces or eliminates the tissue overlap (Takamoto et al., 2013; Roth et al., 2014). It was reported in literature that the omission diagnostic rate of breast cancers resulted in by a traditional X-ray photography in the patients with dense breasts was as high as 76% (Niklason et al., 1997) the groups with more quantity of the glands accounted for 87.6% in our 832 patients. Therefore, the use of a traditional digital breast mammography had major limitations in our region. Using the classification criterion of breast image report and data system established and recommended by the American College of Radiology (Lieberman et al., 2012) as the footstone of BI-RADS classification, the signs, such as mass edge, the bright ring around a mass, blood vessel images, calcification foci and the relations with the adjacent tissues and so on, were shown more clearly in tomographic images (Partyka et al., 2014). DBT avoided overlap of breast tissues with lesion foci, discriminated between normal breast tissues and lesion foci with high density, allowed the shape and edge of a mass to be shown clearly and decreased the false negative and false positive results caused by omission diagnosis and tissue overlap respectively, so as to reduce the recall rate caused by false positive results and patient's unnecessary anxiety (Sun et al., 2014). Lei J et al. (2014) evaluated the efficiency of diagnosing benign and malignant lesions by using DBT and FFDM through searching the databases, such as PubMed, EMBASE, Cochrane Library, Science Network, Chinese Biological and Medical Database and so on; analyzed the sensitivity, specificity, diagnostic odds ratio (DOR) and positive and negative likelihood ratio by using metadisc 1.4 software; and summarized the receiver operating characteristic curve (SROC) of the two different diagnostic methods, which dealt with a total of 7 researches on 2014 patients and 2666 cases of breast lesions; compared with gold standard, the sensitivity and specificity of the compiled COMBO and FFDM were 90% and 79%, 89% and 72% respectively, the positive likelihood ratios of combination of COMBO with FFDM were 3.50 and 2.83 and the negative likelihood ratios of combination of DBT with FFDM were 15% and 18%, respectively. Lei et al. (2014) thought that DBT might have a higher sensitivity and specificity than FFDM in the diagnosis of breast cancers and would become a preferred method for evaluating breast lesions. An analysis of 79 cases with pathologic results made by using ROC curve in our case group showed that the area under ROC curve of COMBO (0.914) was greater than that of FFDM (0.805), the sensitivity of the optimal cut-off point value of COMBO results (82.9%) was higher than that of FFDM (60%) and the specificity of both methods was the same (93.2%), thereby indicating that the examination method of COMBO is more optimal. This is considerably significant for the judgment of the gland content, manifestation of mass characteristics, the probing of hidden calcification and judgment of the changes in vascular images, skin and subcutaneous soft tissue all, extensive documentation focused on the significance of DBT for dense breasts. The author found in study that DBT had its unique contribution for any types of breasts and positive meaning for our classification of breast

lesions. In a multi-center and multi-sample experiment, the effects of DBT observations were better for 89% of cases with breast tumors and mammary dysplasia (Margolies et al., 2014). It was shown in our study that DBT might give a more accurate evaluation of contents of mammary glands, reveal their distributions and show edges of the tumors. It was reported in some literatures that the possibility of malignant changes was less than 2% among the patients with a clear, sharp and smooth edge of tumor. The possibility was as high as 81%-97% among the patients with a burr on edge of tumor, a positive burr sign hinting possible breast cancer to a great extent (Smith, 2005; Gong et al., 2006) Poplack et al. (Poplaek et al., 2007) deemed that DBT images, especially the images of tumors, were superior to traditional FFDM images. From the results, we might make judgment of a benign tumor for a mass with a smooth edge, clear borders and a fine uniform bright ring around it, which is consistent with the previous study (Hakim et al., 2014). This might provide a more accurate basis of images for the minimally invasive surgery expected by the women who love beauty. The study objects reported in the foreign literatures all were European and American women, whose breasts were characterized mainly by fat type breasts, therefore the effects of the gland overlap on images were relatively small (Gong et al., 2006; Park et al., 2007; Poplaek et al., 2007). In the Southern China, the race belongs to thin small type, whose breasts are small in size and high in the gland contents; in our study, the ratio of the groups with more quantity of the glands were as high as 87.6%, and nearly ninety percent of the population were the objects which were insensitive for FFDM. Therefore, the significance of use of will be more will be more profound for the southern districts of our country. Micro-calcification has been a highly specific sign that predicts benign and malignant tumors. For a long time, FFDM has been considered to have incomparable advantage for revealing micro-calcification compared with other imaging examinations (Greenberg et al., 2014; Margolies et al., 2014). DBT was thought to be superior to FFDM to a certain extent (Niklason et al., 1997; Reiser et al., 2008). The author thinks that the tomographic images shown by DBT, which eliminate interferences from overlaps of the gland tissues and other normal structures of breasts, would allow the micro-calcification hidden in dense mammary glands or lesions to be found. The use of DBT could improve the detection of micro-calcification significantly, thereby enhancing the detection rate of early-stage breast cancers notably (Fidewald et al., 2014). It is remarkable that when clustering micro-calcification is shown in some cases, to make observations in combination with FFDM or adjust the shown layer thickness is still necessary, as thickness of 1mm would permit the total amount of calcification in each field of view to decrease, which is unfavorable to make judgment of characters of the lesions (Gur et al., 2012). Therefore, the observations made by COMBO model are the recommended method. It was reported in literature that narrow angle DBT could provide a higher sensitivity and demonstrate the fine clusters of micro-calcification (Chan et al., 2014). In traditional mammary gland X-ray photography, X-ray is difficult to

pass through this area when the overlap of mammary gland tissues occurs in a area, so as to leave the area to be suspected easily as a pathological lesion in images, especially in the cases with dense type mammary glands. Clinical investigations found that the cases misdiagnosed because of unclear image display were not isolated examples, and the misdiagnosis not only influenced the related treatments of patients, but also increased the patient' psychological burden. The false positive results caused from the limited densification brought about by overlap of normal tissues or blur of tumor edge would also affect the positive prediction values and specificity of experiments (Lang et al., 2014). A research on diagnostic accuracy rate and recall rate with radiologists (Rafferty et al., 2013) demonstrated that combination of digital photography with tomography was superior to digital mammary gland photography alone and reduced the recall rate of non-cancer cases significantly at the same time. The small mass that could not be found due to overlap of breast tissues could be revealed in the images of DBT, increasing the detection rates of multi-center lesions (Gong et al., 2006). In general, we were more to make judgment of benign tumors for multiple tumors with a smooth edge, clear borders and uniform density. The breast screening system has been established in many countries with increasing morbidity of breast cancers, the mortality was down on the contrary, this benefited from the screening practices for breast cancers (Vaughan et al., 2012; Nie et al., 2013). A study of community (Greenberg et al., 2014) demonstrated that DBT reduced recall rates and increased overall cancer detection rate (CDR). In our country, the related research is still on the initial stage; however, it is believed that will be more would be more widely used, bringing well-being to the people.

References

- Ahn HS, Kim SM, Jang M, et al (2014). A new full-field digital mammography system with and without the use of an advanced post-processing algorithm: comparison of image quality and diagnostic performance. *Korean J Radiol*, **15**, 305-312.
- Chan HP, Goodsitt MA, Helvie MA, et al (2014). Digital breast tomosynthesis: observer performance of clustered microcalcification detection on breast phantom images acquired with an experimental system using variable scan angles, angular increments, and number of projection views. *Radiology*, **7**, 132722.
- Fidewald SM, Rafferty EA, Rose SL, et al (2014). Breast cancer screening using tomosynthesis in combination with digital mammography. *JAMA*, **311**, 2499-507.
- Gong X, Glick SJ, Liu B, Vedula AA, Thacker S (2006). A computer simulation studycomparing lesion detection accuracy with digital mammography, breast tomosynthesis, and cone-beam CT breast imaging. *Med Phys*, **33**, 1041-52.
- Greenberg JS, Javitt MC, Katzen J, Michael S, Holland AE. (2014). Clinical performance metrics of 3d digital breast tomosynthesis compared with 2d digital mammography for breast cancer screening in community practice. *Am J Roentgenol*, **203**, 687-93.
- Gur D, Zuley ML, Anello MI, et al (2012). Dose reduction in digital breast tomosynthesis (DBT). screening using synthetically reconstructed projection images: an observer

- performance study. *Acad Radiol*, **19**, 166-71.
- Hakim CM, Anello MI, Cohen CS, et al (2014). Impact of and interaction between the availability of prior examinations and DBT on the interpretation of negative and benign mammograms. *Acad Radiol*, **21**, 445-9.
- Lang K, Andersson I, Zackrisson S. (2014). Breast cancer detection in digital breast tomosynthesis and digital mammography-a side-by-side review of discrepant cases. *Br J Radiol*, **87**, 20140080.
- Lei J, Yang P, Zhang L, Wang Y, Yang K. (2014). Diagnostic accuracy of digital breast tomosynthesis versus digital mammography for benign and malignant lesions in breasts: a meta-analysis. *Eur Radiol*, **24**, 595-602.
- Liberman L, Menell JH. (2002). Breast imaging reporting and data system (BI-RADS).. *Radiol Clin Noah Am*, **40**, 409-30.
- Margolies L, Cohen A, Sonnenblick E, et al (2014). Digital breast tomosynthesis changes management in patients seen at a tertiary care breast center. *ISRN Radiol*, **2014**, 658929.
- Nie LY, Lu QT, Li WH, et al (2013). Sterol regulatory element-binding protein 1 is the required for ovarian tumor growth. *Oncol Rep*, **30**, 1346-54.
- Niklason LT, Christian BT, Niklason LE, et al. (1997). Digital tomosynthesis in breast imaging. *Radiol*, **205**, 399-406.
- Park JM, Franken EA, Garg M, Fajardo LL, Niklason LT. (2007). Breast tomosynthesis: present considerations and future applications. *Radiographics*, **27**, 231-40.
- Partyka L, Lourenco AP, Mainiero MB. (2014). Detection of mammographically occult architectural distortion on digital breast tomosynthesis screening: initial clinical experience. *Am J Roentgenol*, **203**, 216-22.
- Poplaek SP, Tosteson TD, Xogd CA, Nagy HM (2007). Digital breast tomosynthesis: initial experience in 98 women with abnormal digital screening mammography. *Am J Roentgenol*, **189**, 616-23.
- Rafferty EA, Park JM, Philpotts LE, et al (2013). Assessing radiologist performance using combined digital mammography and breast tomosynthesis compared with digital mammography alone: results of a multicenter, multireader trial. *Radiol*, **266**, 104-13.
- Rao M, Stough J, Chi YY, et al (2005). Comparison of human and automatic segmentations of kidneys from CT images. *Int J Radiat Oncol Biol Phys*, **61**, 954-60.
- Reiser I, Nishikawa RM, Edwards AV, et al (2008). Automated detection of microcalcification clusters for digital breast tomosynthesis using projection data only: a preliminary study. *Med Phys*, **35**, 1486-93.
- Roth RG, Maidment AD, Weinstein SP, Roth SD, Conant EF (2014). Digital breast tomosynthesis: lessons learned from early clinical implementation. *Radiographics*, **34**, E89-102.
- Smith A (2005). Full-field breast tomosynthesis. *Radiol Manage*, **27**, 25-31.
- Sun JH, Jiang L, Guo F, Zhang XS (2014). Diagnostic significance of apparent diffusion coefficient values with diffusion weighted MRI in breast cancer: a meta-analysis. *Asian Pac J Cancer Prev*, **15**, 8271-7.
- Takamoto Y, Tsunoda H, Kikuchi M, et al (2013). Role of breast tomosynthesis in diagnosis of breast cancer for Japanese women. *Asian Pac J Cancer Prev*, **14**, 3027-40.
- Vaughan CL, Evans MD (2012). Diagnosing breast cancer: an opportunity for innovative engineering. *S Afr Med J*, **102**, 562-4.