

RESEARCH ARTICLE

Diagnosis of Hepatocellular Carcinoma Using C-11 Choline PET/CT: Comparison with F-18 FDG, Contrast-Enhanced MRI and MDCT

Chanisa Chotipanich^{1*}, Anchisa Kunawudhi¹, Chetsadaporn Promteangtrong¹, Puntira Tungsuppawattanakit², Thaniya Sricharunrat³, Paramest Wongsai¹

Abstract

Purpose: The aim of this study was to compare C-11 choline and F-18 FDG PET/CT, gadoteric-enhanced 3-T MRI and contrast-enhanced CT for diagnosis of hepatocellular carcinoma (HCC). **Materials and Methods:** Twelve chronic hepatitis B patients suspected of having HCC by abdominal ultrasonography received all diagnostic modalities performed within a one-week timeslot. PET/CT results were analyzed visually by two independent nuclear medicine physicians and quantitatively by tumor to background ratio (T/B). Nine patients then had histopathological confirmation. **Results:** Six patients had well differentiated HCC, while two and one patient(s) were noted with moderately and poorly differentiated HCC, respectively. All were detected by both CT and MRI with an average tumor size of 5.7 ± 3.8 cm. Five patients had positive C-11 choline and F-18 FDG uptake. Of the remaining four patients, three with well differentiated HCC showed negative F-FDG uptake (one of which showed negative results by both tracers) and one patient with moderately differentiated HCC demonstrated no C-11 choline uptake despite intense F-18 FDG avidity. The overall HCC detection rates with C-11 choline and F-18 FDG were 78% and 67%, respectively, while the sensitivity of F-18 FDG for non-well differentiated HCC was 100%, compared with 83% of C-11 choline. The average T/B of C-11 choline in well-differentiated HCC patients was higher than in moderately and poorly differentiated cases ($p=0.5$) and vice versa with statistical significance for T/B of F-18 FDG ($p = 0.02$). **Conclusions:** Our results suggested better detection rate in C-11 choline for well differentiated HCC than F-18 FDG PET. However, the overall detection rate of PET/CT with both tracers could not compare with contrast-enhanced CT and MRI.

Keywords: HCC - diagnosis - PET/CT - choline - FDG - MRI - CT

Asian Pac J Cancer Prev, 17 (7), 3569-3573

Introduction

Hepatocellular carcinoma (HCC) is a leading cause of cancer deaths among men and women worldwide (Parkin, 2002). According to the National Cancer Institute of Thailand, during 1998-2000, HCC was the most frequently found type of cancer in men, while the 3rd most common cancer in women after cervical cancer and breast cancer (Attasara, 2010). Advances in therapeutic techniques make it possible for curative treatment in almost a third of patients provided that the cancer is detected at an early enough stage (Kanwal et al., 2012).

Diagnostic imaging has now become the mainstay of HCC diagnostic evaluation. A liver nodule larger than 2 cm with a typical vascular enhancement pattern on dynamic CT or MRI is considered diagnostic HCC without the need for histological confirmation, making it one of the few tumors that can be diagnosed by radiological imaging alone (Bruix et al., 2005). However, CT and MRI are not

without limits. Sensitivity for detection varies from as low as 36% to >90% for HCC lesions less than 2 cm and even lower for lesions less than 1 cm in size (Bolog et al., 2011).

Metabolic imaging with F-18 FDG PET/CT has been a very successful modality for detection, staging and restaging various cancers with excellent sensitivity and specificity in certain cancers (Kelloff et al., 2005). However, earlier studies of F-18 FDG PET/CT for HCC detection reported only the moderate sensitivity of about 50% to 60% (Khan et al., 2000; Jeng et al., 2003; Lin et al., 2005; Yamamoto et al., 2008). One study revealed even poorer performance with F-18 FDG PET/CT for failure to detect any HCC lesions that were otherwise detectable by other imaging modalities (Teefey et al., 2003). Whereas, another study suggested that F-18 FDG PET/CT is of limited value in tumors less than 5 cm in size (Wolfort et al., 2010). This may be due to the fact that there is high uptake of F-18 FDG in the normal liver and relatively low uptake of HCC compared with other

National Cyclotron and PET Centre, ²Medical Imaging Unit, ³Pathology Unit, Chulabhorn Hospital, Bangkok, Thailand *For correspondence: Chanisa.ja@gmail.com

malignant liver tumors (Iwata et al., 2000). Moreover, tumor differentiation is one important factor determining F-18 FDG uptake, with well-differentiated tumors being less avid and thus less likely to be detected (Khan et al., 2000).

Choline is incorporated into phosphatidylcholine, a major membrane phospholipid in mammalian cells. It thus stands to reason that malignant tumors with increased cellular proliferation take up more choline than in normal cells (Glunde et al., 2011). C-11 Choline has been synthesized and first experimented on brain tumor PET imaging (Hara et al., 1997). It later evolved as an imaging agent for prostate cancer. Currently, C-11 choline PET/CT has been proven superior to F-18 FDG PET/CT in prostate cancer with biochemical relapse (Picchio and Castellucci, 2012). Nonetheless, there are few studies on the diagnostic performance of C-11 Choline PET/CT for HCC detection. One study found that C-11 Choline PET/CT was slightly better than F-18 FDG PET/CT for the detection of HCC, especially in those with moderate differentiation, but this study was only retrospective in nature and did not compare the sensitivity with CT or MRI (Yamamoto et al., 2008). Hence, the purpose of our study is to prospectively investigate the feasibility of C-11 choline PET/CT, compared with F-18 FDG PET/CT, Gadoxetic acid-enhanced MRI, and dynamic contrast-enhanced 64-slice multidetector CT, for HCC detection. We hypothesized that the radiopharmaceutical C-11 choline may be of value to complement F-18 FDG in imaging HCC patients.

Materials and Methods

The study was approved by Chulabhorn Institutional Review Board and written informed consent was obtained. There is no financial conflict of interest.

Patients

Patients with suspected hepatocellular carcinoma by abdominal ultrasonography findings and sent for further diagnostic imaging at the National Cyclotron and PET Centre, Chulabhorn Hospital were consecutively recruited during October 2011 - September 2012. Informed consent was obtained from all patients prior to the enrollment.

Imaging procedures

All enrolled patients underwent 4 cross-sectional imaging modalities, including C-11 choline whole-body PET/CT, F-18 fluorodeoxy glucose (FDG) whole-body PET/CT, gadoxetic acid-enhanced liver MRI, and contrast-enhanced liver CT.

C-11 choline and F-18 FDG PET/CT

Patients were instructed to fast for 6 hours prior to the radiopharmaceutical administration. Fasting plasma glucose was obtained prior to the examination. PET/CT imaging was performed using Siemens Biograph 16 PET/CT system in 4D scanning mode 5 minutes after intravenous injection of 6 MBq/kg C-11 choline and 90 minutes after intravenous injection of 5 mBq/kg F-18 fluorodeoxy glucose. The field-of-view covered the skull

base to proximal thigh for 3 minutes per bed position. Iterative image reconstruction with 4 iterations and 8 subsets was used. The matrix size was 168 with zoom set at 1 and 5.0 FWHM Gaussian filter.

Gadoxetic acid-enhanced liver MRI

Contrast-enhanced liver MRI was performed using 3 Tesla MRI. Each patient was intravenously injected with 0.025 mmol/kg of gadoxetic acid. Imaging was done in regular sequences with the addition of hepatobiliary phase.

Contrast-enhanced liver CT

Patients underwent four-phase CT scan of the liver, including non-contrast scan phase, late-arterial phase, venous phase, and 5-minute delayed phase. The scans were completed using 64-slice multidetector CT scanner. Intravenous contrast media was administered at a rate of 3 mL/min.

Image analysis

Choline and FDG PET/CT images were visually inspected by two nuclear medicine physicians blinded to CT and MRI findings. Quantitative measurement of the tumor-to-background (T/B) ratio was also conducted. Any areas in the liver with increased, non-physiological uptake were defined as tumor by consensus between the two physicians. The T/B ratio was then calculated by measuring the average standardized uptake value (SUVmean) over the tumor lesion and divided by the SUVmean of surrounding liver parenchyma obtained from the average SUVmean measurements of 3 liver regions with the same volume.

Histopathological diagnosis

Tissues for pathological diagnosis were obtained by either resection of the tumor or needle biopsy. A pathologist graded the tumor as well-differentiated (grades I and II), moderately differentiated (grade III), and poorly differentiated (grade IV).

Statistical analysis

The T/B ratios were expressed as mean \pm SD. Independent T-test was used to compare the T/B ratio between well-differentiated and non-well-differentiated HCCs. A p-value of less than 0.05 was considered statistically significant.

Results

During the study period, 12 patients with suspected HCC from ultrasonography were sent for evaluation. Patient characteristics were listed in Table 1. Three patients were excluded due to lack of histopathological confirmation. Of the remaining 9 patients, 6 had well-differentiated, followed by 2 and 1 patient(s) with moderately differentiated and poorly differentiated HCC, respectively. All tumors were detected on both MRI and CT scan with 100% concordance rate and average tumor size of 5.7 \pm 3.8 cm. The tumor lesions of 5 patients were detected on both C-11 choline and F-18 FDG PET/CT, while 1 patient with a 3.4 cm well-differentiated HCC

had negative results by both radiopharmaceuticals. Two patients had HCC with avidity only to C-11 choline; whilst, one patient with a 7.7 cm moderately differentiated HCC showed no C-11 choline uptake despite intense F-18 FDG avidity. Thus, the overall detection rate for C-11 choline and F-18 FDG were 78% (7 out of 9) and 67% (6 out of 9), respectively. Figure 1 demonstrated discrepant the findings between F-18 FDG and C-11 choline tumor uptake in patients with large HCCs demonstrated on CT scan. The three patients with negative results by F-18 FDG all had well-differentiated tumors. However, F-18 FDG PET/CT successfully detected 100% of non-well-differentiated HCC (3 out of 3). Also, the detection rate

of C-11 choline PET/CT for well-differentiated HCC was 83% (5 out of 6). Table 1 summarized the characteristics of HCC lesions in our study.

Overall, the average T/B ratios of HCC lesions for C-11 choline and F-18 FDG were 1.80 ± 0.68 and 2.09 ± 1.50 , respectively. The average T/B ratio of C-11 choline in patients with well-differentiated HCC was higher than those with moderately and poorly differentiated tumors. These differences, however, were not statistically significant ($p = 0.5$). In contrast, the average T/B ratio of F-18 FDG in moderately and poorly differentiated HCC were statistically higher than in well differentiated HCC ($p = 0.027$).

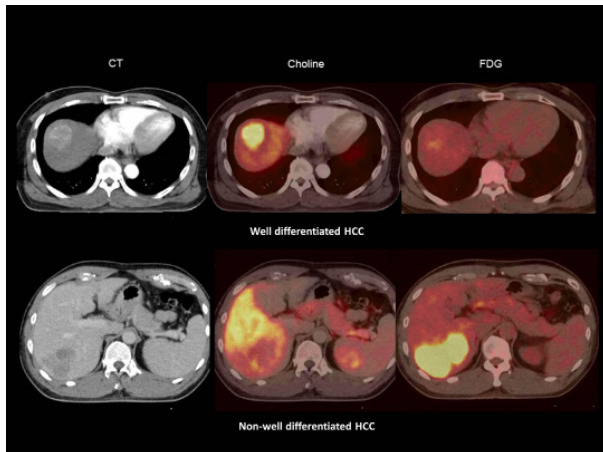


Figure 1 Imaging Findings. Two patients with HCC demonstrated on contrast-enhanced CT, the first row shows C-11 choline avid well-differentiated HCC lesion which demonstrates almost no F-18 FDG uptake. The second row shows a large moderately differentiated HCC which demonstrates intense F-18 FDG uptake but no C-11 choline uptake

Table 1. Patient Characteristics

Characteristics	Number (%)
Sex	
Male	7 (78)
Female	2 (12)
Age (years)	
Mean	54.2
Range	43 – 62
Histology	
Well differentiated	6 (67)
Moderately differentiated	2 (22)
Poorly differentiated	1 (11)

Table 2. PET/CT and Histopathological Characteristics of HCC Lesions

Differentiation	Subject	Tumor size (cm)	Grade	T/B	FDG			Choline			
					Mean T/B	SD	95%CI of difference	T/B	Mean	SD	95%CI of difference
Well-differentiated	1	1.6	I	1.08	1.36*	0.29	-4.03 to -0.34	1.43	1.9	0.74	-0.90 to 1.55
	2	1.6	I	1.60				1.57			
	3	7.2	II	1.30				1.82			
	4	3.4	II	1.00				1.00			
	5	4.5	II	1.74				2.73			
	6	13.4	II	1.45				2.85			
Non-well-differentiated	7	8.4	III	3.21	3.54	2.01	2.03	1.58	0.63		
	8	7.7	III	5.71			0.86				
	9	4.0	IV	1.73			1.84				
All					2.09	1.5		1.8	0.68		

*P=0.027

Discussion

In this study we investigated the diagnostic value of C-11 choline PET/CT for the evaluation of patients with HCC. The strength of our study is on the comparison of C-11 choline PET/CT head-to-head with 3 other imaging modalities, including F-18 FDG PET/CT, contrast-enhanced liver MRI, and CT scanning using histopathological confirmation as the gold standard. Although limited by the small number of subjects, the findings demonstrated the variation of tumor metabolism of HCC, similar to F-18 FDG and C-11 choline uptake. The short-comings of F-18 FDG for detection of HCC lesions has been well established in previous studies (Khan et al., 2000; Jeng et al., 2003; Teefey et al., 2003; Lin et al., 2005; Yamamoto et al., 2008; Wolfort et al., 2010) and has also been shown in this study with the overall F-18 FDG sensitivity of only 67%. However, F-18 FDG PET/CT successfully detected all three non-well-differentiated tumors, partly due to the fact that all three tumors are of relatively large size. Meanwhile, the degree of F-18 FDG avidity for non-well-differentiated HCC was statistically higher than for well-differentiated tumors. Our findings concurred with the convention that F-18 FDG sensitivity is often dependent on tumor differentiation with better sensitivity for less well-differentiated tumors that likely to have increased glucose utilization, resulting in increased avidity to F-18 FDG. Thus, the radiopharmaceutical C-11 choline has been developed for tumor imaging. By incorporation into cell membrane components, the radiopharmaceutical theoretically should be avidly taken up by tissues with high cell proliferation rate such

as malignant tumors. It has been then well established as a promising imaging agent in prostate cancer with biochemical relapse. Nonetheless, one limitation of using C-11 choline is the requirement of an on-site cyclotron. As well, the development of fluorine-based radiotracer may be more practical. Imaging characteristics of C-11 choline and F-18 fluoroethylcholine has therefore been compared using the animal models of HCC, with similar imaging characteristics of the two tracers (Kolthammer et al., 2011).

Likewise, an in vitro study demonstrated that choline uptake in HCC occurred through the choline transporter and the incorporation of choline into phosphocholine (Kuang et al., 2010). Previous studies have as well evaluated choline PET tracers for HCC detection and demonstrated varying detection rates of 66% to 100% (Talbot et al., 2006; Talbot et al., 2010; Wu et al., 2011; Fartoux et al., 2012; Bieze et al., 2014; Castilla et al., 2015; Lopci et al., 2015). In this study we found that C-11 choline PET/CT had only slightly better overall sensitivity of 78% for detection of HCC compared with F-18 FDG PET/CT, compatible with most previous studies that revealed only slight or non-significant superiority of choline PET to F-18 FDG PET/CT in HCC. The detection rate found by Wu et al was 61% for F-18 FDG and 71% for C-11 choline (Wu et al., 2011). Talbot et al showed that F-18 fluoroethylcholine had higher sensitivity than F-18 FDG (88% vs 68%), but no statistically significant difference (Talbot et al., 2006). Our study illustrated the degree of tumor uptake of C-11 choline for well-differentiated tumors to be slightly higher than non-well-differentiated tumors, but not statistically significant, probably due to the small sample size. In the meantime, similar findings were observed in previous studies showing that choline tracers had a propensity for accumulation in well-differentiated HCC, while less differentiated HCC was more avid to F-18 FDG (Yamamoto et al., 2008; Talbot et al., 2010; Wu et al., 2011). So, the seemingly complementary nature of F-18 FDG and choline PET tracers has led to the investigation of using both of these tracers in dual-tracer PET studies (Castilla et al., 2015). Wu et al found the improved detection rate from 63% using F-18 FDG alone to 89.5% using both F-18 FDG and C-11 choline (Wu et al., 2011). Our study revealed similar findings with 88% sensitivity by dual-tracer PET which was higher than either tracer alone.

Interestingly, both F-18 FDG and C-11 choline PET/CT had inferior diagnostic performance than CT and MRI for the detection of HCC lesion. Large lesions failed to be detected by one or both of the radiopharmaceuticals, while small lesions were detected by both CT and MRI imaging. The findings could support the use of dynamic anatomical imaging including CT and MRI as the primary modality for evaluating primary tumors in HCC patients. Although PET/CT in this study showed no significant extrahepatic disease for the alteration of patient management, the advantage of PET/CT being a whole body imaging leads to the possibility of distant metastasis identification. Lopci found that C-11 choline PET had less accuracy than CT or MRI for the detection of liver lesions (66% versus 85%), while the opposite

was true for the detection of extrahepatic lesions which C-11 choline greatly out-performed CT or MRI (99% versus 32%) (Lopci et al., 2015). Another similar finding was found in one study where C-11 choline had 100% accuracy for the identification of extrahepatic lesions (Bieze et al., 2014). Additionally, PET/CT with both tracers may offer prognostic value. Fartoux noted that HCC patients with good avidity to F-18 FDG but poor avidity to F-18 fluoroethylcholine had a greater chance of recurrence after surgical resection. This may be related to the tumor differentiation with FDG-avid lesion that more likely to be less differentiated, concurring with our results (Fartoux et al., 2012). However, further studies should be recommended to explore the use of PET/CT by either F-18 FDG or C-11 choline for the evaluation of distant metastasis, as well as to solidify the role of these functioning imaging techniques in term of prognostic value.

In conclusion, Our results suggested that C-11 choline seems to have better detection rate for well differentiated HCC; whereas, F-18 FDG PET yields a better detection rate for moderately and poorly differentiated HCC. However, the overall detection rate of PET/CT by both radiopharmaceuticals is inferior to hepatic CT and MRI.

Acknowledgements

The present study was supported by Chulabhorn Hospital research funding.

References

- Bieze M, Klumpen HJ, Verheij J, et al (2014). Diagnostic accuracy of (18) F-methylcholine positron emission tomography/computed tomography for intra- and extrahepatic hepatocellular carcinoma. *Hepatol*, **59**, 996-1006.
- Bolog N, Andreisek G, Oancea I, et al (2011). CT and MR imaging of hepatocellular carcinoma. *J Gastrointest Liver Dis*, **20**, 181-9.
- Bruix J, Sherman M, Practice Guidelines Committee AAftSoLD (2005). Management of hepatocellular carcinoma. *Hepatol*, **42**, 1208-36.
- Castilla-Lievre MA, Franco D, Gervais P, et al (2016). Diagnostic value of combining C-choline and F-FDG PET/CT in hepatocellular carcinoma. *Eur J Nucl Med Mol Imaging*, **43**, 852-9.
- Fartoux L, Balogova S, Nataf V, et al (2012). A pilot comparison of 18F-fluorodeoxyglucose and 18F-fluoroethylcholine PET/CT to predict early recurrence of unifocal hepatocellular carcinoma after surgical resection. *Nucl Med Commun*, **33**, 757-65.
- Glunde K, Bhujwala ZM, Ronen SM (2011). Choline metabolism in malignant transformation. *Nat Rev Cancer*, **11**, 835-48.
- Hara T, Kosaka N, Shinoura N, et al (1997). PET imaging of brain tumor with [methyl-11C]choline. *J Nucl Med*, **38**, 842-7.
- Iwata Y, Shiomi S, Sasaki N, et al (2000). Clinical usefulness of positron emission tomography with fluorine-18-fluorodeoxyglucose in the diagnosis of liver tumors. *Ann Nucl Med*, **14**, 121-6.
- Jeng LB, Changlai SP, Shen YY, et al (2003). Limited value of 18F-2-deoxyglucose positron emission tomography to detect hepatocellular carcinoma in hepatitis B virus carriers. *Hepato gastroenterol*, **50**, 2154-6.

- Kanwal F, Befeler A, Chari RS, et al (2012). Potentially curative treatment in patients with hepatocellular cancer--results from the liver cancer research network. *Aliment Pharmacol Ther*, **36**, 257-65.
- Kelloff GJ, Hoffman JM, Johnson B, et al (2005). Progress and promise of FDG-PET imaging for cancer patient management and oncologic drug development. *Clin Cancer Res*, **11**, 2785-808.
- Khan MA, Combs CS, Brunt EM, et al (2000). Positron emission tomography scanning in the evaluation of hepatocellular carcinoma. *J Hepatol*, **32**, 792-7.
- Kolthammer JA, Corn DJ, Tenley N, et al (2011). PET imaging of hepatocellular carcinoma with 18F-fluoroethylcholine and 11C-choline. *Eur J Nucl Med Mol Imaging*, **38**, 1248-56.
- Kuang Y, Salem N, Corn DJ, et al (2010). Transport and metabolism of radiolabeled choline in hepatocellular carcinoma. *Mol Pharm*, **7**, 2077-92.
- Lin WY, Tsai SC, Hung GU (2005). Value of delayed 18F-FDG-PET imaging in the detection of hepatocellular carcinoma. *Nucl Med Commun*, **26**, 315-21.
- Lopci E, Torzilli G, Poretti D, et al (2015). Diagnostic accuracy of (1)(1)C-choline PET/CT in comparison with CT and/or MRI in patients with hepatocellular carcinoma. *Eur J Nucl Med Mol Imaging*, **42**, 1399-407.
- Picchio M, Castellucci P (2012). Clinical indications of C-choline PET/CT in prostate cancer patients with biochemical relapse. *Theranostics*, **2**, 313-7.
- Talbot JN, Fartoux L, Balogova S, et al (2010). Detection of hepatocellular carcinoma with PET/CT: a prospective comparison of 18F-fluorocholine and 18F-FDG in patients with cirrhosis or chronic liver disease. *J Nucl Med*, **51**, 1699-706.
- Talbot JN, Gutman F, Fartoux L, et al (2006). PET/CT in patients with hepatocellular carcinoma using [(18)F]fluorocholine: preliminary comparison with [(18)F]FDG PET/CT. *Eur J Nucl Med Mol Imaging*, **33**, 1285-9.
- Teefey SA, Hildeboldt CC, Dehdashti F, et al (2003). Detection of primary hepatic malignancy in liver transplant candidates: prospective comparison of CT, MR imaging, US, and PET. *Radiol*, **226**, 533-42.
- Wolford RM, Papillion PW, Turnage RH, et al (2010). Role of FDG-PET in the evaluation and staging of hepatocellular carcinoma with comparison of tumor size, AFP level, and histologic grade. *Int Surg*, **95**, 67-75.
- Wu HB, Wang QS, Li BY, et al (2011). F-18 FDG in conjunction with 11C-choline PET/CT in the diagnosis of hepatocellular carcinoma. *Clin Nucl Med*, **36**, 1092-7.
- Yamamoto Y, Nishiyama Y, Kameyama R, et al (2008). Detection of hepatocellular carcinoma using 11C-choline PET: comparison with 18F-FDG PET. *J Nucl Med*, **49**, 1245-8.