

## RESEARCH ARTICLE

# Clinical Application of Ultrasound-Guided Thyroid Fine Needle Aspiration Biopsy and Thinprep Cytology Test in Diagnosis of Thyroid Disease

Ying Wei, Yao Lu\*, Chenxi Li

### Abstract

**Purpose:** To study the clinical application value of ultrasound guided thyroid fine needle aspiration biopsy and thinprep cytology testing in diagnosis of thyroid disease. **Methods:** A total of 78 patients with thyroid nodules were enrolled, 34 males and 44 females, aged 33-64 years old with mean age of 47.6 years. All underwent thyroid nodule fine needle puncture after surgery to assess cell pathology and histopathological features. **Results:** Sufficient specimens were obtained from all of 78 patients, the cytological results of 73 cases (93.6 %) being consistent with pathological results. While 20 cases (25.6 %) were malignant tumors, 44 (56.4 %) were benign and 9 (11.5 %) were non-tumor lesions. The sensitivity of benign and malignant thyroid nodule by thyroid fine needle puncture was 90.9 %, specificity was 98.1 % and the positive predictive value was 96.3 %. **Conclusions:** It is demonstrated that ultrasound-guided thyroid fine needle aspiration biopsy and thinprep cytology testing have diagnostic value in clinical application for thyroid disease, showing good diagnostic coincidence rates with histopathological examination. They can thus be regarded as safe and effective for preoperative diagnosis and providing an appropriate basis for selection of surgery.

**Keywords:** Ultrasound guided- thyroid nodule- fine needle aspiration biopsy- thinprep cytology test- histopathology

*Asian Pac J Cancer Prev*, 17 (10), 4689-4692

### Introduction

Thyroid nodule (TN) is one of the most common diseases occurred on the thyroid, and showing an apparently increasing trend. It has been reported that the prevalence rate in thyroid assessed by palpation is approximately 3 %~7 % (Tae et al., 2007). Ultrasonic diagnosis found that 30 %~50 % of people suffered from TN. Fine-needle aspiration biopsy (FNAB) which was used to efficiently characterize the pathogenicity, to determine the diagnosis, and to guide the treatment, is the conventional method for diagnosis of goiter and thyroid nodal diseases. Thinprep cytology test (TCT) uses a filtration process and thin-layer deposition of cells, which offers better cell preservation, by preserving drop-off cells into liquid through mechanical, pneumatic, and hydromechanics. The first choice of TN prognosis is FNAB, however, FNAB combining with TCT, increase the diagnostic rate obviously pre-operation for the timely treatment, and reduce efficiently unnecessary thyroid surgery, consequently decrease the pain in patients and financial burden.

In present study, 78 TN patients diagnosed by FNAB and TCT in Heilongjiang Land Reclamation Hospital from 2012 to 2014 in were retrospectively studied, follow-up visited, and discussed on the clinical value of FNAB and

TCT.

### Material and Methods

#### *Clinical data*

Our study enrolled 78 patients with suspicious TN (34 patients were male, 44 patients were female). Age at presentation was ranged from 33~66 years (mean age 47.6). Among them, 37 cases were solitary nodule, while others were multiple nodules. Fifty four cases did not show any clinical symptoms, while 24 cases were diagnosed with the anterior portion neoplasm. All the pathogenicity of patients were diagnosed and confirmed by FNAB and TCT.

Indications for TN fine-needle puncture: (American Thyroid Association Guidelines Taskforce on Thyroid et al., 2009) solid hypoechoic nodule with diameter greater than 10 mm; (Andrioli and Persani, 2014) or nodule was ultrasonic-examined with relative symptom of malignant lesions, though diameter was less than 10 mm; (Cesur et al., 2006) result of ultrasonic-examination suspected that any sizes of TN grown in extracapsular or transferred from cervical lymph nodule. (Cusick et al., 1990) regarding multinodular goiter, the number of nodule should be examined with FNAB rarely required more than 2, while the symptom of nodule was accord with above-mentioned

Heilongjiang Land Reclamation Bureau General Hospital, Department of physical Diagnosis, Haerbin, China. \*For correspondence: luyaochina54321@163.com

ultrasonic-examined malignant signs.

*Ultrasonic-guided puncturing technique*

All prebiopsy diagnostic ultrasonic studies were performed by ultrasound diagnostic equipment Philips iU22 using a 5-12 MHz linear-array transducer. Thyroid gland evaluation was performed using grayscale and color Doppler examinations by standard equipment setting. The ultra-sonic images of TN were obtained from the picture archiving and communication system and observed by an attending radiologist. The following sonographic feature of TN was assessed: position, size, property, and surrounding blood flow; body surface location were assessed for lesion tissue or focal lesion, and meanwhile, inserting depth into needle were also measured.

The anterior region of neck was groovy disinfected, and narcotized topically. 5 ml injection syringe were punctured rapidly into TN, and the sample was obtained by the needle moving up and down for 20 times; the organization in syringe were transferred on the object slide and fixed. The exfoliated cells were preserved in liquid, and attached dispersedly onto object slide for smear preparation.

*Cytopathological examinations*

Data of cytopathological examinations were divided into four groups: benign, malignancy, suspected malignancy, or non-diagnostic smear (Yang et al., 2007). Smear was defined as non-diagnostic if it did not have more than 6 groupings of at least 10 thyroid follicular cells each. Malignancy was defined as lesion with character of malignant cell. Suspected malignancy included follicular lesion or several character of thyroid cancerization, such as cells with intra-nuclear inclusion bodies or nuclear groove, however, this definition has not yet to be a diagnostic criteria.

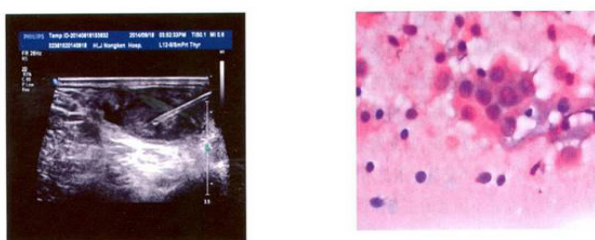


Figure 1. Ultrasonography and Puncture Cytology Image of 62 Year Old Male Patient with Thyroid Papillary Carcinoma

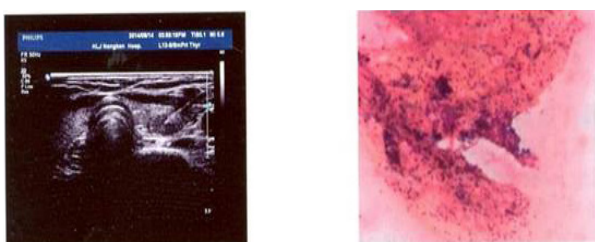


Figure 2. Ultrasonography and Histopathology Images of 50 Year Old Female Patient with Nodular Goiter

Follow-up histopathological test and tumors classification

Focal lesion tissue was histopathological examined post-operation.

Classification criterion of thyroid tumors: (American Thyroid Association Guidelines Taskforce on Thyroid et al., 2009) benign lesion included nodular goiter, subacute thyroiditis, simple goiter, hashimoto disease, and thyroid adenoma; (Andrioli and Persani, 2014) malignant lesions included papillary thyroid carcinoma, follicular thyroid carcinoma, and medullary thyroid carcinoma.

**Results**

*Cytodiagnosis data*

In present study, 55.0 patients (70.5 % of total 78 patients) were diagnosed as benign based on FNAB and TCT, while 21 patients (26.9 %) were diagnosed as malignant. Two samples were sorted into non-diagnostic smear. This data is confirmed by pathologic results in which 54 patients were diagnosed as benign, and 22 patients were diagnosed as malignant (Table.1).

Comparison of diagnosis result between aspiration cytology and histopathology

In total 55 patients with benign lesion diagnosed by cytological examination, 53 were confirmed by histopathologic examination post-operation. Among them, 38 patients were diagnosed as nodular goiter, 9 were chronic lymphocytic thyroiditis, and 6 were thyroid adenoma, respectively; the remaining 2 patient were diagnosed as papillary thyroid carcinoma (Figure 1). Twenty one malignant lesion tissue diagnosed by cytology were resected without exception. Among them, 20 were malignancy confirmed by histopathologic examination post-operation: 16 cases were papillary thyroid carcinoma, while 4 cases were medullary thyroid carcinoma. Remaining 1 benign case was nodular goiter (Figure 2). Within 2 cases with non-diagnostic smear, one of patients was operated and confirmed as nodular goiter by lesion tissue histopathologic examination post-operation; another one was arranged follow-up ultrasonic visit semiannually, the result showed that the TN did not show significant changes (Table 2).

**Discussion**

In present study, thyroid fine-needle puncture biopsy was performed under guidance of ultra-sonic, to guarantee the insertion angle and depth and avoid injuring surrounding organs and vessels, and consequently met the demand of pathological diagnosis. Fine-needle puncture biopsy was the most reliable and valuable diagnosis method to identify the benign and malignant (Andrioli

Table 1. Comparison of Diagnosis Result between Puncture Cytology and Post-Operation Pathology

Aspiration cytology	Post-operation Pathology	
	Benign	Magnlinant
Benign	53	2
Magnlinant	1	20

Table 2. Comparison of Examination Results between Puncture Cytology and Histopathology.

Aspiration cytology	nodular goiter	Post -operation Pathology			Consistency rate (%)
		thyroid adenoma	chronic lymphocytic thyroiditis	thyroid carcinoma	
nodular goiter	38	0	0	2	95
thyroid adenoma	0	6	0	0	100
chronic lymphocytic thyroiditis	0	0	9	0	100
thyroid carcinoma	1	0	0	20	95

and Persani, 2014; Zhao, 2010), with the sensitivity of 83%, specificity of 92% and accuracy rate of 95%, and hence every patient with suspected TN malignant lesions should be conducted with fine-needle puncture biopsy.

High-resolution ultra-sonic is generally considered as the most efficient and safe diagnosis to distinguish the benign and malignant of TN (Zhang et al., 2015). Compared to conventional diagnosis, the routine utilization of ultra-sonic guided FNAB was capable of decreasing the rates of non-diagnostic sampling and false-negative aspirates because of selective specific nodules, resulting in an overall decline in the number of needless surgeries conducted to TN patients (American Thyroid Association Guidelines Taskforce on Thyroid et al., 2009; Danese et al., 1998; Cesur et al., 2006). In present study, 21 cases in these retrospectively studied 78 patients were diagnosed as malignant. Among them, 16 cases were papillary thyroid carcinoma, 4 cases were medullary carcinoma, and 1 case was benign TN. These diagnosis results did not show any corresponding with that of cytological examination. It has been reported that the false positive rate of thyroid FNAB were 3~5% (Cusick et al., 1990); the false negative rate were 2~19 %. The main reasons includes: (American Thyroid Association Guidelines Taskforce on Thyroid et al., 2009) needle is too fine to provide the enough cellular sample; (Andrioli and Persani, 2014) lesion tissue was not extracted in puncturing; (Cesur et al., 2006) boundedness of cytology; (Cusick et al., 1990) non-proficiency of manual operational techniques. Reasons (American Thyroid Association Guidelines Taskforce on Thyroid et al., 2009) and (Cusick et al., 1990) were the major reasons resulting in non-diagnosed smear.

In the diagnosis criteria of TN cytology, the features of benign lesion included mass rarefied colloid, schistose, follicular single layer formed by small and round follicular cells; macrophage containing hemosiderin, the number of which is associated with whether there existed retrogression or cystic degeneration (Zheng et al., 2010). Character of malignancy lesion includes nucleus enlargement or irregularity in papillocarcinoma, thin pulverulent chromatin, visible nucleolus, nuclear groove, or intra-nuclear inclusions. Compared to conventional cytological smear methods, the background cell of TCT smear reduced significantly; colloid decreased and were liable to present a densely stained water-drop shapes instead of diffuse-distributed membrane; cellular nucleus always small but observable for nuclear membrane, chromatin, and nucleolus. In addition, the positive rate of TCT is higher than that of conventional cytological

examination. Li et al found that diagnosis efficiency of TCT is 66.7 % which close to that of conventional cytological examination (Frost et al., 1998). Frost AR et al found that 1.0~2.0 TCT smears could meet the demand of FNAB diagnosis.

In conclusion, ultrasound guided FNAB has become the most essential diagnosis method of thyroid disease, besides, involvement of TCT examination increased the positive rate of conventional smear cytology. However, the accuracy of ultrasound FNAB was similar with that of conventional diagnosis, which is so-called 'golden standard' of property determination and treatment of TN (Shi, 2010). As a consequence, ultra-sonic guided FNAB combined with TCT examination displayed a high clinical application value in the pre-operative diagnosis of most thyroid diseases.

## Acknowledgements

There are no funds or financial grants needing to be acknowledged.

## References

- American Thyroid Association Guidelines Taskforce on Thyroid N Differentiated Thyroid C, Cooper DS, Doherty GM, et al (2009). Revised American Thyroid Association management guidelines for patients with thyroid nodules and differentiated thyroid cancer. *Thyroid*, **19**, 1167-214.
  - Andrioli M, Persani L (2014). Elastographic techniques of thyroid gland: current status. *Endocr*, **46**, 455-61.
  - Cesur M, Corapcioglu D, Bulut S, et al. (2006). Comparison of palpation-guided fine-needle aspiration biopsy to ultrasound-guided fine-needle aspiration biopsy in the evaluation of thyroid nodules. *Thyroid*, **16**, 555-61.
  - Cusick EL, MacIntosh CA, Krukowski ZH, et al (1990). Management of isolated thyroid swellings: a prospective six year study of fine needle aspiration cytology in diagnosis. *Br Med J*, **301**, 318-21.
  - Danese D, Sciacchitano S, Farsetti A, et al (1998). Diagnostic accuracy of conventional versus sonography-guided fine-needle aspiration biopsy of thyroid nodules. *Thyroid*, **8**, 15-21.
  - Frost AR, Sidawy MK, Ferfelli M, et al (1998). Utility of thin-layer preparations in thyroid fine-needle aspiration: diagnostic accuracy, cytomorphology, and optimal sample preparation. *Cancer*, **84**, 17-25.
  - Shi B (2010). Standardization of management of thyroid nodule and cancer should be vigorously implemented. *Chin J End Met*, **26**, 833-34.
  - Tae HJ, Lim DJ, Baek KH, et al (2007). Diagnostic value of ultrasonography to distinguish between benign and
- Asian Pacific Journal of Cancer Prevention, Vol 17* **4691**

- malignant lesions in the management of thyroid nodules. *Thyroid*, **17**, 461-6.
- Yang J, Schnadig V, Logrono R, et al (2007). Fine-needle aspiration of thyroid nodules: a study of 4703 patients with histologic and clinical correlations. *Cancer*, **111**, 306-15.
- Zhang J, Chen Z, Anil G. (2015). Ultrasound-guided thyroid nodule biopsy: outcomes and correlation with imaging features. *Clin Imaging*, **39**, 200-6.
- Zhao Y. (2010). The current status on ultrasonic diagnosis of thyroid carcinoma. *Med Rec*, **16**, 835-37.
- Zheng JY, Bai T, Zhang YF, et al. (2010). [Cytology diagnosis and clinical management of fine-needle aspiration for thyroid nodules]. *Zhonghua Bing Li Xue Za Zhi*, **39**, 349-52.