

## REVIEW

# Current Trends in Management of Oral Mucositis in Cancer Treatment

**Abhishek Shankar<sup>1\*</sup>, Shubham Roy<sup>2</sup>, Menal Bhandari<sup>3</sup>, GK Rath<sup>3</sup>, Aalekhya Sharma Biswas<sup>4</sup>, Ravi Kanodia<sup>3</sup>, Narayan Adhikari<sup>3</sup>, Rashika Sachan<sup>3</sup>**

### Abstract

Oral Mucositis (OM) is among the most common and dreaded toxicities of cancer therapy. It occurs in almost all patients who receive radiation therapy in which areas of oral and oropharyngeal mucosa are included in the treatment field. With the advent of chemotherapy in 1940 and its extended clinical legacy, it is only within the past two decade or so that mucositis' complex pathobiology has become fully appreciated. There are still many unanswered questions about the risk factors for developing OM, but historically, risk factors have been attributed to both therapy and patient characteristics. One thing that has been consistent from the initial descriptions of its clinical manifestations has been the frustration on the part of clinicians and patients with the scarcity of therapeutic options to prevent or treat the condition, or effectively ameliorate the symptoms. Clinicians, researchers and those involved in oral and periodontal medicine should join hand in hand in pursuit of understanding and developing treatment strategies for treatment of inflammatory conditions like OM in oncology. This will lead to development of effective treatments and reducing the burden of OM and other inflammatory conditions in oncology.

**Keywords:** Oral Mucositis- cancer- treatment

*Asian Pac J Cancer Prev*, **18 (8)**, 2019-2026

### Introduction

Since Madame Curie discovered radium in 1897 and the application of radiation to treat cancers in the days before World War I, injury to the mucosal surfaces of the mouth (Oral Mucositis or OM) has been a prominent toxicity of anti-tumor therapies. With the advent of chemotherapy in 1940 the etiology of mucositis broadened. Despite its extended clinical legacy, it is only within the past two decade, the mucositis' complex pathobiology has become fully discovered. One thing that has been consistent from the initial descriptions of its clinical manifestations has been the frustration on the part of clinicians and patients with the scarcity of therapeutic options to prevent or treat the condition, or effectively ameliorate the symptoms. The main challenge is to predict toxicity risk and personalise toxicity interventions for genetically suitable patients. It is essential to clearly understand the mucositis pathobiology and the pharmacogenomics of toxicity. The pre-clinical research and animal models can help to findings for toxicity prediction and attenuation in the clinic.

### Nomenclature

Historically, oral mucosal injury associated with cancer treatment was referred to as stomatitis. However,

because stomatitis was also used to refer to many oral mucosal conditions with etiologies exclusive of cancer treatment-related damage (eg. Infection), a more specific term was needed. Consequently, the term mucositis was recognised as being more appropriate for lesions specifically associated with cytotoxic cancer therapy, and in 2007 was adopted and assigned ICD-9 code of 528.0. The ICD-10 code for oral mucositis is K12.3.

### Clinical Presentation

In its most advanced clinical form, OM presents as confluent, deep, and devastatingly painful ulcerations of oral mucosa. However, like most diseases, mucositis has a clinical continuum. At its beginning stages or in its most mild form, mucositis presents as mucosal erythema and is accompanied by a feeling of burning, not dissimilar to that which result from a bad hot food burn. In some patients who receive selected chemotherapy regimens for the treatment of solid tumors (eg. Breast or colorectal), mucositis may not progress to more severe mucosal changes.

In contrast, many patients go on to develop the more severe and classic form of mucositis which is characterized by ulcerative lesions. The ulcers of mucositis tend to be deeper and markedly more painful than those typically

<sup>1</sup>Department of Preventive Oncology, <sup>3</sup>Department of Radiation Oncology, Dr. B.R. Ambedkar Institute Rotary Cancer Hospital, All India Institute of Medical Sciences, <sup>2</sup>Department of Paediatrics, VMMC and Safdarjung Hospital, Delhi, <sup>4</sup>Maulana Abul Kalam Azad University of Technology, Kolkata, India. \*For Correspondence: doc.abhishankar@gmail.com

associated with cancer sores (aphthous stomatitis) or traumatic lesions. Unlike aphthous stomatitis, mucositis ulcers do not have a typical inflammatory component and so do not have a peripheral ring of erythema. Ulcer development is associated with increased pain and inability to tolerate normal foods. It is not unusual for patients with significant mucositis to exclude solid foods completely. Ulcers may be focal and localised or consolidated and diffuse. Their borders are generally poorly defined.

There are no sentinel sites for lesions of mucositis. Any part of the movable mucosa can be involved, although the buccal mucosa, floor of the mouth, lateral and ventral borders of the tongue and soft palate are most frequently involved. Interestingly, the more heavily keratinised mucosa is usually not involved in mucositis. Thus in cancer patients with ulcerative lesions of the hard palate, dorsal surface of tongue, and gingiva, an etiology other than mucositis should be suspected. Most commonly lesions in these areas are the consequence of viral (herpes simplex) or fungal (candidiasis) etiology.

*The course of mucositis*

The course of mucositis is generally predictable and depends on the cancer treatment associated with its generation.

*Mucositis induced by chemotherapy*

Frequency of chemotherapy induced oral mucositis varies differently among different studies (Al-Azri et al., 2013; Al-Dasooqi et al., 2010). For patients being treated with chemotherapy, the first signs of mucositis usually begin with a feeling of mucosal irritation about 3-4 days after infusion which is accompanied by ulcer development. In a prospective study involving 298 patients treated with chemotherapy for solid tumors, 120 patients (40.3 %) developed WHO grade 1 OM, 15 patients (5 %) showed WHO grade 2, and only 3 patients (1 %) had severe OM (WHO grades 3-4) (Andreassen, 2013).

*Mucositis induced by radiotherapy*

In contrast, mucositis induced by radiation therapy is less acute both in its onset and resolution. Patients begin to develop mucosal soreness by the end of week 1. The intensity of mucositis builds until ulceration occurs, in most cases by the end of week 2 and then consolidates to form confluent mucosal ulcers by the end of third week. In a review of 33 studies involving approximately 6,000 patients, in which the incidence of OM was investigated in patients treated with radiation therapy as well as chemoradiation, the mean incidence of OM was found to be 80 % (Barasch and Peterson, 2003).

*The pathobiology of oral mucositis*

The antineoplastic agents not only affect the cancer cells but also the normal cells of the body. Historically the concept of oral mucositis was simple: since neither chemotherapy nor radiation could differentiate between rapidly dividing (and DNA synthesizing) tumor cells or the rapidly dividing cells of the basal epithelium, these normal cells were killed and replenishment of the normally renewing epithelium was eliminated. But

animal studies have shown that pathobiology of OM is much more complex and it prompted Sonis to propose a model involving connective tissues and epithelial tissues (Bensinger et al., 2008). These have been summarised in a five phase model. Phases include initiation, upregulation and activation, signal amplification, ulceration, an healing.

The Signalling pathway of OM is shown in Figure 1. The initiation phase is characterized by radio or chemotherapy-induced direct DNA injury that results in injury of basal epithelial, submucosal, and endothelial cells. These cells release endogenous damage-associated molecular patterns, which then bind to specific receptors and play an integral role in initiating inflammation and toxicity (Blijlevens and Sonis, 2007). In response to this damage, oxidative stress results in the formation of reactive oxygen species inside injured cells. These further damage cell membranes, stimulate macrophages, and trigger molecules that activate transcription factors, including nuclear factor (NF)-κ B. (Boers-Doets et al., 2012). NF-κ B is the gatekeeper for inflammatory pathways involved in mucositis. Its activation precedes peaks in proinflammatory cytokines such as tumor necrosis factor (TNF)-α, interleukin (IL)-6, and IL-1β, and upregulates cyclooxygenase-2 (COX-2) in submucosal fibroblasts and endothelial cells. (Boers-Doets et al., 2013; Castellani et al., 2014).

Many of the molecules induced by this primary response have the ability to alter the local tissue response through feedback loops. For example, TNF-α activation may generate positive feedback on NF-κB to amplify its response (signal amplification phase) and initiate mitogen-activated protein kinase (MAPK) signaling, leading to activation of c-Jun N-terminal kinase (JNK) signaling (Coracin et al., 2013). NF-κ B independent pathways such as the ceramide pathway also play a role, resulting in apoptosis of submucosal and basal epithelial cells, leading to mucosal ulceration (ulcerative phase). Recent studies suggest the involvement of deregulated expression of metalloproteinases (MMPs) in the pathobiology of mucositis (Castellani et al., 2014; Elting et al., 2013).

The ulcerative phase comprises loss of mucosal integrity and microbiological colonization by oral bacteria. Bacterial cell wall products are capable of

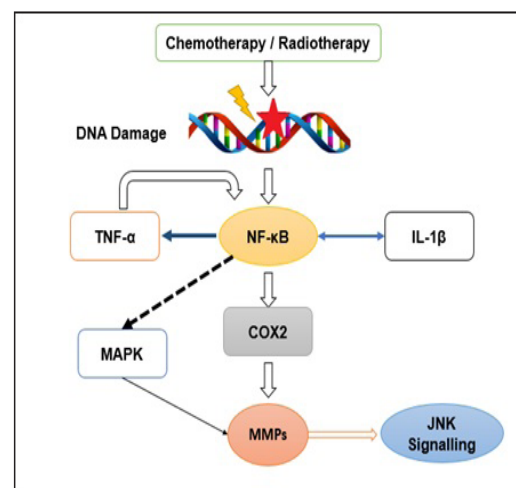


Figure 1. Signalling Pathway of Mucositis

Table 1. Oral Cavity Mucositis Guideline Modified from MASCC/ISOO Clinical Practice Guidelines for Oral Mucositis (Lalla et al, 2014)

Diagnosis	Therapy	Prevention/ Treatment	Intervention
Cancer of any kind	All cancer treatment modalities	Prevention	Oral care protocols: The panel suggests that oral care protocols be used to prevent oral Mucositis in all age groups and across all cancer treatment modalities
		Treatment	Doxepin mouthwash: The panel suggests that 0.5% doxepin mouthwash may be effective to treat pain due to oral Mucositis.
	Bolus 5-fluorouracil chemotherapy	Prevention	Oral cryotherapy: The panel recommends that 30 min of oral cryotherapy be used to prevent oral mucositis in patients receiving bolus 5-fluorouracil chemotherapy.
		Bone marrow transplant	Prevention
	Conventional and high-dose chemotherapy, with or without total body irradiation	Treatment	Transdermal fentanyl: The panel suggests that transdermal fentanyl may be effective to treat pain due to oral mucositis in patients receiving conventional and high-dose chemotherapy, with or without total body irradiation.
		Stem cell transplant	Prevention
	Chemotherapy	Treatment	Morphine: The panel recommends that patient-controlled analgesia with morphine be used to treat pain due to oral mucositis in patients undergoing HSCT.
		Prevention	Sucralfate mouthwash: The panel recommends against that sucralfate mouthwash be used to prevent oral mucositis in patients receiving chemotherapy for cancer.
	Radiation therapy	Treatment	Sucralfate mouthwash: The panel recommends against that sucralfate mouthwash be used to treat oral mucositis in patients receiving radiation therapy.
	Head and neck cancer	Moderate dose radiation therapy without concomitant chemotherapy	Prevention
Prevention			Chlorhexidine mouthwash: The panel suggests against that chlorhexidine mouthwash be used to prevent oral mucositis in patients receiving radiation therapy for head and neck cancer .  Misoprostol mouthwash: The panel suggests against that misoprostol mouthwash be used to prevent oral mucositis in patients receiving radiation therapy for head and neck cancer .  Pilocarpine: The panel suggests against that systemic pilocarpine, administered orally, be used to prevent oral mucositis in patients receiving radiation therapy for head and neck cancer. ,  PTA and BCoG: The panel recommends against that PTA (polymyxin, tobramycin, amphotericin B) and BCoG antimicrobial lozenges and PTA paste be used to prevent oral mucositis in patients receiving radiation therapy for head and neck cancer.
Radiation therapy		Prevention	Chlorhexidine mouthwash: The panel suggests against that chlorhexidine mouthwash be used to prevent oral mucositis in patients receiving radiation therapy for head and neck cancer .  Misoprostol mouthwash: The panel suggests against that misoprostol mouthwash be used to prevent oral mucositis in patients receiving radiation therapy for head and neck cancer .  Pilocarpine: The panel suggests against that systemic pilocarpine, administered orally, be used to prevent oral mucositis in patients receiving radiation therapy for head and neck cancer. ,  PTA and BCoG: The panel recommends against that PTA (polymyxin, tobramycin, amphotericin B) and BCoG antimicrobial lozenges and PTA paste be used to prevent oral mucositis in patients receiving radiation therapy for head and neck cancer.
Treatment		Treatment Morphine mouthwash: The panel suggests that 0.2% morphine mouthwash may be effective to treat pain due to oral mucositis in patients receiving chemoradiation therapy for head and neck cancer.	

Table 1. Continued

Diagnosis	Therapy	Prevention/ Treatment	Intervention
Head and neck cancer	Radiation therapy or concomitant chemoradiation	Prevention	Sucralfate mouthwash: The panel recommends against that sucralfate mouthwash be used to treat oral mucositis in patients receiving radiation therapy for head and neck cancer. Isegran antimicrobial mouthwash: The panel recommends against that isegran antimicrobial mouthwash be used to prevent oral mucositis in patients receiving radiation therapy or concomitant chemoradiation for head and neck cancer. Sucralfate mouthwash: The panel recommends against that sucralfate mouthwash be used to prevent oral mucositis in patients receiving radiation therapy or concomitant chemoradiation for head and neck cancer.
	Radiation therapy, without concomitant chemotherapy	Prevention	Low-level laser therapy: The panel suggests that low-level laser therapy (wavelength around 632.8 nm), be used to prevent oral mucositis in patients undergoing radiotherapy, without concomitant chemotherapy, for head and neck cancer.
	Radiation therapy, without concomitant chemotherapy	Prevention	Low-level laser therapy: The panel suggests that low-level laser therapy (wavelength around 632.8 nm), be used to prevent oral mucositis in patients undergoing radiotherapy, without concomitant chemotherapy, for head and neck cancer.
Hematological malignancy	Stem cell transplant revised from 2014 MASCC/ISOO Guidelines based on current labeling indication	Prevention	KGF-1/palifermin: The panel recommends that recombinant human keratinocyte growth factor-1 (KGF-1/palifermin) be used to prevent oral mucositis (at a dose of 60 µg/kg per day for 3 days before conditioning treatment and for 3 days after transplant) in patients... • Original MASCC/ISOO guideline: receiving high-dose chemotherapy and total body irradiation, followed by autologous stem cell transplantation, for a hematological malignancy. • Updated ESMO guideline:...with hematological malignancy treated with chemotherapy and/or targeted agents, and/or HSCT with or without total body irradiation (TBI) (local–regional radiotherapy alone not included), and who are anticipated to develop grade 3 or grade 4 oral mucositis (National Cancer Institute, 2015) Oral cryotherapy: The panel suggests that oral cryotherapy be used to prevent oral mucositis in patients receiving highdose melphalan, with or without total body irradiation, as conditioning for HSCT
Oral cancer	Radiation therapy or chemoradiation	Prevention	Zinc supplements: The panel suggests that systemic zinc supplements administered orally may be of benefit to prevent oral mucositis in oral cancer patients receiving radiation therapy or chemoradiation.

extending mucosal damage as they stimulate infiltrating macrophages to produce additional pro-inflammatory cytokines.

Healing of ulcerations is associated with epithelial proliferation, often concurrent with hematopoietic recovery, reestablishment of local microbial flora, and absence of factors that interfere with wound healing such as infection and mechanical irritation (Hensley et al., 2009). The extracellular matrix (ECM) is a complex structural network of fibrous proteins, proteoglycans, and glycoproteins that plays a role in signaling between tissues. ECM stimulates epithelial cell migration, proliferation, and differentiation, leading to renewal of the mucosa (Jensen et al., 2013).

#### Risk assessment of mucositis

OM is among the most common and dreaded toxicities of cancer therapy. It occurs in almost all patients who receive radiation therapy in which areas of oral and

oropharyngeal mucosa are included in the treatment field. There are still many unanswered questions about the risk factors for developing OM, but historically, risk factors have been attributed to both therapy and patient characteristics. (Kashiwazaki et al., 2012). As mentioned above, treatment variables that may affect the incidence and the severity of OM include the type, dose, and schedule of systemic cytotoxic drugs delivered, radiation dose and field, and concomitant use of chemotherapy and radiation. Studies have shown that the risk of OM increases as the intensity of therapy increases. (Keefe et al., 2007).

Even though the diagnosis and treatment is similar, patients are not at equal risk of mucositis. What accounts for such variation? Historically, mucositis risk has been attributed to factors that are associated with treatment and those attributable to the patient. Patient-related risk factors are more complex and, for the most part, are poorly defined. Despite similarities in diagnosis and treatment,



patients are not at equal risk of developing mucositis. Among patient-associated factors, age, malnutrition, gender, pre-existing medical conditions, alterations in salivary production and composition, poor oral health, and mucosal trauma have been reported to influence the risk of OM (Kwitkowski et al., 2010). Poor dental health, particularly periodontal disease, has been identified as an environmental factor that may increase the severity of OM (discussed in more detail below) (Laheij et al., 2012). Reducing oral bacterial load and periodontal inflammation was associated with a lower prevalence of OM in HSCT recipients (Laheij and de Soet., 2013; Lalla and Sonis, 2008). There has been increased interest recently in the role of the oral microbiome in OM risk (Logan et al., 2007; National Cancer Institute, 2015), with studies suggesting that shifts in the composition of the oral microbiome during chemotherapy influence OM severity (Napenas et al., 2007). *Porphyromonas gingivalis* and other periodontal pathogens have been identified as explanatory variables for oral ulcerations (Nicolatou-Galitis et al., 2001). In addition, fungi and viruses that are typically associated with mucosal injury have been studied for their potential involvement in the development of ulcerative OM, but no firm conclusions can be drawn (Nicolatou-Galitis et al., 2001; Peterson et al., 2015).

Genomic differences, which are major determinants of toxicity risk, have been identified among patients with head and neck cancer who received radiotherapy (Pratesi et al., 2011; Russi et al., 2014). Genetic determinants of chemotherapy-induced risk of mucositis include genes that regulate the availability of active drug metabolites. For example, evaluation of genetic variations in folate-metabolising enzymes may help in identifying patients at greater risk for methotrexate toxicity, although enzyme deficiencies may be relatively rare. In contrast, differences in the expression of genes associated with biological pathways that drive mucositis are more common. For instance, genetic polymorphisms associated with the expression of inflammatory mediators such as TNF- $\alpha$  have been implicated in OM risk (Santos et al., 2011). The tumor itself has recently become appreciated as playing a role in OM risk (Saunders et al., 2013). The inflammatory response induced by the tumour, together with inflammation from treatment-induced cytotoxicity, may contribute to adverse events, including OM (Soga et al., 2009).

#### *Mucositis associated with targeted therapies*

Targeted anticancer agents influence or inhibit the signaling of many cellular targets, including mammalian target of rapamycin (mTOR), EGFR, vascular endothelial growth factor receptor (VEGFR), human epidermal growth factor receptor (EGF)-2, and several tyrosine kinases. Many monoclonal antibodies and small molecule inhibitors are now used to improve survival for a wide variety of malignancies.

Oral toxicities caused by these agents differ clinically, and likely also pathobiologically, from conventional OM. Therefore, the broader term stomatitis is preferred to mucositis for describing the mucosal injuries and other oral toxicities (e.g., mucosal sensitivity, taste alterations,

dry mouth, jaw bone necrosis) associated with selected targeted agents (Sonis et al., 2010; Sonis, 2004). Although oral mucosal lesions are usually mild and self-limiting, lesions may persist over long periods, presenting a significant burden to patients.

The prevalence of oral toxicities (any grade) has been reported at 38 % for sunitinib, 28 % for sorafenib, and 4 % for pazopanib in patients with renal cancer (Sonis, 2002). In meta-analyses conducted by Elting and coworkers, stomatitis was most frequently reported among patients treated with bevacizumab, erlotinib, sorafenib, or sunitinib (Sonis, 2007).

mTOR inhibitors (everolimus and temsirolimus) are approved for the treatment of renal cell cancer and selected other malignancies. mTOR inhibitor-associated stomatitis resembles aphthous stomatitis, characterized as distinct ovoid ulcers with a central gray area surrounded by a ring of erythema (Sonis et al., 2010). These lesions typically present with a rapid onset (usually within 5 days), most frequently in the first cycle of therapy. Similar to conventional OM it almost exclusively affects the non-keratinized, movable oral surfaces. Even small ulcerations can cause significant pain, and mucosal sensitivity may occur in the absence of clinical changes. The use of assessment tools driven primarily by ulceration size may underestimate this stomatitis and assessment should include patient-reported outcomes.

Sonis (2010), in a systematic review evaluating 44 studies, mTOR inhibitor-associated stomatitis was identified as the most frequent adverse event overall (73.4%), accounting for 27.3 % of dose reductions and 13.1 % of therapy discontinuation (Trotti et al., 2003).

#### *Current approaches to the management of oral mucositis*

Despite its frequency, impact on patients and health and economic costs, there are currently limited evidence-based options for the prevention and treatment of oral mucositis. Mucositis management relies on symptom management and prevention of complications, which includes pain control, nutritional support, and prophylaxis/treatment of secondary infections (van der Beek et al., 2012). Although these components continue to be of great importance, research has also identified a number of specific strategies to prevent the onset or reduce the severity of OM. Clinical practice guidelines have been prepared for the management of OM based on evidence and expert opinion (Vanhoecke et al., 2015; Woo et al., 1990). The Multinational Association of Supportive Care in Cancer/International Society of Oral Oncology (MASCC/ISOO) recommends or suggests (depending on the level of supporting evidence) interventions for the prevention or treatment of OM in specific patient populations. Oral care is a key factor in the prevention and mitigation of oral injury; thus, reducing the microbial load and educating the patient regarding oral hygiene is very important. Other preventive measures include cryotherapy, keratinocyte growth factor-1, low-level laser therapy, benzydamine mouthwash, and zinc. Some studies are present where they summarized the activity of different agents for the management of oral mucositis in cancer patients (Wuketich et al., 2012; Yeoh et al., 2006).

Patients should be educated on the value of good oral health relative to cancer therapy. Oral hygiene instructions should be given, which includes tooth brushing, flossing, and rinsing with bland (saline or sodium bicarbonate) solutions. There are data to support the notion that this may be best accomplished through the use of multidisciplinary team that couple's nurses and dental professionals (Al-Azri et al., 2013). Regular oral assessment during therapy is therefore an important component of a program to assure maximum oral health.

Diet plays a role in oral health. Therefore, patients should be advised on food selection that promote, or which could interfere with, oral health. Since patients may experience modification of taste, changes in appetite, and dysphagia, food recommendations need to balance the need to maintain intake with the increased risk of oral disease. Avoidance of foods containing processed sugar, particularly those of a sticky consistency, should be discussed. Acidic and spicy foods may exacerbate the discomfort of mucositis and should be avoided.

Recently the use of the human recombinant keratinocyte growth factor (palifermin) has proven as a promising agents. However, the cost is an important factor to consider. The potential use of keratinocyte growth factor in the treatment of other forms of oral disease also remains unexplored. As there is no single or combination of treatment modalities are available, active and appropriate follow-up and management will improve the outcome of cancer treatment. Dentists should take initiative to prevent and management of mucositis by reducing and preventing local and systemic infection, patient education, and optimal quality of life.

The MASCC/ISOO guidelines for management of oral mucositis published in March 2007 was describe in Table 1 (Al-Azri et al., 2013). However, there are no evidence-based guidelines for the management of mucosal lesions associated with targeted therapies. Management begins with assessment and oral hygiene measures, diet modifications, and pain management. In most cases, pain can be controlled with locally applied products containing lidocaine or doxepin and mucosal coating agents. In persistent cases, treatment with local or systemic corticosteroids can be considered (Sonis, 2010). Secondary candidiasis is a common side effect of topical steroid therapy. If this occurs, topical antifungal therapy should be initiated. However, systemically absorbed azole antifungal agents may increase the toxicity of mTOR inhibitors.

In conclusions, oral mucositis represents significant burden of antineoplastic therapies and its treatment still remains a challenge. The understanding of epidemiology of oral mucositis is incomplete, however significant progress has been made in understanding the pathogenesis of oral mucositis and some preventive measures have been identified. Also the understanding of oral adverse events of targeted therapies is very little. So for majority of patients no effective interventions are available.

Clinicians, researchers and those involved in oral and periodontal medicine should join hand in hand in pursuit of understanding and developing treatment strategies for treatment of inflammatory conditions like OM in

oncology. This will lead to development of effective treatments and reducing the burden of OM and other inflammatory conditions in oncology.

#### Conflict of Interest

We don't have any sponsorship for this research, authorship. This is review article, so data is taken from many original articles and review papers related to this topic. Although all authors completed the disclosure declaration, there is no conflict of interests.

#### References

- Al-Azri AR, Gibson RJ, Keefe DM, Logan RM (2013). Matrix metalloproteinases: do they play a role in mucosal pathology of the oral cavity?, *Oral Dis*, **19**, 347–59.
- Al-Dasooqi N, Gibson RJ, Bowen JM, et al (2010). Matrix metalloproteinases are possible mediators for the development of alimentary tract mucositis in the dark agouti rat. *Exp Biol Med (Maywood, NJ)*, **235**, 1244–56.
- Andreassen C (2013). The biological basis for differences in normal tissue response to radiation therapy and strategies to establish predictive assays for individual complication risk. In: Keefe STSaDM, editor. Pathobiology of Cancer Regimen-Related Toxicities. New York, USA: Springer, pp 19–33.
- Barasch A, Peterson DE (2003). Risk factors for ulcerative oral mucositis in cancer patients: unanswered questions. *Oral Oncol*, **39**, 91–100.
- Bensinger W, Schubert M, Ang KK, et al (2008). NCCN Task Force Report. prevention and management of mucositis in cancer care. *J Natl Comp Cancer Netw*, **121**, 2–4.
- Blijlevens N, Sonis S (2007) Palifermin (recombinant keratinocyte growth factor-1): a pleiotropic growth factor with multiple biological activities in preventing chemotherapy- and radiotherapy-induced mucositis. *Ann Oncol*, **18**, 817–26.
- Boers-Doets CB, Epstein JB, Raber-Durlacher JE, et al (2012). Oral adverse events associated with tyrosine kinase and mammalian target of rapamycin inhibitors in renal cell carcinoma: a structured literature review. *Oncologist*, **17**, 135–44.
- Boers-Doets CB, Raber-Durlacher JE, Treister NS, et al (2013) Mammalian target of rapamycin inhibitor-associated stomatitis. *Future Oncol (London, England)*, **9**, 1883–92.
- Bogunia-Kubik K, Mazur G, Urbanowicz I, et al (2006) Lack of association between the TNF-alpha promoter gene polymorphism and susceptibility to B-cell chronic lymphocytic leukaemia. *Int J Immunogenet*, **33**, 21–4.
- Castellani P, Balza E, Rubartelli A (2014). Inflammation, DAMPs, tumor development, and progression: a vicious circle orchestrated by redox signaling. *Antioxid Redox Signal*, **20**, 1086–97.
- Coracin FL, Santos PS, Gallottini MH, et al (2013). Oral health as a predictive factor for oral mucositis. *Clinics (Sao Paulo, Brazil)*, **68**, 792–6.
- Elting LS, Chang YC, Parelkar P, et al (2013). Risk of oral and gastrointestinal mucosal injury among patients receiving selected targeted agents: a meta-analysis. *Support Care Cancer*, **21**, 3243–54.
- Hensley ML, Hagerty KL, Kewalramani T, et al. (2009) American society of clinical oncology 2008 clinical practice guideline update: use of chemotherapy and radiation therapy protectants. *J Clin Oncol*, **27**, 127–45.
- Jensen SB, Jarvis V, Zadik Y, et al (2013). Systematic review of miscellaneous agents for the management of oral mucositis

- in cancer patients. *Support Care Cancer*, **21**, 3223-32.
- Kashiwazaki H, Matsushita T, Sugita J, et al (2012). Professional oral health care reduces oral mucositis and febrile neutropenia in patients treated with allogeneic bone marrow transplantation. *Support Care Cancer*, **20**, 367-73.
- Keefe DM, Schubert MM, Elting LS, et al (2007). Updated clinical practice guidelines for the prevention and treatment of mucositis. *Cancer*, **109**, 820-31.
- Kwitkowski VE, Prowell TM, Ibrahim A, et al (2010). FDA approval summary: temsirolimus as treatment for advanced renal cell carcinoma. *Oncologist*, **15**, 428-35.
- Laheij AM, de Soet JJ, von dem Borne PA, et al. (2012) Oral bacteria and yeasts in relationship to oral ulcerations in hematopoietic stem cell transplant recipients. *Support Care Cancer*, **20**, 3231-40.
- Laheij AM, de Soet JJ (2013). Can the oral microflora affect oral ulcerative mucositis?. *Curr Opin Support Palliat Care*, **8**, 180-7.
- Lalla RV, Bowen J, Barasch A, et al (2014). MASCC/ISOO clinical practice guidelines for the management of mucositis secondary to cancer therapy. *Cancer*, **120**, 1453-61.
- Lalla RV, Sonis ST, (2008). Peterson DE. Management of oral mucositis in patients who have cancer. *Dent Clin N Am*, **52**, 61-77.
- Logan RM, Gibson RJ, Sonis ST, Keefe DM (2007). Nuclear factor-kappaB (NF-kappaB) and cyclooxygenase-2 (COX-2) expression in the oral mucosa following cancer chemotherapy. *Oral Oncol*, **43**, 395-01.
- Mendonca RM, Araujo M, Levy CE, et al (2015). Oral mucositis in pediatric acute lymphoblastic leukemia patients: Evaluation of microbiological and hematological factors. *Pediatr Hematol Oncol*, **32**, 322-30.
- National Cancer Institute (2015). FDA approval for palifermin; <http://www.cancer.gov/cancertopics/druginfo/fda-palifermin> (9 April 2015, date last accessed).
- Napenas JJ, Brennan MT, Bahrani-Mougeot FK, et al (2007). Relationship between mucositis and changes in oral microflora during cancer chemotherapy. *Oral Surg Oral Med Oral Pathol Oral Radiol Endodontics*, **103**, 48-59.
- Nicolatou-Galitis O, Dardoufas K, Markoulatos P, et al (2001). Oral pseudomembranous candidiasis, herpes simplex virus-1 infection, and oral mucositis in head and neck cancer patients receiving radiotherapy and granulocyte-macrophage colony-stimulating factor (GM-CSF) mouthwash. *J Oral Pathol Med*, **30**, 471-80.
- Nicolatou-Galitis O, Migkou M, Psyrris A, et al (2012). Gingival bleeding and jaw bone necrosis in patients with metastatic renal cell carcinoma receiving sunitinib: report of 2 cases with clinical implications. *Oral Surg Oral Med Oral Pathol Oral Radiol*, **113**, 234-8.
- Nicolatou-Galitis O, Sarri T, Bowen J, et al (2013). Systematic review of anti-inflammatory agents for the management of oral mucositis in cancer patients. *Support Care Cancer*, **21**, 3179-89.
- Parkhill AL (2013). Oral mucositis and stomatitis associated with conventional and targeted anticancer therapy. *J Pharmacovigilance*, **1**, 1-4.
- Peterson DE, Boers-Doets CB, Bensadoun RJ, Herrstedt J (2015) Management of oral and gastrointestinal mucosal injury: ESMO Clinical Practice Guidelines for diagnosis, treatment, and followup. *Ann Oncol*, **139-51**, doi: 10.1093/annonc/mdv202.
- Pratesi N, Mangoni M, Mancini I, et al (2011). Association between single nucleotide polymorphisms in the XRCC1 and RAD51 genes and clinical radiosensitivity in head and neck cancer. *Radiother Oncol*, **99**, 356-61.
- Raber-Durlacher JE, Elad S, Barasch A (2010). Oral mucositis. *Oral Oncol*, **46**, 452-6.
- Russi EG, Raber-Durlacher JE, Sonis ST (2014). Local and systemic pathogenesis and consequences of regimen-induced inflammatory responses in patients with head and neck cancer receiving chemoradiation. *Mediat Inflamm*, **2014**, 518261.
- Santos PS, Coracin FL, Barros JC, et al (2011). Impact of oral care prior to HSCT on the severity and clinical outcomes of oral mucositis. *Clin Transpl*, **25**, 325-8.
- Saunders DP, Epstein JB, Elad S, et al (2013). Systematic review of antimicrobials, mucosal coating agents, anesthetics, and analgesics for the management of oral mucositis in cancer patients. *Support Care Cancer*, **21**, 3191-207.
- Soga Y, Yamasuji Y, Kudo C, et al (2009). Febrile neutropenia and periodontitis: lessons from a case periodontal treatment in the intervals between chemotherapy cycles for leukemia reduced febrile neutropenia. *Support Care Cancer*, **17**, 581-7.
- Sonis S, Treister N, Chawla S, Demetri G, Haluska F (2010). Preliminary characterization of oral lesions associated with inhibitors of mammalian target of rapamycin in cancer patients. *Cancer*, **116**, 210-5.
- Sonis ST (2002). The biologic role for nuclear factor-kappaB in disease and its potential involvement in mucosal injury associated with antineoplastic therapy. *Crit Rev Oral Biol Med*, **13**, 380-9.
- Sonis ST (2004). A biological approach to mucositis. *J Support Oncol*, **2**, 21-32.
- Sonis ST (2004). The pathobiology of mucositis. *Nat Rev Cancer*, **4**, 277-84.
- Sonis ST (2007). Pathobiology of oral mucositis: novel insights and opportunities. *J Support Oncol*, **5**, 3-11.
- Sonis ST (2010). New thoughts on the initiation of mucositis. *Oral Dis*, **16**, 597-600.
- Trotti A, Bellm LA, Epstein JB, et al (2003). Mucositis incidence, severity and associated outcomes in patients with head and neck cancer receiving radiotherapy with or without chemotherapy: a systematic literature review. *Radiother Oncol*, **66**, 253-62.
- van der Beek MT, Laheij AM, Raber-Durlacher JE, et al (2012). Viral loads and antiviral resistance of herpesviruses and oral ulcerations in hematopoietic stem cell transplant recipients. *Bone Marrow Transplant*, **47**, 1222-8.
- Vanhoecke B, De Ryck T, Stringer A, Van de Wiele T, Keefe D (2015). Microbiota and their role in the pathogenesis of oral mucositis. *Oral Dis*, **21**, 17-30.
- Werbrouck J, De Ruyck K, Duprez F, et al (2009). Acute normal tissue reactions in head-and-neck cancer patients treated with IMRT: influence of dose and association with genetic polymorphisms in DNA DSB repair genes. *Int J Radiat Oncol Biol Phys*, **73**, 1187-95.
- Woo SB, Sonis ST, Sonis AL (1990). The role of herpes simplex virus in the development of oral mucositis in bone marrow transplant recipients. *Cancer*, **66**, 2375-9.
- Wuketich S, Hienz SA, Marosi C (2012). Prevalence of clinically relevant oral mucositis in outpatients receiving myelosuppressive chemotherapy for solid tumors. *Support Care Cancer*, **20**, 175-83.
- Ye Y, Carlsson G, Agholme MB, Wilson JA, et al (2013). Oral bacterial community dynamics in paediatric patients with malignancies in relation to chemotherapy-related oral mucositis: a prospective study. *Clinical Microbiol Infect*, **19**, 559-67.
- Yeoh A, Gibson R, Yeoh E, et al (2006). Radiation therapy-induced mucositis: relationships between fractionated radiation, NF-kappaB, COX-1, and COX-2. *Cancer Treat Rev*, **32**, 645-51.

Yeoh AS, Bowen JM, Gibson RJ, Keefe DM (2005). Nuclear factor kappaB (NFkappaB) and cyclooxygenase-2 (Cox-2) expression in the irradiated colorectum is associated with subsequent histopathological changes. *Int J Radiat Oncol Biol Phys*, **63**, 1295– 303.