

RESEARCH ARTICLE

18-Fluorodeoxy-Glucose Positron Emission Tomography-Computed Tomography (18-FDG-PET/CT) for Gross Tumor Volume (GTV) Delineation in Gastric Cancer Radiotherapy

Kinga Dębiec^{1*}, Jerzy Wydmański², Izabela Gorczewska³, Paulina Leszczyńska⁴, Kamil Gorczewski³, Wojciech Leszczyński⁴, Andrea d'Amico³, Michał Kalemba⁵

Abstract

Purpose: Evaluation of the 18-fluorodeoxy-glucose positron emission tomography-computed tomography (18-FDG-PET/CT) for gross tumor volume (GTV) delineation in gastric cancer patients undergoing radiotherapy. **Methods:** In this study, 29 gastric cancer patients (17 unresectable and 7 inoperable) were initially enrolled for radical chemoradiotherapy (45Gy/25 fractions + chemotherapy based on 5 fluorouracil) or radiotherapy alone (45Gy/25 fractions) with planning based on the 18-FDG-PET/CT images. Five patients were excluded due to excess blood glucose levels (1), false-negative positron emission tomography (1) and distant metastases revealed by 18-FDG-PET/CT (3). The analysis involved measurement of metabolic tumor volumes (MTVs) performed on PET/CT workstations. Different threshold levels of the standardized uptake value (SUV) and liver uptake were set to obtain MTVs. Secondly, GTV_{PET} values were derived manually using the positron emission tomography (PET) dataset blinded to the computed tomography (CT) data. Subsequently, GTV_{CT} values were delineated using a radiotherapy planning system based on the CT scans blinded to the PET data. The referenced GTV_{CT} values were correlated with the GTV_{PET} and were compared with a conformality index (CI). **Results:** The mean CI was 0.52 (range, 0.12-0.85). In 13/24 patients (54%), the GTV_{PET} was larger than GTV_{CT} and in the remainder, GTV_{PET} was smaller. Moreover, the cranio-caudal diameter of GTV_{PET} in 16 cases (64%) was larger than that of GTV_{CT}, smaller in 7 cases (29%), and unchanged in one case. Manual PET delineation (GTV_{PET}) achieved the best correlation with GTV_{CT} (Pearson correlation = 0.76, $p < 0.0001$). Among the analyzed MTVs, a statistically significant correlation with GTV_{CT} was revealed for MTV_{10%SUV_{max}} ($r = 0.63$; $p = 0.0014$), MTV_{liv} ($r = 0.60$; $p = 0.0021$), MTV_{SUV2.5} ($r = 0.54$; $p = 0.0063$); MTV_{20%SUV_{max}} ($r = 0.44$; $p = 0.0344$); MTV_{30%SUV_{max}} ($r = 0.44$; $p = 0.0373$). **Conclusion:** 18-FDG-PET/CT in gastric cancer radiotherapy planning may affect the GTV delineation.

Keywords: Positron-emission tomography- 18-Fluorodeoxyglucose- radiotherapy planning- Gross tumor volume

Asian Pac J Cancer Prev, **18 (11)**, 2989-2998

Introduction

The gastric cancer is a major issue worldwide. It is the fifth most common cancer and the third most frequent cause of death from cancer in the world. High mortality indirectly reflects the low curability of gastric cancer, and therefore, there is further need to study the efficiency of diagnosis and therapies for this type of cancer (Globocan, 2012).

In most Western countries, the 5-year overall survival (OS) of this disease is low, approximately 10% to 30%. These statistics are correlated with initially advanced tumor stage and a significant percentage of loco-regional recurrence and distant metastases (Matsuda and Saika, 2013). The results of surgical treatment, especially in advanced gastric cancer stages, are not satisfactory.

Improved treatment outcomes have been sought in the perioperative proceedings as pre- or postoperative chemoradiotherapy (CRT) (Maehara et al., 2000; Ratoso et al., 2015).

For patients in good general conditions with unresectable gastric cancer, recommendations according to the National Comprehensive Cancer Network (NCCN Guidelines, 2016) are chemotherapy or CRT with a subsequent restaging of the disease and consideration of gastrectomy. It was reported that radical CRT in patients of this group can lead to a reduction of infiltration, which, in some cases, allows for surgical intervention or even enables a complete resection (R0) (Ratoso et al., 2015). In the inoperable group of patients, where surgery is not possible because of the lack of consent of the patient or comorbidities, this method can potentially provide an

¹Radiotherapy and Chemotherapy I Clinic, ²Department of Radiotherapy, ³Department of PET Diagnostics, ⁴Department of Radiotherapy Planning, ⁵Department of Nuclear Medicine and Endocrine Oncology, Maria Skłodowska-Curie Memorial Institute of Oncology, Gliwice Branch, Poland. *For Correspondence: grabinska.kinga@gmail.com

opportunity to extend overall survival (Wydanski *et al.*, 2014).

In radiotherapy (RT), an accurate definition of the volume of interest is highly significant. Computed tomography is a commonly used modality in radiotherapy planning (RTP) (Matzinger *et al.*, 2009). Recently, the application of 18-fluorodeoxyglucose positron emission tomography-computed tomography (18-FDG-PET/CT) has been used to improve the precision of volume delineation and has enabled to individualized cancer treatment (Thorwarth, 2015).

One example is lung cancer, where this method helps to distinguish differences between atelectasis and neoplastic infiltration, reduces the area of irradiation and sparse organs at risk (OAR) (Nestle *et al.*, 1999). Furthermore, for this localization, 18-FDG-PET/CT enables visualization of metastatic lymph nodes that were not suspected to be malignant based on computed tomography (CT) images (De Ruyscher *et al.*, 2012).

Positron emission tomography (PET) is an attractive technique due to the different types of information provided compared to CT or magnetic resonance imaging (MRI). PET can reveal biologically active regions of tumors that morphological CT imaging does not offer. The utilization of different markers in PET imaging may reflect the degree of proliferation and the presence of hypoxia in the tumor. Escalating RT doses for increased tracer uptake – functional image-guided RT can allow for personalized treatment and increase the chances of improving results (Thorwarth, 2015).

Efforts are also attempting to define the gross tumor volume (GTV) via automatic and semi-automatic segmentation methods based on different threshold values of maximum standardized uptake volume (SUV_{max}), using the gradient of tracer uptake on the border of the tumor and the background, level based on activity uptake in the liver or mediastinal large vessels (Cheebsumon *et al.*, 2011). Unfortunately, to our knowledge, there are no reports of RTP in gastric cancer using this method.

The aim of this study was to evaluate the usefulness of 18-FDG-PET/CT in RTP of gastric cancer therapy, and in particular, to precisely determine GTV. In addition, how this method allows for the verification of the clinical stage defined in previously performed imaging studies, directly before planning a high dose of radiation therapy. Further analysis compared the tumor volumes measured separately using PET and CT.

Materials and Methods

Study group

This study was approved by the local ethics committee (committee number-KB/493-59/09) in accordance with the Helsinki Declaration of 1975, as revised in 2000. Retrospectively, for five years (2011-2016) in Maria Skłodowska-Curie Memorial Institute of Oncology, Gliwice Branch, Poland we had analyzed all the medical history of patients with gastric cancer who underwent 18-FDG PET/CT imaging. In this group of 262 patients, in 75 cases 18-FDG-PET/CT was used for imaging of RTP. 29/75 patients met the inclusion criteria for this

study. Remaining 46/75 patients were excluded from further analysis due to previous oncological treatment. The inclusion criteria for patients were: histologically confirmed gastric cancer, unresectable or inoperable tumor, locally advanced disease, no prior oncological treatment, good performance status (Zubrod Scale 0-2), qualification for the radical treatment: CRT or RT and 18-FDG-PET/CT imaging for RTP. The exclusion criteria were: confirmed distant metastases (M1) in tests before qualification for CRT or RT, previous oncological treatment, bad performance status (Zubrod Scale 3-4) which made impossible carrying out radical RCT/RT treatment.

The study group included 4 women and 25 men aged 41 to 90 years. Initially, all patients underwent a diagnostic abdominal contrast-enhanced CT, upper gastrointestinal gastroscopy with lesion biopsy and histopathological examination, chest CT scan or X-ray to assess cancer stage. Moreover, standard a blood panel test was performed and additional tumor markers, carcinoma antigen 19-9 (CA 19-9) and carcinoembryonic antigen (CEA), were considered. Patients were qualified for CRT (45Gy in 25 fractions + 5-fluorouracil 325 mg/m² as a 10-min bolus intravenous injection at least 1 h prior to irradiation on 1-5 and 29-33 days of treatment) or RT alone (45Gy in 25 fractions) with planning based on the 18-FDG-PET/CT images. Five patients (17%) were disqualified. One patient was disqualified because of unregulated diabetes, and one patient due to a false negative PET. The remaining three patients (10%) were excluded because, after the PET/CT study for RTP, distant metastasis was detected, which is indescribable for assessing the progress of cancer as reported in previous studies. These patients were relegated to palliative chemotherapy.

In the group of 24 patients subjected to further analysis, 17 patients were classified as unresectable cases. This evaluation was made based on exploratory laparotomy or imaging studies. The other patients were inoperable due to comorbidities or lack of permission for surgical treatment. The clinical characteristics of the patients are presented in Table 1.

PET/CT examination

Examination of the 18-FDG-PET/CT for RTP was performed using a hybrid PET-CT scanner (Siemens® Biograph™ mCT) according to the internal protocol: after 6 h of fasting, patients were given the intravenous radiotracer 18-FDG, activity 5-15 mCi (185-555 MBq), 0.1 mCi/kilogram of body weight and Buscopan 20 mg. Acquisition was performed 60 min after radioactive marker injection and just after the drinking 500 ml of water. The exhale CT examination was performed without contrast agent within 9.6 seconds; the duration of the PET acquisition ranged from 17-20 min, approximately 2 min for each bed position. The study region included the entire body from below the eyes to the upper 1/3 of the femur. During PET and CT examination, the same region of the body was imaged with the same field of view (FOV) and slice thickness of 3 mm. Both PET and CT studies were performed in the same therapeutic position: on a flat table for RT, patients were immobilized with a thermoplastic

mask, laying on their back with straight legs, hands raised above the head and a support bolster for their head.

Cross calibration was performed on the PET/CT scanners, which were installed in Department of PET Diagnostic. This calibration was performed according to the manufacturer's recommendations and ensures accordance between the dose calibrator and the PET-CT scanner.

Further analysis of the metabolic parameters

Retrospectively, 18-FDG PET/CT was evaluated for 24 patients with gastric cancer. The PET images with attenuation correction were utilized for the evaluation. The resulting DICOM images were analyzed on dedicated PET-CT workstations Siemens Syngo.via. Metabolic parameters such as SUVmax and metabolic tumor volume (MTV) were estimated. MTVs were measured according to the different thresholds of SUV and included a designated three-dimensional region of interest (ROI), covering the well visible tumor of the stomach with the surrounding infiltration. MTVs were determined as follows: MTV_{2.5} (threshold: SUV \geq 2.5), MTV_{liv} [\geq mean SUV of the patient's liver \pm 2 standard deviations (SD)], MTV₁₀ (\geq 10% of SUVmax), MTV₂₀, MTV₃₀, MTV₄₀, MTV₅₀, MTV₆₀, and MTV₇₀, respectively, according to the definitions above. Subsequently, the PET/CT images in DICOM format were acquired by the RTP system (Eclipse Software, version 13.6, Varian Medical Systems). After the rigid registration of the morphological and functional images, a medical radiation oncologist who was not directly related to the patient's treatment delineated GTVCT volume (the primary tumor of the stomach) based on the CT series. During this process, the physician had access to the complete patient documentation containing, among others information, a description of the diagnostic abdominal CT with contrast agent and gastroscopy.

Second, independent of the CT images, a physician delineated the GTV_{PET} volumes based on the PET images according to the subjective interpretation of visible radiotracer uptake of 18-FDG and the PET diagnostic description previously prepared by a doctor with a specialization in nuclear medicine. The measurements of the aforementioned structural volumes were made using the RTP system Eclipse 13.6. The GTVs volumes were quantitatively compared using a conformity index [conformity index (CI) = intersection / union]. This method has been previously described by Gondi et al., (2007) in a similar study related to lung and esophageal tumors. This ratio represents the relation of overlapping parts of two GTVs (intersection) to the total volume of the connected areas (union = GTVCT + GTV_{PET} - intersection) and is expressed as a value from 0 to 1. A value of 1 means that the GTVCT and GTV_{PET} areas are identical, while a value of 0 means that there is no spatial coverage between the volumes. The percentage relative difference (%RD) of the volumes between GTV_{PET} and GTVCT was calculated with the following formula: %RD = (GTV_{PET} - GTVCT) / GTVCT * 100%. The correlation of those volume was evaluated. An example of the intersection of GTV_{PET} and GTVCT contours is presented in Figure 1.

Then, the different MTVs and GTVCT were compared,

which allowed us to obtain the auto segmentation volume that best correlates with the GTVCT volume. In addition the GTVCT and GTV_{PET} volumes were analyzed in craniocaudal dimensions (CC).

Statistical analysis

Statistical analysis was performed using the Statistica v.10 program (StatSoft, Poland). For all calculations, the significance level was $\alpha = 0.05$. The result was considered as statistically significant if the determined p value was less than 0.05 ($p < 0.05$). Correlations between volumes obtained based on the PET (GTV_{PET} and MTVs) and CT (GTV_{CT}) studies were appointed by the Pearson or Spearman statistic, depending on the type of the distribution. Comparisons the lengths of the GTVs based on the CT and PET examinations and the volumes of the GTVs according to histopathology were evaluated using Student's t-tests or the Mann-Whitney statistic, depending on the distribution. The statistical review of the study was performed by a statistician.

Results

The average conformity index (CI) of the whole group was 0.52 (range 0.12 - 0.85). The average GTV_{CT} volume was 163.3 cm³ (51.6 - 316.1 cm³), while the GTV_{PET} was 170.3 cm³ (11.4 - 479.3 cm³). For 13 (54%) patients, the GTV_{PET} was larger than the GTVCT (228.4 cm³ vs 178.7 cm³) by an average of approximately 49.7 cm³ (28%). In the remaining 11 (46%) patients, the average GTV_{PET} volume was 43.6 cm³ (30%) smaller than the volume defined in the CT (101.6 cm³ vs 145.2 cm³). A comparison of the GTV volumes is shown in Table 2.

The diagnostics of the patients with the lowest CI and with the highest % RD were analyzed in detail.

For patient no. 7, the CI and %RD parameters were 0.17 and 71.1%, respectively. For this patient, both endoscopy and a previous abdominal CT imaging with contrast revealed swelling of the walls of the whole stomach body with the infiltration of stomach adipose and a number of erosions at this location (cT3N0). The physician outlining the GTVCT included the thickened wall of the stomach body. According to the 18-FDG-PET/CT, pathological uptake (SUVmax = 4.82) was located in a much smaller area on the border between the body and pyloric antrum, also including part of the pylorus, which is not taken into account during the delineation of GTV based on CT.

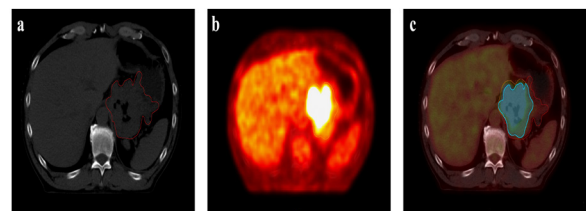


Figure 1. Gross Tumor Volumes (GTVs) Contoured Based on CT Scans (Red Contour) (a) and the PET Dataset (Orange Contour) (b). Intersection of the Two GTVs (blue area) Illustrated on the PET/CT Scan (c).

Table 1. Clinical Patients Characteristics

Variable	Patient no. (%) n=24
Average age (years), range	67 (41-90)
Gender	
Male	20 (83%)
Female	4 (17%)
Performance status	
0	5 (21%)
1-2	19 (79%)
Tumor	
Unresectable	17 (71%)
Inoperable	7 (29%)
Average blood glucose level (range)	105 mg/dl (78-193 mg/dl)
cT stage	
T2	3 (12,5%)
T3	13 (54%)
T4a	3 (12,5%)
T4b	5 (21%)
cN stage	
N0	14 (58%)
N1	4 (17%)
N2	2 (8%)
N3	4 (17%)
Histopathology	
Adenocarcinoma	
Intestinal type	16 (67%)
Diffuse type	8 (33%)
Tumor differentiation	
G1	1 (4%)
G2	5 (21%)
G3	12 (50%)
Not specified	6 (25%)
Ca19.9 average (range), IU/mL	155.38 (2- 1571)
CEA average (range), IU/ mL	11.27 (0.5-117)

For patient no. 9, the CI and %RD parameters were 0.33 and 63.4%, respectively. For this patient, the smaller structure of the GTV_{PET} was entirely contained in the larger structure of the GTV_{CT} , apparently consisting of a thickened wall of the gastric antrum (cT3N0). The 18-FDG uptake was very low, and SUVmax was 3.52.

For patient no. 24, the CI and %RD parameters were 0.12 and 85.2%, respectively. The CT and gastroscopy examinations described the neoplastic infiltration of the cardia extending to the fundus and lesser curvature of the stomach and enlarged regional lymph nodes (cT3N1). PET imaging revealed a smaller infiltration area than the CT study, covering only the region of cardia, 18-FDG uptake was low, and SUVmax was 4.3.

In all three cases above, GTV_{PET} was much smaller than GTV_{CT} . The histopathological examination of tumors indicated carcinoma mucocellulare. Such diagnosis is characterized by low 18-FDG uptake by cells that produce mucus (low SUV).

A significant volume difference also appeared in

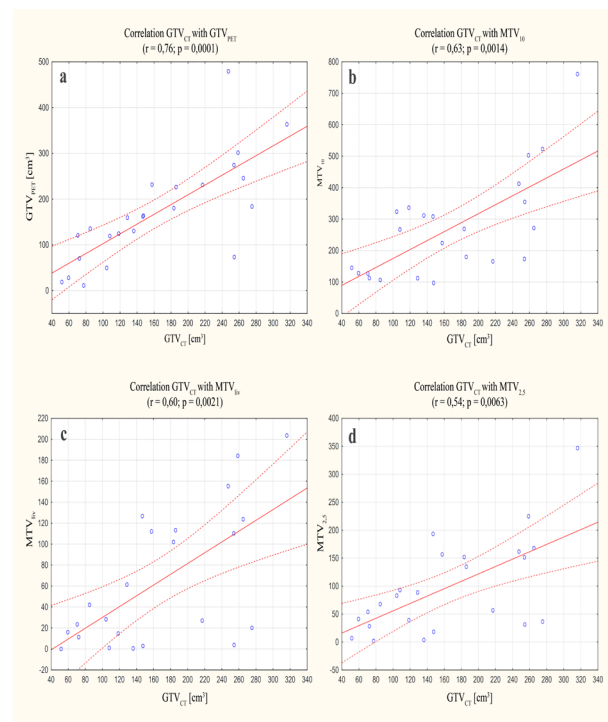


Figure 2. Graphs Showing the Strongest Correlations between the Assessed Volumes: Gross Tumor Volumes Contoured Based on CT (GTV_{CT}) vs Volumes Contoured Based on PET (GTV_{PET}) (a); GTV_{CT} vs metabolic tumor volume designated by $\geq 10\%$ of SUVmax threshold (MTV_{10}) (b); GTV_{CT} vs MTV_{liv} [threshold: \geq mean SUV of the patient's liver ± 2 standard deviations (SD)] (c); GTV_{CT} vs $MTV_{2.5}$ (threshold: SUV ≥ 2.5) (d).

patient 10. The patient, despite an average CI of 0.51, corresponded to the highest coefficient %RD of 94.7%. For this patient, GTV_{PET} was almost twice as large as the GTV_{CT} . This was attributed to the extensive 18-FDG uptake within the infiltration exceeding the outline of the stomach visible on the PET images, which grew into the perigastric (adipose tissue and spleen) region. Infiltration was not distinct in the CT study for treatment planning. Moreover, in this patient, considerable respiratory mobility was seen (infiltration in PET in the CC dimension was 2 cm higher than in the CT study), which also had an

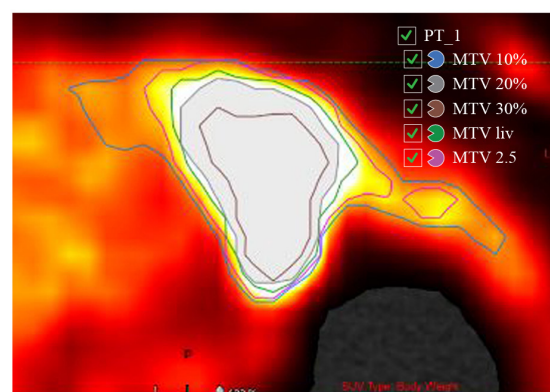


Figure 3. A PET Image with an Example of Auto-Segmentation of the MTV According to Different SUV Cut-Off Levels (MTV_{10} , MTV_{20} , MTV_{30} , MTV_{liv} and $MTV_{2.5}$)

Table 2. Comparison of Gross Tumour Volumes (GTVs) Created on the Basis of CT versus PET Imaging

Patient	GTV _{CT} (cm ³)	GTV _{PET} (cm ³)	% Relative difference	Intersection	Union	Conformality index	SUVmax
1	108	119.6	10.70%	104.6	123	0.85	5.27
2	157.6	231.7	47.00%	142.7	246.6	0.58	17.46
3	128.7	159.7	24.10%	99.5	188.9	0.53	20.66
4	253.9	274.4	8.10%	196.2	332.1	0.59	22.66
5	118.5	124.6	-5.00%	87.9	155.2	0.57	5.28
6	185.8	226.1	21.70%	149	262.9	0.57	17
7	254.4	73.6	-71.10%	47.3	280.6	0.17	4.82
8	104.2	49.9	-52.10%	46.7	107.4	0.43	9.58
9	51.6	18.9	-63.40%	17.5	53	0.33	3.52
10	247.4	479.3	94.70%	246.1	480.6	0.51	7.27
11	136.1	130.5	-4.10%	93.8	172.8	0.54	3.79
12	275.2	184	-33.10%	130.4	328.8	0.39	4.54
13	146.8	162.1	10.40%	129.6	179.3	0.72	16.36
14	183.3	180.4	-1.60%	157.6	206.1	0.76	11.7
15	147.5	163.9	11.00%	106.8	204.6	0.52	7.75
16	72.2	70.4	-2.50%	52.2	90.4	0.58	4.22
17	217	231	6.00%	127.8	320	0.4	9.6
18	265	245.8	-7.20%	185.2	326.6	0.57	18.58
19	258.7	301.7	16.60%	234.7	325.7	0.72	9.56
20	59.5	28.2	-52.60%	28	59.7	0.5	12.47
21	85	135.5	59.40%	79.6	140.9	0.56	16.41
22	70.5	121	70.60%	55.4	136.1	0.41	10.87
23	316.1	363.5	15.00%	219	460	0.47	13.53
24	77.2	11.4	-85.20%	9.6	79	0.12	4.3
Mean	163.3	170.3				0.52	10.72

impact on the delineated GTV_{PET} volume.

In whole study group the correlation between GTV_{CT} and GTV_{PET} was statistically significant (p < 0.0001), and the Pearson coefficient was 0.76. The graph shows this relationship (Figure 2). In Figure 2A, two outliers can be observed, which refer to patients 7 and 10. The reasons for

Table 3. Average Values of Metabolic Tumour Volumes (MTVs) and Their Correlation with the Gross Tumour Volumes, Contoured Based on the CT (GTV_{CT})

	Average value (cm ³)	Range (cm ³)	Correlation coefficient (r)	P =
MTV ₁₀	270.3	97.4-761.3	0.63 ²	0.0014
MTV ₂₀	169.5	41.4-438.0	0.44 ²	0.0344
MTV ₃₀	101.6	19.7-252.8	0.44 ¹	0.0373
MTV ₄₀	58.7	5.6-148.0	0.28 ¹	0.1909
MTV ₅₀	33.4	3.4-73.3	0.20 ¹	0.3572
MTV ₆₀	17.7	1.9-45.4	0.16 ²	0.4663
MTV ₇₀	8.2	0.8-27.2	0.14 ²	0.5115
MTV _{2.5}	97.6	2.1-347.0	0.54 ²	0.0063
MTV _{liv}	61.9	0.0-203.7	0.60 ²	0.0021

¹, Person's Correlation; ², Spearman's Correlation; MTVs, MTV_{2.5} (threshold: SUV ≥ 2.5), MTV_{liv} [≥ mean SUV of the patient's liver ± 2 standard deviations (SD)], MTV₁₀ (≥ 10% of SUVmax), MTV₃₀, MTV₃₀, MTV₄₀, MTV₅₀, MTV₆₀, MTV₇₀ respectively, according to the foregoing.

the differences between the GTV_{CT} and GTV_{PET} volumes between these patients have already been analyzed and are described above.

Among the auto-segmented MTV volumes, the best compatibility with GTV_{CT} had MTV₁₀, which was immediately followed by MTV_{liv} and MTV_{2,5}, as shown in the diagrams (Figure 2B, C, D). On the graphs showing the correlation between GTV_{CT} and MTV₁₀ (Figure 2B) and between GTV_{CT} and MTV_{2.5} (Figure 2D), a visible outlier can be observed corresponding to patient 23. The large MTV₁₀ volume (761.3 cm³) was caused by the increased uptake of 18-FDG in numerous regional lymph nodes confluent with the infiltration of the stomach wall and the direct adherence of this irregular change to the left lobe and hilar area of the liver. Assuming a low threshold of 10% SUVmax = 1.35, MTV₁₀ included almost the entire ROI, in addition to the background corresponding to high physiological activity of the liver. MTV_{2.5} was also greater than GTV_{CT} (347.0 cm³ vs 316.1 cm³). This volume was contained in the GTV_{PET} volume delineated manually (363.5 cm³).

The mean MTVs values with different threshold levels and their correlation with GTV_{CT} volume are shown in Table 3 (the significant correlations are shown as boldface). Sample MTV contours were significantly correlated with GTV_{CT} volumes, as shown in Figure 3.

The craniocaudal dimension was compared between

the CT and PET examinations. For the whole study group, the average length of GTV_{PET} was not significantly longer than that of GTVCT [7.2 (1.8-12.3 cm) vs 6.7 cm (2.7-10.2 cm)]. There was no statistically significant difference between the lengths ($p = 0.1500$). For 16 (67%) patients in the PET study, the CC tumor dimension was longer (average 20%) than that designated in the CT study, while for 7 (29%) patients, the GTV_{PET} CC length was shorter (average 22%), and in 1 (4%) patient, these dimensions were the same in both studies.

The cranial extent of the primary tumor defined based on the PET vs CT varied for 96% (23) of patients, including 5 patients (21%) by more than 1 cm. The caudal direction differed in 58% (14) patients, including 4 (17%) patients by more than 1 cm.

The GTVCT and GTV_{PET} volumes were analyzed with respect to the histological type (IT -intestinal type, DT-diffuse type). In the PET study, DT tumors, which in theory have worse uptake of the radiotracer, proved to be smaller by approximately 82.3 cm³ compared to IT tumors (115.4 cm³ vs 197.7 cm³). The mean SUVmax for DT was also lower than that for IT (7.70 vs 12.22).

In the CT examination, DT tumors were larger by approximately 5.5 cm³ (167.0 cm³ vs 161.5 cm³). For GTVCT ($p = 0.8786$) and GTV_{PET} ($p = 0.0905$) and for the average value SUVmax ($p = 0.0618$) there were no statistically significant differences between the tumor histologies.

Discussion

The literature has confirmed the utility of 18-FDG PET/CT diagnostics in the staging of gastric cancer (Wu and Zhu, 2014; Smyth *et al.*, 2012), the detection of recurrence (Park *et al.*, 2009) and its prognostic and predictive value (Grabinska *et al.*, 2015). However, there are controversies regarding the use of PET in this application. This technique, although characterized by a high specificity (78-100%), has a relatively low sensitivity, especially for the detection of early gastric cancer (EGC) and cancers of signet-ring cell carcinoma. The sensitivity of the method for EGC ranges from 26% to 63%, while in patients with advanced gastric cancer (AGC), the sensitivity is significantly higher and varies in the range of 84.9% to 98% (Mukai *et al.*, 2006; Stahl *et al.* 2003). In this study, we did not analyze EGC; all tumors were of an advanced stage, especially the unresectable cases. Among the analyzed patients, one patient was found to be a false negative via PET, despite the obvious infiltration of tumor in CT imaging and endoscopy. It was a histological signet-ring cell carcinoma tumor type, where the reduced uptake of FDG may be associated with a large quantity of accumulated mucus in signet cells, reduced tumor cell density than in the intestinal type and a decrease of glucose transporter 1 (GLUT-1) expression. These receptors are responsible for the active transport of FDG to the cells. Cancer cells usually overexpress GLUT-1, while signet cells not always (Stahl *et al.*, 2003). This occurrence can cause a low CI for patients who had a much larger GTVCT than GTV_{PET} (as is likely the case in the analyzed patients 7, 9, and 24). Moreover, the lack of local FDG

uptake in certain areas of the tumor may be induced by the presence of necrosis, which is metabolically inactive. In gastric cancer, there is also a possibility of false positive uptake in regions not including malignancies. This is due to physiologic FDG uptake of strong blood supplied mucosa and the possible coexistence of inflammatory processes where the metabolism of FDG is also increased (Wu and Zhu, 2014). In this case, the GTV_{PET} volume may be larger than the GTVCT volume and affect the low CI index. A method to reduce this occurrence is to fill the stomach, for example with water, which leads to stretching of the stomach wall and reduces background activity (Kamimura *et al.*, 2009). Our analyzed group of patients were administered 500 ml of water before the examination. This procedure before each RT fraction can improve the repeatability and precision of irradiation.

Considering the limitations of the 18-FDG marker in gastric cancer, the use of other radiopharmaceuticals can be considered. There are reports that fluorothymidine (FLT) is a more sensitive marker for the primary focus of gastric cancer and lymph nodes than FDG. This marker is captured by intensively proliferating cells but is not routinely used in cancer diagnostics (Herrmann *et al.*, 2007).

Studies of tumor locations other than the stomach (e.g., esophagus, lung, pancreas) have shown that the additional biological information from PET examination influences the variation of the GTV volume during RTP and can reduce the risk of geographical error (Gondi *et al.*, 2007; Wilson *et al.*, 2014) and affect the normal tissue dose-volume histograms and the corresponding normal tissue complication probability values (Muijs *et al.*, 2009). Our results also suggest that the utilization of hybrid 18-FDG-PET/CT in three-dimensional RTP of large GTV volumes may change many analyzed cases. Although the difference between the average GTV_{PET} and GTVCT volumes was not statistically significant, the effects of radiation therapy are of major importance. It is meaningful that each underdosed volume of the tumor is a source of further disease progression.

In previously published studies relating to this issue, the most often have compared the GTV volumes determined using CT and PET/CT studies. First, the GTV area was delineated based on CT series, and then the contour was modified after registration with the PET scans to obtain the GTVCT and GTVPET/CT volumes (Gondi *et al.*, 2007; Leong *et al.*, 2006). In our work, the GTVs were determined from independent CT and PET series and then compared to the registration. The aim was to evaluate the absolute of information coming from the two methods, and we used the CI for this purpose, which was 0.52 for the whole study group. This demonstrates the significant spatial disparity of GTV areas delineated based on various diagnostic methods. In our study, the GTV_{PET} volumes turned out to be larger than the GTVCT volumes in 13 patients (54%) but smaller in 11 patients (46%). Publications related to other locations, e.g., esophagus or lung, have also shown significant changes in the volume of interest region after the application of PET. As in our study, some patients exhibit reduced while others exhibited increased GTV volumes (Gondi *et al.*, 2007; Leong *et al.*,

2006, Muijs et al., 2009).

In the study by Gondi et al., (2007), in a group of 16 patients with esophagus cancer, the CI was quite low at 0.44. For 62.5% of patients, the additional application of PET with CT resulted as a smaller GTV, but for the remaining patients, it was larger. In the same study, 14 patients with non-small-cell lung cancer (NSCLC) were also evaluated, for whom the CI was 0.46, and the GTVPET/CT was smaller than the GTV_{CT} by 85.7%. Such a high percentage of smaller GTVs for patients with NSCLC after the introduction of PET could be related to a better exclusion of atelectasis. For our patients with gastric cancer, increased uptake of FDG was often observed in the stomach wall, which was not changed in the CT study. These could be cases of a diffuse submucosal infiltration of the cancer or the coexistence of inflammation. In addition, infiltration of the stomach often penetrates in an irregular manner without clear boundaries. Delineation of stomach tumors based on CT is often difficult and is associated with significant inter-observer variability. A study by McCreadie and Oliver (2009) analyzed mistakes during CT evaluations. For all investigated locations, many false negative results were observed for changes in the pathologies of the gastrointestinal tract and pancreas. The tubular structure of the gastrointestinal tract, its many bends, peristalsis and the image of the walls dependent on the fulfillment of the organs make the interpretation of CT difficult. The additional information from PET examination may be more valuable.

Studies concerning tumor delineation of the gastroesophageal junction (Vesprini et al., 2008) the rectum (Buijsen et al., 2012) or the lungs (van Baardwijk et al., 2007) have shown that the use of the FDG_{PET} for RTP significantly reduced inter-observer variability.

In relation to gastric cancer, even in the case of a homogeneous dose of 45 Gy (without a boost to the primary infiltration area), precise designation of the GTV, to which are added additional margins for CTV and PTV, is very important for the effectiveness of therapy (Matzinger et al., 2009).

Grange et al., (2015) showed that the use of PET/CT during the contouring of esophageal cancer (19 patients) induced the delineation of a larger $PTV_{PET/CT}$ than PTV_{CT} for 12 (63%) patients. The average CI for GTV was higher than in the above-mentioned research and amounted to 0.74, while for PTV, the CI was 0.82. In 9 cases (47%), the original RT plan for PTVCT provided less than 95% of the reference dose to 95% of the PTVPET/CT volume. This could be a potential cause of geographical error. Three patients could not be treated radically because the primary tumor or lymph nodes were too large. For the remaining patients whose RT was planned based on the CT (total dose 45Gy), modification of the target and RT plan based on PET aided in maintaining the safety doses for OAR and obtaining good tolerance of the treatment.

The treatment of the analyzed patients in our study group (24p) was planned taking into account the stomach tumor imaged in the PET/CT study. Although in most cases the final GTV volume was large, for all patients, radical RT (45Gy) was planned in accordance with the tolerance doses for OAR. Dose sparing of the

kidneys, liver and spinal cord is particularly important and difficult to achieve during RTP of advanced gastric cancer (Wydanski and Mohanti, 2008; Hawrylewicz et al., 2016). Therefore, all treatment plans were realized using dynamic techniques: intensity modulated radiation therapy (IMRT) or volumetric arc therapy (RapidArc), which allowed dose to be reduced to the OAR and ensured safe RT (Leszczynski et al., 2016).

Unfortunately, few prospective studies have evaluated the impact of changes in the GTV introduced after the application of PET for further RT results. Muijs et al., (2014) in a prospective study involving 90 patients with esophageal cancer treated with radical RT, also showed the impact of PET examination on changes in GTV volume (larger in 23% of patients and smaller in 27%). Further analysis demonstrated that, in the prevention of locoregional recurrence, treatment plans based on PET/CT had no advantage over plans prepared based on CT diagnostics alone. The study did not evaluate the influence of PET/CT on the dose distribution or toxicity of RT.

Our analysis of the GTV_{CT} vs GTV_{PET} volumes in subgroups of patients with histological diagnosis of IT and DT showed that based on PET, DT tumors, which in theory have worse uptake of the marker, were shown to be an average of 82.3 cm³ smaller compared to histological IT tumors. Considering CT studies, this relationship has been proven to be reversed, as DT tumors are larger by 5.5 cm³ compared to IT tumors. It seems that the weaker tracer uptake in DT gastric cancer can lead to an underestimation of the tumor volume or false negative results, as was described above. In our study, the mean value of SUVmax for DT tumors was lower than that for IT tumors; although the difference was not statistically significant, a trend was observed ($p = 0.0618$). Based on the preclinical Shütze et al., (2007) model, it was postulated that the radiation dose escalation in tumors with higher uptake of FDG exhibited improved local control, while there were no benefits in low-uptake tumors. According to this suggestion, initial FDG-PET/CT may be helpful for defining the subareas that need boosted, particularly in the subgroup of patients with high FDG metabolism.

The cranial dimension of the primary tumor defined based on the PET vs CT studies differed in 96% of patients, while in the caudal dimension differed for 58%. For 67% of patients of the analyzed group, this dimension was higher (average of 20%) according to PET compared to CT. In these patients, GTV_{PET} exceeded the borders of the delineated GTV_{CT} .

A study by Leong et al., (2006) study encompassing 21 patients with esophageal cancer demonstrated that the main reason for the differences between CT and PET/CT studies was the longitudinal extent of the disease. In contrast to our observation, the cranial dimension of the tumor differed for fewer patients than the caudal dimension (75% vs 81%).

A study by Hong et al., (2008) also analyzed the CC borders of esophagus tumors. For 84% of patients, the addition of PET to RTP resulted as a change in the length of the manually delineated GTV.

The important factor is that the acquisition time of PET imaging is much longer than that of fast helical CT and

includes all breathing phases. This gives a blurring effect of the tumor associated with respiratory motion. Due to the physiological mobility of the stomach and adjacent organs, e.g., the liver and kidneys, this information is of great importance during radiation therapy planning (Bettinardi et al., 2012). This may be one of the reasons behind the low CI and large proportion of longer GTV_{PET} compared to GTV_{CT} in our study group, as GTV_{PET} was delineated as a tumor with a “blur” reflecting its mobility.

For RTP, it is very important to perform examinations using a hybrid scanner PET/CT in the therapeutic position and with the appropriate immobilization of the patient. Most current scanners are designed to carry out imaging dedicated for treatment planning and enable automatic image registration. All these features reduce the risk of errors associated with the geographic repositioning of the patient and registration of the CT and PET images performed under different conditions.

To increase the dose at the stomach tumor, the next step of treatment (e.g., 54Gy dose) should be designed with high conformity, taking into account the respiratory motion of this location. To minimize the radiation toxicity for OAR, the best option is to utilize respiratory gating techniques (PET/CT 4-Dimension, 4-D RT) in boosted and treated patients. The 4D gated PET/CT examination can help to establish the tumor boundaries and sparing of normal tissue that is of similar density to the tumor (Chi and Nguyen, 2014). Using this technique, the designated GTV area would be likely smaller than in the classic study not including respiratory motion, which would facilitate the planning procedure of RT (Bettinardi et al., 2012). In our institute, we are currently working on a respiratory gating PET/CT protocol for patients with gastric cancer. Additionally, irradiation at the appropriate respiratory phase would increase the precision of the treatment. Unfortunately, this is a very time-consuming procedure and is a major logistical challenge for the center in the daily, conventional RT.

Using the different SUV threshold levels, we sought to develop methods for auto-segmentation of the GTV volume based on PET, which would help to create a tumor volume that best suits infiltration in the CT scans. In our work, the highest correlation degree between the GTV_{CT} volume and volumes based on PET was the manually delineated tumor volume (GTV_{PET}), followed by MTV_{10} , MTV_{15} , $MTV_{2.5}$, MTV_{20} , MTV_{30} . Low SUV_{max} threshold levels used to create the GTV volume during auto-segmentation tended to be more useful than the widely proposed thresholds, e.g., SUV_{max} thresholds of 40% and 50% in lung cancer (Uto et al., 2010; Edet-Sanson et al., 2012). Previously, our research group showed that low SUV_{max} threshold of 30% and $SUV=2.5$ used to determine the volume parameters (MTV, TLG) for gastric cancer had predictive value (Grabinska et al., 2015). However, in the work by Bilici et al., (2011), the threshold level of SUV was set to 2.3, which allowed for detecting the recurrence of gastric cancer after gastrectomy via PET/CT much more effectively than CT.

Despite the possible error of the subjective interpretation of borders of the pathological uptake of FDG by physicians, the most universal evaluation method

for stomach cancer seems to be the manual method. Due to the fixed thresholds of maximum voxel intensity within tumors, the semi-automatic determination of the MTV area based on the cut-off level of SUV can lead to errors depending on the absolute value of SUV_{max} . In cases of very low SUV_{max} (e.g., in DT gastric cancer) $MTV_{10\%}$ corresponds to almost the entire area covered by the ROI, in addition to the physiological uptake in the background region such as by the liver. Therefore, it is always advisable to verify the contours created by auto-segmentation methods.

To establish the most useful method to determine the GTV volume, it would be ideal to compare the tumor size evaluated in CT and PET with histopathological assessments. Unfortunately, for our patients, this was impossible. Such an evaluation was performed by Buijsen et al., (2011) in relation to the length of rectal tumors. The PET/CT imaging was the most highly correlated with the length assessed in the postoperative study, especially for automatic segmentation of the MTV with a signal-to-background ratio (SBR) method (Pearson correlation = 0.91; $p < 0.001$) and manually measured tumor lengths via PET (Pearson correlation = 0.72 and 0.76 for two different observers). For the manual method, the inter-observer correlation between the two PET observers was very high (Pearson correlation = 0.97, $p < 0.001$). Length designated by MRI was less correlated with the HP study, although significant (Pearson correlation = 0.55 and 0.57 for two different observers; $p < 0.001$), and the inter-observer correlation between the two MRIs was lower than for PET (Pearson correlation = 0.78; $p < 0.001$). Measurements based on the CT study showed no valuable correlation with pathological evaluations (Pearson correlation = 0.34; $p = 0.09$), and the inter-observer correlation between the two CTs was the lowest among all the analyzed methods (0.69; $p < 0.001$). In another study that assessed tumor length of the esophagus, Rollins et al. (2015) showed that measurements made by FDG-PET/CT were better correlated with postoperative histopathology than measurements made by endoscopic ultrasound (EUS) or upper gastrointestinal endoscopy.

The impact of PET/CT for RTP to re-verify the advancement of cancer is also significant. Because of the possibility of rapid disease progression, it is a valuable assessment too that can be directly used during the RTP (Dębiec and Wydmanski, 2016). The previously cited Leong's et al., (2006) study on patients with esophageal cancer showed that the disease stage changed in 8/21 patients. Four patients were diagnosed distant metastasis, and for 4 patients were diagnosed with unexpected regional nodal spread. Finally, 16/21 patients received definitive CRT with treatment planning based on 18-FDG-PET/CT. In our study group, distant metastasis was detected in 3 patients (12.5%) upon PET/CT examination during the RTP. These patients were excluded from the radical treatment, which allowed them to avoid ineffective, long-term therapy. They were administered palliative chemotherapy.

A limitation of this study is the sample size and retrospective nature of the work. This study is the first summary of the observations of the use of PET/CT in

RT of gastric cancer in our center. We have focused on methods of designating GTV volume, as we plan to use such methods to implement prospective studies related with the increase in the total dose of RT in tumors localized in the stomach. Previous studies on NSCLC (Aerts et al., 2009), the pancreas (Wilson et al., 2014) and colorectal cancer (Lambin et al., 2011) have demonstrated that the residual areas of tumor revealed by PET/CT imaging after RT coincided with the location of the highest FDG uptake in pretreatment examination. Therefore, in the absence of the possibility to escalate the dose to the tumor, it seems reasonable to boost smaller areas with the highest uptake. Unfortunately, because of the low sensitivity for detecting metastatic lymph nodes for gastric cancer (Cui et al., 2013) diagnostic PET does not seem to be appropriate for designating the nodal boost region. Another disadvantage is that the spatial resolution of PET is much lower than that of CT, which is a problem especially for determining small changes (Cheebsumon et al., 2011).

In summary, 18-FDG-PET/CT has an impact for GTV delineation in gastric cancer RT. Based on our results and clinical experience, it seems that the most appropriate way to use PET during delineation of the target is to perform individualized interpretations of the regions with increased FDG uptake and manually create contours in the context of other clinical data. The automatic segmentation method can now be regarded as complementary to the manual process of contouring. None of the tested algorithms are able to completely replace manually defined GTV volumes, which represents an extremely valuable interdisciplinary collaboration of radiation oncologists, radiologists and nuclear medicine physicians. Today's PET/CT workstation software allows for the creation of outlines of the tumor (in manual, semi-automatic, and automatic modes) via PET scans by an evaluating doctor of nuclear medicine, and the contours can be easily sent to the RTP system. This allows for the possibility of remote collaboration, which could improve the quality and accuracy of RT.

Taking into account our experience in this area and reports of other cancer sites, we believe that the inclusion of hybrid PET/CT to routine diagnostics for gastric cancer RTP is worth considering. More prospective studies are needed to assess the real impact of the application of PET/CT examination in RTP and further clinical outcomes.

Statement conflict of Interest

This manuscript has not been published and is not under consideration for publication elsewhere. None of the authors have any study-related conflicts of interest to disclose.

References

Aerts HJ, van Baardwijk AA, Petit SF, et al (2009). Identification of residual metabolic-active areas within individual NSCLC tumours using a pre-radiotherapy (18)Fluorodeoxyglucose-PET-CT scan. *Radiother Oncol*, **91**, 386-92.
Bettinardi V, Picchio M, Di Muzio N, Gilardi MC (2012). Motion management in positron emission tomography/computed tomography for radiation treatment planning. *Semin Nucl*

Med, **42**, 289-307.
Bilici A, Ustaalioglu BB, Seker M, et al (2011). The role of 18F-FDG PET/CT in the assessment of suspected recurrent gastric cancer after initial surgical resection: can the results of FDG PET/CT influence patients' treatment decision making?. *Eur J Nucl Med Mol Imaging*, **38**, 64-73.
Buijssen J, van den Bogaard J, Janssen MH, et al (2011). FDG-PET provides the best correlation with the tumor specimen compared to MRI and CT in rectal cancer. *Radiother Oncol*, **98**, 270-6.
Buijssen J, van den Bogaard J, van der Weide H, et al (2012). FDG-PET-CT reduces the interobserver variability in rectal tumor delineation. *Radiother Oncol*, **102**, 371-6.
Cheebsumon P, Yaqub M, van Velden FH, et al (2011). Impact of [18F]FDG PET imaging parameters on automatic tumour delineation: need for improved tumour delineation methodology. *Eur J Nucl Med Mol Imaging*, **38**, 2136-44.
Chi A, Nguyen NP (2014). 4D PET/CT as a strategy to reduce respiratory motion artifacts in FDG-PET/CT. *Front Oncol*, **4**, 205.
Cui JX, Li T, Xi HQ, Wei B, Chen L (2013). Evaluation of (18) F-FDG PET/CT in preoperative staging of gastric cancer: a meta-analysis. *Zhonghua Wei Chang Wai Ke Za Zhi*, **16**, 418-24.
De Ruyscher D, Nestle U, Jeraj R, Macmanus M (2012). PET scans in radiotherapy planning of lung cancer. *Lung Cancer*, **75**, 141-5.
Debiec K, Wydmanski J (2016). Gastric cancer metastasis. In 'Introduction to cancer metastasis', Ahmed A. Academic Press is an imprint of Elsevier, London, San Diego, Cambridge, Oxford, pp137-61.
Edet-Sanson A, Dubray B, Doyeux K, et al (2012). Serial assessment of FDG-PET FDG uptake and functional volume during radiotherapy (RT) in patients with non-small cell lung cancer (NSCLC). *Radiother Oncol*, **102**, 251-7.
Globocan (2012). Estimated cancer incidence, mortality and prevalence worldwide in 2012. Available from: <http://globocan.iarc.fr>. Accessed 30 November 2016.
Gondi V, Bradley K, Mehta M (2007). Impact of hybrid fluorodeoxyglucose positron-emission tomography/computed tomography on radiotherapy planning in esophageal and non-small-cell lung cancer. *Int J Radiat Oncol Biol Phys*, **67**, 187-95.
Grabinska K, Pelak M, Wydmanski J, Tukiendorf A, d'Amico A (2015). Prognostic value and clinical correlations of 18-fluorodeoxyglucose metabolism quantifiers in gastric cancer. *World J Gastroenterol*, **21**, 5901-9.
Hawrylewicz L, Leszczyński W, Namysł-Kaletka A, Bronclik I, Wydmański J (2016). Protection of organs at risk during neoadjuvant chemoradiotherapy for gastric cancer based on a comparison between conformal and intensity-modulated radiation therapy. *Oncol Lett*, **12**, 692-8.
Herrmann K, Ott K, Buck AK, et al (2007). Imaging gastric cancer with PET and the radiotracers 18F-FLT and 18F-FDG: a comparative analysis. *J Nucl Med*, **48**, 1945-50.
Hong TS, Killoran JH, Mamede M, Mamon HJ (2008). Impact of manual and automated interpretation of fused PET/CT data on esophageal target definitions in radiation planning. *Int J Radiat Oncol Biol Phys*, **72**, 1612-8.
Kamimura K, Nagamachi S, Wakamatsu H, et al (2009). Role of gastric distention with additional water in differentiating locally advanced gastric carcinomas from physiological uptake in the stomach on 18F-fluoro-2-deoxy-D-glucose PET. *Nucl Med Commun*, **30**, 431-9.
Lambin P, Petit SF, Aerts HJ, et al (2010). The ESTRO Breur Lecture 2009. From population to voxel-based radiotherapy: exploiting intra-tumour and intra-organ heterogeneity for

- advanced treatment of non-small cell lung cancer. *Radiother Oncol*, **96**, 145-52.
- le Grange F, Wickers S, Warry A, et al (2015). Defining the target in cancer of the oesophagus: direct radiotherapy planning with fluorodeoxyglucose positron emission tomography-computed tomography. *Clin Oncol (R Coll Radiol)*, **27**, 160-7.
- Leong T, Everitt C, Yuen K, et al (2006). A prospective study to evaluate the impact of FDG-PET on CT-based radiotherapy treatment planning for oesophageal cancer. *Radiother Oncol*, **78**, 254-61.
- Leszczyński W, Polanowski P, Leszczyńska P, et al (2016). Can we obtain planning goals for conformal techniques in neoadjuvant and adjuvant radiochemotherapy for gastric cancer patients?. *Rep Pract Oncol Radiother*, **21**, 149-55.
- Maehara Y, Hasuda S, Koga T, et al (2000). Postoperative outcome and sites of recurrence in patients following curative resection of gastric cancer. *Br J Surg*, **87**, 353-7.
- Matsuda T, Saika K (2013). The 5-year relative survival rate of stomach cancer in the USA, Europe and Japan. *Jpn J Clin Oncol*, **43**, 1157-8.
- Matzinger O, Gerber E, Bernstein Z, et al (2009). EORTC-ROG expert opinion: radiotherapy volume and treatment guidelines for neoadjuvant radiation of adenocarcinomas of the gastroesophageal junction and the stomach. *Radiother Oncol*, **92**, 164-75.
- McCreadie G, Oliver TB (2009). Eight CT lessons that we learned the hard way: an analysis of current patterns of radiological error and discrepancy with particular emphasis on CT. *Clin Radiol*, **64**, 491-9.
- Muijs CT, Schreurs LM, Busz DM, et al (2009). Consequences of additional use of PET information for target volume delineation and radiotherapy dose distribution for esophageal cancer. *Radiother Oncol*, **93**, 447-53.
- Muijs CT, Beukema JC, Woutersen D, et al (2014). Clinical validation of FDG-PET/CT in the radiation treatment planning for patients with oesophageal cancer. *Radiother Oncol*, **113**, 188-92.
- Mukai K, Ishida Y, Okajima K, et al (2006). Usefulness of preoperative FDG-^{PET} for detection of gastric cancer. *Gastric Cancer*, **9**, 192-6.
- NCCN (2016). Clinical practice guidelines in oncology (NCCN Guidelines). Gastric cancer. Version 3.2016. Available from: http://www.nccn.org/professionals/physician_gls/pdf/gastric.pdf. Accessed 30 November 2016.
- Nestle U, Walter K, Schmidt S, et al (1999). 18F-deoxyglucose positron emission tomography (FDG-PET) for the planning of radiotherapy in lung cancer: high impact in patients with atelectasis. *Int J Radiat Oncol Biol Phys*, **44**, 593-7.
- Park MJ, Lee WJ, Lim HK (2009). Detecting recurrence of gastric cancer: the value of FDG PET/CT. *Abdom Imaging*, **34**, 441-7.
- Ratosa I, Oblak I, Anderluh F, et al (2015). Preoperative treatment with radiochemotherapy for locally advanced gastroesophageal junction cancer and unresectable locally advanced gastric cancer. *Radiol Oncol*, **49**, 163-72.
- Rollins KE, Lucas E, Tewari N, et al (2015). PET-CT offers accurate assessment of tumour length in oesophageal malignancy. *Eur J Radiol*, **84**, 195-200.
- Schütze C, Bergmann R, Yaromina A, et al (2007). Effect of increase of radiation dose on local control relates to pre-treatment FDG uptake in FaDu tumours in nude mice. *Radiother Oncol*, **83**, 311-5.
- Smyth E, Schöder H, Strong VE, et al (2012). A prospective evaluation of the utility of 2-deoxy-2-[(18) F] fluoro-D-glucose positron emission tomography and computed tomography in staging locally advanced gastric cancer. *Cancer*, **118**, 5481-8.
- Stahl A, Ott K, Weber WA, et al (2003). FDG ^{PET} imaging of locally advanced gastric carcinomas: correlation with endoscopic and histopathological findings. *Eur J Nucl Med Mol Imaging*, **30**, 288-95.
- Thorwarth D (2015). Functional imaging for radiotherapy treatment planning: current status and future directions—a review. *Br J Radiol*, **88**, 20150056.
- Uto F, Shiba E, Onoue S, et al (2010). Phantom study on radiotherapy planning using PET/CT-delineation of GTV by evaluating SUV. *J Radiat Res*, **51**, 157-64.
- van Baardwijk A, Bosmans G, Boersma L, et al (2007). PET-CT-based auto-contouring in non-small-cell lung cancer correlates with pathology and reduces interobserver variability in the delineation of the primary tumor and involved nodal volumes. *Int J Radiat Oncol Biol Phys*, **68**, 771-8.
- Vesprini D, Ung Y, Dinniwell R, et al (2008). Improving observer variability in target delineation for gastro-oesophageal cancer—the role of (18F)fluoro-2-deoxy-D-glucose positron emission tomography/computed tomography. *Clin Oncol (R Coll Radiol)*, **20**, 631-8.
- Wilson JM, Mukherjee S, Chu KY, et al (2014). Challenges in using 18F-fluorodeoxyglucose-PET-CT to define a biological radiotherapy boost volume in locally advanced pancreatic cancer. *Radiat Oncol*, **9**, 146.
- Wu CX, Zhu ZH (2014). Diagnosis and evaluation of gastric cancer by positron emission tomography. *World J Gastroenterol*, **20**, 4574-85.
- Wydmański J, Mohanti BK (2008). An appraisal of radiation therapy techniques for adjuvant and neoadjuvant therapy in gastric cancer. *J Radiother Pract*, **7**, 67-75.
- Wydmański J, Grabinska K, Polanowski P, et al (2014). Radiotherapy and chemoradiotherapy as a novel option for the treatment of locally advanced inoperable gastric adenocarcinoma: A phase II study. *Mol Clin Oncol*, **2**, 1150-4.