

RESEARCH ARTICLE

Editorial Process: Submission:10/07/2017 Acceptance:12/13/2017

## Intra-Operative Frozen Sections for Ovarian Tumors – A Tertiary Center Experience

Nur Zaiti Md Arshad<sup>1</sup>, Beng Kwang Ng<sup>1\*</sup>, Noor Asmaliza Md Paiman<sup>2</sup>,  
Zaleha Abdullah Mahdy<sup>1</sup>, Rushdan Mohd Noor<sup>3</sup>

### Abstract

**Background:** Accuracy of diagnosis with intra-operative frozen sections is extremely important in the evaluation of ovarian tumors so that appropriate surgical procedures can be selected. **Study design:** All patients who with intra-operative frozen sections for ovarian masses in a tertiary center over nine years from June 2008 until April 2017 were reviewed. Frozen section diagnosis and final histopathological reports were compared. **Main outcome measures:** Sensitivity, specificity, positive and negative predictive values of intra-operative frozen section as compared to final histopathological results for ovarian tumors. **Results:** A total of 92 cases were recruited for final evaluation. The frozen section diagnoses were comparable with the final histopathological reports in 83.7% of cases. The sensitivity, specificity, positive predictive value and negative predictive value for benign and malignant ovarian tumors were 95.6%, 85.1%, 86.0% and 95.2% and 69.2%, 100%, 100% and 89.2% respectively. For borderline ovarian tumors, the sensitivity and specificity were 76.2% and 88.7%, respectively; the positive predictive value was 66.7% and the negative predictive value was 92.7%. **Conclusion:** The accuracy of intra-operative frozen section diagnoses for ovarian tumors is high and this approach remains a reliable option in assessing ovarian masses intra-operatively.

**Keywords:** Accuracy- frozen sections- ovarian tumors- Malaysia

*Asian Pac J Cancer Prev*, **19** (1), 213-218

### Introduction

Ovarian cancer is a devastating disease as it is often diagnosed late, hence related to poor diagnosis and survival. It is one of the ten leading cancers in the United States with 22,440 estimated new cases and 14,080 deaths in 2017 (Siegel et al., 2017). In Malaysia, there were 3,472 cases diagnosed between 2007 and 2011. The incidence was found to be higher among Chinese followed by Indians and Malay. The normal breakdown percentage of ethnicity in Malaysia were Malay 68.6%, Chinese 23.4%, Indian 7.0%, other 1.0% and non-citizens 10.3% (Press Release, Current Population Estimates, Malaysia, 2014-2016). The lifetime risk is 1 in 158 and more than half of ovarian cancer cases were detected in stages III and IV (Malaysian National Cancer Statistic 2011). In Indonesia, the Jakarta Cancer registry reported that ovarian cancer was among the top three cancers in Indonesia between 2005 and 2007. The incidence was reported as 4.27 per 100,000 (Wahidin et al., 2012). In India, ovarian cancer contributed to 14.4% of female cancers after breast cancer (44.3%) and cervical cancer (41.5%) (Krishnatreya et al., 2014).

Ovarian tumor is commonly diagnosed in women of

all ages, including those of reproductive age group. These women have almost 10% need for surgery and in those who underwent surgery, approximately 13 to 21% were diagnosed with malignant ovarian tumor (Lisa, 2008). Gynaecologists are facing difficulty in clinical diagnosis of ovarian malignancy, as the presentation is insidious and generally asymptomatic in the early stages without any effective screening method for early detection. Moreover, public awareness of risk factors for ovarian cancer is low. A recent local study showed that up to 71% of Malaysia women had low levels of awareness of ovarian cancer risk factors (Keng et al., 2015).

At present, cancer antigen 125 (CA 125) remains the most widely used biomarker for detection and surveillance in the clinical setting despite its low sensitivity and limited specificity (Sölétormos et al., 2016). Among the biomarkers being evaluated is the human epididymis protein 4 (HE4) or combination, which includes the risk of malignancy index (RMI) and risk of malignancy algorithm (ROMA) (Pitta et al., 2013; Shen et al., 2017; Dora et al., 2017). Other methods used to assess the likelihood of malignancy in women who presents with adnexal masses include ultrasonography, computed tomography (CT) scan and magnetic resonance imaging (MRI) (Fischerova and

<sup>1</sup>Department of Obstetrics and Gynaecology, Universiti Kebangsaan Malaysia Medical Centre, Jalan Yaacob Latif, Cheras, 56000 Kuala Lumpur; <sup>2</sup>Department of Pathology; <sup>3</sup>Department of Obstetrics and Gynaecology, Hospital Sultanah Bahiyah, Km 6, Jln Langgar, Bandar Alor Setar, 05460 Alor Setar, Kedah, Malaysia. \*For Correspondence: nbk\_9955@yahoo.com

Burgetova, 2014). However, none of these methods is able to accurately predict the malignant properties of an ovarian mass.

Frozen section (FS) is an intraoperative diagnostic procedure performed on tissue, which is frozen with liquid nitrogen, sectioned with cryostat, stained and viewed under the microscope by a pathologist who has been informed preoperatively. The result will help provide a preliminary diagnosis, hence assisting the operating surgeons to decide on further management especially with regards to the extent of surgery. Other important aspects include diagnosis of the benign or malignant lesions, confirmation of clinical diagnosis of malignancy and marginal status.

FS has been used in various disciplines including management of endometrial pre-malignant lesions (Oz et al., 2014). The FS result reliably predict the final pathology i.e. subtype, grade and depth of myometrial invasion up to 97.5%, 88% and 98.2% respectively (Stephan et al., 2014). An accurate FS is crucial, aiming to avoid extensive debulking surgery and proceed with fertility sparing surgery in the case of benign tumors, and avoiding incomplete surgery and staging in borderline and malignant tumors (Fanfanni et al., 2007).

The use of FS in the diagnosis of ovarian masses was studied by Ilvan et al in 2005 with overall accuracy reported to be as high as 97% (Ilvan et al., 2005). The sensitivity of diagnosing benign, borderline and malignant tumors were 100%, 87% and 87%, whereas the specificity for benign, borderline and malignant tumors were 97%, 98% and 100% (Ilvan et al., 2005).

This study aims to assess the diagnostic accuracy, sensitivity and specificity of intraoperative FS compared to the final histopathological examination (HPE). We also evaluate the reasons for unmatched diagnosis between intraoperative FS and final HPE. With this study, we hope that the use of FS in the management of ovarian mass will be further clarified and the risk of under or over treating the disease will be reduced.

## Materials and Methods

### Study Design

This was a retrospective study reviewing the case records of all patients who underwent intraoperative frozen section evaluation over a span of almost nine years between June 2008 and April 2017 in a tertiary hospital with a gynecology unit.

### Procedure

Approval was obtained from the National Medical Research Register (NMRR) and given the project code NMRR-16-2322-33273 (Investigator Initiated Research, IIR). No funding was required.

Patients' demographic and clinical data, operative details, FS and final HPE report were reviewed from the medical records. The request for intraoperative FS was based on the individual attending gynecologist after preoperative assessment, which includes evaluation of clinical history and examination, biomarkers and radiological imaging. All these information were

informed to the pathologist one week before the scheduled surgery. Intra-operatively, fresh specimens were sent to the histopathology lab where the attending pathologist immediately froze the samples using optimal cutting temperature (OCT) compound. The number of FS in each case depended on the decision of the pathologist. A minimum of two samples were examined for each patient. Once the sample was frozen, it was sectioned in the cryostat machine at a controlled temperature of  $-20^{\circ}\text{C}$ . The pathologist read the slides and conveyed the result to the operating surgeon via direct telephone call to the operation theatre. The remaining tissue after being frozen was fixed in formalin and processed for paraffin embedding. The turn-around time from retrieving the sample until informing the result was around 30 minutes. The FS diagnosis was deferred when there were suspicious features that were not definitely diagnostic. The intraoperative FS diagnoses were compared to the final HPE, which was considered as the gold standard, in each case. The diagnoses were categorized as benign, borderline or malignant. A comparable result meant that the FS diagnosis and the final HPE were identical. Slides from incomparable cases were retrieved and reevaluated by the same pathologist to determine the reasons contributing to the discrepancy between both. Diagnostic accuracy, sensitivity, specificity, positive predictive value (PPV) and negative predictive value (NPV) were calculated.

### Statistical Analysis

All data in the checklist was collected in an electronic database and analyzed using IBM SPSS statistics for Windows, Version 22.0® (Armonk, NY:IBM Corp). Descriptive study was used to summarize the demographic characteristics of the women. The result from frozen section diagnosis was compared with the final HPE and sensitivity, specificity, negative predictive values and positive predictive values were analyzed. The details of all cases with discordant diagnosis between FS and final HPE were reviewed.

## Results

A total of 94 cases of ovarian tumors were examined by intraoperative FS and final HPE. The mean age of patients in the study was  $26.8 \pm 8.5$  years. The majority of patients were pre-menopausal (98.9%), Malays (88.0%) who were married (52.2%) but nulliparous (64.1%). There were no statistically significant differences between benign, borderline and malignant lesions in terms of patient demographics ( $p > 0.05$ ) (Table 1).

Two cases (2.2%) were noted to be metastatic adenocarcinoma of the stomach and leukemia. The results for FS and final histopathological diagnoses were identical in both cases. Therefore, there were 92 cases of primary ovarian tumors that were recruited and analyzed. Out of these cases of ovarian tumor, 50 were benign, 24 borderline, and 18 malignant tumors after intraoperative FS evaluation (Figure 1). Among 50 cases of benign tumors reported by intraoperative FS, 43 were confirmed in the final HPE. A total of 7 cases were under-reported, 5 confirmed borderline and 2 confirmed to be malignant

Table 1. Patients' Demographic Characteristics

Characteristic	Total n=92	Benign n=45	Borderline n=22	Malignant n=25	p value
Age, years	26.8 ± 8.552	27.0 ± 8.725	27.4 ± 7.295	25.8 ± 9.472	0.829
Ethnicity, n (%)					
Malays	81 (88.0)	39 (86.7)	21 (95.5)	21 (84.0)	
Chinese	4 (4.3)	1 (2.2)	1 (4.5)	2 (8.0)	0.568
Indian	3 (3.3)	2 (4.4)	-	1 (4.0)	
Others	4 (4.3)	3 (6.7)	-	1 (4.0)	
Nulliparous, n(%)	59 (64.1)	29 (64.4)	13 (59.1)	17 (68.0)	0.916
Married, n (%)	48 (52.2)	25 (55.6)	12 (54.5)	11 (44.0)	0.672
Pre-menopause, n (%)	91 (98.9)	44 (97.8)	22 (100.0)	25 (100.0)	0.654

All data were expressed in mean ± standard deviation unless specified.

Table 2. Correlation between Intraoperative Frozen Sections with Final Histopathological Examination (HPE)

Frozen section	Final HPE			Total (n)
	Benign	Borderline	Malignant	
Benign	43	5	2	50
Borderline	2	16	6	24
Malignant	0	0	18	18
Total (n)	45	21	26	92

lesions in the final HPE. On the other hand, among 24 cases of borderline tumors, 6 cases were underreported in the final HPE and 2 were over-reported and confirmed to be benign lesions at the final HPE. In comparison, all 18 cases of malignant tumors during FS evaluation were confirmed malignant at the final HPE (Table 2). Of the 45 cases of benign tumours confirmed during final HPE, 15 were benign serous cystadenoma, 17 were benign mucinous cystadenoma, 3 were endometrioma and 10 were mature cystic teratoma. Therefore, there were 77 cases (83.7%) of ovarian tumors evaluated by intraoperative FS that were comparable to the final HPE.

The sensitivity of intraoperative FS for benign and malignant ovarian tumors were 95.6% and 69.2% respectively, whereas the sensitivity for borderline tumors was 76.2%. The specificity of intraoperative FS for benign, borderline and malignant tumors were 85.1%, 88.7% and 100.0% respectively (Table 3).

In this study, all patients were subjected to surgical intervention, either fertility sparing or debulking. For benign ovarian tumors, 27 cases (54.0%) underwent cystectomy and 22 cases (44.0%) underwent unilateral salpingo-oophorectomy. One

Table 3. Diagnostic Value of Intraoperative Frozen Section for Benign, Borderline and Malignant Lesions

	Benign	Borderline	Malignant
Accuracy (%)	85.9	91.3	91.3
Sensitivity (%)	95.6	76.2	69.2
Specificity (%)	85.1	88.7	100
Positive Predictive Value (%)	86	66.7	100
Negative Predictive Value (%)	95.2	92.7	89.2
False Positive Rate (%)	14	33.3	0
False Negative Rate (%)	4.7	7.3	10.8

Table 4. Type of Surgery Performed According to Final Intraoperative Frozen Section

Surgery	Total n=92	Benign n=50	Borderline n=24	Malignant n=18
Cystectomy	29 (31.5)	27 (54.0)	2(8.3)	-
Unilateral SO	54 (58.7)	22 (44.0)	20 (83.4)	12 (66.7)
TAHBSO	1 (1.1)	1 (2.0)	-	-
TAHBSO + Omentectomy +PLND	8 (8.7)	-	2 (8.3)	6 (33.3)

SO, Salpingo-oophorectomy; TAHBSO, Total abdominal hysterectomy bilateral salpingo-oophorectomy; PLND, Pelvic lymph node dissection

patient underwent total abdominal hysterectomy and bilateral salpingo-oophorectomy (TAHBSO) despite the intraoperative FS showing a benign lesion.

The majority of patients (83.4%) with borderline

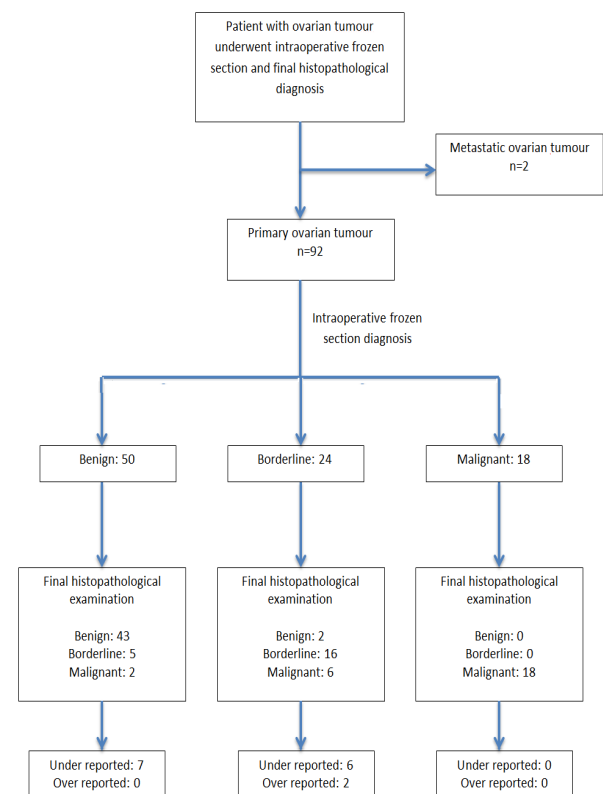


Figure 1. Summary of Results for Intraoperative Frozen Section and Final Histopathological Diagnosis

Table 5. Unmatched Frozen Section Diagnosis

Frozen section	HPE diagnosis	n	
Benign – mature teratoma	Immature teratoma	2	Non representative sample Foci of immature areas not sampled during FS
Benign mucinous tumour	Borderline mucinous tumour	4	Non representative sample Frozen sample not representative Size of tumour : 175mm to 300mm No. of FS : 2 – 3
Benign epithelial tumour	Borderline serous tumour	1	Non representative sample Frozen sample not representative Size of tumour : 165mm No. of FS : 2
Borderline mucinous tumour	Benign mucinous tumour	2	Overestimation due to very huge ovarian tumour Size of tumour : 230mm and 300mm No. of FS : 3
Borderline mucinous tumour	Malignant mucinous tumour	4	Non representative sample Foci of malignant stromal invasion not sampled during FS Size of tumour : 135 – 210mm No. of FS : 2 – 3
Borderline epithelial tumour	Malignant endometrioid tumour	1	Non representative sample Frozen sample not representative Size of tumour : 60mm No. of FS : 3
Borderline epithelial tumour	Malignant monodermal teratoma with somatic type tumour (Papillary carcinoma)	1	Interpretational error Colloid materials seen in FS mimics mucinous tumour and papillary structures mimic borderline features.

ovarian tumors had fertility sparing surgery, two (8.3%) underwent cystectomy and the other two were treated by TAHBSO, omentectomy and pelvic lymph node dissection (PLND). In patients with malignant ovarian tumors, one third of them (6/18) was subjected to TAHBSO, omentectomy and PLND. Twelve cases (66.7%) had unilateral salpingo-oophorectomy (SO) (Table 4).

Amongst 15 unmatched FS and HPE diagnoses, two were benign teratoma on FS, however final HPE revealed immature teratoma. Four benign mucinous and one benign serous tumor were under reported and final HPE confirmed borderline lesions. Two borderline mucinous tumors were over reported and final HPE revealed benign lesions. However, another 4 borderline mucinous tumors were under reported and final HPE confirmed malignant tumors. All these borderline tumors were of mucinous type. There was one borderline epithelial tumor diagnosed during FS which was confirmed to be malignant endometrioid carcinoma on final HPE whilst the other borderline epithelial tumor was confirmed to be a malignant monodermal teratoma with somatic type tumor (Table 5). Majority of the discrepancy between the FS and final HPE results were due to sampling errors as frozen samples may not be representative.

## Discussion

Up until today, there is no recommended preoperative evaluation to determine the histology of an ovarian tumor. Most patients present with noticeable abdominal mass and there is no way to determine its malignant potential except through surgery. Intraoperative FS evaluation may help the gyne-oncology team to decide on the type of surgery

for patients with ovarian tumor, especially when fertility is a concern.

The accuracy of frozen section is very important. Studies have established that frozen section diagnosis of ovarian tumors is a reliable technique, with overall accuracy ranging from 71.9% to 97% (Tempfer et al., 2007; Ilvan et al., 2005). In this study, the rate of accurate diagnosis by intraoperative FS was 83.7%, which is consistent with previous reports. The sensitivity of FS for a benign tumor from our observation was 95.6%. Previous studies also reported a high sensitivity ranging from 92.8% - 100% (Ivanov et al., 2005; Ilvan et al., 2005; Suprasert et al., 2008). Five borderline tumors were diagnosed as benign on FS and four of these were mucinous tumors. Foci of immature tissue were seen in two cases reported as mature cystic teratoma on FS. Mature cystic teratomas usually contain neuroectodermal, endodermal and mesodermal elements. The cyst wall may be lined by respiratory epithelium or contain glial tissue with immature or embryonal tissues within. This area may not have been sampled during intraoperative FS and was only detected upon paraffin section during the final HPE.

In our study, we found that the sensitivity for borderline tumors was 76.2%. Similarly, a few previous studies also reported low sensitivity values for borderline tumor (Ivanov et al., 2005; Ilvan et al., 2005; Suprasert et al., 2008; Tempfer et al., 2007). There were 13 frozen section examinations, which were incomparable with the final paraffin section, and of these, eleven were of the mucinous type. Mucinous tumors are usually large with heterogeneous component with a mixture of benign, borderline and malignant components in the same tumor, making it difficult to diagnose (Twaalfhoven et al., 1991;



Baker and Oliva, 2008; Suprasert et al., 2008). A study reported that tumor diameter was the only independent predictor of incongruent FS diagnosis compared to paraffin section for borderline tumors. Over diagnosis and under diagnosis were identified in 6.6% and 30.6% of cases, respectively (Tempfer et al., 2007). This indicates that large tumors should be investigated and interpreted with caution. Wang et al., (1998) suggested at least one FS for every 10cm of tumor diameter to help improve the rate of comparable diagnoses for mucinous tumors. However, due to the turnaround time from receiving the specimen to reporting the result to the operating surgeon, the possibility of multiple frozen sections is limited especially in large tumors. In our center, the average number of FS was 2.7 sections per tumor. Accuracy was enhanced by sampling macroscopically solid areas for better diagnosis. If a borderline tumor is reported by FS and informed to the surgeon, it should be treated as a malignant tumor and if fertility sparing surgery is desired, a unilateral salpingo-oophorectomy is performed followed by regular post-operative surveillance.

Besides the nature of the tumor affecting FS examination, frozen artifact may also cause misinterpretation of FS. The ovarian tumor that was sent to the laboratory, is preferably frozen in liquid nitrogen. It is important that the tissue be frozen as soon as possible to prevent ice crystal formation resulting in artifact and poor morphological preservation of the tissue, rendering poor slide quality and difficulty to obtain a diagnosis. Another factor that may contribute to misinterpretation is the presence of necrosis. A tumor that has become necrotic following torsion might have limited tissue available for FS evaluation.

A recent Cochrane Database publication that reviewed 38 retrospective studies reported that the average sensitivity in detecting malignant tumor by FS was 90.0% with most studies typically reporting a range of 71% to 100%, and average specificity ranging from 96% to 100% (Ratnavelu et al., 2016). In our study, the sensitivity of detecting malignant ovarian tumor was 69.2% and the specificity was 100%, reflecting that FS examination was highly specific in diagnosing ovarian malignancy. The sensitivity was slightly lower as compared to other studies (Tempfer et al., 2007; Oz et al., 2014). It is very important to correctly detect malignant ovarian tumors as it determines the type of surgery that should be done. As most of our patients were in reproductive age (mean age 26.8 years), fertility is a very important issue in determining the appropriate type of surgery. In this group, seven patients underwent debulking surgery based on FS reports of malignancy, which were all comparable to the final paraffin section results. There were 8 cases that were actually malignant but were under diagnosed by frozen section.

The first patient was diagnosed with immature teratoma and had undergone cystectomy. Post operatively she was counseled for chemotherapy (Bleomycin – etoposide – cisplatin regime) for 3 to 4 cycles but patient refused. Currently she was still under our follow up and there was no evidence of recurrence after one year. The second patient was diagnosed to have mucinous cystadenocarcinoma and she underwent

cystectomy in 2012. She refused adjuvant chemotherapy and relaparotomy. She had caesarean section and unilateral SO in 2015. There was no evidence of recurrence until now. The third patient had TAHBSO + omentectomy + PLND though FS reported borderline tumour as intraoperative findings were consistent with malignant ovarian tumour. HPE revealed malignant mucinous adenocarcinoma. The remaining 5 patients all underwent unilateral SO. All of them were attending regular follow up at our gynaecology clinic and there were no evidence of recurrence thus far.

A study by Bige et al., (2011) suggested that prevention of sampling errors and misinterpretation, along with efficient communication, may be achieved if the managing pathologist has subspecialty training in gynecological pathology. The gyne-oncology team should be able to communicate with the anesthetist and pathologist preoperatively if FS is needed during surgery. A complete clinical history and intraoperative findings should be conveyed to the pathologist as it may help the pathologist reach the correct diagnosis especially in problematic cases. Despite the advancements in histological and molecular techniques, FS clearly remains a valuable tool to consider during operative procedures.

The strength of this study was the fact that all slides from both FS and final HPE for all the unmatched cases were traced and reevaluated by the pathologist to determine the possible reason for any difference in the result or interpretation. However, several limitations were identified in this study. Firstly, the sample size was limited and the number of borderline tumors was only 21 cases. Secondly, we did not have all the data on the progress of the patients after the intraoperative FS and surgery. Thirdly, the cost effectiveness of intraoperative FS was not assessed in our study. Lastly, if another blinded pathologist was recruited to determine the contributing reasons to the discrepancy, perhaps this could reduce our study bias.

In conclusion, the accuracy of intra-operative FS for ovarian tumors is high, hence it remains a reliable option in assessing ovarian masses intra-operatively. The use of FS helps establish the nature of ovarian tumors and determine the surgical management. It also assists in preventing under or over treating an ovarian tumor especially in young patients within the reproductive age group. A multidisciplinary team should be involved in planning a FS. In order to ensure a comparable diagnosis, the clinical presentation should be discussed thoroughly with the attending pathologist. Surgeons should be able to evaluate the patient's clinical history, intraoperative findings and limitations of FS diagnosis and proceed with surgery accordingly.

#### *Submission Declaration*

This study was submitted to the 25th Congress of The Obstetrical & Gynaecological Society of Malaysia as an oral presentation. The congress was held on 27-30th July 2017 at Shangri-La Hotel in Kuala Lumpur, Malaysia.

#### *Contributors*

Nur Zaiti Md Arshad and Noor Asmaliza MP were responsible for preparation of the study proposal for

ethics approval and data collection. Ng Beng Kwang was responsible for the literature review, data analysis and final writing of this study. Zaleha Abdullah Mahdy and Rushdan Mohd Noor were responsible for manuscript correction and proof reading.

## Acknowledgements

The authors have no conflict of interest to declare.

## References

- Baker P, Oliva E (2008). A practical approach to intraoperative consultation in gynecological pathology. *Int J Gynecol Pathol*, **27**, 353-65.
- Bige O, Demir A, Saygili U, et al (2011). Frozen section diagnoses of 578 ovarian tumors made by pathologists with and without expertise on gynecologic pathology. *Gynecol Oncol*, **123**, 43-6.
- Dora SK, Dandapat AB, Pande B, Hota JP (2017). A prospective study to evaluate the risk malignancy index and its diagnostic implication in patients with suspected ovarian mass. *J Ovarian Res*, **10**, 55.
- Fanfanni F, Zannoni GF, Fagotti A, et al (2007). Importance of a specialized pathologist for the examination of frozen sections of adnexal masses. *Int J Gynecol Cancer*, **17**, 1034-9.
- Fischerova D, Burgetova A (2014). Imaging techniques for the evaluation of ovarian cancer. *Best Pract Res Clin Obstet Gynaecol*, **28**, 697-720.
- Ilvan S, Ramazanoglu R, Ulker Akyildiz E, et al (2005). The accuracy of frozen section (intraoperative consultation) in the diagnosis of ovarian masses. *Gynecol Oncol*, **97**, 395-9.
- Ivanov S, Ivanov S, Khadzhiolov N (2005). Ovarian tumours – accuracy of frozen section diagnosis. *Akush Ginekolog (Sofia)*, **44**, 11-3.
- Keng SL, Abdul Wahab SB, Chiu LB, Yusuf A (2015). Awareness of ovarian cancer risk factors among women in Malaysia: a preliminary study. *Asian Pac J Cancer Prev*, **16**, 537-40.
- Krishnatreya M, Katak AC, Sharma JD, et al (2014). Descriptive epidemiology of common female cancers in the north East India- a hospital based study. *Asian Pac J Cancer Prev*, **15**, 10735-8.
- Lisa G (2008). ACOG releases guidelines on management of adnexal masses. *Am Fam Physician*, **77**, 1320-3.
- Malaysia cancer statistic- data and figure (2007 - 2011). The Malaysian national cancer registry report (MNCR) 2007-2011. Ministry of health, Malaysia [Online].
- Oz M, Ozgu E, Korkmaz E, et al (2014). Utility of frozen section pathology with endometrial pre-malignant lesions. *Asian Pac J Cancer Prev*, **15**, 6053-7.
- Pitta Dda R, Sarian LO, Barreta A, et al (2013). Symptoms, CA 125 and HE4 for the preoperative prediction of ovarian malignancy in Brazilian women with ovarian masses. *BMC Cancer*, **13**, 423.
- Press release. Current population estimates, Malaysia 2014-2016. Available online: <https://www.dosm.gov.my/v1/index.php>.
- Ratnavelu ND, Brown AP, Mallett S, et al (2016). Intraoperative frozen section analysis for the diagnosis of early stage ovarian cancer in suspicious pelvic masses. *Cochrane Database Syst Rev*, **3**, CD010360.
- Shen F, Lu S, Peng Y, et al (2017). Performance of ROMA based on architect CA 125 and HE4 values in Chinese women presenting with a pelvic mass: A multicenter prospective study. *Clin Chim Acta*, **471**, 119-25.
- Siegel RL, Miller KD, Jemal A (2017). Cancer statistic, 2017.

*CA Cancer J Clin*, **67**, 7-30.

- Sölétormos G, Duffy MJ, Othman Abu Hassan S, et al (2016). Clinical use of cancer biomarkers in epithelial ovarian cancer: Updated guidelines from the European group on tumor markers. *Int J Gynecol Cancer*, **26**, 43-51.
- Stephan JM, Samuelson M, McDonald M, et al (2014). Intra-operative frozen section results reliably predict final pathology in endometrial cancer. *Gynecol Oncol*, **133**, 499-505.
- Suprasert P, Khunamornpong S, Phusong A, Settekorn J, Siriaungkul S (2008). Accuracy of intra-operative frozen sections in the diagnosis of ovarian masses. *Asian Pac J Cancer Prev*, **9**, 737-40.
- Tempfer CB, Polterauer S, Bentz EK, Reinthaller A, Hefler LA (2007). Accuracy of intraoperative frozen section analysis in borderline tumors of the ovary: A retrospective analysis of 96 cases and review of the literature. *Gynecol Oncol*, **107**, 248-52.
- Twaalfhoven FC, Peters AA, Trimbos JB, Hermans J, Fleuren GJ (1991). The accuracy of frozen section diagnosis of ovarian tumors. *Gynecol Oncol*, **41**, 189-92.
- Wahidin M, Noviani R, Hermawan S, et al (2012). Population-based cancer registration in Indonesia. *Asian Pac J Cancer Prev*, **13**, 1709-10.
- Wang KG, Chen TC, Wang TY, Yang YC, Su TH (1998). Accuracy of frozen section diagnosis in gynecology. *Gynaecol Oncol*, **70**, 105-10.



This work is licensed under a Creative Commons Attribution-Non Commercial 4.0 International License.