

Diagnostic and Prognostic Value of Talin-1 and Midkine as Tumor Markers in Hepatocellular Carcinoma in Egyptian Patients

Aya H Mashaly^{1*}, Rokiah Anwar², Mohamed A Ebrahim³, Laila A Eissa¹, Mamdouh M El Shishtawy^{1*}

Abstract

Background: Hepatocellular carcinoma (HCC) is a main cause of cancer death all over the world. Treatment and outcome of HCC based on its early diagnosis. This study was conducted to estimate the role of talin-1 and midkine in combination with total antioxidant capacity (TAC) as tumor markers in HCC patients. **Methods:** Serum levels of talin-1 and midkine were measured in 90 Egyptian subjects including 44 patients with HCC, 31 patients with cirrhosis and 15 healthy controls using enzyme-linked immunosorbent assay (ELISA) technique. While a colorimetric method was used for measurement of TAC. **Results:** Serum talin-1 in HCC patients was significantly lower than that in patients with cirrhosis ($P < 0.001$) and normal control ($P < 0.001$). In addition, increased invasion and metastasis correlated with reduced talin-1 level. Serum midkine in HCC patients was significantly higher compared to cirrhotic patients ($P < 0.001$) and normal control ($P < 0.001$). Midkine at a cut off value of 1683 pg/ml showed a sensitivity of (81.82%) and specificity of (83.87%). While alpha-fetoprotein (AFP) at a cut off value of 200 ng/ml had a sensitivity of (52.27%), while specificity was (96.77%). Midkine was positive in 80.9% of HCC patients with negative AFP. Serum TAC was significantly decreased in HCC patients when compared with control group ($P < 0.001$). **Conclusion:** Talin-1 may be implicated in the carcinogenesis and metastasis of HCC and can be used as a useful tumor marker for HCC. Midkine may be a potential diagnostic marker for HCC and may be used in addition to AFP to increase the sensitivity of HCC detection.

Keywords: Talin-1- Midkine- hepatocellular carcinoma- alpha-fetoprotein- total antioxidant capacity

Asian Pac J Cancer Prev, **19** (6), 1503-1508

Introduction

Hepatocellular carcinoma (HCC) is a common primary malignant tumor of the liver. It is one of the most widespread and aggressive cancers all over the world (Liang et al., 2014; Sapisochin et al., 2014). HCC is correlating with poor prognosis and has limited treatment options (Ashworth and Wu, 2014). In Egypt, the increasing incidence of HCC is due to the highest rate of spread of hepatitis C virus (HCV) (Shaker et al., 2013). HCV increased risk of HCC by enhancing fibrotic and cirrhotic changes of the liver (El-Serag and Rudolph, 2007). A lot of HCC patients are diagnosed at advanced stage and their prognosis remain very poor. Early detection of HCC is the best chance for the success of treatments and improvement of the income (Yuen et al., 2000).

AFP is used as a diagnostic tumor marker for HCC. Only about 33% to 65% of HCC patients had high AFP level. Also AFP showed nonspecific increase in 15% to 58% of cirrhotic patients (Zhu et al., 2013). Its poor sensitivity makes a great necessity for new biomarkers for

HCC diagnosis (Teofanescu et al., 2010).

Talin-1 is a cytoplasmic protein that is encoded in humans by TLN1 gene. It has a molecular weight of 270 kDa (2541 amino acids). It has an essential role in regulating the action of the integrins which are a family of cell adhesion molecules, linking integrins to actin cytoskeleton (Kanamori et al., 2011), and it is a focal adhesion protein linked to various adhesion molecules, such as integrins, vinculin, and actin. Talin-1 is important for activation of integrins. As a result of activation, integrins increase cell-to-extracellular matrix (ECM) interactions, so transduce bidirectional signals and finally regulating adhesion, cell growth, apoptosis, and tumor growth (Fang et al., 2014).

Midkine, a small growth factor bounded to heparin with a molecular weight of 13-KDa. It was found in embryonal carcinoma cells. It participates in the early stage of differentiation induced by retinoic acid during embryogenesis (Muramatsu, 2002). Midkine participate in the growth of bone, lung, tooth, kidney and nerve tissues during the midgestation period of embryogenesis

¹Department of Biochemistry, Faculty of Pharmacy, ²Department of Internal Medicine (Gastroenterology and Hepatology Unit), Faculty of Medicine, ³Oncology Center, Mansoura University, Mansoura, Egypt. *For Correspondence: mshisht@mans.edu.eg, ayamashaley@yahoo.com

(Vilar et al., 2002). In normal adults midkine is present at low levels (Dai, 2009). Midkine has an essential role in activities related to carcinogenesis such as proliferation, anti-apoptosis, transformation, migration, and angiogenesis, in many types of tumors, including HCC (Shaheen et al., 2015).

Oxidative stress resulted from impaired balance between the production of reactive oxygen species (ROS) and antioxidant defenses of the body. It leads to DNA damage, mutations and cell death (Kusano C, 2008). The total antioxidant capacity in a sample can be estimated by TAC. It is considered a good test for estimating the total antioxidant status that results from the generation of antioxidants and their utilization by oxidative stress (Cao and Prior, 1998; Bruha et al., 2012).

In this study, we aimed to estimate the role of talin-1, midkine and TAC as tumor markers for HCC.

Materials and Methods

Subjects and Methods

This study was approved by the institutional review board of Faculty of pharmacy Ethical Committee, Mansoura University, and written informed consent was provided by every subject.

The study included 75 patients. Forty-four HCC patients including 11 females and 33 males with a mean age \pm SE of 58.11 ± 1.05 (range, 46-70 years) enrolled from Oncology Center, Mansoura University, Mansoura, Egypt. HCC was suspected clinically by elevated AFP levels, further imaging studies done to detect focal hepatic lesions using abdominal ultrasound then confirmed by computed tomography or magnetic resonance. Barcelona-Clinic Liver Cancer Group diagnostic and treatment strategy (BCLC) was used to define the stage and management of HCC.

Thirty one cirrhotic patients including 13 females and 18 males with a mean age \pm SE of 56.55 ± 1.37 (range, 40-70 years) enrolled from the Specialized Medical Hospital, Mansoura University, Mansoura, Egypt. Liver cirrhosis was diagnosed based on clinical examination, biochemical findings, and ultrasonography. The degree of liver disease was evaluated using Child–Pugh classification.. In addition, 15 healthy individuals including 6 females and 9 males with a mean age \pm SE of 57.11 ± 1.05 (range, 40-69 years) were included. The blood samples were collected once at the period from January to September 2015. Patients with other malignancies or organ dysfunction were precluded.

Blood sampling

After 12-14 hour fasting, 5 ml blood samples were drawn from patients and healthy subjects and left to clot for 20–30 min at room temperature, then centrifuged at 1500 rpm for 10 min. The serum samples were divided and maintained at -80°C until use.

Analysis of Biochemical Parameters

Serum talin-1 was measured using human talin-1 ELISA kit from (Glory Bioscience, Del Rio, TX, USA). Serum midkine was measured using human midkine

ELISA kit from (Boster Biological Technology Company, Pleasanton, CA, USA). Serum AFP was measured using human AFP ELISA kit from (DiaMetra Company, Spello, Perugia Italy). Serum TAC was determined by using a colorimetric kit from (Biodiagnostic, Giza, Egypt).

Statistical analysis of the data

Data were analyzed using Statistical Package for the Social Sciences (SPSS) version 20.0. The statistical significance was taken at $P < 0.05$. Number and percent were used for describing qualitative data. Minimum, maximum and mean \pm standard error (Mean \pm SE) was used to represent quantitative data. Chi-square test was used for testing categorical variables, if chi square test was not applicable; Fisher's exact test was used. Comparison between the three studied groups were analyzed using analysis of variance (ANOVA) and Post Hoc test [Fisher's least significant difference (LSD)] for pair-wise comparisons. Pearson coefficient was used to analyze the correlations between two quantitative variables.

Results

Serum AFP concentration

HCC patients showed significantly higher AFP levels than cirrhotic patients and control group ($p < 0.001$). There was no significant difference between cirrhotic patients and normal control group ($p = 0.201$) (Table 1).

Serum Talin-1 level

HCC patients showed highly significant decrease in talin-1 concentration than cirrhotic patients and normal controls ($p < 0.001$) and cirrhotic patients showed highly significant decrease in talin-1 concentration than control group ($p < 0.001$) (Table 1) and (Figure 1).

Serum midkine concentration

HCC patients showed highly significant increase in midkine concentration than cirrhotic patients and normal controls ($p < 0.001$) and Cirrhotic patients showed highly significant increase in midkine concentration than control group ($p < 0.001$) (Table 1) and (Figure 2).

Serum TAC

HCC patients showed highly significant decrease in TAC when compared with control group ($p < 0.001$), while there was no significant difference when compared with cirrhotic patients (Table 1) and (Figure 3).

Correlation between Talin-1, Midkine and TAC with different parameters within Cirrhotic and HCC groups

Our study found significant negative correlation between talin-1 and total bilirubin in HCC patients ($p = 0.011$). TAC showed significant negative correlation with serum ALT in HCC ($p = 0.009$) and cirrhotic patients ($p = 0.005$) and significant positive correlation with albumin in cirrhotic patients ($p < 0.001$). There was also significant negative correlation between TAC and tumor size in HCC patients ($p < 0.001$).

Table 1. Serum Concentration of AFP, Talin-1, Midkine and Total Antioxidant Capacity in HCC Patients as Compared to Cirrhotic Patients and Control Group (Mean ± SE).

	Control (n=15)	Cirrhosis (n=31)	HCC (n=44)
AFP (ng/ml)	4.57± 0.94	14.9 ± 6.58	419.16 ± 68.22 ^{s*}
Talin-1 (pg/ml)	178.57 ± 19.13	94.62 ± 12.54 ^s	30.45 ± 3.82 ^{s*}
Midkine (pg/ml)	758.33 ± 68.10	1358.03 ± 57.68 ^s	1847.22 ± 66.29 ^{s*}
TAC (mM/L)	1.21± 0.02	0.82 ± 0.01 ^s	0.80 ± 0.01 ^s

n, number of subjects in each group; \$, Significance against control group (p<0.001); *, Significance against cirrhotic group (p<0.001).

Relation between talin-1 (pg/ml) with different characters in HCC patients

To further investigate the possible role of Talin-1 in HCC, we analyze the relation between serum talin-1 in HCC patients and some tumor characteristics such as number of lesions, portal vein tumor thrombus, metastasis and BCLC score by statistical analysis.

As shown in Table 2, there was no significant difference between talin-1 level and ascites or number of lesions (P>0.05). However, talin-1 was significantly decreased greatly in presence of portal vein invasion, metastasis and high BCLC score.

Performance of biomarkers

Table 3 shows specificity, sensitivity, positive and negative predictive values (PPV, NPV) of serum talin-1, midkine and AFP in HCC patients relative to liver cirrhosis group.

Diagnostic performance of serum midkine compared with AFP in hepatocellular carcinoma

Although midkine and AFP were found to have comparable specificity for HCC diagnosis, the sensitivity of midkine was higher than that of AFP (Table 3).

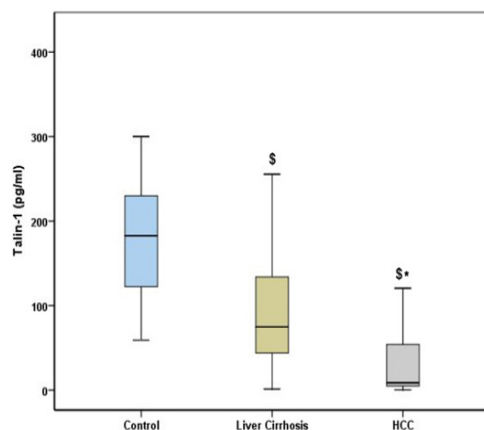


Figure 1. Serum Talin-1 Concentration in Patients with Hepatocellular Carcinoma (HCC), Liver Cirrhosis and Control Subjects. \$, Significance against control group; *, Significance against cirrhotic group.

Table 2. Relation between Talin-1 (pg/ml) with Different Characters in Hepatocellular Carcinoma (HCC) Patients.

	n	Serum Talin-1 level (pg/ml) (Mean ± SE)	P
Ascites			
Absent	20	24.52 ± 2.49	0.416
Present	24	35.40 ± 4.48	
No lesions			
Single	12	21.54 ± 1.98	0.782
Multifocal	32	33.80 ± 3.53	
BCLC			
A – B	18	40.46 ± 4.54	0.006
C – D	26	23.53 ± 2.15	
Metastasis			
No metastasis	18	48.75 ± 5.13	0.012
Metastasis	26	17.79 ± 1.88	
Portal vein invasion			
patent	27	43.01 ± 4.16	<0.001
Thrombosed	17	10.51 ± 1.31	

n, number of subjects

Performance of serum midkine for the diagnosis of hepatocellular carcinomas with negative AFP

Among HCC cases, 21 out of 44 patients (47.7%) were AFP negative. Midkine was positive in (80.9%) (17/21) of AFP-negative HCC patients. Thus the combined determination of midkine and AFP increases the sensitivity to 90.9% without seriously compromising the specificity. The combined markers test accuracy increased to 88% .

ROC curve analysis

ROC curve analysis showed area under the curve (AUC) for talin-1(0.810), midkine (0.831) and for AFP (0.90) (Figure 4).

Midkine/Talin-1 ratio for diagnosis of HCC

ROC curve analysis of the midkine/talin-1 ratio showed area under the curve (AUC) (0.88) which was statistically significant (p<0.001). The midkine/talin-1

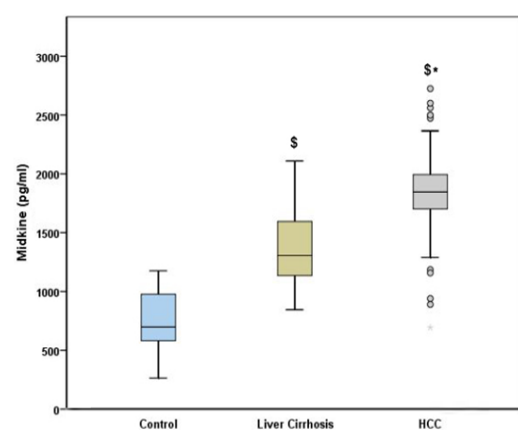


Figure 2. Serum Midkine Level in Patients with Hepatocellular Carcinoma (HCC), Liver Cirrhosis and Control Subjects. \$, Significance against control group; *, Significance against cirrhotic group.

Table 3. Sensitivity and Specificity Values for Talin-1, Midkine and AFP in Hepatocellular Carcinoma (HCC) Patients vs. Cirrhotic Patients

	Cut-off value	Cirrhosis	HCC	Sensitivity	Specificity	PPV	NPV	Accuracy
Talin-1	>33.44	25	12	72.73	80.65	84.2	67.6	76
	<33.44	6	32					
Midkine	<1683	26	8	81.82	83.87	87.8	76.47	82.67
	>1683	5	36					
AFP	<200	30	21	52.27	96.77	95.83	58.82	70.67
	>200	1	23					

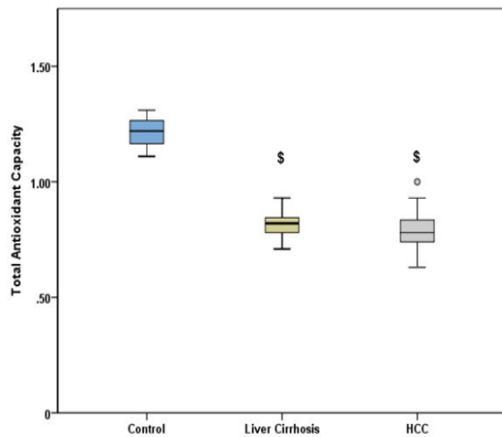


Figure 3. Serum Total Antioxidant Capacity Level in Patients with Hepatocellular Carcinoma (HCC), Liver Cirrhosis and Control Subjects. \$, Significance against control group.

ratio at a cutoff point 29 achieved both sensitivity and specificity of 82% for diagnosis of HCC (Figure 5). Midkine alone showed AUC (0.83), with sensitivity of 81% and specificity of 83%. In addition, talin-1 showed AUC (0.81), with sensitivity of 72% and specificity of 80%. The midkine/talin-1 ratio achieved the best sensitivity and comparable specificity in comparison with midkine or talin-1 alone.

Discussion

HCC is the fifth most prevalent cancer all over the

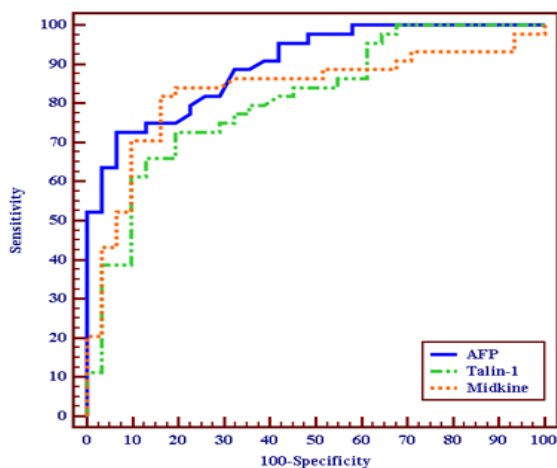


Figure 4. ROC Curve for Talin-1, Midkine and AFP to Diagnose HCC Patients.

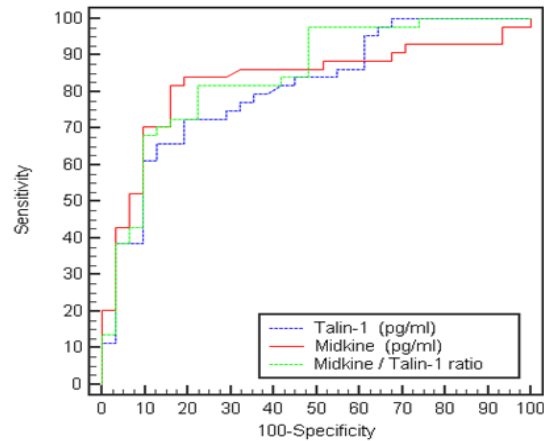


Figure 5. ROC Curve for Talin-1, Midkine and Midkine/talin-1 Ratio for Diagnosis of Hepatocellular Carcinoma (HCC).

world and the third most widespread cause of cancer death (Farazi and DePinho, 2006). HCC is not often discovered early and is generally lethal in a few months of diagnosis (Thomas and Zhu, 2005). In Egypt, HCV infection has a great importance in the etiology of HCC, it is responsible for 40-50% of HCC cases (Omar et al., 2013). For HCC management, early diagnosis of HCC is very important issue. Although AFP is used by oncologists for assessing HCC besides imaging techniques, it is not completely dependable marker due to its low sensitivity. So there is a need for new biomarkers with better sensitivity for diagnosis of HCC (Makuuchi et al., 2008).

Talin-1 is an integrin regulatory protein that arranges interactions of integrin with ECM (Sakamoto et al., 2010). It is necessary for cell motility and adhesion and is the basic talin component of focal adhesions (Youns et al., 2013). Cell adhesion is a pivotal factor in cell motility in embryogenesis, inflammation, wound healing and neoplasm metastasis. Formation of focal adhesions is induced by cell adhesion and is a controlled process which is implicated in cellular movement. Invasion into surrounding tissues is a character of tumor cells, and mechanisms that regulate cell motility are crucial in this process (Zhang et al., 2011).

In our study, HCC patients showed significantly lower talin-1 concentration than patient with cirrhosis and normal controls. In addition, talin-1 level was significantly much lower in presence of portal vein invasion, metastasis and in patients of high BCLC score. Talin-1 may be connected to invasion and migration of cancer cells. The

increase in invasion and migration was correlated with low talin-1 level. The results show that the decreased talin-1 level may give more chances for cancer cells to invade and metastasize and this result was in agreement with Zhang et al., (2011).

The loss of talin in tumor tissue give the chance for cancer cell to detach from the primary tumor and invade surrounding stroma due to loss of cell adhesion, finally lead to tumor angiogenesis and development (Slater et al., 2007).

The disruption of tumor cell adhesion is the first step of invasion and metastasis of tumor cells (Liang et al., 2003). Cancer cells usually exhibit a decrease in cell-cell and/or cell-matrix adhesion. This decrease in cell adhesion correlates with invasion and metastasis of the tumor (Cavallaro and Christofori, 2001). The metastasis rely on the loss of adhesion between cells, so the cell is separated from the tumor and get a motile phenotype through the alteration in interaction of the cell with matrix (Martin and Jiang, 2009). So as talin-1 is important for cell adhesion, the loss of talin may leads to the loss of cell adhesion which may contribute in invasion and metastasis of tumor cells. This result was in accordance with Fang et al., (2014) and Zhang et al., (2011).

Talin-1 expression in HCC is still argumentative. In agreement with our results, Zhang et al., (2011) and Sun et al., (2015) have proved that HCC tissues had significantly lower protein and mRNA expression of talin-1 compared to non- cancerous and normal liver tissues.

In accordance to our results, Fang et al., (2014) showed that the invasion and migration of liver cancer cells were linked to talin-1 and the increased invasion and migration were correlated with reduced talin-1 expression.

On the other hand talin-1 has been identified by proteomic analysis of liver homogenate of living donor liver transplantation as a promising marker for HCC and that talin-1 elevation is linked to HCC development, which means that it may act as a prognostic marker (Kanamori et al., 2011). Also, Youns et al., (2013) reported that HCC patients showed significant increase in serum talin-1 levels compared to cirrhotic patients and normal controls.

Midkine activates several cell surface receptors to participate in modulating various biological activities. It participates in many cellular processes such as cell growth, survival, migration, and tissue remodeling (Kadomatsu and Muramatsu, 2004). Midkine is significantly increased in different types of cancers and plays pivotal roles in cancer formation. Midkine is involved in the pathogenesis of different diseases especially malignant tumors due to its multifunctional properties (Jono and Ando, 2010).

Our results indicate that, HCC patients showed significant increase in serum midkine levels in comparison with cirrhotic patients and normal controls. This suggests that midkine may be involved in carcinogenesis and development of HCC.

Midkine has been recorded to be involved in many cancer-related activities. Overexpression of midkine promotes cellular proliferation and protects tumor cells from antitumor drugs and autophagocytosis. Midkine has angiogenic and fibrolytic activities that create a suitable microenvironment for the growth of cancer cells

(Sakamoto and Kadomatsu, 2012). Ohuchida et al., (2004) reported that midkine protects HCC cells from apoptosis, it inhibits the activity of caspase-3, which is important in the apoptotic pathway.

Also, our study showed that midkine at cut-off value of 1683 pg/ml showed higher sensitivity than that of AFP at cut-off 200 ng/ml (81.82% versus 52.27%). There was no correlation between midkine and AFP, which indicates that the increase of serum midkine was independent to AFP level. Midkine was positive in 80.9% (17/21) of AFP-negative HCC patients. The sensitivity of HCC detection increased up to 90.9% after combination of AFP and midkine. As a result, serum midkine levels may be used in conjugation with AFP levels to increase the sensitivity of HCC detection. The combination of AFP and midkine may be important for early diagnosis of HCC.

These results are in agreement with that of Zhu et al., (2013) and Shaheen et al., (2015), who found that serum midkine levels were increased significantly in HCC group in comparison with cirrhotic group and healthy control group. They also found that specificities of midkine and AFP for HCC diagnosis at different cut-off values were similar but the sensitivities of midkine were significantly higher than that of AFP.

In order to achieve the best detection of HCC, we analyze the midkine/talin-1 ratio and find its role in detection of HCC. Midkine/talin-1 ratio showed both sensitivity and specificity of 82% for diagnosis of HCC at cutoff value 29. This ratio achieve a sensitivity higher than that of midkine or talin-1 alone. The ratio also achieve a specificity comparable to that of midkine alone and higher than that of talin-1 alone. These results indicate that the midkine/talin-1 ratio may be useful for the detection of HCC and may be used as a promising marker for HCC diagnosis.

Oxidative stress has a key role in the development of HCC. Accumulated reactive oxygen species alter gene expression, lead to DNA damage and lipid peroxidation (El-Ashrawy et al., 2016). Weak antioxidant defenses make the body more vulnerable to diseases. A preventive measure of many diseases or even its management plan can be achieved by Keeping adequate antioxidant levels (Kusano C, 2008). We found that, TAC was significantly lower in HCC patients when compared to the control but there was no significant difference when compared with cirrhotic patients. The decrease of TAC in HCC patients suggested the need of antioxidants to aid in the protection from HCC.

Our results are in agreement with many reports (Yahya et al., 2013; Zhou et al., 2013); these reports observed that TAC was significantly decreased in HCC patients compared to control subjects.

In conclusion, the present study demonstrated that serum talin-1 concentration is significantly decreased while midkine level is significantly increased in patients with HCC as compared to cirrhotic patients and control subjects. Therefore we conclude that, talin-1 may be a promising diagnostic and prognostic marker for HCC with better sensitivity and accuracy than AFP. It may be used as a marker for the severity and aggressiveness of the tumor as it correlated with invasion and metastasis of the tumor.

Midkine may serve as a novel diagnostic marker for HCC with better sensitivity and accuracy than AFP. The combined determination of midkine and AFP increase the sensitivity of HCC detection.

Conflict of Interest

The Authors declare that there is no conflict of interest.

References

- Ashworth RE, Wu J (2014). Mammalian target of rapamycin inhibition in hepatocellular carcinoma. *World J Hepatol*, **6**, 776-82.
- Bruha R, Vitek L, Marecek Z, et al (2012). Decreased serum antioxidant capacity in patients with Wilson disease is associated with neurological symptoms. *J Inher Metab Dis*, **35**, 541-8.
- Cao G, Prior RL (1998). Comparison of different analytical methods for assessing total antioxidant capacity of human serum. *Clin Chem*, **44**, 1309-15.
- Cavallaro U, Christofori G (2001). Cell adhesion in tumor invasion and metastasis: loss of the glue is not enough. *Biochim Biophys Acta*, **1552**, 39-45.
- Dai LC (2009). Midkine translocated to nucleoli and involved in carcinogenesis. *World J Gastroenterol*, **15**, 412-6.
- El-Ashmawy NE, Khedr EG, El-Bahrawy HA, et al (2016). Effect of pomegranate hull extract on liver neoplastic changes in rats: More than an antioxidant. *Nutr Cancer*, **68**, 1044-51.
- El-Serag HB, Rudolph KL (2007). Hepatocellular carcinoma: epidemiology and molecular carcinogenesis. *Gastroenterology*, **132**, 2557-76.
- Fang KP, Zhang JL, Ren YH, et al (2014). Talin-1 correlates with reduced invasion and migration in human hepatocellular carcinoma cells. *Asian Pac J Cancer Prev*, **15**, 2655-61.
- Farazi PA, DePinho RA (2006). Hepatocellular carcinoma pathogenesis: from genes to environment. *Nat Rev Cancer*, **6**, 674-87.
- Jono H, Ando Y (2010). Midkine: a novel prognostic biomarker for cancer. *Cancers (Basel)*, **2**, 624-41.
- Kadomatsu K, Muramatsu T (2004). Midkine and pleiotrophin in neural development and cancer. *Cancer Lett*, **204**, 127-43.
- Kanamori H, Kawakami T, Effendi K, et al (2011). Identification by differential tissue proteome analysis of talin-1 as a novel molecular marker of progression of hepatocellular carcinoma. *Oncology*, **80**, 406-15.
- Kusano C FB (2008). Total antioxidant capacity: a biomarker in biomedical and nutritional studies. *J Cell Mol Biol*, **7**, 1-15.
- Liang L, Li Q, Huang LY, et al (2014). Loss of ARHGDI A expression is associated with poor prognosis in HCC and promotes invasion and metastasis of HCC cells. *Int J Oncol*, **45**, 659-66.
- Liang YL, Lei TW, Wu H, et al (2003). S-phase delay in human hepatocellular carcinoma cells induced by overexpression of integrin beta1. *World J Gastroenterol*, **9**, 1689-96.
- Makuuchi M, Kokudo N, Arii S, et al (2008). Development of evidence-based clinical guidelines for the diagnosis and treatment of hepatocellular carcinoma in Japan. *Hepatol Res*, **38**, 37-51.
- Martin TA, Jiang WG (2009). Loss of tight junction barrier function and its role in cancer metastasis. *Biochim Biophys Acta*, **1788**, 872-91.
- Muramatsu T (2002). Midkine and pleiotrophin: two related proteins involved in development, survival, inflammation and tumorigenesis. *J Biochem*, **132**, 359-71.
- Ohuchida T, Okamoto K, Akahane K, et al (2004). Midkine protects hepatocellular carcinoma cells against TRAIL-mediated apoptosis through down-regulation of caspase-3 activity. *Cancer*, **100**, 2430-6.
- Omar A, Abou-Alfa GK, Khairy A, et al (2013). Risk factors for developing hepatocellular carcinoma in Egypt. *Chin Clin Oncol*, **2**, 43.
- Sakamoto K, Kadomatsu K (2012). Midkine in the pathology of cancer, neural disease, and inflammation. *Pathol Int*, **62**, 445-55.
- Sakamoto S, McCann RO, Dhir R, et al (2010). Talin1 promotes tumor invasion and metastasis via focal adhesion signaling and anoikis resistance. *Cancer Res*, **70**, 1885-95.
- Sapisochin G, de Sevilla EF, Echeverri J, et al (2014). Management of "very early" hepatocellular carcinoma on cirrhotic patients. *World J Hepatol*, **6**, 766-75.
- Shaheen KY, Abdel-Mageed AI, Safwat E, et al (2015). The value of serum midkine level in diagnosis of hepatocellular carcinoma. *Int J Hepatol*, **2015**, 146389.
- Shaker MK, Abdella HM, Khalifa MO, et al (2013). Epidemiological characteristics of hepatocellular carcinoma in Egypt: a retrospective analysis of 1313 cases. *Liver Int*, **33**, 1601-6.
- Slater M, Cooper M, Murphy CR (2007). The cytoskeletal proteins alpha-actinin, Ezrin, and talin are De-expressed in endometriosis and endometrioid carcinoma compared with normal uterine epithelium. *Appl Immunohistochem Mol Morphol*, **15**, 170-4.
- Sun J, Fang K, Shen H, et al (2015). MicroRNA-9 is a ponderable index for the prognosis of human hepatocellular carcinoma. *Int J Clin Exp Med*, **8**, 17748.
- Teofanescu I, Gologan E, Stefanescu G, et al (2010). Surveillance of cirrhosis for hepatocellular carcinoma—clinical validation of new serological biomarkers for improved diagnosis. *Rev Med Chir Soc Med Nat Iasi*, **114**, 39-46.
- Thomas MB, Zhu AX (2005). Hepatocellular carcinoma: the need for progress. *J Clin Oncol*, **23**, 2892-9.
- Vilar J, Lalou C, Duong Van Huyen JP, et al (2002). Midkine is involved in kidney development and in its regulation by retinoids. *J Am Soc Nephrol*, **13**, 668-76.
- Yahya RS, Ghanem OH, Foyouh A, et al (2013). Role of interleukin-8 and oxidative stress in patients with hepatocellular carcinoma. *Clin Lab*, **59**, 969-76.
- Youns MM, Abdel W, Abdel HA, et al (2013). Serum talin-1 is a potential novel biomarker for diagnosis of hepatocellular carcinoma in Egyptian patients. *Asian Pac J Cancer Prev*, **14**, 3819-23.
- Yuen MF, Cheng CC, Lauder IJ, et al (2000). Early detection of hepatocellular carcinoma increases the chance of treatment: Hong Kong experience. *Hepatology*, **31**, 330-5.
- Zhang JL, Qian YB, Zhu LX, et al (2011). Talin1, a valuable marker for diagnosis and prognostic assessment of human hepatocellular carcinomas. *Asian Pac J Cancer Prev*, **12**, 3265-9.
- Zhou L, Yang Y, Tian D, et al (2013). Oxidative stress-induced 1, N6-ethenodeoxyadenosine adduct formation contributes to hepatocarcinogenesis. *Oncol Rep*, **29**, 875-84.
- Zhu W-W, Guo J-J, Guo L, et al (2013). Evaluation of midkine as a diagnostic serum biomarker in hepatocellular carcinoma. *Clin Cancer Res*, **19**, 3944-54.



This work is licensed under a Creative Commons Attribution-Non Commercial 4.0 International License.