

## RESEARCH ARTICLE

Editorial Process: Submission:08/06/2021 Acceptance:12/25/2021

# Black Turmeric and Aloe Vera in the Management of Oral Submucous Fibrosis: A Prospective Clinical Study

Ankita Bohra<sup>1</sup>, T.N.Uma Maheswari<sup>1</sup>, Aditya Harsh<sup>2\*</sup>, Ayush Garg<sup>3</sup>

### Abstract

**Aim:** To determine the therapeutic efficacy of Kali haldi in the management of Oral submucous Fibrosis (OSMF) v/s steroid therapy. **Materials and Methods:** A clinical prospective study was conducted on 42 patients of oral submucous fibrosis were equally divided into 2 groups. Group A patients were treated with a mixture of powdered Kali Haldi and aloe vera gel in equal ratio 3 times a day for 3 months. Group B patients were treated with intralesional injection of hydrocortisone and hyaluronidase for 6 weeks with oral antioxidant supplements for 3 months. Burning sensation, cheek flexibility, mouth opening, and tongue protrusion were evaluated before, during, and after treatment at an interval of 15 days, 1 month, 2, month and 3 months. **Results:** Statistically significant results were obtained at the end of 3 months duration for both the groups ( $P < 0.001$ ). The Symptomatic correction was more evident in the case of Group A patients than Group B. Response of the ayurvedic regimen was potentially better as compared to the regular steroid therapy. **Conclusion:** The study concludes that Combination therapy works wonders in the case of OSMF in stages I, II, III and can be a good option, comparatively safe and with negligible side effects, but potent and equally effective management of oral submucous fibrosis. Henceforth, it will be better to do such kinds of studies on a vast scale including larger samples and longer duration to check the efficacy and durability of this ancient ayurvedic regimen.

**Keywords:** Aloe vera- antioxidant- ayurvedic management- oral submucous fibrosis

*Asian Pac J Cancer Prev*, 22 (12), 3941-3947

### Introduction

Oral submucous fibrosis (OSMF) is considered a potentially malignant condition of the oral cavity, mostly found in Southern and western Countries of the Asian continent. The Principle cause of OSMF is chewing areca nut in the majority of cases. Patients with OSMF have a common complaint of reduced or restricted mouth opening, burning sensation, frequent ulceration, reduced tongue movements, and cheek flexibility. Even muscles of facial expression and mastication show reduced muscle tonicity (Anuradha et al., 2017). Up till now, a lot of treatment protocols have been hypothesized and even tried on patients under clinical trials but there is no such one treatment that shows long-lasting and promising results in the case of OSMF. Therapeutic approaches for OSMF include combination corticosteroid intralesional injections, IFN- $\alpha$ , oral administration of peripheral vasodilators, immune milk, turmeric, lycopene, and micronutrient supplementation (Jayavelu and Sambandan, 2012). Steroids to date are the most accepted modality of treatment for OSMF but the fact is that steroids act as a double-edged sword. The actual sign and symptoms of inflammation in OSMF are not cured rather suppressed

by the use of steroidal injections. So, to overcome this side effect as well as to provide a better treatment option to the patient's well-being, search for some alternative drug is still going on. Out of many alternative treatment modalities, ayurvedic therapy is so far considered to be effective and with minimal side effects reported. Many Ayurvedic products like aloe vera, tulsi, amla, honey have proved to be equally good in treating OSMF cases effectively and economically as well. Aloe vera, Flaxseed, and tulsi combination acts as an adaptogen that acts on the human body and makes our system strong. These herbs help our body to develop immunity against any cytotoxic action of the scavenger radicals and homeostasis of the oral cavity maintained under any stressful condition (Rahmani et al., 2015).

The Biochemical studies of Kali Haldi, also known as *Curcuma caesia roxib* (Figure 1), (*C. caesia*) revealed the presence of multiple phytoconstituents like essential oils with camphor, ar-turmerone, (*Z*) ocemene, ar-curcumene, 1, 8- cineole. It has anti-mutagenic, anti-inflammatory, antioxidant, anti-tumorous properties that show promising results against breast, colon, skin, and rectal cancer (Sarangthem and Haokip, 2010; Ganjre et al., 2015; Rao et al., 2020). Aloe vera contains vitamin A (beta-carotene),

<sup>1</sup>Department of Oral Medicine and Radiology, Saveetha Dental College and Hospitals, Saveetha Institute of Medical and Technical Sciences, Saveetha University, Chennai- 600077, Tamil Nadu, India. <sup>2</sup>Department of Oral and Maxillofacial Surgery, Vyas Dental College and Hospital, Jodhpur, Rajasthan, India. <sup>3</sup>Department of Oral and Maxillofacial Surgery, Mahatma Gandhi Dental College and Hospital, Sitapura, Jaipur, India. \*For Correspondence: dr.adityaharsh@gmail.com

C, and E, which are antioxidants and acts on scavenger free radicals. Important enzymes are present in aloe vera like aliase, alkaline phosphatase, and amylase, bradykinase, etc. acts on the site of inflammation when applied to the skin or oral tissues topically. The polysaccharide present in Aloe vera has anti-cancer and anti-oxidant properties (Anuradha et al., 2017). All such properties of Kali Haldi and aloe vera will act synergistically on mutagens present in oral tissues of OSMF patients and will be considered to be a useful and convenient treatment option for the patient. In this present study, we have a comparative analysis of the combination of Ayurvedic therapy and combined efficacy of Steroidal intralesional injections along with antioxidant supplements.

## Materials and Methods

This study was conducted in the Department of Oral Medicine and Radiology at the Vyas Dental College and Hospital, Jodhpur, India, between November 2020 and January 2021. Approval from the institutional ethical committee (VDCH/IEC/25/2020) was obtained for the study. Patients with OSMF (Stage 2 according to Pindborg et al criteria (Bailoor and Nagesh, 2005) were enrolled in the study. Pregnant women, lactating mothers, patients with other debilitating diseases like diabetes, hypothyroidism, hypertension, renal disorder, etc, patients with a known history of hypersensitivity to any allergen or drugs, and those who had received prior treatment for OSMF, patient history of any other oral lesion or condition along with OSMF were excluded.

Forty-two patients who were ready to co-operate with written consent and attend regular follow-up treatment protocol were included in the study. Out of them, 29 were males and 13 were females age varies from 25 to 65. Informed consent was obtained from all the patients after the nature of the study, and its procedures were explained to all of them thoroughly. But every ingredient used was not revealed to the patient. A thorough clinical examination was carried out, and the following parameters were measured and recorded by an independent examiner. The Biopsy specimen was collected from each patient and sent for histo pathological confirmation for OSMF. Out of various clinical parameters for OSMF, 4 were selected to check and compare the improvement in each patient pre and post-treatment.

1. Burning scale- The patient was asked for a burning sensation in his oral cavity and based on the severity numerical scores was given by using the Visual Analogue Scale.

2. Mouth opening scale- Patients were asked to open the mouth wide as much as he/she can and with the help of metal scale and divider upper central incisor to the lower central incisor and recorded in millimeters.

3. The Cheek flexibility scale (CF) was measured according to the method described by Bailoor and Nagesh (Patil and Maheshwari, 2014).

4. Tongue protrusion was assessed from normal mesio-incisal angle of upper central incisor to the tip of the tongue when maximally extended with mouth wide open (Ramesh and Saba, 2017).

The patients were divided into 2 groups equally with each group having 21 patients with an unequal male to female ratio (Group A and Group B) Group A patients were given pure ayurvedic treatment with combination therapy of Kali Haldi and aloe vera gel (Organically Processed and manufactured under the supervision of the ayurvedic university of Jodhpur). Kali Haldi of Kerala variety was grown and the rhizome of the plant was dried and powdered. Pure aloe vera pulp is been extracted from the leaves of the aloe vera plant. A thick viscous gel is been prepared by mixing the pulp at a high-speed frequency rotation of 400-500 rpm.

Patients were instructed to apply an equal quantity of Kali Haldi (2mg), Aloe vera gel (2 mg) provided to each patient in separate containers with a measuring scoop of 1mg in a ratio of 2:2. Every patient was asked to mix the ingredients in the measured quantity and apply them over the lesion 3 times a day for 3 months. Follow-ups were scheduled every 15days for regular monitoring.

Group B patients were given intralesional injections of hydrocortisone acetate 25 mg/ml and hyaluronidase (1500 IU) weekly for 6 weeks along with an oral topical application of turbocort on the affected areas twice daily. They have also prescribed Cap SM Fibro twice daily for 3 months. Each capsule of SM Fibro Capsule contains Alpha lipoic acid, Beta-carotene, Elemental copper, Lycopene, Vitamin E, and Zinc sulphate used as multivitamin and antioxidant supplement to correct the oxidative damage at cellular level (Patil et al., 2015). Follow-ups were scheduled after the completion of every 15 days till the end of 3 months duration. Clinical findings were checked, assessed, and recorded at an interval of every 15 days till the completion of 3 months by the same inspector who measured the pre-treatment sign and symptoms of the patients. The assigned inspector was not aware of the treatment provided to each group of patients, making it a double-blind study.

### Statistical analysis

Statistical analysis was carried out using SPSS software version 22 (IBM corporation). Intragroup comparison for the study parameters at different time intervals was made using the repeated ANOVA test. Comparative analysis of the two study groups was made using Student's unpaired t-test.

## Results

The study comprised 29 male and 13 female subjects. The mean age of the study population was 29.2. +/- 5.3 years. Areca nut chewing was the most prevalent habit noted (58.9%) of individuals while 16.1% of subjects had a habit of chewing gutka, slaked lime, and areca nut altogether along with paan masala. 12.3% of the subjects reported having only gutka chewing habits. Another 11.8% of subjects had a habit of smoking cigarettes and drinking alcohol. 0.9% of patients did not have any habits. 53.6% of subjects had a habit of >10 years, followed by 29.7% with 5–10 years of habit and 16.7% with <5 years of habit.

Of the 42 study subjects, 7 were lost to follow-up, and the remaining 35 patients continued till the end of 3 months



Figure 1. Black Turmeric Rhizome

Table 1. Comparison of Mean Value of Parameters between Study Groups at Different Time Intervals

Variables	At Baseline			After 1 month			After 2 months			After 3 months		
	Group A	Group B	P value	Group A	Group B	P value	Group A	Group B	P value	Group A	Group B	P Value
burning sensation	6.09 +/-1.34	6.29 +/-1.34	0.6	2.89 +/-1.01	5.13 +/-0.57	0.004*	1.7 +/-0.62	3.29 +/-1.39	0.003*	1.39 +/-0.51	1.23 +/-1.05	0.12
mouth opening	2.1 +/-0.42	2.58 +/-0.73	0.1	3.21 +/-0.47	2.71 +/-0.6	0.06	2.84 +/-0.53	2.80 +/-0.69	0.01*	2.22 +/-0.49	3.22 +/-0.56	0.31
cheek flexibility	0.12 +/-0.04	0.21 +/-0.05	0.003*	0.21 +/-0.08	0.31 +/-0.13	0.02*	0.58 +/-0.09	0.37 +/-0.13	0.001*	0.44 +/-0.03	0.54 +/-0.11	0.004*
tongue protrusion	3.66 +/-0.62	2.52 +/-0.53	0.02*	3.12 +/-0.71	3.67 +/-0.43	0.5	3.23 +/-0.54	3.09 +/-0.63	0.04	3.87 +/-0.62	3.11 +/-0.32	0.02*

\*, Statistically Significant P Value.

duration. Comparison of Group A with Group B patients concerning clinical parameters showed statistically significant changes from baseline till 3-month duration (Table 1). For patients in Group A, the Mean percentage reduction in VAS score for burning sensation at baseline was 47.6 +/- 1.02. At the end of the 1<sup>st</sup>, 2<sup>nd</sup> and third months, burning sensation VAS scores were improved by 57.2, 61.3, and 75.9 percentages respectively.

While, on the other hand, in Group B, the Burning sensation VAS scores recorded from baseline to 3 months were 28.3, 40.2, 46.3, and 57.2 respectively. Both the groups showed a statistically significant ( $P < 0.001$ ) reduction in burning sensation as shown in Figure 1. Mean percentage increase in interincisal mouth opening noticed for Group A subjects from baseline to 3<sup>rd</sup> month was 2.9, 3.5, 4.1, 4.9cm respectively while in group B, values noticed were 2.1, 2.9, 3.8, 4.5 cm after completion of baseline to 1<sup>st</sup>, 2<sup>nd</sup>, and 3<sup>rd</sup> month, respectively. This increase in mean values for mouth opening at the end of 3<sup>rd</sup> month for both the groups was not statistically significant ( $P > 0.001$ ) (Figure 2) at baseline, Group A patients had a mean score of 69.2 for cheek flexibility. Patients showed an increase in cheek flexibility after 1 month with a mean value of 79.5. After the 2<sup>nd</sup> and 3<sup>rd</sup> months, mean values were 86.4 and 92.6 respectively. The results were statistically significant ( $P < 0.001$ ) at the end of 3<sup>rd</sup> month for this group. Group B patients had a noticeable change from baseline to the end of 1st month with a mean % increase in value from 71.8 to 82.7 A sudden increase was seen after the 2<sup>nd</sup> and 3<sup>rd</sup> months with mean scores of 91.3 and 111.4 respectively. (Figure 3) The Mean % increase in tongue Protrusion in Group A at baseline to 3<sup>rd</sup> month was 1.8, 2.0, 2.7, 3.2 respectively while in Group B the value at baseline is 2.1 that gradually increased to 2.5 by the end of 1st month, 3.1 by the end of 2<sup>nd</sup> month and 3<sup>rd</sup> month 3.8 respectively (Figure 4).

Comparison of different study parameters at different intervals between groups revealed a remarkable decrease ( $P < 0.001$ ) in burning sensation in Group A in comparison with Group B at the end of the 3<sup>rd</sup> month. Interincisal mouth opening did not differ significantly ( $P = 0.06$ ) between the 2 groups at the end. An increase in cheek flexibility and tongue protrusion was significantly ( $P = 0.004$  and 0.01, respectively) higher in Group B subjects than in Group A at the end of the 3<sup>rd</sup> month. The

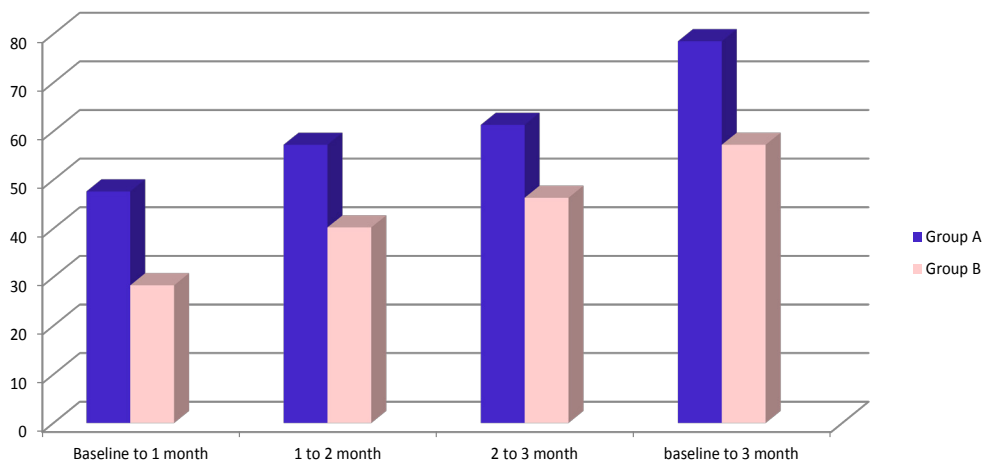


Figure 2. Mean Percentage Reduction in VAS Scores for Burning Sensation

improvement in cheek flexibility was more in Group B while burning sensation reduction was significant in Group A.

### Discussion

To date, we do not have any specific and standardized treatment modality for OSMF patients. The most common treatment option chosen for OSMF patients is intralesional injection. But alternative medicine plays a major role in treatment purposes with the least number of side effects. Many ayurvedic herbs like turmeric, tulsi, ashwagandha, amla, aloe vera, etc have been used in the treatment of pre-cancerous lesions like leukoplakia, and pre-cancerous conditions like lichen planus and OSMF. Combination therapy always worked for OSMF and oral lichen planus patients. The combination of Aloe vera and Spirulina also gives promising results in OSMF treatment (Angel et al., 2014).

Patients with OSMF come with a common complaint of burning sensation and reduced mouth opening. The

cause behind mucosal burning is epithelial atrophy caused by inflammation of juxta epithelial cells. In this study, Group A showed great results in the reduction of burning sensation as compared to group B. both the result were statistically significant as well. The mean percentage reduction in VAS score burning sensation for Group A and Group B was 75.9% and 57.2%, respectively. Reduction in burning sensation was gradual and continuous for both Group A and Group B but more effective results were found in Group A. On contrary, criteria for burning sensation by VAS scores compared in Anuradha et al study showed almost equal results for both Group A (Aloe vera) and Group B (Steroid) therapy (Anuradha et al., 2017).

In this study, Curcuma caesia Roxb, commonly known as black turmeric or Kali Haldi, Kerala variety was used because of the highest curcumin content. Black turmeric was used for the very first time in the treatment of any oral pre-cancerous pathology. The reason behind using black turmeric over regular yellow turmeric is its higher curcumin percentage (Pandey and Chowdhury, 2003; Behura and Srivastava, 2004; Alonso-Amelot, 2016).

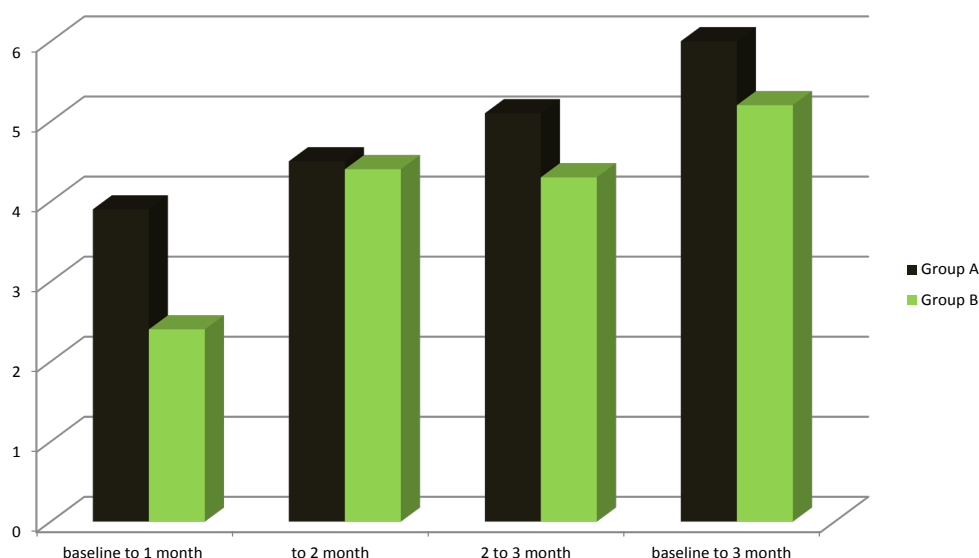


Figure 3. Mean Percentage Increase in Interincisal Mouth Opening

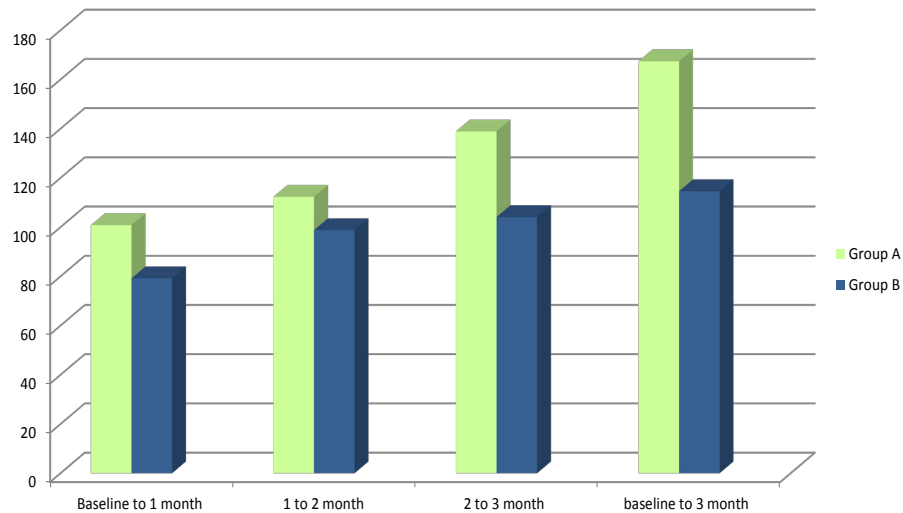


Figure 4. Mean Percentage of Cheek Flexibility

Black turmeric contain ar-curcumene (14.8%) and yellow turmeric contains ar-curcumene (6.3%) (Hossain et al., 2015; Dosoky and Setzer, 2018; Sanatombi and Sanatombi, 2017) Black turmeric have anti-inflammatory, antioxidant anti-ulcer, anti-fibrotic (Devi, 2015), anti-mutagenic (Jurenka, 2009). anti-nociceptive, and anti-bacterial property (Recio et al., 2012; Mangla et al., 2010; Das et al., 2012) potentially better than yellow turmeric (Rajamma and Bai, 2012) The reduction in burning sensation can be attributed to the anti-inflammatory properties of black turmeric due effective action of curcumin as the anti-inflammatory effect is by attenuating inflammatory response of TNF- $\alpha$  stimulated human endothelial cells by interfering with NF $\kappa$ B. The synergistic action of Aloe vera and black turmeric even stimulates the mechanism thus resulting in a better outcome (Abhijeet, 2015). The percentage increase in restricted mouth opening was mainly due to the synergistic action of Kali Haldi along with aloe vera that makes this combination equally potent when compared with steroidal therapy. Tongue

protrusion and cheek flexibility were improved in the case of Group A and Group B respectively and that too was statistically significant. Aloe vera plays a vital role in tongue protrusion and enhancing cheek flexibility by stimulating the fibroblasts and elastin fibers that restore the elasticity of the mucosal tissues.

The results of the present study can be compared with the preliminary study carried out by Sudarsan et al., (2012) and Anuradha et al., (2016). They have reported an improvement in various parameters such as burning sensation, mouth opening, cheek flexibility, and tongue protrusion using aloe vera on OSMF patients. Alam et al., (2013) used aloe vera as an adjunct with dexamethasone, hyaluronidase, and showed statistically significant improvement in various parameters in OSMF patients that are under our study (Alam et al., 2013). Different grades of OSMF are yet to be accessed under the same treatment protocol. Study with larger sample size need to be conducted with complete follow ups. Early stages of OSMF should have been included in the study and the

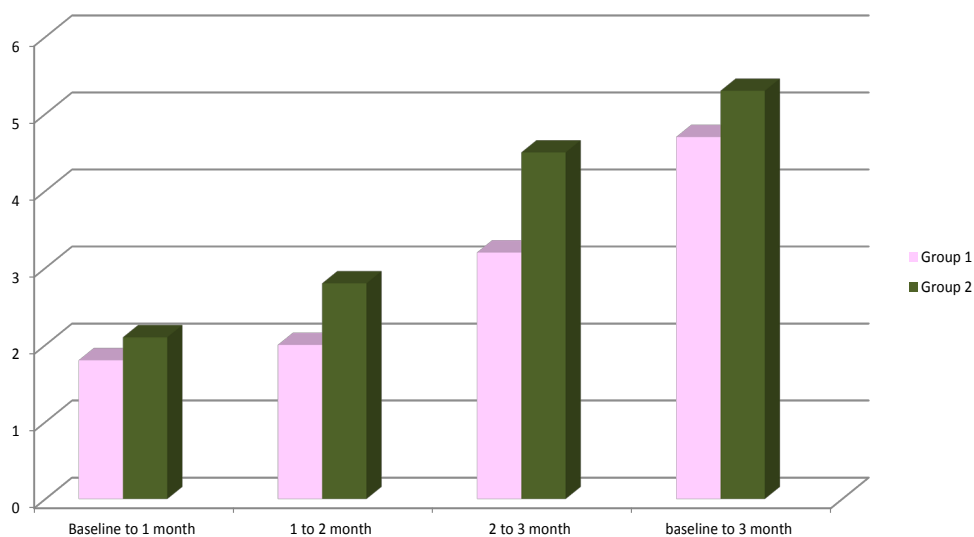


Figure 5. Mean Percentage Increase in Tongue Protrusion



results would have been compared with topical steroid applications. It can be considered as one of the limitation for the present study. Use of this herbal drug regimen for other mucosal lesions like oral lichen planus, leukoplakia, different grades of OSMF etc can be considered fruitful for future aspects.

In the present study, Kali Haldi and Aloe vera act synergistically against oxidative free radical species in OSMF patients. No major side effects were observed in our study. Group A with the combination of Kali Haldi and aloe vera gel was equally good, even better for burning sensation correction when compared with the intralesional injections of hydrocortisone, hyaluronidase, and antioxidant supplements. Null hypothesis proved wrong for the present study as these herbal ingredients showed positive results in OSMF patients. Benefit of using the Ayurveda regimen due to its cost-effectivity, availability, safety for use, time tested by ancient Indian science and non-invasive method to manage OSMF comfortably for both patient as well as clinician. Further studies involving a larger sample size, different grades of OSMF, different ratios of the herbs used, and also for longer period of treatment duration followed by proper follow-ups are recommended.

### Author Contribution Statement

Each author contributed well to their part while performing the study as well as during framing the literature. Study design: Aditya harsh; manuscript preparation and data collection: Ankita Bohra, analysis of the manuscript: T.N Uma Maheshwari; interpretation of results: Peeyush Sharma and Ayush Garg; All authors reviewed and approved the final version of the manuscript.

### Acknowledgements

#### Research facilities

We thank to the management of the VDCH for granting the permission to the authors to use patients' medical record; space and assets belong to the hospital during the process of conducting the research.

#### Technical support

We thank to all members of Pathology Lab of VDCH for providing technical assistance.

#### Ethical approval

The ethical approvals of this research were obtained from the Institutional ethical committee of Vyas dental college and Hospital (VDCH/IEC/25/2020).

#### Conflicts of interest

The authors declare that there are no conflicts of interests associated with this article.

### References

Abhijeet A (2015). Curcumin – pharmacological actions and its role in oral submucous fibrosis: A Review. *J Clin Diagn*

*Res*, **9**, ZE01-ZE03.

- Alam S, Ali I, Giri K, et al (2013). Efficacy of aloe vera gel as an adjuvant treatment of oral submucous fibrosis. *Oral Surg Oral Med Oral Pathol Oral Radiol*, **116**, 717–24.
- Alonso-Amelot ME (2016). Multitargeted bioactive materials of plants in the Curcuma genus and related compounds: Recent advances. *Nat Prod Chem*, **47**, 111–200.
- Angel GR, Menon N, Vimala B, et al (2014). Essential oil composition of eight starchy Curcuma species. *Industrial Crops Prod*, **60**, 233–8.
- Anuradha A, Patil B, Asha VR (2017). Evaluation of efficacy of aloe vera in the treatment of oral submucous fibrosis - a clinical study. *J Oral Pathol*, **46**, 50–5.
- Bailoor D, Nagesh KS (2005). Fundamentals of oral medicine and radiology, 1st edn. New Delhi: Jaypee Publisher, pp 182-94.
- Behura S, Srivastava VK (2004). Essential oils of leaves of Curcuma species. *J Essential Oil Res*, **16**, 109–10.
- Das S, Bordoloi PK, Phukan D, et al (2012) Study of the anti-ulcerogenic activity of the ethanolic extracts of rhizome of Curcuma caesia (eccc) against gastric ulcers in experimental animals. *Asian J Pharm Clin Res*, **5**, 200–3.
- Devi HP (2015). Antioxidant and antimutagenic activity of Curcuma caesia Roxb. Rhizome extracts. *Toxicol Rep*, **2**, 423–8.
- Dosoky NS, Setzer WN (2018). Chemical composition and biological activities of essential oils of curcuma species. *Nutrients*, **10**, 1193-6.
- Ganjre A, Kathariya R, Bagul N, et al (2015). Anti carcinogenic and anti bacterial properties of selected spices: Implications in oral health. *Clin Nutr Res*, **4**, 209 15.
- Hossain CF, Al-Amin M, Sayem ASM, et al (2015). Antinociceptive principle from Curcuma aeruginosa. *BMC Compl Alternat Med*, **15**, 191.
- Jayavelu P, Sambandan T (2012). Medical treatment modalities of oral sub mucous fibrosis. *Nat J Integrated Res Med*, **3**, 147-51.
- Jurenka JS (2009). Anti-inflammatory properties of curcumin, a major constituent of Curcuma longa: A review of preclinical and clinical research. *Alternat Med J Clin Ther*, **14**, 141–53.
- Mangla M, Shuaib J, Jain G, et al (2010) In-vitro evaluation of antioxidant activity of Curcuma caesia Roxb. *Int J Pharm Sci Res*, **1**, 98-102.
- Pandey AK, Chowdhury AR (2003). Volatile constituents of the rhizome oil of Curcuma caesia Roxb from central India. *Flavor Fragrance J*, **18**, 463–5.
- Patil S, Al-Zarea B, Maheshwari S, et al (2015). Comparative evaluation of natural antioxidants spirulina and aloe vera for the treatment of oral submucous fibrosis. *J Oral Biol Craniofacial Res*, **5**, 11–5.
- Patil S, Maheshwari S (2014). Proposed new grading of oral submucous fibrosis based on cheek flexibility. *J Clin Exp Dentist*, **6**, 255-8.
- Rahmani AH, Aldebasi YH, Srikar S, et al (2015). Aloe vera: Potential candidate in health management via modulation of biological activities. *Pharm Rev*, **9**, 120-6.
- Rajamma AG, Bai V, Nambisan B (2012). Antioxidant and antibacterial activities of oleoresins isolated from nine Curcuma species. *Phytopharmacology*, **2**, 312–7.
- Ramesh DNSV, Saba N (2017). Lycopene and combination of lycopene with multivitamins in the treatment of oral submucous fibrosis patients: A comparative study. *Int J Curr Res*, **9**, 53177-82.
- Rao NR, Villa A, More CB, et al (2020). Oral submucous fibrosis: a contemporary narrative review with a proposed inter-professional approach for an early diagnosis and clinical management. *J Otolaryngol Head Neck Surg*, **49**, 1-3.

- Recio MC, Andujar I, Rios JL (2012). Anti-inflammatory agents from plants: Progress and potential. *Curr Med Chem*, **19**, 2085-8.
- Sanatombi R, Sanatombi K (2017). Nutritional value, phytochemical composition, and biological activities of edible Curcuma species: A review. *Int J Food Propert*, **20**, 2668-87.
- Sarangthem K, Haokip MJ (2010). Bioactive components in Curcuma caesia Roxb grown in Manipur. *Bioscan J Biol Edu*, **1**, 113-5.
- Sudarshan R, Annigeri R, Sree Vijayabala G (2012). Aloe vera in the treatment for oral submucous fibrosis - a preliminary study. *J Oral Pathol Med*, **41**, 755-61.



This work is licensed under a Creative Commons Attribution-Non Commercial 4.0 International License.