

Comparison of TransPerineal Prostate Biopsy Using Novel Affordable VY Probe (TPPB-VY) and TransRectal Prostate Biopsy (TRPB) in Detection of Prostate Cancer on Hypoechoic Lesions

Sawkar Vijay Pramod^{1*}, Ferry Safriadi¹, Ali Ridho Al Haddar¹, Bethy S Hernowo²

Abstract

Introduction: Prostate cancer is one of the most commonly encountered urologic malignancy. Biopsy samples may be attained using TPPB-VY or TRPB; both of the approaches are relatively comparable in terms of accuracy. Transperineal Access System revolutionizes the methodology for obtaining prostate biopsies. But in Indonesia this device is not available and expensive, we developed VY probe mounted needle guide device. The study was aimed to compare cancer detection rate and rates of cancer detection in Grade Groups (GG) between these two approaches, particularly in prostate cancer patients. **Methods:** A cross-sectional study with retrospective data from patients diagnosed with prostate cancer in Hasan Sadikin General Hospital in 2019 – 2020 was performed. Ethical approval of this study was sought from the hospital authorities (IRB number: LB.02.01/X.6.5/ 55/2020). The patient was included to the study if PSA \geq 4 ng/ml, DRE results suggestive of prostate cancer. The diagnostic accuracy of both approaches was compared using histopathological analysis. **Results:** There were 44 patients included in the study; 22 patients had received TRPB and 22 patients had TPPB-VY. Higher degree of cancer detection rates was found in patients receiving TPPB-VY. Patient with Prostatic adenocarcinoma were all found having hypoechoic lesion in TPPB-VY. On the other hand, half of the patient with Prostatic adenocarcinoma shown having no lesion in TRPB. Prostate cancer with hypoechoic lesion can be detected better by TPPB-VY than TRPB. Cancer detection rates on TPPB-VY were significantly higher than on TRPB for each grade group. **Conclusion:** Among patient with hypoechoic lesions, TPPB-VY led to more detection of prostate cancer, it provides detection of all grade groups and high-grade prostate cancer, this showed a non-inferior TPPB-VY compared to TRPB. TPPB-VY should be considered as an option for all men in whom a prostate biopsy is indicated.

Keywords: Comparison- diagnostic- transrectal- transperineal- prostate biopsy- VY Probe

Asian Pac J Cancer Prev, 23 (5), 1513-1516

Introduction

Prostate cancer is one of the most commonly encountered urologic malignancy in Europe; reported incidences according to the latest report of European Association of Urology (EAU) had exceeded 200 per 100,000 men each year (Heidenreich et al., 2011; Mottet et al., 2017). In the United States, significantly higher proportion of prostate cancer patients were found on African-Americans compared to Caucasians (Kumar, 2010). Asia had comparatively lower incidence of prostate cancer, with incidence of 7.2 per 100,000 men per year. According to Globocan in Indonesia, during 2020, prostate cancer contributed 7.4% new cases among all cancer in the world. In Indonesia, currently there are 1,102 prostate cancer patients treated in three tertiary referral hospitals. (Umbas, 2014)

Prostate biopsy is the golden standard for detection of prostate cancer, with two approaches, namely TPPB-VY or TRPB (Guo et al., 2015). Accuracy using TPPB-VY in an autopsystudy had successfully diagnosed 17.2% out of 54% patients with histopathological confirmation of prostate cancer. The same study had noted overall sensitivity of 32.3% for TPPB-VY (75% for clinically significant and 11% clinically insignificant prostate cancer) (Rocco et al, 2006). Conversely, no significant difference of accuracy was noted between TRPB and TPPB-VY; despite the latter had lower complication rates (Cerruto, 2014).

Transperineal Access System (for example: The PrecisionPoint™) revolutionizes the methodology for obtaining prostate biopsies. This medical system takes full advantage of the transperineal path to more thoroughly sample all regions of the prostate including those

¹Department of Urology, Faculty of Medicine Universitas Padjadjaran / Hasan Sadikin Academic Medical Center, Bandung, Indonesia. ²Department of Pathology Anatomy, Faculty of Medicine Universitas Padjadjaran / Hasan Sadikin Academic Medical Center, Bandung, Indonesia. *For Correspondence: doktervj@yahoo.co.id

difficult to access with the transrectal approach. Since the technique is free hand, the practitioner can easily target the desired locations with certainty and through a single puncture of the skin. But in Indonesia this device is not available and expensive, we developed VY probe mounted needle guide device. It was made by 3D printing machine with corn starch-based bioplastic material commonly called polyacetic acid material, a biodegradable plastic (Guo et al., 2015).

Both of the approaches were similarly efficacious; however, lower complication rates were found in patients receiving TPPB-VY compared to the patients receiving TRPB (Guo et al., 2015). As such, the study was aimed to compare cancer detection rate and rates of cancer detection in grade groups between these two approaches, particularly in prostate cancer patients.

Materials and Methods

The cross-sectional study was performed in Hasan Sadikin Academic Medical Center. All patients with suspected prostate cancer were included in this study; inclusion criteria of this study were patients treated in Hasan Sadikin Academic Medical Center during the study period, had indications for further examination using prostate biopsy (PSA \geq 4 ng/ml, digital rectal examination had revealed signs suggestive of prostate cancer); and had complete sociodemographic data; patients were excluded from the study if the patient had previous history of urological malignancy, had received therapy for secondary malignancy, or previous history of congenital urological defects.

Patients presenting with suggestive signs of prostate cancer were first screened using physical examination. If prostate enlargement was suspected, blood test was performed to reveal PSA levels. Patients with \geq 4 ng/ml serum PSA were considered as candidates for prostate biopsy. Both biopsy methods follow the protocol outlined for the procedure in the hospital. TPPB-VY was performed using VY probe and TRPB was performed using conventional probe (ultrasound-guided probe). The patients included in this study were instructed to temporarily stop taking anticoagulants (in patients with previous history of anticoagulant use for certain medical conditions) for 7 days prior to the biopsy. Before the biopsy, the patient was given an enema.

Biopsy Protocols

For TRPB: patients received the perioperative oral antibiotics (empirically using levofloxacin) for 1 days and an enema was given on the morning of the biopsy. Biopsy gun (DELTA CUT/14*16*18; Geisingen, Germany) was applied through the transrectal ultrasonography (2202 profocus; BK medical Aps, Herlev, Denmark) with full lidocaine cream lubrication. Generally, the 10-12 core biopsy needed. The biopsy number might vary according to the prostate volume or additional suspicious transrectal ultrasound findings.

For TPPB-VY: The patient was placed in the lithotomy position with well- disinfected perineum preparation. The patients underwent intravenous general anesthesia. Under

the transrectal ultrasonography guidance (2202 profocus; BK medical Aps, Herlev, Denmark), the VY probe was fixed in TRUS guidance. Systemic and/or targeted biopsy was done with 10-12 cores according to the prostate volume. Perioperative antibiotic treatment wasn't needed during the procedure.

Detection rate of both approaches were collected as primary outcome variables; detection rate of both methods was compared using histopathology examination of the biopsy sample. Descriptive statistics were utilized to present frequency and percentages of sociodemographic data. Normally-distributed, numerical data were presented with mean and standard deviation; non-normally-distributed numerical data were presented using median. Diagnostic accuracy of both groups were compared against histopathology examination of the biopsy sample. The data were analyzed using chi-square method to find difference between groups. P value of < 0.05 was deemed as statistical significance.

Results

There were 44 patients suspected for prostate cancer were included in this study; each group consisted of 22 patients. No significant difference was noted in terms of differ of age, PSA concentration, and prostate volume in both group between the patient with hypoechoic lesion and without hypoechoic lesion. There were 6 out of 22 patients (27.2%) in TRPB group and 7 out of 22 patients (31.8%) in the TPPB-VY group were confirmed to have prostate cancer. There was not significantly different between technique with $p = 0.112$ for detection rate.

On ultrasonography examination there were 7 patients (31.8%) and 15 patients (68.2%) with hypoechoic lesion in TRPB and TPPB-VY group, respectively. Patients presenting with hypoechoic lesion had a higher detection rate in both TRPB (42.9%) and TPPB-VY (46.7%) group compared to the patients without hypoechoic lesion.

Prostate cancer was found in 3 out of 7 patients (42.9%) with hypoechoic lesions in TRPB group; prostate cancer was found in 7 out of 15 patients (46.7%) with hypoechoic lesions in the TPPB-VY group. There were 12 out of 15 patients (80.0%) in TRPB group diagnosed with benign prostatic hyperplasia in patients presenting without hypoechoic lesion. All patients in TPPB-VY group presenting without hypoechoic lesion were diagnosed with benign prostatic hyperplasia.

Diagnosis efficacy between TRPB and TPPB-VY was described in Figure 2. The highest detection rate GG4 prostate cancer was found in patients with hypoechoic lesion diagnosed using TPPB-VY (42.8%), followed by GG1 (31.8%), GG2 (28.4%), and GG3 (14.2%). Significantly higher rates of prostate adenocarcinoma detection were found in the patients diagnosed with TPPB-VY ($p < 0.05$).

Discussion

This study showed no significant difference was noted in terms of differ of age, PSA concentration, and prostate volume in both group (with hypoechoic lesion and without

Table 1. Patient Characteristics in TRPB and TPPB-VY

Variable	TRPB		TPPB-VY	
	Hypoechoic Lesion N=7	No lesion N=15	Hypoechoic Lesion N=15	No lesion N=7
Age				
Mean±Std	66.43 ± 6.65	64.53 ± 5.82	67.64 ± 6.902	60.13 ± 9.265
PSA (ng/mL)				
Mean±Std	599.76± 702.87	46.17 ± 58.14	334.76 ± 733.981	53.38 ± 74.105
DRE				
Nodule	5 (71.4%)	0 (0.0%)	9 (64.3%)	7 (87.5%)
Without Nodule	2 (57.1%)	15 (100.00%)	5 (35.7%)	1 (12.5%)
Volume Prostat (mL)				
Mean ± SD	54.80 ± 35.636	47.02 ± 18.007	60.83 ± 33.36	65.23 ± 60.55
Pathologic Diagnostic				
Prostatic adenocarcinoma	3 (42.9%)	3 (20.0%)	7 (46.7%)	0 (0.0%)
Benign Prostatic Hyperplasia	4 (57.1%)	12 (80.0%)	8 (53.3%)	7 (100%)

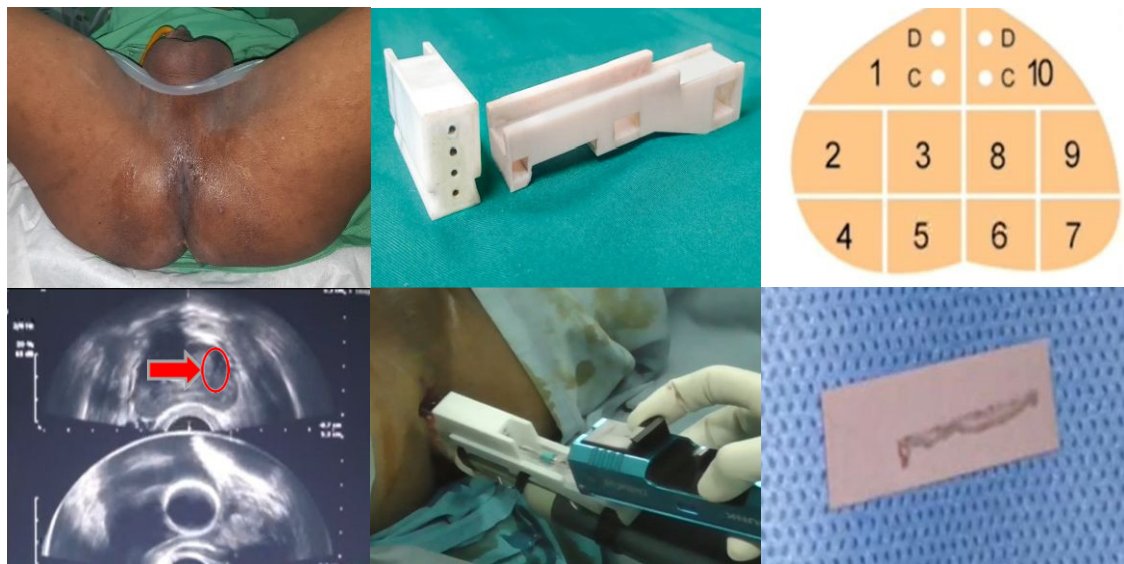


Figure 1. TPPB using Novel Affordable VY Probe. A. Patient position for biopsies B. VY probe C..Mapping Prostate Biopsy D and E Hypoechoic lesion on left anterior prostate. F. Biopsies's specimen

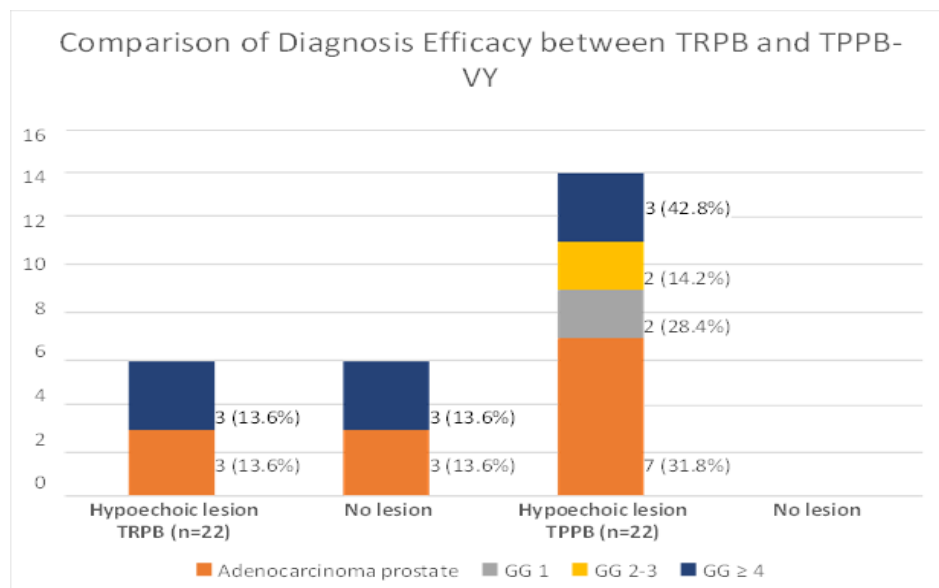


Figure 2. Comparison of Diagnosis Efficacy between TRPB and TPPB-VY

hypoechoic lesion) between the TRPB and TPPB-VY group (Huang, 2019).

In this study, there were 3 out of 22 patients (13.6%) in TRPB group and 7 out of 22 patients (31.8%) in the TPPB-VY group were confirmed to have prostate cancer with hypoechoic lesion; detection rate of prostate cancer between both groups was significantly different, the patients receiving TPPB-VY had significantly higher detection rate of prostate cancer on patients with hypoechoic lesions. This is similar to the result of a study conducted by Huang et al., which stated that the cancer detection rates, with respect to TPPB and TRPB (45 and 49%), were statistically comparable (Huang, 2019).

In a recent report, of a multicenter study (Vis et al., 2000), simulated transrectal and transperineal biopsies were performed on 40 radical prostatectomy specimens obtained of 40 tumors, 33 (82%) were detected by the transperineal approach and 29 (72%) by the transrectal approach. Prostate maps demonstrated that tumors undiagnosed by transperineal biopsy were either small (0.2 cm or less) or mainly located at the prostatic base, this showed that TPPB-VY had higher detection rates of prostate cancer. (Vis et al., 2000)

As Emiliozzi (2003) reported in his previous work, he concluded that the transperineal approach might detect more insignificant cancers. This result is similar in our study where transperineal biopsy manage to detect GG1, GG2-GG3, and > GG4 in Adenocarcinoma patients while only GG4 was found in transrectal biopsies. Transperineal biopsy includes cores from the lateral area of the gland, and this could explain the higher cancer diagnosis achieved with this procedure.

In conclusion, among patient with hypoechoic lesions, TPPB-VY had higher detection rate of prostate cancer in all grade groups. The technique was able to detect high grade prostate cancer with good accuracy. Diagnostic accuracy of TPPB-VY was non-inferior compared to TRPB. Biopsy using TPPB-VY should be considered as an option for all men with suspected prostate cancer.

Author Contribution Statement

Conceptualization: Pramod, Safriadi, Al Haddar. Methodology: Pramod, Safriadi, Al Haddar. Investigation: Pramod, Safriadi, Al Haddar. Data Curation: Pramod, Safriadi, Al Haddar. Writing - Original Draft: Pramod, Safriadi, Al Haddar. Writing -Review and Editing: Pramod, Safriadi, Al Haddar. Visualization: Pramod, Safriadi, Al Haddar, Hernowo. Supervision: Pramod, Safriadi, Hernowo.

Acknowledgements

None.

Ethics Approval

Ethics approval and consent to participate All human samples were collected under Institutional Review Board approval. In addition, written informed consent was obtained from participants in this study.

Conflict of Interest

The authors declare that they have no potential conflict of interest

References

- Cerruto MA, Vianello F, D'Elia C, Artibani W, Novella G (2014). Transrectal versus transperineal 14-core prostate biopsy in detection of prostate cancer: a comparative evaluation at the same institution. Vol. 86, *Archivio italiano di urologia, andrologia: organo ufficiale [di] Società italiana di ecografia urologica e nefrologica / Associazione ricerche in urologia. Italy: Archivio italiano di urologia, andrologia: organo ufficiale [di] {Società} italiana di ecografia urologica e nefrologica*, pp 284–7.
- Emiliozzi P, Corsetti A, Tassi B, et al (2003). Best approach for prostate cancer detection: a prospective study on transperineal versus transrectal six-core prostate biopsy. *Urology*, **61**, 961–6.
- Guo LH, Wu R, Xu HX, et al (2015). Comparison between Ultrasound Guided Transperineal and Transrectal Prostate Biopsy: A Prospective, Randomized, and Controlled Trial. *Sci Rep*, **5**, 16089.
- Heidenreich A, Bellmunt J, Bolla M, et al (2011). EAU guidelines on prostate cancer. Part 1: Screening, diagnosis, and treatment of clinically localised disease. *Eur Urol*, **59**, 61–71.
- Huang G-L, Kang C-H, Lee W-C, Chiang P-H (2019). Comparisons of cancer detection rate and complications between transrectal and transperineal prostate biopsy approaches - a single center preliminary study. *BMC Urol*, **19**, 101.
- Kumar V, Abbas AK, Fausto N, Aster J (2010). Robbins & Cotran Pathologic Basis of Disease 8th edition, US Elsevier Health Bookshop. 2010.
- Mantica G, Pacchetti A, Aimar R, et al (2019). Developing a five-step training model for transperineal prostate biopsies in a naïve residents' group: a prospective observational randomised study of two different techniques. *World J Urol*, **37**, 1845–50.
- Mottet N, Bellmunt J, Bolla M, et al (2017). EAU-ESTRO-SIOG Guidelines on Prostate Cancer. Part 1: Screening, Diagnosis, and Local Treatment with Curative Intent. *Eur Urol*, **71**, 618–29.
- Rocco B, de Cobelli O, Leon ME, et al (2006). Sensitivity and Detection Rate of a 12-Core Trans-Perineal Prostate Biopsy: Preliminary Report. *Eur Urol*, **49**, 827–33.
- Umbas R, Hardjowijoto S, Mochtar C, Safriadi F, Djatisoesanto W (2014). Panduan Penanganan Kanker Kandung Kemih Tipe Urotelial. In: Ikatan Ahli Urologi Indonesia (IAUI). p. 56.
- Vis AN, Boerma MO, Ciatto S, et al (2000). Detection of prostate cancer: a comparative study of the diagnostic efficacy of sextant transrectal versus sextant transperineal biopsy. *Urology*, **56**, 617–21.
- Young R, Norris B, Reeves F, Peters JS (2019). A Retrospective Comparison of Transrectal and Transperineal Prostate Biopsies: Experience of a Single Surgeon. *J Endourol*, **33**, 498–502.



This work is licensed under a Creative Commons Attribution-Non Commercial 4.0 International License.