

3D-CRT versus RapidArc in Deep Temporo-Parietal High Grade Gliomas: Do We Really Need Higher Technology?

Karim Mashhour^{1*}, Hoda Abdelghany², Ashraf Mounir¹, Wedad Hashem¹

Abstract

Purpose: The aim of this study was to dosimetrically compare single arc RapidArc with conventional 3D-CRT plans for temporo-parietal high grade gliomas with respect to PTV coverage and doses perceived by surrounding critical organs at risk. **Methods:** Thirty patients with the pathological diagnosis of high grade gliomas (WHO grade III-IV) were selected to be enrolled in our study. Patients were referred to our center (center of Clinical Oncology and Radiotherapy, Cairo University) during the period March 2020 till June 2021 for post-operative irradiation using 3D-CRT technique. For all patients, the dose prescribed to the planning target volume (PTV) was 60 Gy in 30 fractions. A RA plan was performed for each patient and dosimetrically was compared to the 3D-CRT plan. **Results:** The PTV coverage in terms of V95% was significantly superior in the RA plans with values of 98.4 ± 1.7 compared to 94.4 ± 2.6 for the 3D-CRT plans (p-value of 0.004). The doses risk structures (eyes, optic nerves and cochleae) was lower with the RA plans as contrasted to the 3D-CRT plan with an exception for the intraocular lens which received higher doses in the RA plan with a statistically significant p-value of 0.001 and 0.002 for the Ipsilateral and contralateral lens, respectively. The average number of MUs \pm SD was 358.6 ± 44.4 for the RA plans versus 247.6 ± 16.1 for 3D-CRT plans (p-value 0.001). The Dmean of healthy brain tissue was nearly equal for both plans (p-value of 0.071). **Conclusion:** The plans achieved by RA showed superior dose conformity, PTV coverage, more homogeneous dose distribution when contrasted to 3D-CRT plans. With the exception of both intraocular lenses, the RA plans showed better OAR sparing and utilized a higher number of MUs compared to the 3D-CRT.

Keywords: 3D-CRT- RapidArc- Temporo-parietal gliomas

Asian Pac J Cancer Prev, 23 (6), 2169-2176

Introduction

The standard definitive treatment of high grade gliomas (anaplastic astrocytomas and Glioblastoma multiforme (GBM)) typically includes a maximal safe resection of the tumor followed by radiotherapy with concurrent and adjuvant chemotherapy and radiation therapy (RT) (Stupp et al., 2009; Cabrera et al., 2016). Typically these tumors have a relatively inherent radioresistance (Brandes et al., 2009), with a tendency to locally recur (Bashir et al., 1988; Milano et al., 2010) despite of classic treatment with a median time to progression as reported in recent studies to be 7-9 months (Wallner et al., 1998; Souhami et al., 2004; Pan et al., 2012; McDonald et al., 2011).

Intensity-modulated radiation therapy (IMRT) when used as the treatment technique for irradiating high grade gliomas had demonstrated similar or superior target volume coverage and better sparing of organs at risk (OAR) when contrasted to three-dimensional conformal RT (3D-CRT). (MacDonald et al., 2010; Chan et al., 2003; Narayana et al., 2006; Hermanto et al., 2007, Piroth et

al., 2009; Wagner et al., 2009; Zach et al., 2009). Recent studies comparing IMRT to volumetric modulated arc therapy (VMAT) have shown nearly equivalent results as regards target coverage with a slight advantage in normal tissue sparing and shorter treatment delivery time for VMAT (Panet-Raymond et al., 2012; Cao et al., 2007; Amelio et al., 2010; Shaffer et al., 2010).

Acute toxicities accompanying chemo-radiation may include alopecia, dizziness, headache, fatigue, dermatitis and nausea or vomiting (Stupp et al., 2005; Chinnaiyan et al., 2013). Patients usually report lower functional neurological quality of life compared to controls (Taphoorn et al., 2005). Late toxicities associated with radiotherapy can include vision or hearing impairment, persistent fatigue, cognitive deficits and neuro-endocrine dysfunction (Bosma et al., 2007). An important treatment aim and goal in high grade gliomas is to maintain their neurological function in order to perform normal daily activities (MacDonald et al., 2007; Saad et al., 2015).

The deeply seated temporo-parietal gliomas often limit the dose delivered to the target volume due to its

¹Department of Clinical Oncology, Kasr Al-Ainy school of medicine, Cairo University, Egypt. ²Department of Medical Physics, Kasr Al-Ainy School of Medicine, Cairo University, Egypt. *For Correspondence: karim.mashhour.81@gmail.com

proximity to critical adjacent normal organs at risk. The RapidArc (RA) modality was adopted at our center in 2015 and preliminary results in other tumor sites had shown an improvement in sparing organs at risk with adequate coverage of the planning target volume (PTV) (Mashhour et al., 2018). The RapidArc (RA) radiotherapy technique (Varian Medical Systems, Palo Alto, CA) incorporates three essential parameters for an adequate treatment delivery; which are its gantry speed, dose rate and the capability of simultaneously varying the Multileaf Collimator (MLC) position while performing an arc motion of the gantry continuously (Yu et al., 2011; Bhide et al., 2010; Otto K 2008). In addition to the faster delivery time and lower number of monitor units (MU) when contrasted to IMRT (Lagerwaard et al., 2009; Kjaer Kristoffersen et al., 2009).

The aim of this study was to dosimetrically compare RA with conventional 3D-CRT plans for tempero-parietal high grade gliomas with respect to PTV coverage and doses perceived by surrounding critical organs at risk.

Materials and Methods

An acceptance from our Institutional scientific and ethical committees was taken on our study design. A written informed consent was a pre-requisite to enroll the patients into the study.

Patient selection and preparation

Thirty patients with the pathological diagnosis of high grade gliomas (WHO grade III-IV) were selected to be enrolled in our study. According to the World Health Organization (WHO) 2007 classification of central nervous system (CNS) tumors, there were seven cases of grade III and twenty three cases of grade IV (Louis et al., 2007). Patients were referred to our center (center of Clinical Oncology and Radiotherapy, Cairo University) during the period March 2020 till June 2021 for post-operative irradiation using 3D-CRT technique. All patients had a total or partial tumor excision. Temozolomide was used as concurrent and adjuvant chemotherapy. A RA technique plan was performed for each patient and dosimetrically was contrasted to the 3D-CRT plan. Table 1, outlines the patient and tumoral characteristics.

All patients had a thorough pre-treatment clinical assessment including a complete history taking and physical examination. A dedicated Computed Tomography (CT) scan (General Electric, USA) with a 25 mm slice thickness after giving an intravenous contrast was performed for planning. Patients were immobilized using a Duncan headrest type B while they are aligned anatomically in supine position and their heads placed in a neutral position using an Aquaplast semi-rigid facemask (WFR Aquaplast, orfit, NJ). The reference isocenter was allocated close to the tempero-parietal region. The CT scout images were sent to the Eclipse treatment planning system (TPS v8.6) for planning via the "DICOM" network.

Delineation of the PTV and OARs.

Images fusion were performed with the aid of Mim-Version 6.5 software between the CT planning

images and magnetic resonance imaging (MRI) contrast-enhanced T1-weighted done post-operatively after administrating gadolinium contrast. Delineation was done by a senior Radiation Oncologist and following the European Organization for Research and Treatment of Cancer Advisory Committee on Radiation Oncology Practice (EORTC-ACROP) target delineation guidelines (Niyazi et al., 2016).

The gross tumor volume (GTV) was defined as the primary tumor operative resection cavity and any residual enhancing areas identified on the post-operative contrast enhanced MRI images (T1-weighted). The clinical target volume (CTV) was defined and delineated as a 2 cm isotropic margin expanded from the GTV to cover areas at risk of harboring microscopic disease respecting normal anatomical barriers. Minor manual adjustments were made to the CTV to exclude the bones and avoid crossing to the contralateral brain. The CTV margin was reduced to 1mm near the neural structures. The planning target volume (PTV) was created by adding a 0.3 cm expansion from the CTV to take into consideration patient motion and setup errors. Auto-contouring of the normal brain was done and the healthy remaining brain tissue volume was subtracted from the PTV with an additional margin of 0.3 cm. The organs at risk (OAR) were manually contoured with the aid of the fused MRI images (T2-weighted) and included the following structures; brainstem, optic nerves, eye globes, lens, cochleae and optic chiasm.

Dose, fractionation and radiotherapy techniques

The prescribed dose to the PTV was 60Gy/30F/6weeks (2Gy/F) and the beam energy used was 6MV photons. For each patient, two different treatment plans were performed; one using 3D-CRT and the other with RA plans by a senior medical radiation Physicist. The treatment plans were calculated using the Eclipse planning system (Version 8.6, Varian Medical Systems, Helsinki, Finland).

The number of static non-coplanar fields used for the 3D-CRT plans were 2-6 and field in field supplements were allowed for adequate target coverage. A dose rate of 300-350 MU/min was used for the 3D-CRT plans. The RapidArc plan used a single 3600 arc (clockwise rotation). The couch angle was set to 00 while the collimator was adjusted to 100 while the gantry angle started at 181 and stopped at 1790. The calculations and optimization were done using Optimization and calculations were done using the anisotropic analytical algorithm (AAA) on the Eclipse planning system (Van Esch et al., 2006; Fogliata et al., 2006).

In order to avoid the tongue and groove effect, different collimator angles were used. For the single complete arc plan, the treatment fields were splitted into 177 control points. For each control point, the beam aperture were defined by the gantry angle and multileaf collimator (MLC) changes. Re-optimization of the RA plans was allowed to achieve the desired results. The dose rate for the RA plan varied between 0 MU/min and 500 MU/min.

Plan evaluation parameters

The following dose constraints were respected during treatment planning for the OAR; optic nerve maximum

dose (Dmax) <54 Gy, brainstem Dmax <54 Gy, optic chiasm Dmax <54 Gy, cochlea mean dose (Dmean) <45 Gy, eyes Dmean <30 Gy, intraocular lens Dmax <6 Gy. For the healthy remaining brain tissue, the mean dose and D1% were used for calculation.

The dosimetric parameters for target coverage in both plans included V95% (volume receiving 95% of the prescribed dose) and V107% (volume receiving 107% of the prescribed dose). The dose prescribed was 60 Gy to the PTV and all plans were normalized to 100% (60Gy). Other parameters included were Dmax (maximum dose), Dmin (minimum dose) and Dmean (mean dose) within the PTV, respectively.

Conformity index (CI95%) was calculated as the ratio between the volume receiving at least 95% of the prescribed dose and the volume of the PTV while the inhomogeneity index (II) was calculated for the PTV using the following equation [37] : $II = D05\% - D95\%$. The ideal result for the PTV is to have an II of less than 10Gy where Dyy% is the dose covering yy% of the PTV. A higher value of the II reflects a less homogenous distribution of the dose received. The Dose-Volume Histogram (DVH) for PTV coverage and OAR were generated as well the total number of MU were calculated for each plan.

Statistical analysis

Statistical package for social science v.19.0 software (SPSS, Inc., Chicago, IL, USA) was used for statistical analysis. Differences between the mentioned dosimetric parameters of the 3D-CRT and RA plans were statistically evaluated using Mann Whitney U-test. A p value of < 0.05 was considered statistically significant. Independent Student t test was performed to evaluate the differences between both radiotherapy treatment techniques.

Results

Dosimetrically acceptable 3D-CRT and RA treatment plans were fulfilled in all 30 cases. The plans were approved by two senior radiation therapy oncologists. Tables 2 and 3, outlines the dosimetric data outcomes derived from the DVHs with respect to target volume (PTV) coverage (Table 2) and doses to the OAR (Table 3) in both plans, respectively. The data was reported as mean values ± Standard Deviation (SD).

The PTV coverage in terms of V95% was significantly superior in the RA plans with values of 98.4 ± 1.7 compared to 94.4 ± 2.6 for the 3D-CRT plans (p-value of 0.004). Regarding the hot spots documented in each treatment plan, the V107% was found to be significantly higher in the 3D-CRT plans with a value of $10.5\text{cm}^3 \pm 0.04$ in contrast to $1.18\text{cm}^3 \pm 1.15$ in the single arc RA plan with a p value of 0.03.

Other target volume parameters compared were the Dmax, Dmin and Dmean; all three were found to be higher in the RA plans. The Dmax was $60.12\text{Gy} \pm 2.2$ versus $63.7\text{Gy} \pm 1.9$ for the 3D-CRT and RA plans, correspondingly (p-value of 0.014). With respect to the Dmin, the value was $56.8\text{Gy} \pm 2.2$ for the 3D-CRT plan as compared to $58.5\text{Gy} \pm 1.5$ for the RA plan (p-value of 0.321). The Dmean which represents the mean dose within the PTV was also significantly higher in the RA plan with a value of $61.8\text{Gy} \pm 2.3$ versus $58.5\text{Gy} \pm 1.9$ for the 3D-CRT plan with a p-value of 0.050.

Taking a look at the CI95% which represents the dose conformity within the target, it was lower (0.68 ± 0.07) in the 3D-CRT plan as compared to RA plan (0.91 ± 0.05). However, the difference was not statistically significant (p-value of 0.654). As for the inhomogeneity index (II), the dose was more homogenous in the RA plan ($1.9\text{Gy} \pm 0.123$) than the 3D-CRT plan ($2.3\text{Gy} \pm 0.120$) with an

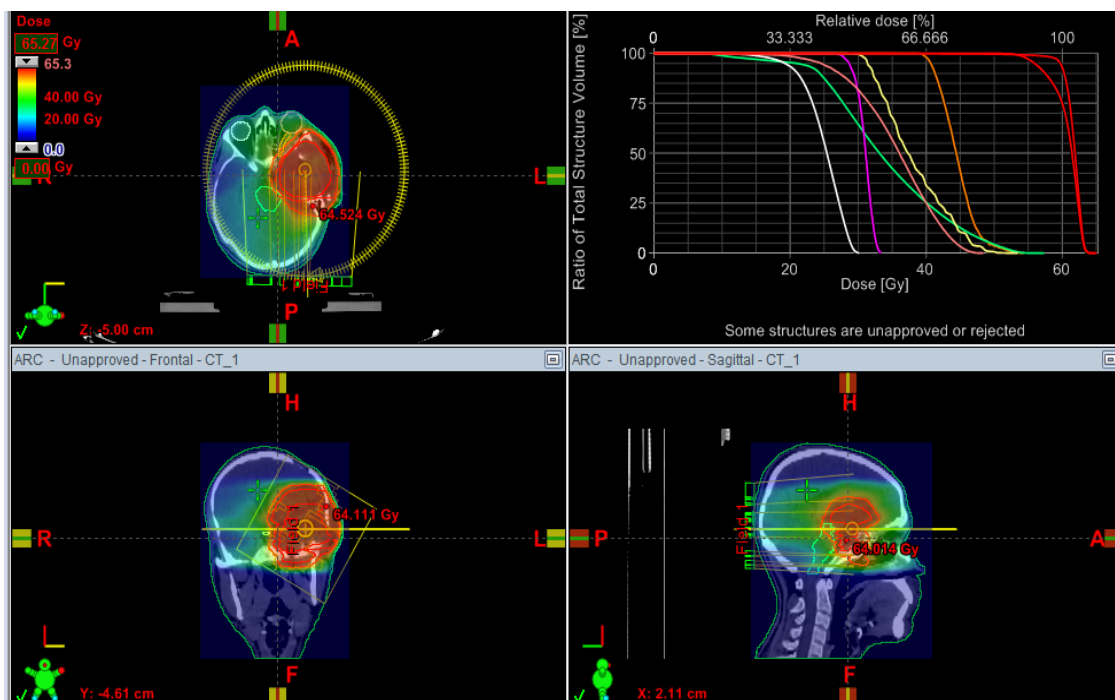


Figure 1. Dose Distribution in 3D View Created by a Single arc RA Plan

Table 1. Patient and Tumoral Characteristics of the Thirty Cases Diagnosed with High Grade Gliomas

	No	%
Age		
< 40 years	10	33.3
>40 years	20	66.7
Sex		
Male	18	60.0
Female	12	40.0
Clinical presentation		
Headache	10	33.3
Weakness	10	33.3
Diminution of vision	3	10.0
Convulsions	7	23.4
Performance status (ECOG)		
I	15	50.0
II	13	43.3
III	2	6.7
IV	0	0.0
Pathological type		
Astrocytoma	7	23.4
Glioblastoma multiformis	23	76.6
Pathological grade(WHO)		
III	7	23.4
IV	23	76.6
Laterality		
Right	12	40.0
Left	18	60.0
Tumor Site		
Temporal	8	26.6
Parietal	6	20.1
Temporo-parietal	16	53.3
Tumor size		
<2 cm ²	2	6.7
2-4 cm ²	12	40.0
4-6 cm ²	14	46.6
>6 cm ²	2	6.7

Table 2. Planning Target Volume Comparative Dosimetric Outcomes and Parameters between Both Techniques

Parameter	3D-CRT plan	RapidArc plan	P-value
V95%	94.4 ± 2.6	98.4 ± 1.7	0.004
V107% (cm ³)	10.5 ± 0.04	1.18 ± 1.15	0.03
Dmax(Gy)	60.12 ± 2.2	63.7 ± 1.9	0.014
Dmin (Gy)	56.8 ± 2.2	58.5 ± 1.5	0.321
Dmean(Gy)	58.5 ± 1.9	61.8 ± 2.3	0.05
CI95%	0.68 ± 0.07	0.91 ± 0.05	0.654
II(Gy)	2.3 ± 0.120	1.9 ± 0.123	0.113
MU	247.6 ± 16.1	358.6 ± 44.4	0.001

insignificant p-value of 0.113. The average number of MUs ± SD needed to deliver a dose of 2Gy per fraction was 358.6± 44.4 for the RA plans versus 247.6 ± 16.1 for 3D-CRT plans; the p-value reached statistical significance (p-value 0.001). Figure 1 shows a three dimensional view for a single arc RA plan while Figure 2 represents the same case with a 3D-CRT plan highlighting the difference in the target volume coverage.

With respect to the OAR in our study, the dose received by each organ was always kept below the tolerance dose (Table 3). In general, the doses documented to the Ipsilateral and contralateral risk structures (eyes, optic nerves and cochleae) was lower with the RA plans as contrasted to the 3D-CRT plan with an exception for the intraocular lens which received higher doses in the RA plan with a statistically significant p-value of 0.001 and 0.002 for the Ipsilateral and contralateral lens, respectively. The brainstem and optic chiasm also received lower doses in the RA plans but the p-value did not reach statistical significance (p-value of 0.648 and 0.127)

The Dmean of healthy brain tissue contour, as equivalent for low-dose area, was nearly equal for both plans with a value of (25.2Gy ± 4.1) for 3D-CRT and 25.8Gy ± 4.6 for the RA plans (p-value of 0.071). This was not observed in the D1% for healthy normal brain tissue which was significantly higher in the 3D-CRT when opposed to the RA plan with a p-value of 0.001. Figure 3 demonstrates comparative DVHs for PTV coverage and doses to OAR for 3D-CRT (triangles) and RapidArc

Table 3. Organs at Risk Dosimetric Comparison between Both Radiotherapy Techniques

Organ	Parameter	3D-CRT plan	RapidArc plan	P-value
Healthy	D _{mean} (Gy)	25.2 ± 4.1	25.8 ± 4.6	0.071
brain volume	D1% (Gy)	61.2 ± 2.5	57.4 ± 3.1	0.001
Brainstem	D _{max} (Gy)	52.6 ± 9.5	50.5 ± 18.1	0.648
Chiasma	D _{max} (Gy)	44.5 ± 13.4	41.8 ± 13.8	0.127
Ipsilateral optic nerve	D _{max} (Gy)	34.5 ± 17.1	31.6 ± 14.4	0.904
Contralateral optic nerve	D _{max} (Gy)	35.1 ± 19	31.7 ± 17.3	0.659
Ipsilateral Eye	D _{mean} (Gy)	18.4 ± 11.6	15.5 ± 10.5	0.042
Contralateral Eye	D _{mean} (Gy)	16.8 ± 14.1	13.1 ± 12.2	0.172
Ipsilateral Cochlea	D _{mean} (Gy)	10.7 ± 13.4	5.9 ± 9.1	0.485
Contralateral Cochlea	D _{mean} (Gy)	16.9 ± 21.1	8.6 ± 15.9	0.432
Ipsilateral Lens	D _{max} (Gy)	2.7 ± 2.3	2.9 ± 1.5	0.002
Contralateral Lens	D _{max} (Gy)	1.5 ± 2.1	1.6 ± 2.2	0.001

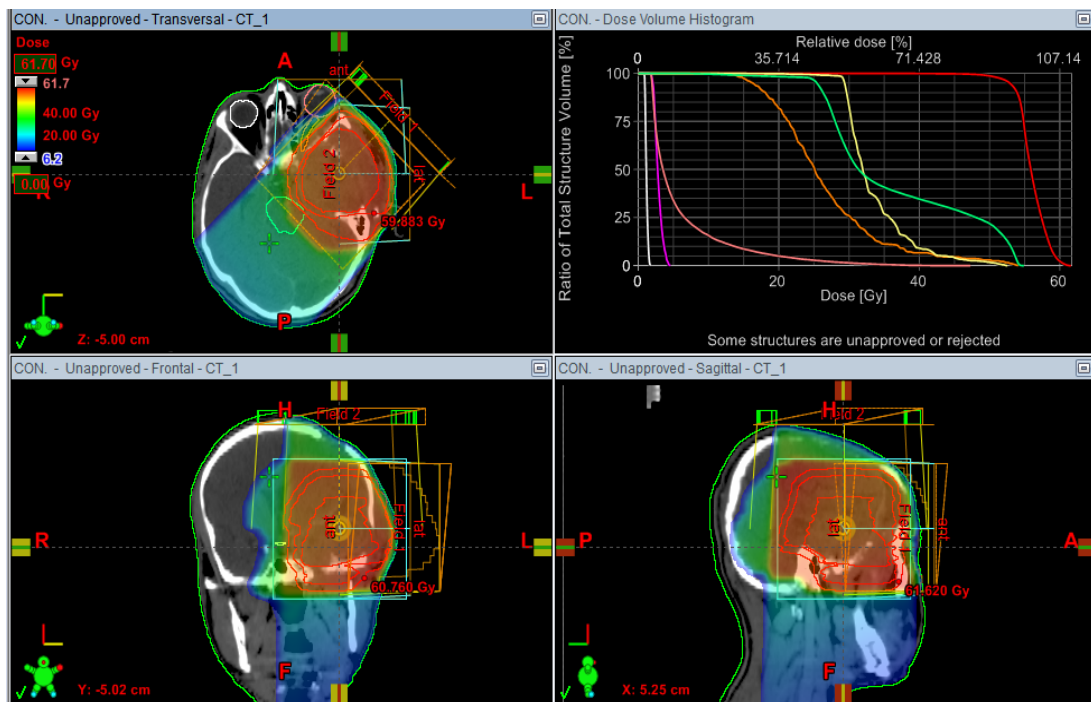


Figure 2. Dose Distribution in 3D View for a 3D-CRT Plan

(squares), respectively.

Discussion

This study compared and analyzed 3D-CRT and RapidArc for patients diagnosed with deep temporo-parietal high grade gliomas. There are six studies published in literature comparing 3D-CRT and IMRT planning techniques in the treatment of high grade gliomas (MacDonald et al., 2007; Chan et al., 2003; Hermanto et al., 2007; Piroth et al., 2009; Lorentini et al., 2013; Thibouw et al. 2018). In a study by Lorentini et al., (2013) seventeen patients diagnosed as GBM were re-planned after being previously treated using both 3D-CRT and IMRT techniques. The GTV was described as the resection cavity in addition to any contrast enhanced areas in T1

weighted images. An additional margin of 2 cm was created to account for the CTV. A 0.5 cm isotropic margin defined the PTV and the normal anatomical barriers were manually corrected. This study reported better target coverage with the IMRT plans compared to 3D-CRT with similar sparing to the OAR and doses received by the normal healthy brain tissue. Thibouw et al., (2018) evaluated clinical and survival data for 220 patients diagnosed with GBM as well as dosimetric parameters contrasting IMRT and 3D-CRT techniques, respectively. They reported lower neurological toxicity and better target volume conformity in patients treated with IMRT.

In a study by Buglione et al., (2014) they compared IMRT, 3D-CRT and tomotherapy in 10 patients diagnosed with GBM. The GTV was defined as resection cavity and areas with contrast demonstrated in the pre or

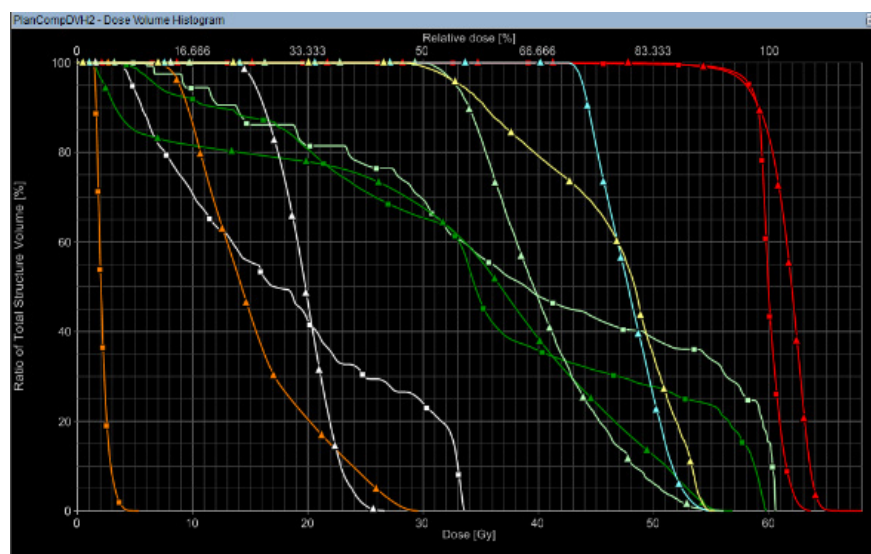


Figure 3. A Comparative DVHs for PTV Coverage and Doses to OAR for 3D-CRT (triangles) and RapidArc (squares).

post-operative T1 weighted MRI. A 2 cm margin from the GTV defined the CTV with minimal amendments in respect to the normal anatomical boundaries such as the ventricles, skull bones and nearby OAR. The dose prescribed was 60Gy/30F/6weeks. A significantly higher dosimetric advantage was observed in the tomotherapy plans as compared to the IMRT and 3D-CRT plans. In another similar study design published by Zach et al., 2009, four different planning techniques were used including 3D-CRT, integrated boost IMRT, sequential boost IMRT and tomotherapy for twenty patients with high grade gliomas. The researchers reported higher doses to the OAR in the 3D-CRT plans while the lowest was in the integrated-boost IMRT. The peri-tumoral edema was included when the treatment volume was defined. The least integral mean dose to the healthy brain was observed in the integrated-boost plan. The authors concluded that there was no single treatment plan superior to the others.

Navarria et al., (2016) analyzed progression free and overall survival as well as dosimetric assessment in 341 patients with high grade gliomas. They compared 3D-CRT and VMAT plans. They defined GTV as the post-operative resection cavity in addition to any contrast enhanced areas in T1 weighted images. An isotropic margin of 1 cm defined the CTV in their study with an additional margin of 0.3 cm to account for the PTV. They reported superior clinical and dosimetric results with the VMAT plans compared to the 3D-CRT. The results of their study was in accordance with our dosimetric outcomes which revealed that the RA showed superior dose conformity, PTV coverage, more homogeneous dose distribution when contrasted to 3D-CRT plans.

Three studies compared IMRT with VMAT in the treatment of patients with high grade gliomas (Sheffer et al., 2010; Davidson et al., 2012; Briere et al., 2017). Sheffer et al dosimetrically compared both techniques in 10 patients diagnosed with temporal and frontal high grade gliomas. All plans used a single phase dosage of 60Gy in 30 fractions over 6 weeks (2Gy/F). The authors defined the GTV as any contrast enhanced tumoral volume in T1 weighted MRI images. The CTV was defined as a 2 cm margin from the GTV taking into consideration the post-operative tumoral area in the T2 weighted MRI series. The PTV was a 0.5cm expansion from the CTV. The researchers reported an equal/similar PTV coverage, conformity and homogeneity between both plans. Nevertheless, the VMAT plans showed a statistically significant decrease in mean and maximum retinal dose, lens and contralateral optic nerve OAR doses.

Davidson et al contrasted IMRT to single arc VMAT in 12 patients with GBM. The GTV was defined as the post-operative resection cavity in addition to contrast enhancing areas in T1 weighted MRI images. The CTV was created after adding a 1.5 cm from the GTV. An isotropic margin of 0.5 cm accounted for the PTV. The authors reported similar dosimetric parameters between both techniques with the exception of a faster treatment delivery in the VMAT plans.

Briere et al., (2009) also compared IMRT and VMAT in 90 GBM patients. The dose administrated was 50Gy in 30 fractions for the PTV and 60Gy in 30 fractions for

the boost volume. The GTV and CTV were defined as per the ESTRO-ACROP guidelines. The mean doses to the brainstem, ipsilateral and contralateral cochleae were significantly lower in the VMAT plans. Treatment time was also shorter in the VMAT plans compared to IMRT. Regarding target coverage and dose homogeneity, it was found to be similar in both arms. In our present study, we concluded that with the exception of both intraocular lenses, the RA plans showed better OAR sparing and utilized a higher number of MUs compared to the 3D-CRT.

Wagner et al., (2009) compared three radiation therapy modalities dosimetrically (3D-CRT, IMRT and VMAT) in the treatment of 14 patients diagnosed as malignant gliomas. The authors defined the GTV based on the preoperative T1 weighted MRI series. An expansion of 1.5 cm from the GTV defined the CTV. A better target volume coverage was observed in the IMRT plans as compared to the VMAT plans. The VMAT plans had a lower number of monitor units, faster treatment time and a smaller V107%. The authors of this study concluded that the 3D-CRT technique is safe if the PTV is distant from the OAR while in other cases the IMRT or VMAT techniques should be considered. Similar results were shown in our study, taking the consideration the difficult location of the deep temporo-parietal high grade gliomas and its close proximity to the OARs. The Rapid Arc plans in our study showed better sparing for the OAR with the exception of both intraocular lenses.

Shorter delivery of VMAT plans is supported by previously published studies (Sheffer et al., 2010, Panet-Raymond et al., 2012). The coplanar beam configuration and the limited number of beams used in RapidArc accounts for the time saving. In our study, the average number of MUs \pm SD needed to deliver a dose of 2Gy per fraction was 358.6 ± 44.4 for the RA plans versus 247.6 ± 16.1 for 3D-CRT plans; respectively. Clinical efficacy maybe improved with shorter treatment delivery techniques especially in patients who can't tolerate the treatment mask for a long time during the session.

Our institution has now more than 10 years experience with RapidArc treatment planning and delivery. Enrollment of more patients in future clinical trials would possibly make the arc delivery a standard of care in treating deep temporo-parietal high grade gliomas in view of the difficult location of these tumors and close proximity to the nearby OAR. Further validation by other studies is highly recommended.

In conclusion, the plans achieved by RA showed superior dose conformity, PTV coverage, more homogeneous dose distribution when contrasted to 3D-CRT plans. With the exception of both intraocular lenses, the RA plans showed better OAR sparing and utilized a higher number of MUs compared to the 3D-CRT.

Author Contribution Statement

KM, AM and WH drafted the manuscript. KM & HA performed clinical data; acquisition and analysis. All authors participated in clinical data acquisition; WH, KM, HA & AM critically revised the manuscript. All authors read and approved the final manuscript.

Acknowledgments

The Authors would like to thank Ms. Lamia B for manuscript editing.

Availability of data and materials

The datasets used during the present study available from the corresponding author on reasonable request.

Ethics approval and consent to participate

An acceptance from Kasr Al-Ainy Institutional scientific and ethical committees was taken on our study design. A written informed consent was a pre-requisite to enroll the patients into the study.

Competing interests

All authors declare that they have no competing interests.

Conflict of interest

On behalf of all authors, the corresponding author states that there is no conflict of interest. There was no funding for this randomized trial

References

- Amelio D, Lorentini S, Schwarz M, Amichetti M (2010). Intensity-modulated radiation therapy in newly diagnosed glioblastoma: a systematic review on clinical and technical issues. *Radiother Oncol*, **97**, 361–9.
- Bashir R, Hochberg F, Oot R (1988). Regrowth patterns of glioblastoma multiforme related to planning of interstitial brachytherapy radiation fields. *Neurosurgery*, **23**, 27–30.
- Bhide SA, Nutting CM (2010). Advances in radiotherapy for head and neck cancer. (Review) *Oral Oncol*, **46**, 439–41.
- Bosma I, Vos MJ, Heimans JJ, et al (2007). The course of neurocognitive functioning in high-grade glioma patients. *Neuro Oncol*, **9**, 53–62.
- Brandes AA, Tosoni A, Franceschi E, et al (2009). Recurrence pattern after temozolomide concomitant with and adjuvant to radiotherapy in newly diagnosed patients with glioblastoma: correlation With MGMT promoter methylation status. *J Clin Oncol*, **27**, 1275–9.
- Briere TM, McAleer MF, Levy LB, Yang JN (2017). Sparing of normal tissues with volumetric arc radiation therapy for glioblastoma: single institution clinical experience. *Radiat Oncol*, **12**, 79.
- Buglione M, Spiazzi L, Saiani F, et al (2014). Three-dimensional conformal radiotherapy, static intensity-modulated and helical intensity-modulated radiotherapy in glioblastoma. Dosimetric comparison in patients with overlap between target volumes and organs at risk. *Tumori*, **100**, 272–7.
- Cabrera AR, Kirkpatrick JP, Fiveash JB, et al (2016). Radiation therapy for glioblastoma: Executive summary of an American Society for Radiation Oncology Evidence-Based Clinical Practice Guideline. *Pract Radiat Oncol*, **6**, 217–25.
- Cao D, Holmes TW, Afghan MK, Shepard DM (2007). Comparison of plan quality provided by intensity-modulated arc therapy and helical tomotherapy. *Int J Radiat Oncol Biol Phys*, **69**, 240–50.
- Chan MF, Schupak K, Burman C, Chui CS, Ling CC (2003). Comparison of intensity-modulated radiotherapy with three-dimensional conformal radiation therapy planning for glioblastoma multiforme. *Med Dosim*, **28**, 261–5.
- Chinnaiyan P, Won M, Wen PY, et al (2013). A phase 1 study of daily everolimus (RAD001) in combination with radiation therapy and temozolomide in patients with newly diagnosed glioblastoma. *Int J Radiat Oncol Biol Phys*, **86**, 880–4.
- Davidson MT, Masucci GL, Follwell M, et al (2012). Single arc volumetric modulated arc therapy for complex brain gliomas: is there an advantage as compared to intensity modulated radiotherapy or by adding a partial arc?. *Technol Cancer Res Treat*, **11**, 211–20.
- Fogliata A, Nicolini G, Vanetti E, Alessandro C, Cozzi L (2006). Dosimetric validation of the anisotropic analytical algorithm for photon dose calculation: fundamental characterization in water. *Phys Med Biol*, **51**, 1421–38.
- Hermanto U, Frija EK, Lii MJ, et al (2007) Intensity-modulated radiotherapy (IMRT) and conventional three-dimensional conformal radiotherapy for high-grade gliomas: does IMRT increase the integral dose to normal brain?. *Int J Radiat Oncol Biol Phys*, **67**, 1135–44.
- Kjaer Kristoffersen F, Ohlhues L, Medin J, et al (2009). RapidArc volumetric modulated therapy planning for prostate cancer patients. *Acta Oncol*, **48**, 227–32.
- Lagerwaard FJ, Meijer OW, Van der Hoorn EA, et al (2009). Volumetric modulated arc radiotherapy for vestibular schwannomas. *Int J Radiat Oncol Biol Phys*, **74**, 610–5.
- Lorentini S, Amelio D, Giri MG, et al (2013). IMRT or 3D-CRT in glioblastoma? A dosimetric criterion for patient selection. *Technol Cancer Res Treat*, **12**, 411–20.
- Louis DN, Ohgaki H, Wiestler OD, et al (2007). The 2007 WHO classification of tumours of the central nervous system. *Acta Neuropathol*, **114**, 97–109.
- MacDonald SM, Ahmad S, Kachris S, et al (2007). Intensity modulated radiation therapy versus three-dimensional conformal radiation therapy for the treatment of high grade glioma: a dosimetric comparison. *J Appl Clin Med Phys*, **8**, 47–60.
- Mashhour K, Kamaleldin M, Hashem W (2018). RapidArc vs Conventional IMRT for Head and Neck Cancer Irradiation: Is Faster Necessary Better?. *Asian Pac J Cancer Prev*, **19**, 207–11.
- McDonald MW, Shu HK, Curran Jr WJ, Crocker IR (2011). Pattern of failure after limited margin radiotherapy and temozolomide for glioblastoma. *Int J Radiat Oncol Biol Phys*, **79**, 130–6.
- Milano MT, Okunieff P, Donatello RS, et al (2010). Patterns and timing of recurrence after temozolomide-based chemoradiation for glioblastoma. *Int J Radiat Oncol Biol Phys*, **78**, 1147–55.
- Narayana A, Yamada J, Berry S, Shah P, et al (2006). Intensity-modulated radiotherapy in high grade gliomas: clinical and dosimetric results. *Int J Radiat Oncol Biol Phys*, **64**, 892–7.
- Navarria P, Pessina F, Cozzi L, et al (2016). Can advanced new radiation therapy technologies improve outcome of high grade glioma (HGG) patients? analysis of 3D-conformalradiotherapy (3DCRT) versus volumetric-modulated arc therapy (VMAT) in patients treated with surgery, concomitant and adjuvant chemo-radiotherapy. *BMC Cancer*, **16**, 362.
- Niyazi M, Brada M, Chalmers AJ, et al (2016). ESTRO-ACROP guideline “target delineation of glioblastomas”. *Radiother Oncol*, **118**, 35–42.
- Otto K (2008). Volumetric modulated arc therapy: IMRT in a single gantry arc. *Med Phys*, **35**, 310–7.
- Panet-Raymond V, Ansbacher W, Zavgorodni S, et al (2012). Coplanar versus noncoplanar intensity-modulated radiation therapy (IMRT) and volumetric-modulated arc therapy (VMAT) treatment planning for fronto-temporal high grade glioma. *J Appl Clin Med Phys*, **13**, 3826.

- Pan H, Alksne J, Mundt AJ, et al (2012). Patterns of imaging failures in glioblastoma patients treated with chemoradiation: a retrospective study. *Med Oncol*, **29**, 2040–5.
- Piroth MD, Pinkawa M, Holy R, et al (2009). Integrated-boost IMRT or 3-D-CRT using FET-PET based auto-contoured target volume delineation for glioblastoma multiforme—a dosimetric comparison. *Radiat Oncol*, **4**, 57.
- Saad S, Wang TJ (2015). Neurocognitive Deficits After Radiation Therapy for Brain Malignancies. *Am J Clin Oncol*, **38**, 634–40.
- Shaffer R, Nichol AM, Vollans E, et al (2010). A comparison of volumetric modulated arc therapy and conventional intensity modulated radiotherapy for frontal and temporal high-grade gliomas. *Int J Radiat Oncol Biol Phys*, **76**, 1177–84.
- Souhami L, Seiferheld W, Brachman D, et al (2004). Randomized comparison of stereotactic radiosurgery followed by conventional radiotherapy with carmustine to conventional radiotherapy with carmustine for patients with glioblastoma multiforme: report of Radiation Therapy Oncology Group 93–05 protocol. *Int J Radiat Oncol Biol Phys*, **60**, 853–60.
- Stupp R, Hegi ME, Mason WP, et al (2009). European Organisation for Research and Treatment of Cancer Brain Tumour and Radiation Oncology Groups; National Cancer Institute of Canada Clinical Trials Group. Effects of radiotherapy with concomitant and adjuvant Temozolomide versus radiotherapy alone on survival in Glioblastoma in a randomised phase III study: 5-year analysis of the EORTC-NCIC trial. *Lancet Oncol*, **10**, 459–66.
- Stupp R, Mason WP, van den Bent MJ, et al (2005). Radiotherapy plus concomitant and adjuvant temozolomide for glioblastoma. *N Engl J Med*, **352**, 987–96.
- Taphoorn MJ, Stupp R, Coens C, et al (2005). Health-related quality of life in patients with glioblastoma: a randomised controlled trial. *Lancet Oncol*, **6**, 937–44.
- Thibouw D, Truc G, Bertaut A, et al (2018). Clinical and dosimetric study of radiotherapy for glioblastoma: three-dimensional conformal radiotherapy versus intensity-modulated radiotherapy. *J Neurooncol*, **137**, 429–38.
- Van Esch A, Tillikainen L, Pyykkonen J, et al (2006). Testing of the analytical anisotropic algorithm for photon dose calculation. *Med Phys*, **33**, 4130–48.
- Wagner D, Christiansen H, Wolff H, Vorwerk H (2009). Radiotherapy of malignant gliomas: comparison of volumetric single arc technique (RapidArc), dynamic intensity-modulated technique and 3D conformal technique. *Radiother Oncol*, **93**, 593–6.
- Wallner KE, Galicich JH, Krol G, Arbit E, Malkin MG (1989). Patterns of failure following treatment for glioblastoma multiforme and anaplastic astrocytoma. *Int J Radiat Oncol Biol Phys*, **16**, 1405–9.
- Yu CX, Tang G (2011). Intensity-modulated arc therapy: Principles, technologies and clinical implementation. (Review). *Phys Med Biol*, **56**, 31–54.
- Zach L, Stall B, Ning H, et al (2009). A dosimetric comparison of four treatment planning methods for high grade glioma. *Radiat Oncol*, **4**, 45.



This work is licensed under a Creative Commons Attribution-Non Commercial 4.0 International License.