

RESEARCH COMMUNICATION

Altered Expression of Fas (APO-1, CD95) and Fas Ligand in the Liver of Mice Infected with *Schistosoma Japonicum* and *Schistosoma Mansoni*: Implications for Liver Carcinogenesis

Qin Shao^{1,2}, Yasuo Tohma^{1,3}, Hiroko Ohgaki¹, Hiroshi Ohshima^{1,4}

Abstract

Epidemiological studies have associated infection with *Schistosoma japonicum* and *S. mansoni* with increased risk of cancers of the liver and colon, although the mechanism of carcinogenesis remains unestablished. The livers of mice experimentally infected with *S. japonicum* or *S. mansoni* were analysed for expression of Fas (CD95/APO-1) and Fas ligand immunohistochemically and for apoptotic cell death by the TUNEL method. Fas expression was significantly decreased in hepatocytes around the inflammatory area of egg granulomas; this decrease was most prominent during the chronic phase of infection. Fas ligand was expressed in hepatocytes inside and outside granulomas, especially from mice at the early stage of infection, but not in hepatocytes from uninfected mice. Abnormal proliferation and Fas ligand expression were also observed in capillary bile ducts inside egg granulomas. Apoptotic cell death of inflammatory cells and, less frequently, of hepatocytes was found both inside and around granulomas. The rate of apoptotic cell death was high during the early stage of infection with *S. mansoni*, but decreased during the chronic phase of infection. Our results suggest that schistosome infection causes alterations of the Fas-Fas ligand system, one of the major apoptotic pathways, in mouse liver.

Key Words : Apoptosis - Fas - Fas ligand- liver cancer- *Schistosoma japonicum/mansoni* - tumour necrosis factor

Asian Pacific J Cancer Prev, 3, 361-366

Introduction

Schistosomiasis is widespread, especially in Asia, Africa and Latin America (IARC, 1994, Ross et al., 2002). A report of the World Health Organization in 1993 estimated that 200 million people were infected with schistosomes and that 600 million people were at risk of infection in 74 countries (WHO, 1993). Although in recent years the endemic areas have tended to decrease as a result of administration of antischistosomal drugs such as praziquantel and new strategies for prevention, rapid reinfection poses a threat to younger age groups due to the slow maturation of natural resistance (Wu et al., 1994; Etard et al., 1995; Jiang et al., 1996; Ross et al., 2002).

Epidemiological studies have associated schistosome infection with increased risk of cancers of the liver, colon

and urinary bladder (Ishii et al., 1989; IARC, 1994). Infection with *Schistosoma mansoni* has been associated with giant follicular lymphoma of the spleen, colorectal cancer, hepatocellular cancer, cholangiocarcinoma and other malignancies, whereas infection with *S. japonicum* has been correlated with liver and colorectal cancers (IARC, 1994). In addition, infections with *S. intercalatum* or *S. haematobium* have been associated with hydronephrosis, ovarian teratoma and urinary bladder cancer (IARC, 1994). *S. haematobium* infection has been evaluated as carcinogenic to humans by the International Agency for Research on Cancer (IARC, 1994).

Several mechanisms have been proposed for schistosome-mediated carcinogenesis. It has been suggested that parasite eggs laid by adult worms are a major factor contributing to the pathogenesis of schistosomiasis (IARC,

¹International Agency for Research on Cancer, 150 Cours Albert Thomas, 69372 Lyon Cedex 08, France, ²Present address: Dept of Parasitology, Jiangxi Medical College, Nanchang University, Nanchang 330006, People's Republic of China, ³Present address: Department of Neurosurgery, Nanto Sougou Hospital, 2007-5 Umeno Fukuokamachi, 939-0724 Toyama, Japan

⁴Correspondence: Unit of Endogenous Cancer Risk Factors, International Agency for Research on Cancer, 150 Cours Albert Thomas, 69372 Lyon Cedex 08 France Telephone: 33 4 72 73 85 09, Fax: 33 4-72 73 80 88, E-mail: ohshima@iarc.fr

1994). The parasite eggs, deposited in the liver and colon, induce strong inflammatory reactions, which may result in formation of severe lesions such as granuloma and fibrosis in the tissue. Infection can also activate inflammatory cells to generate factors (e.g. reactive oxygen and nitrogen species, etc.) which kill parasites, but may at the same time damage DNA and cells in surrounding tissues (Badawi et al., 1993; Ohshima and Bartsch, 1994). Persistent DNA and tissue damage may cause induction and accumulation of mutations, leading to cancer development. However, so far only a few laboratory studies have been carried out to investigate the role of schistosome infection in carcinogenesis and the carcinogenic mechanism remains unestablished.

Fas (APO-1 or CD95) is a 45-kDa transmembrane protein belonging to the tumour necrosis factor (TNF) and nerve growth factor receptor family (Itoh et al., 1991; Oehm et al., 1992). The Fas ligand (FasL) is a member of the TNF family of cytokines (Suda et al., 1993). Binding of the FasL to its receptor Fas induces apoptosis in Fas-expressing target cells (Nagata and Golstein, 1995; Nagata, 1997;). The Fas-FasL system plays a role in the deletion of T lymphocytes in the peripheral immune system, in the down-regulation of immune reactions, in T-cell-mediated cytotoxicity, and in the elimination of Fas-expressing leukocytes in immune privileged sites (Nagata and Golstein, 1995; Streilein, 1995; Strand et al., 1996; Nagata, 1997; Wajant, 2002). Abnormal functioning of the Fas-FasL system may, however, cause deleterious effects (Nagata and Golstein, 1995; Nagata, 1997). Although the system has been relatively well investigated in viral infections (Kishi et al., 1997; Sieg et al., 1997; Hayashi and Mita, 2002), there have been only a few investigations on Fas and FasL in relation to parasite infection. In this paper, we present evidence indicating that schistosome infection alters expression of Fas and FasL in the liver, which may be associated with hepatocarcinogenesis.

Materials and Methods

Treatment of Animals

A total of 80 female C57BL/6JICO mice were obtained from IFFA-CREDO (Lyon, France). They were divided into three groups: (i) *S. japonicum*-infected group: 20 mice 9 weeks of age were infected through the shaved abdomen with 20 cercariae of *S. japonicum* (Chinese strain); (ii) *S. mansoni*-infected group: 40 mice 11 weeks of age were exposed to 40 cercariae of *S. mansoni* (Puerto Rican strain) by subcutaneous injection; (iii) uninfected group: 20 mice were used as control. Faecal samples were collected from each mouse to analyse for parasite eggs. Four to eleven mice from each group were killed by cervical dislocation between 7 and 21 weeks after infection, and liver samples were fixed in 10% buffered formalin and embedded in paraffin.

Immunohistochemistry

Immunohistochemical staining of Fas and FasL was carried out using an anti-human Fas polyclonal antibody

(kindly provided by Dr. Nakanishi. Kanazawa University, Japan), which recognizes Fas extracellular domains of both the mouse and human proteins. FasL polyclonal antibody against human FasL, which also reacts with murine FasL, was purchased from Santa Cruz Biotechnology (Santa Cruz, CA). The avidin-biotin peroxidase method was applied. Briefly, to stain with Fas antibody, sections were deparaffinized and rehydrated. Endogenous peroxidase was blocked by incubating the sections in 0.3% hydrogen peroxide in absolute methanol for 30 min at room temperature, followed by a brief wash in phosphate-buffered saline (PBS). Tissue sections were treated with (a) 0.1% trypsin-CaCl₂ solution (pH 7.8, 37°C) for 15 min, (b) 5% skim milk plus 0.1 % bovine serum albumin for 120 min, (c) Fas antibody (dilution 1:1000 in PBS containing 0.1 % bovine serum albumin) at 4°C overnight, (d) biotinylated goat anti-rabbit IgG antibody, (e) avidin-biotin peroxidase complex (ABC kit, Vector Lab. Inc., Burlingame, CA) and (f) 3,3'-diaminobenzidine tetrahydrochloride (0.05% in 0.05 M Tris-HCl, pH 7.6) solution. The sections were counterstained with hematoxylin, rehydrated and mounted. For FasL staining, a high-temperature antigen unmasking technique, instead of proteinase digestion, was applied to enhance antigen retrieval. The sections were immersed in 0.01 M sodium citrate buffer (pH 6.0) and heated in a pressure cooker for 10 min. FasL antibody (dilution 1:2000 in PBS containing 0.1 % bovine serum albumin) was used. Specificities of antibodies against Fas and FasL were verified using formalin-fixed, paraffin-embedded sections of mouse tissues and human liver. Positive controls, i.e. human liver for Fas immunohistochemistry and mouse testis, thymus and spleen for FasL immunohistochemistry were consistently positive, while negative controls, i.e., sections without primary antibody and those with non-immunized rabbit serum for Fas and FasL immunohistochemistry were consistently negative.

Analysis of Apoptosis and Mitotic Cells

Apoptotic cells with DNA fragmentation were analysed in the liver sections using the terminal deoxynucleotidyl transferase-mediated dUTP-biotin nick end labelling (TUNEL) method (Apop Tag, Oncor Inc., Gaithersburg, MD). Cells were defined as apoptotic if the cell was labelled positively in the whole nuclear area or formed an apoptotic body. The number of apoptotic cells outside egg granuloma were counted under a light microscope in more than ten high-power field areas (400x). Hepatocytes in division were also quantified as % of mitotic hepatocytes.

Results

Mice infected with *S. mansoni* or *S. japonicum* began to excrete parasite eggs in their faeces less than 7 weeks after infection. Egg granulomas were observed in the colon and liver from the infected mice killed after seven weeks after infection. Under the present experimental conditions, the liver from mice infected with *S. japonicum* was darker in

colour and showed more lesions than the liver of mice infected with *S. mansoni*. Some *S. japonicum*-infected mice died 8 weeks after infection, and all the remaining mice were sacrificed at 9 weeks, whereas those infected with *S. mansoni* were kept for 21 weeks.

Expression of Fas

Fas antigen was expressed in cytoplasmic membrane and cytoplasm of hepatocytes from the liver of uninfected mice (Figure 1A). Fas was also expressed in hepatocytes of the mice infected with *S. mansoni* or *S. japonicum*. However,

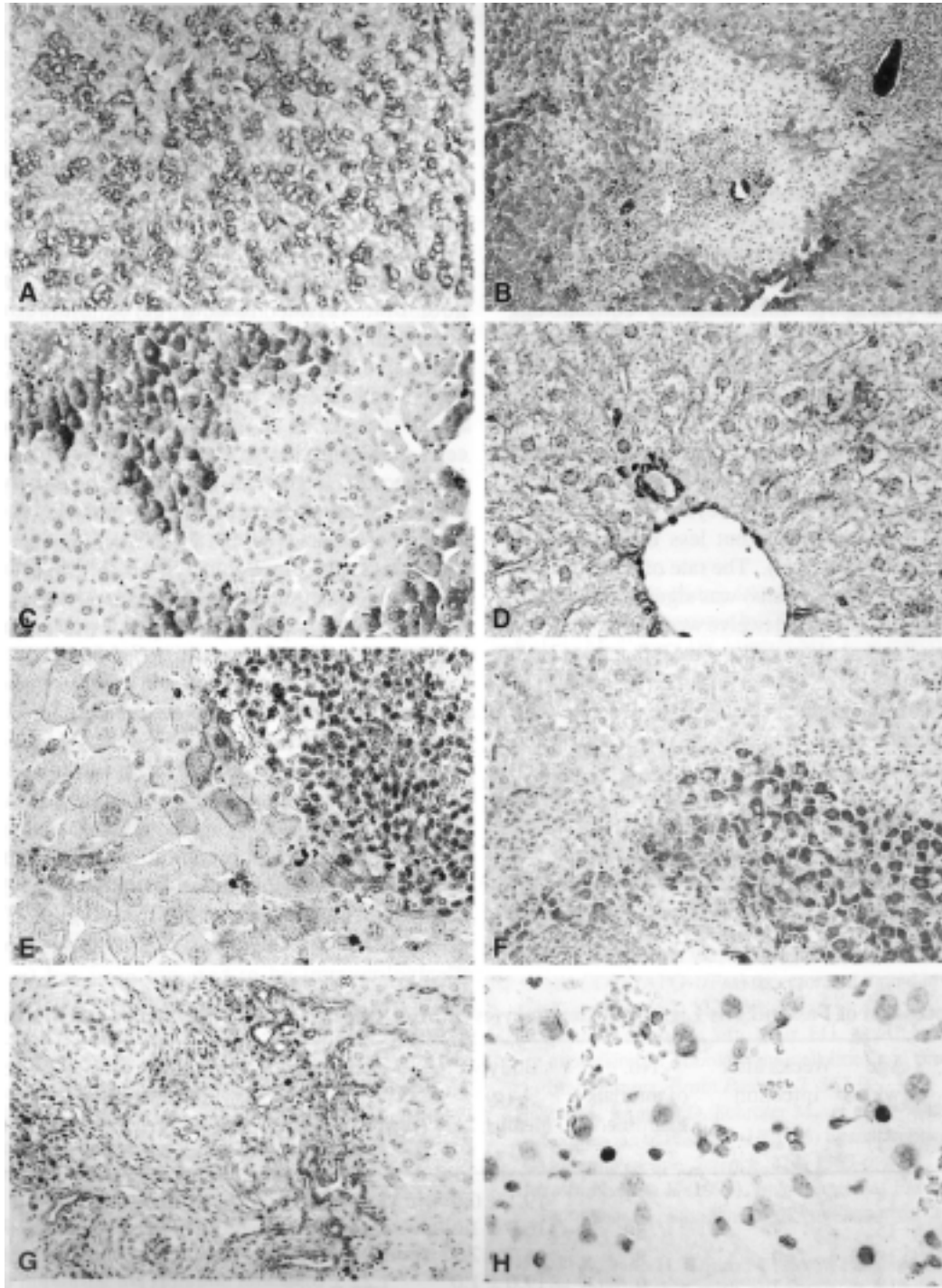


Figure 1. Altered expression of Fas and FasL in the liver of mice infected with *S. japonicum* or *S. mansoni*. A, Fas expression in cytoplasmic membrane of hepatocytes in the liver of an uninfected mouse (15 weeks old) x300; B and C, decreased expression of Fas in the liver from a mouse 9 weeks after infection with *S. japonicum* and in the liver from a mouse 12 weeks after infection with *S. mansoni*, respectively, x200; D, FasL is expressed in bile duct cells, but not in hepatocytes of an uninfected mouse, x350; E and F, FasL expression in hepatocytes inside and outside granulomas from a mouse 7 weeks after infection with *S. japonicum*, x350 and x200, respectively; G, proliferating capillary bile ducts, which show strong FasL expression in the periphery of egg granuloma, especially in a mouse 21 weeks after infection with *S. mansoni*, x200; H, apoptotic cells observed outside granuloma from the liver of a mouse 7 weeks after infection with *S. mansoni*, x450.

its expression decreased significantly in the areas around egg granulomas from the liver of some mice infected with *S. mansoni* or *S. japonicum* (Figure 1B, C). This effect was more prominent in the liver of mice after prolonged infection with *S. mansoni* (Table I). Fas expression was also observed in some inflammatory cells infiltrating in egg granulomas (Figure 1B, C).

Expression of FasL

FasL was not expressed in normal hepatocytes, but was expressed in bile ducts in uninfected mice (Figure 1D). In infected mice, cytoplasmic membrane and cytoplasm of hepatocytes and proliferating bile ducts inside and outside granulomas expressed FasL (Figure 1E-G). FasL expression was detected more frequently at seven weeks after infection than at longer periods of infection with either *S. mansoni* or *S. japonicum* (Table 1). Inflammatory cells in egg granulomas also occasionally expressed FasL in infected mice killed earlier than 12 weeks after infection.

Apoptotic Cell Death

In the liver of infected mice, apoptotic cell death of inflammatory cells was detected especially inside granulomas, whereas that of hepatocytes was found both inside and around granulomas, but less frequently than inflammatory cells (Figure 1H). The rate of apoptotic cell death (mainly inflammatory cells) was significantly higher in the liver of mice at seven and twelve weeks after infection with *S. mansoni* and at nine weeks after infection with *S. japonicum*, compared to that of uninfected mice. The percentage of these apoptotic cells began to decrease at 12 weeks after infection with *S. mansoni* and reached the levels of non-infected livers at 21 weeks.

Mitotic Index

Mitotic hepatocytes outside granulomas tended to decrease at 9 weeks after infection with *S. japonicum* and 12 weeks after infection with *S. mansoni*, compared to uninfected mice.

Discussion

Mice infected with either *S. mansoni* or *S. japonicum* developed granulomatous inflammation in the liver. We have studied expression of Fas and FasL, as well as apoptotic cell death and mitosis in relation to egg granuloma formation in the liver. We found that Fas expression in the areas around egg granulomas decreased significantly during chronic infection. The mechanism of this decreased expression of Fas remains to be established. Only a few compounds, including an immunosuppressive agent, FK506 (Yokoyama et al., 1996), have been reported to down-regulate Fas expression, although some compounds such as interferon- γ and TNF- α up-regulate its expression in various cells including hepatocytes (Maciejewski et al., 1995; Ortiz Arduan et al., 1996; Yano et al., 1996). It is interesting to note that various tumour cells, including human hepatocellular carcinomas, have partially or completely lost expression of Fas, which is constitutively expressed by normal cells (Leithauser et al., 1993; Higaki et al., 1996; Strand et al., 1996). Loss of Fas antigen may render tumour cells less sensitive to Fas-mediated cytotoxicity of T lymphocytes. In contrast, Fas expression in hepatocytes is highly elevated in hepatitis B virus-related cirrhosis and in acute liver failure (Galle et al., 1995).

In this study, expression of FasL, which is not observed in hepatocytes of uninfected liver, was detected frequently in hepatocytes both inside and outside granulomas in mice infected with either *S. mansoni* or *S. japonicum*. In contrast to Fas expression, FasL expression in hepatocytes was more prevalent during the acute than the chronic phase of infection. FasL has been reported to be expressed in activated T lymphocytes (Suda et al., 1995) in several normal adult tissues, including the thymus, lung, spleen, small intestine etc. (French et al., 1996), in tumour cells including human hepatocellular carcinomas, colon adenocarcinomas, melanomas and glioblastomas (Hahne et al., 1996; Higaki et al., 1996; Strand et al., 1996; Gratas et al., 1997; Niehans et al., 1997; O'Connell et al., 1997) and in hepatocytes from

Table 1. Expression of Fas and Fas Ligand in Hepatocytes of Mice Infected with *S. japonicum* and *S. mansoni*

Infection	Age (wk)	Weeks after infection	No. of animals examined	Body wt (g) mean \pm SD	Liver wt (g) mean \pm SD	No. of animals with decreased Fas expression (%)	No. of animals with FasL expression (%)
Control	15	-	6	19.1 \pm 0.9	0.98 \pm 0.09	0	0
<i>S. japonicum</i>	15	7	8	16.0 \pm 1.2	1.44 \pm 0.17	1 (13)	7 (88)
<i>S. japonicum</i>	18	9	8	16.7 \pm 2.3	1.44 \pm 0.37	2 (25)	3 (38)
<i>S. mansoni</i>	18	7	9	19.0 \pm 1.0	1.22 \pm 0.98	1 (11)	6 (67)
Control	24	-	6	21.0 \pm 1.0	1.05 \pm 0.11	0	0
<i>S. mansoni</i>	24	12	9	19.8 \pm 1.4	1.49 \pm 0.13	2 (22)	2 (22)
Control	32	-	4	19.9 \pm 0.9	1.05 \pm 0.07	0	0
<i>S. mansoni</i>	32	21	11	20.7 \pm 1.4	1.61 \pm 0.23	5 (46)	0

patients with alcoholic hepatitis (Galle et al., 1995). Tumour cells expressing FasL may counterattack the immune system, by actively killing lymphocytes via the Fas-FasL system (French et al., 1996; Higaki et al., 1996; Strand et al., 1996; Gratas et al., 1997; Niehans et al., 1997; O'Connell et al., 1997). FasL expression can also be induced by cytostatic drugs (Muller et al., 1997) as well as by reactive oxygen species including hydrogen peroxide (Hug et al., 1997) in a variety of cell lines.

Apoptotic cell death of inflammatory cells and, less frequently, of hepatocytes was found both inside and around granulomas. The rate of apoptotic cell death was high during the early stage of infection with *S. mansoni*, but decreased during the chronic phase of infection. FasL was expressed in hepatocytes frequently during the acute phase of infection, whereas Fas expression in the areas around egg granulomas decreased significantly during chronic infection. Thus, the expression of FasL in hepatocytes during the acute phase of infection may contribute to apoptotic cell death of hepatocytes through an autocrine (fratricide) mechanism. Inflammatory cells may also be killed by interaction between Fas-expressing leukocytes and FasL-expressing hepatocytes. On the other hand, the decreased expression of Fas receptor in hepatocytes around egg granulomas could contribute to decreased apoptotic cell death during the chronic phase of infection. This decreased apoptosis may result in prolonged exposure of the cells to reactive oxygen and nitrogen species produced by inflammatory cells, leading to increased DNA damage and mutations, which contribute to cancer development.

The altered expression of Fas and FasL may also have effects on egg granuloma formation. It has been reported that the responsiveness of T lymphocytes to mitogens and egg antigens is impaired during the chronic stage of infection with *S. mansoni* or *S. japonicum* (Warren et al., 1975; Olds et al., 1989; Weinstock, 1992). As a result, newly formed granulomas are less dynamic and are smaller in size during the chronic stage than during the acute stage of infection. This down-regulation of granuloma formation (termed modulation) has been reported to be immunologically regulated and to be dependent on the interaction of Th1 and Th2 subsets of lymphocytes (Olds et al., 1989). Our results suggest that altered expression of Fas and FasL after infection with schistosomes may contribute to this modulation process. Recent studies have shown that expression of FasL in colon carcinoma cells suppresses the activity of cytotoxic T cells and inhibits the generation of alloantibodies of both IgM and IgG subclasses (Arai et al., 1997). Thus altered expression of Fas-FasL could be involved in the modulation process by modulating responsiveness of T lymphocytes as well as by impairing the immune function.

In summary, loss of Fas expression and gain of FasL expression observed during schistosome infection may affect the mechanism of apoptotic cell death mediated by the Fas-FasL system in the liver. Hepatocytes with altered Fas-FasL expression could escape from the immune system, resulting in accumulation of DNA damage and genetic alterations.

Thus infection with schistosomes may be associated with hepatocarcinogenesis through several factors such as immune suppression, tumour-promoting activity from egg antigen, carcinogens formed endogenously or present in the environment, and altered metabolic and detoxifying functions of the infected liver (Ishii et al., 1989; IARC, 1994; Ohshima and Bartsch, 1994).

Acknowledgements

We gratefully acknowledge Dr Maurice Cornu (Institut Pasteur, Lyon) for helping us to infect animals with *S. mansoni*, Professor Anne-Françoise Pétavy (Laboratoire de Parasitologie et de Mycologie Médicale, Faculté de Pharmacie, Université Claude Bernard Lyon 1), for useful discussion and Dr. Nakanishi, Kanazawa University, Japan for kindly providing the antibody against Fas. The authors also thank Dr. J. Cheney for editing the manuscript, Mrs. M. Laval and N. Lyandrat for technical assistance and Mrs. P. Collard for secretarial work. QS is a recipient of a fellowship from the State Education Commission of the People's Republic of China.

References

- Arai H, Chan SY, Bishop DK, Nabel GJ (1997). Inhibition of the alloantibody response by CD95 ligand. *Nat Med*, **3**, 843-8.
- Badawi AF, Cooper DP, Mostafa MH, et al (1993). Promutagenic methylation damage in liver DNA of mice infected with *Schistosoma mansoni*. *Carcinogenesis*, **14**, 653-7.
- Etard JF, Audibert M, Dabo A (1995). Age-acquired resistance and predisposition to reinfection with *Schistosoma haematobium* after treatment with praziquantel in Mali. *Am J Trop Med Hyg*, **52**, 549-58.
- French LE, Hahne M, Viard I, et al (1996). Fas and Fas ligand in embryos and adult mice: ligand expression in several immune-privileged tissues and coexpression in adult tissues characterized by apoptotic cell turnover. *J Cell Biol*, **133**, 335-43.
- Galle PR, Hofmann WJ, Walczak H, et al (1995). Involvement of the CD95 (Apo-1/Fas) receptor and ligand in liver damage. *J Exp Med*, **182**, 1223-30.
- Gratas C, Tohma Y, Van Meir EG, et al (1997). Fas ligand expression in glioblastoma cell lines and primary astrocytic brain tumors. *Brain Pathol*, **7**, 863-9.
- Hahne M, Rimoldi D, Schroter M, et al (1996). Melanoma cell expression of Fas(Apo-1/CD95) ligand: implications for tumor immune escape. *Science*, **274**, 1363-6.
- Hayashi N, Mita E (1999). Involvement of Fas system-mediated apoptosis in pathogenesis of viral hepatitis. *J Viral Hepat*, **6**, 357-65.
- Higaki K, Yano H, Kojiro M (1996). Fas antigen expression and its relationship with apoptosis in human hepatocellular carcinoma and noncancerous tissues. *Am J Pathol*, **149**, 429-37.
- Hug H, Strand S, Grambihler A, et al (1997). Reactive oxygen intermediates are involved in the induction of CD95 ligand mRNA expression by cytostatic drugs in hepatoma cells. *J Biol Chem*, **272**, 28191-3.

- IARC (1994). IARC Monographs on the Evaluation of Carcinogenic Risks to Humans Vol.61, Schistosomes, liver flukes and Helicobacter pylori, IARC, Lyon, pp 45-119.
- Ishii A, Matsuoka H, Aji T, et al (1989). Evaluation of the mutagenicity and the tumor-promoting activity of parasite extracts: Schistosoma japonicum and Clonorchis sinensis. *Mutat Res*, **224**, 229-33.
- Itoh N, Yonehara S, Ishii A, et al (1991). The polypeptide encoded by the cDNA for human cell surface antigen Fas can mediate apoptosis. *Cell*, **66**, 233-43.
- Jiang Q, Zhang S, Yuan H, et al (1996). The effect of a combined approach to schistosomiasis control on the transmission of Schistosoma japonicum in Xingzi of Poyang Lake area, China. *Southeastern Asian J Trop Med Public Health*, **27**, 535-41.
- Kishi S, Saijyo S, Arai M, et al (1997). Resistance to fas-mediated apoptosis of peripheral T cells in human T lymphocyte virus type I (HTLV-I) transgenic mice with autoimmune arthropathy. *J Exp Med*, **186**, 57-64.
- Leithauser F, Dhein J, Mechtersheimer G, et al (1993). Constitutive and induced expression of APO-1, a new member of the nerve growth factor/tumor necrosis factor receptor superfamily, in normal and neoplastic cells. *Lab Invest*, **69**, 415-29.
- Maciejewski J, Sessler C, Anderson S, Young NS (1995). Fas antigen expression on CD34+ human marrow cells is induced by interferon gamma and tumor necrosis factor alpha and potentiates cytokine-mediated hematopoietic suppression in vitro. *Blood*, **85**, 3183-90.
- Muller M, Strand S, Hug H, et al (1997). Drug-induced apoptosis in hepatoma cells is mediated by the CD95 (APO-1/Fas) receptor/ligand system and involves activation of wild-type p53. *J Clin Invest*, **99**, 403-13.
- Nagata S (1997). Apoptosis by death factor. *Cell*, **88**, 355-65.
- Nagata S, Golstein P (1995). The Fas death factor. *Science*, **267**, 1449-56.
- Niehans GA, Brunner T, Frizelle SP, et al (1997). Human lung carcinomas express Fas ligand. *Cancer Res*, **57**, 1007-12.
- O'Connell J, Bennett MW, O'Sullivan GC, Collins JK, Shanahan F (1997). The Fas counterattack: a molecular mechanism of tumor immune privilege. *Mol Med*, **3**, 294-300.
- Oehm A, Behrmann I, Falk W, et al (1992). Purification and molecular cloning of the APO-1 cell surface antigen, a member of the tumor necrosis factor/nerve growth factor receptor superfamily. Sequence identity with the Fas antigen. *J Biol Chem*, **267**, 10709-15.
- Ohshima H, Bartsch H (1994). Chronic infections and inflammatory processes as cancer risk factors: possible role of nitric oxide in carcinogenesis. *Mutat Res*, **305**, 253-64.
- Olds GR, El Meneza S, Mahmoud AF, Kresina, TF (1989). Differential immunoregulation of granulomatous inflammation, portal hypertension, and hepatic fibrosis in murine schistosomiasis mansoni. *J Immunol*, **142**, 3605-11.
- Ortiz Arduan A, Danoff TM, Kalluri R, et al (1996). Regulation of Fas and Fas ligand expression in cultured murine renal cells and in the kidney during endotoxemia. *Am J Physiol*, **271**, F1193-201.
- Ross AGP, Bartley PB, Sleight AC, et al (2002) Schistosomiasis. *N Engl J Med*, **346**, 1212-20.
- Sieg S, Huang Y, Kaplan D (1997). Viral regulation of CD95 expression and apoptosis in T lymphocytes. *J Immunol*, **159**, 1192-9.
- Strand S, Hofmann WJ, Hug H, et al (1996). Lymphocyte apoptosis induced by CD95 (APO-1/Fas) ligand-expressing tumor cells—a mechanism of immune evasion? *Nat Med*, **2**, 1361-6.
- Streilein JW (1995). Unraveling immune privilege. *Science*, **270**, 1158-9.
- Suda T, Okazaki T, Naito Y, et al (1995). Expression of the Fas ligand in cells of T cell lineage. *J Immunol*, **154**, 3806-13.
- Suda T, Takahashi T, Golstein P, Nagata S, (1993). Molecular cloning and expression of the Fas ligand, a novel member of the tumor necrosis factor family. *Cell*, **75**, 1169-78.
- Wajant H (2002). The Fas signaling pathway: more than a paradigm. *Science*, **296**, 1635-6.
- Warren KS, Boros DL, Hang LM, Mahmoud AA (1975). The Schistosoma japonicum egg granuloma. *American J Pathol*, **80**, 279-93.
- Weinstock JV (1992). The pathogenesis of granulomatous inflammation and organ injury in schistosomiasis: interactions between the schistosome ova and the host. *Immunol Invest*, **21**, 455-75.
- WHO (1993). The control of schistosomiasis. Second report of the WHO Expert Committee. *World Health Organ Tech Rep Ser*, **830**, 1-86.
- Wu Z, Shaoji, Z., Pan, B., et al (1994). Reinfection with Schistosoma japonicum after treatment with praziquantel in Poyang lake region, China. *Southeastern Asian J Trop Med Public Health*, **25**, 163-9.
- Yano H, Fukuda K, Haramaki M, et al (1996). Expression of Fas and anti-Fas-mediated apoptosis in human hepatocellular carcinoma cell lines. *J Hepatol*, **25**, 454-64.
- Yokoyama I, Hayakawa A, Hayashi S, et al (1996). Decreased Fas antigen expression of cultured hepatocytes with FK 506. *Transplant Proc*, **28**, 3189-90.