
RESEARCH COMMUNICATION

Sonographic Morphology Scores (SMS) for Differentiation between Benign and Malignant Adnexal Masses

Chanane Wanapirak, Kasemsri Srisupundit, Theera Tongsong*

Abstract

Objective: To determine the sensitivity and specificity of a scoring system for distinguishing between benign and malignant adnexal masses and to detect threshold scores for prediction of malignant ovarian tumors. **Study design:** Cross-sectional diagnostic testing. **Setting:** Department of Obstetrics and Gynecology, Faculty of Medicine, Chiang Mai University. **Subjects:** A total 158 patients scheduled for elective surgery due to ovarian tumors at Maharaj Nakorn Chiang Mai Hospital between June 16, 2002 and August 8, 2004 were recruited into the study. **Methods:** All patients were sonographically examined within 72 hours before surgery by the same sonographer to evaluate the morphology including wall structure, shadowing, septum, echogenicity and score the tumors. The final diagnosis was based on either pathological or operative findings. **Main outcome measure :** Sensitivity and specificity of the best cut-off score. **Results:** A score of 5 from the receiver operating characteristic curve was found to be the best cut-off score, giving a sensitivity and a specificity of 85% and 70%, respectively. **Conclusion:** Sonographic morphology scores are useful in distinguishing adnexal malignancies from benign lesions in some selected cases.

Key Words: Ultrasonography - sonographic morphology scores - adnexal masses

Asian Pacific J Cancer Prev, 7, 407-410

Introduction

Ovarian cancer is the leading cause of death in women with gynecologic cancer in developing countries. A woman's lifetime risk has been estimated to be about 1 in 55, which represents an increase from the 1970 figure of 1 in 70 (Piver et al., 1996). In the year 2005, an estimated 22,220 new cases of ovarian cancer were diagnosed in the US alone, with 16,210 deaths predicted (Jemal et al., 2005). The incidence of ovarian cancer among all female cancers in our Hospital between 1987-1994 was 9.6%, only 51.3% of the tumors being stage I and many being late stage (Annual Report 2004).

Until currently, there has been no effective screening method for ovarian cancer and because the lesions are usually asymptomatic until they have metastasized, patients have advanced disease at diagnosis in more than two-thirds of the cases and the prognosis is therefore poor. Several attempts have been made to distinguish benign from malignant conditions, especially using pelvic ultrasound based on either morphological appearance or Doppler waveforms. However, there has been no ideal screening test developed with very high sensitivity and specificity for ovarian cancer.

Some studies (Sassone et al., 1991; Lerner et al., 1994; Wanapirak et al., 2001) showed that sonographic features of masses may offer clues to effectively differentiate benign from malignant tumors with various degrees of accuracy. At present, the Lerner and Timor-Tritsch sonographic scoring system (Lerner et al., 1994) is considered to be most effective. The purpose of the present study was to determine sensitivity and specificity for threshold sonographic scores for prediction of malignant adnexal masses based on the Lerner and Trimor-Tritsch scoring system.

Materials and Methods

One hundred and fifty-eight patients (185 adnexal masses) scheduled for elective surgery due to ovarian tumors at Maharaj Nakorn Chiang Mai Hospital between June 16, 2002 and August 8, 2004 were recruited into the study. Exclusion criteria were as follows: 1) patients with ovarian malignancies who were scheduled for second look operations; 2) patients undergoing operations more than 72 hours after ultrasound examination. All of the participating women were counseled and invited to join the study with informed consent.

Transabdominal sonography was conducted by the same

Department of Obstetrics and Gynecology, Faculty of Medicine, Chiang Mai University, Chiang Mai, 50200, Thailand

**For Correspondence Tel : 66 053 946429 Fax : 66 53 946112 E-mail : ttongson@mail.med.cmu.ac.th*

Table 1. The Sonographic Scoring System

Parameter	0	1	2	3
Wall structure	Smooth/irregularity < 3 mm	-	Solid or non-applicable	Papillarity ≥ 3 mm
Shadowing	Yes	No	-	-
Septa	None or thin (<3 mm)	Thick (≥ 3 mm)	-	-
Echogenicity	Sonolucent/low-level	-	-	Mixed or high

Table 2. Mean Sonographic Scores for the Benign and Malignant Groups

Pathology	Number	SMS	SD	Range
Benign	120	2.59	2.33	0-8
Malignant	65	5.75	1.77	0-8
- Borderline	7	6.43	1.51	4-8
- Cancer	58	5.67	1.79	0-8
Total	185	3.70	2.63	0-8

sonographer using a curvilinear transabdominal probe, Aloka model 5000, frequency 3.5 MHz, scan 90 degrees. If the morphology of mass could not be seen clearly by transabdominal sonography then a transvaginal approach was made using a curvilinear transvaginal probe, Aloka model 5000, frequency 5 MHz, scan 120 degree (Tokyo, Japan). Sonographic morphology scores were based on the Lerner and Trimor-Tritsch scoring system (Lerner et al., 1994) with concentration on the 4 parameters of wall structure, shadowing, septa and echogenicity, with weighting of the values for each variable then summing of scores with range of possible scores of 0-8 points, as shown in Table 1.

A score was assigned to each ovarian or adnexal mass, rather than to each patient. The final diagnosis for the gold standard was by histopathological examination in all cases for which specimens were obtained. However, for the cases with no specimen, including the few cases of benign conditions such as follicular cyst, the diagnosis was based on intraoperative or laparoscopic findings. We included

borderline ovarian tumors into the malignant group, so all ovarian tumor and adnexal masses were divided in 2 groups featuring benign and malignant adnexal masses.

All data were analyzed using the Stata program.

Results

One hundred and fifty-eight patients (185 adnexal masses) with a suspected ovarian tumor were examined by sonography and underwent laparotomy or laparoscopic surgery during June 16, 2002 to August 8, 2004. The patient's age ranged from 13 to 79 with a mean of 44.84 years. According to histologic diagnosis or intraoperative findings, 120 of adnexal masses were benign and 65 masses were malignant, including 58 cancer masses and 7 borderline tumor masses. The mean ages in the benign and malignant groups were 41.2 and 51.57 years, respectively.

In premenopausal patients, there were 79.0% benign tumors, 3.4% borderline tumors and 17.7% cancers. In postmenopausal patients the respective figures were 36.4%, 4.6% and 56.1%. The mean score of the malignant group was significantly higher than that of the benign group, 2.6 and 5.8, as shown in Table 2, respectively.

The sensitivity and specificity for each score were plotted to create a receiver operating characteristic curve (ROC). Construction of this curve showed that 5 was the score that best distinguished malignant from benign adnexal masses, giving a sensitivity and specificity of 85 and 70 per cent, respectively, a positive predictive value (PPV) of 60% and

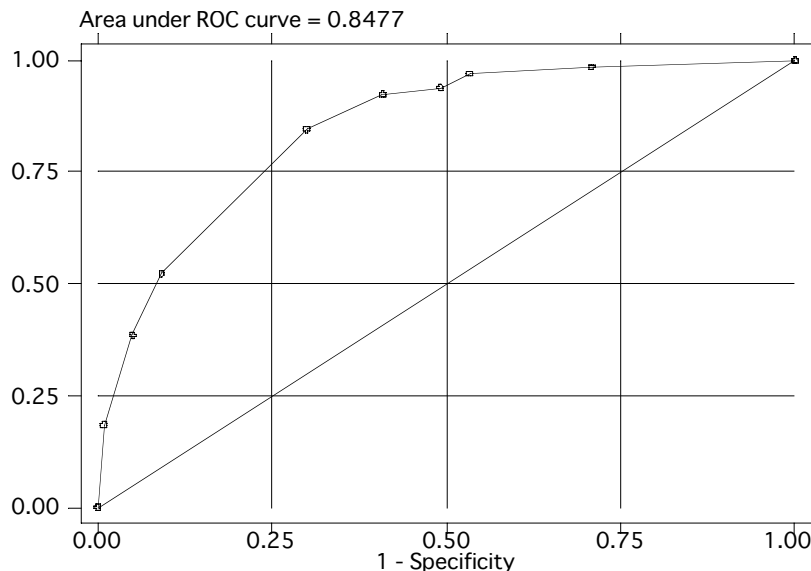


Figure 1. Receiver Operating Characteristic (ROC) Curve for the Scoring System

Table 3. Sonographic Scores for Each Type of Final Diagnosis with SMS>5

Final Diagnosis	Number	SMS		Number (%)
		Mean	Range	
Malignant				
Mucinous tumor of LMP	7	6.4	4-8	6 (85)
Serous adenocarcinoma	17	5.5	3-8	15 (88)
Mucinous adenocarcinoma	4	5.5	2-7	3 (75)
Endometrioid carcinoma	7	6.4	4-8	6 (85)
Germ cell tumor	3	6.0	5-7	3 (100)
Metastatic carcinoma	10	5.8	0-8	7 (70)
Clear cell carcinoma	3	5.7	5-7	3 (100)
Sexcord stromal tumor	2	4.0	1-7	1 (50)
Others	12	5.7	2-8	11 (91)
Benign				
Simple cyst	10	1.5	0-5	1 (10)
Serous cystadenoma	7	0.9	0-3	0 (0)
Mucinous cystadenoma	12	1.8	0-5	1 (8)
Endometriosis	42	1.6	0.7	6 (14)
Mature cystic teratoma	23	4.4	0-7	16 (69)
Tubo-ovarian abscess	2	4.0	4-4	0 (0)
Uterine leiomyoma	6	4.8	0-8	4 (66)
Others	18	3.7	0-6	8 (44)
Total	185	3.7	0-8	91 (49)

a negative predictive value (NPV) of 89 %, as shown in Figure 1. The mean and range of scores for each type of adnexal mass and adnexal masses that had an SMS > 5 are shown in Table 3.

Discussion

Preoperative prediction of the histological diagnosis of adnexal masses especially ovarian masses is important for planning of treatment but there is currently been no effective method for screening for adnexal malignancies. Many investigators attempted to determine the sonographic morphology scoring system that used to differentiate benign from malignant neoplasms as reported by Sassone et al (1991), Lerner et al (1994), Weber et al (1999), and Merz et al (1998). The sensitivity and specificity of these sonography systems in predicting a malignant ovarian tumor varied from 83 to 96.8% and 77 to 100%, respectively.

According to one of the well-known scoring system originally reported by Sassone et al (1991) and later reported from our institution (Wanapirak et al., 2001) Sassone scoring system has rather high sensitivity and specificity, but it has high false positive rate with some benign tumor especially mature teratoma, endometrioma and mucinous cystadenoma.

In 1994, Lerner et al (1994) attempted to improve discriminatory ability in evaluation of adnexal masses and to simplify the scoring system by excluding the parameter of wall thickness from Sassone scoring system (Sassone et al., 1991) and added another important parameter especially shadowing in order to discriminate cystic teratoma from malignant adnexal masses and to improve positive predictive value. The Lerner scoring system using a cut-off at score 3

was reported to have 96.8% sensitivity, 77% specificity and 29.4% and 99.6% positive predictive value and negative predictive value respectively. For practical purposes, we used the variables based on SMS system proposed by Lerner et al (1994) because they are simple and easy to learn and can widely be applied without Doppler equipment. The variables including inner wall structure, shadowing, septa, and echogenicity, could be clearly visualized in most cases. Based on receiver operating characteristic (ROC) curve, the best cut-off score to discriminate malignant from benign adnexal masses was 5 with a sensitivity of 85% and specificity of 70%, lower than the values in the original study of Lerner et al (1994).

Interestingly, we found that despite including shadowing into this new scoring system to improve discriminatory ability in dermoid cysts, the false positive rate remained high (36 from 91 masses), especially in cases of mature teratoma, myoma, and tubo-ovarian abscess or complexes. These tumors were benign but had high scores because of their high echogenicity. This finding was consistent with that observed by Sassone et al (1991).

Our results did not show the superiority of the Lerner scoring system. However, in practical use this pitfall may be overcome by other characteristics of these tumors which are not included in the SMS system, such as fried egg appearance or hair speckles of mature teratoma, highly homogeneous echogenicity of endometrioma, multiple edged-shadow of myoma and some advanced stage ovarian malignancy with its frank peritoneal seeding or omental cake or ascites. In reality, experienced sonographer can diagnose mature teratoma or endometrioma without difficulty. The characteristic sonographic features of some type of adnexal mass alone can predict the histology without using any scoring system at all. Therefore if we had excluded these tumors from the study, the discriminatory ability of scoring system might have been improved.

As previously described, the scoring system may be useful in some selected cases, especially in adnexal masses without typical sonographic characteristics of a certain disorder and difficult to predict subjectively. If a Doppler study of the adnexal masses was added the accuracy of prediction may improve. The reliability of this study is based on the fact that ultrasound examinations were conducted by only one experienced examiner who had no clinical information on the patients, resulting in no inter-observer variability. Furthermore, the examinations were all completed with the same high quality equipment, and finally the sample size was adequate.

In summary, even though the sensitivity and specificity of the Lerner scoring system tested in this study were not as high as in the previous original study of Lerner, it may probably be useful in clinical practice for some selected cases. However, false positive rates were relatively great with mature teratomas, endometriomas and myomas due to their high echogenicity, so that extreme caution should be taken regarding these conditions.

References

- Annual Report on Gynecologic Oncology, Division of Gynecologic Oncology 2004, Department of Obstetrics and Gynecology Faculty of Medicine, Chiang Mai University, Thailand.
- Jemal A, Murray T, Ward E, et al (2005). Cancer statistics, 2005. *CA: A Cancer Journal for Clinicians*, **55**, 10–30.
- Lerner JP, Timor-Tritsch IE, Federman A, Abramovich G (1994). Transvaginal ultrasonographic characterization of ovarian masses with an improved, weighted scoring system. *Am J Obstet Gynecol*, **170**, 81-5.
- Merz E, Weber G, Bahlmann F, Kiesslich R (1998). A new sonomorphologic scoring system (Mainz Score) for the assessment of ovarian tumors using transvaginal ultrasonography. Part I: A comparison between the scoring-system and the assessment by an experienced sonographer. *Ultraschall Med*, **19**, 99-107.
- Piver MS (1996). Prophylactic oophorectomy: reducing the US death rate from epithelial ovarian cancer. A continuing debate. *The Oncologist*, **1**, 326–30.
- Sassone AM, Timor-Tritsch IE, Artner A, Westhoff C, Warren WB (1991). Transvaginal ultrasonographic characterization of ovarian disease: Evaluation of a new scoring system to predict ovarian malignancy. *Obstet Gynecol*, **78**, 70-6.
- Wanapirak C, Nimitwongsakul S, Tongsong T (2001). Sonographic morphology scores (SMS) for differentiation between benign and malignant ovarian tumors. *J Med Assoc Thai*, **84**, 30-5.
- Weber G, Merz E, Bahlmann F, Leber AM (1999). A new sonomorphologic scoring-system (Mainz score) for the assessment of ovarian tumors using transvaginal ultrasonography. Part II: A comparison between the scoring-system and the assessment by an experienced sonographer in postmenopausal women. *Ultraschall Med*, **20**, 2-8.