

## RESEARCH COMMUNICATION

# Expression of Cyclooxygenase-1 in Epithelial Ovarian Cancer: A Clinicopathological Study

Jakkapan Khunnarong<sup>1\*</sup>, Siriwan Tangjitgamol<sup>2</sup>, Sumonmal Manusirivithaya<sup>1</sup>, Pacheun Suekwattana<sup>1</sup>, Surawute Leelahakorn<sup>1</sup>

### Abstract

**Objective:** To determine immunohistochemical expression of cyclooxygenase-1 (COX-1) in epithelial ovarian cancer (EOC), and its association with clinical features and prognosis. **Methods:** EOC patients treated in Bangkok Metropolitan Administration Medical College and Vajira Hospital during 1996-2003, and with available pathological tissue sections, were identified. Immunohistochemical staining was accomplished with antibodies to COX-1 and degree of expression was categorized into low and high for assessment of any association with clinicopathological factors and survival. **Results:** One-hundred and seven patients were included in the study, with a median age of 50 years. Most had stage I and III disease. The most common histologic subtype was serous carcinoma. Overall, we found COX-1 expression in 83.2 %. Non-mucinous lesions had significant higher levels of expression than mucinous tumors, but there was no link expression with other clinicopathological factors or survival. **Conclusions:** EOCs showed high expression of COX-1, especially with a non-mucinous histology, but this appears to lack prognostic significance.

**Key Words:** Cyclooxygenase 1 - epithelial ovarian cancer - clinicopathological factors

*Asian Pacific J Cancer Prev*, 9, 757-762

### Introduction

Ovarian cancer is the sixth most common cancer and the seventh cause of death in women worldwide (Parkin et al., 2002). The incidence rates are highest among developed countries, with rates exceeding 9 per 100,000 per year. In the United States, it is the second most common gynecologic malignancy after endometrial cancer and is the fifth leading cause of female cancer deaths. In 2006, 20,180 new cases and 15,310 deaths from ovarian cancer are expected (Jemal et al., 2006). One explanation for the high mortality rate is an absence of any cost-effective screening strategy for detection of early stage disease (NIH Consensus Development Panel on Ovarian Cancer., 1995).

Approximately 85% of ovarian cancers arise from common surface epithelium, so called epithelial ovarian cancer (EOC) (Auersperg et al., 2001). The provoking mechanism or etiology of EOC is not fully understood, although many theories have been proposed (Whittemore, 1994). One factor might be inflammation (Ness and Cottreau, 1999), for example caused by talc or asbestos exposure, endometriosis, or pelvic diseases (Ness et al., 2000). One intrinsic factor is ovulation. The importance of inflammation/ovulation induced EOC is suggested by an observed risk reduction in women with the decrease in total number of lifetime ovulation due to child bearing or use of oral contraceptive pills (Riman et al., 2004).

Cyclooxygenase (COX) is an enzyme prostaglandin-endoperoxidase synthase which is a key enzyme in a metabolism of membrane-derived arachidonic acid to prostaglandins and other eicosanoids (Vane et al., 1998). Data from animal studies showed that COX plays many important roles in ovulation, fertilization, implantation, and ovarian function (Crofford, 1997; Davis et al, 1999), with possible involvement in establishment and maintenance of cancers (Gupta et al., 2003; Daikoku et al., 2005). There are two iso-forms of COX, COX-1 and COX-2. The association of the latter with carcinogenesis is the better recognized in gastric, lung, colon, breast, and head and neck cancers (Ristimaki et al., 1997; Hwang et al., 1998; Tsujii et al., 1998; Wolff et al., 1998; Zimmermann et al., 1999) and a few in EOC (Koki and Masferrer, 2002; Gasparini et al., 2003). The association of COX-2 with various clinicopathological factors were also reported (Denkert et al., 2002; Seo et al., 2004). The role of COX-1 in ovarian cancer is not clear with fewer numbers of studies. A few recent studies found higher degree of expression of COX-1 rather than COX-2 in EOC, and the authors proposed a possible role of COX-1 inhibitor in EOC prevention and treatment (Gupta et al., 2003; Daikoku et al., 2005).

The objective of the present study was to determine the immunohistochemical (IHC) expression of COX-1 in EOC and their association with clinicopathological characteristic features and outcomes.

<sup>1</sup>Department of Obstetrics and Gynecology, <sup>2</sup>Department of Anatomical Pathology, Bangkok Metropolitan Medical College and Vajira Hospital, Samsen Road, Dusit District, Bangkok 10300, Thailand \*For correspondence: jak020@hotmail.com

## Materials and Methods

The study was conducted after an approval from the Ethics Committee of the institution. We searched the archives of the Department of Pathology and of the Gynecologic Oncology Unit, Department of Obstetrics and Gynecology and Department of Anatomical Pathology of Bangkok Metropolitan Administration Medical College and Vajira Hospital to identify patients with EOC who were operated at the institution between January 1996 and December 2003. Inclusion criteria were: patients with EOC who had primary surgery with available pathological tissue blocks, and had follow-up data in the institution. Exclusion criteria were the patients who had borderline epithelial tumor, patients whose medical records were not available, or those cases with inadequate tumor tissue for an IHC pathological processing. Samples of formalin-fixed, paraffin-embedded tissue of patients were identified and retrieved. Clinical data abstracted from the patients' record included: age, menopausal status, FIGO stage, type of primary surgery and its outcome, primary adjuvant chemotherapy and its responses, and the date of last visit or death. Type of primary surgery was categorized as complete when total hysterectomy and bilateral salpingo-oophorectomy with or without lymph node sampling were performed, or else it would be classified as incomplete. The result of surgery was defined as optimal when the maximal dimension of residual disease was < 2 cm.

### *Immunohistochemical study*

Hematoxylin-and-eosin-stained slides of the tumors were reviewed in all cases by one author (S.T.) in order to confirm a pathologic diagnosis of histology and tumor grade, and to select an appropriate tumor area for an immunohistochemistry study. Immunoperoxidase staining was performed on 5-mm sections of formalin-fixed, paraffin-embedded tissue section. In brief, the paraffin-embedded sections were mounted on slides and dried with a microwave for 15 minutes. The tissues were deparaffinized and rehydrated with xylene and ethanol, blocked endogenous peroxidase with 3% H<sub>2</sub>O<sub>2</sub> for 20 minutes. The sections were pretreated with citrate buffer, pH 6.0 in a microwave for 13 minutes and incubated in protein blocking solution (Thermo, Shandon Immuno, USA) for 10 minutes. All slides were incubated with a 1:40 dilution of primary anti-COX-1 (Novocastra, Newcastle, UK) for 120 minutes with in room temperature followed by secondary antibody (Envision kit, Novocastra, Newcastle, UK) for 30 minutes, and finally with diaminobenzidine for 6 minutes. All samples were counterstained with Mayer's hematoxylin for 2 minutes and mounted in coated glass. Positive staining was controlled by immunostaining of kidney tissue and a negative control was performed in the same tissue without primary antibody.

Expression of IHC staining slides was interpreted independently by two authors (J.K., S.T.), who were blinded to the clinical information, under a transmission light microscope. Granular cytoplasmic staining in the tumor cells were considered as positive. The area (or extent) and the intensity of the immunostaining were

assessed in a semiquantitative fashion: the area of immunostaining was rated as 0 to 4 (0 = 0-5%; 1 = >5-25%; 2 = >25-50%; 3 = >50-75%; 4 = >75-100%)<sup>24</sup>. The area of staining was then categorized into two groups of low and high levels of expression; low level if staining area < 50% and high level with the staining area was > 50%. The intensity of immunostaining was rated as 0-4 (0 = negative; 1+ = weak; 2+ = intermediate; 3+ = strong; 4+ = very strong). Positive result was defined as area of immunostaining of >5% and intensity of staining was > 1+.

Inter-observer and intra-observer reliability were primarily studied in the first 30 cases by the two authors (J.K., S.T.). Total agreements for positive and negative results were 93.3%-96.7% (Kappa value of 0.82-0.92). While these values for the low and high levels of expression were 93.3%-100.0% (Kappa value of 0.86-1.00). The criteria for interpretation of IHC staining of COX-1 were then thoroughly refined between the two authors before proceeding further. Inter-observer reliability of the results from all 107 EOC cases were then analyzed again after a study of all IHC sections were done. Total agreements for positive and negative results were 95.3% (Kappa value of 0.83). While the total agreement for low and high level of IHC expression was 92.6% (Kappa value of 0.85). Finally, 5 cases with discordant results would be studied together and were discussed to reach consensus on the results.

### *Statistical Analysis*

The relationship between the expression of COX-1 and the clinical factors of age, menopausal status, residual disease after surgery, tumor grade, FIGO stage, response to first-line chemotherapy, and overall survival were studied. Responses were determined by means of physical examinations, CA125 tests, or radiologic imaging according to World Health Organisation (WHO) criteria (Mantel, 1996).

Overall survival (OS) was defined as the time from the date of diagnosis to date of death from cancer. For the patients who were still alive at the time of the study or death from other causes, overall survival-time were right-censored at the date of last follow-up visit. Progression-free survival (PFS) was defined as interval from the last date of treatment to the time of recurrence or progression of disease. For the patients who were lost to follow-up, PFS data were right-censored at the time of the last evaluation or contact when the patient was known to be progression-free.

Data were analyzed with parametric and nonparametric statistics using SPSS statistical software, version 11.5 (SPSS, Chicago, IL). Descriptive statistics were used to analyze demographic data and were summarized as mean with standard deviation or median with range. Association between antigens expression and clinical data were compared by Chi square or Fisher's exact test as appropriate. Survival and progression-free survival of each group were analyzed by the Kaplan-Meier method and were compared between groups with log rank test. P values of <0.05 were considered statistically significant.

**Results**

During the study period, 124 patients who underwent primary surgical treatment for EOC in our institution between January 1996 and December 2003 were identified. Amongst these, 14 patients had incomplete clinical data, while three cases had inadequate tumor tissue for an IHC pathological processing. Overall, 107 cases met all diagnostic criteria and were included in the study. Median age of the patients was 50 years (range 24-84). One hundred and one patients (94.4%) had complete primary surgery. Ninety one patients (85.0%) had optimal surgery; 56 patients (52.3%) had no gross residual disease. The two most common histologic types were serous and mucinous carcinomas, 29.9% and 23.4%, respectively. Approximately half of the patients had grade 3 tumors. Most of them had stage I and stage III diseases, 43.9% and 41.1%, respectively. Adjuvant chemotherapy was given in 88 patients (82.2%). Duration of follow-up of all patients ranged from 1-113 months. From 107 patients, 56 patients (52.3%) had progressive diseases during adjuvant chemotherapy or had recurrence diseases afterwards. At the time of study, 48/107 patients (44.9%) were dead of disease. Among the patients who were alive at the time of study, the median follow-up time was 55 months (range, 1-113 months). Overall, the median PFS of patients was 35 month (95% confidence interval [CI], 7-63 months) while median OS was 63 months with 5-year survival of 50.8% (95% CI, 40.5-61.1%). General characteristics of the patients and their diseases are shown in Table 1.

*Immunohistochemical staining of COX-1*

From 107 EOC cases, 89 cases (83.2%) had positive

**Table 1. Clinicopathological Features of the Epithelial Ovarian Cancer Cases**

Characteristic	N (%)
Age; year, median (range)	50 (24-84)
Menopausal status	
premenopausal	51 (47.7)
postmenopausal	56 (52.3)
Result of surgery	
complete	101 (94.4)
incomplete	6 (5.6)
Residual tumor	
none	56 (52.3)
< 2 cm	35 (32.7)
> 2 cm	16 (15.0)
Histology	
serous	32 (29.9)
mucinous	25 (23.4)
endometrioid	16 (15.0)
clear cell	14 (13.1)
adenocarcinoma, nos	12 (11.2)
mixed epithelium	7 (6.5)
adenosquamous	1 (0.9)
Grade	
G1	18 (16.9)
G2	35 (32.7)
G3	54 (50.4)
FIGO Staging	
stage I	47 (43.9)
stage II	7 (6.5)
stage III	44 (41.1)
stage IV	9 (8.4)
Adjuvant chemotherapy	
yes	19 (17.8)
no	88 (82.2)
<b>Total</b>	<b>107 (100)</b>

**Table 2. Clinicopathological Characteristics with Reference to Area of COX-1 Expression**

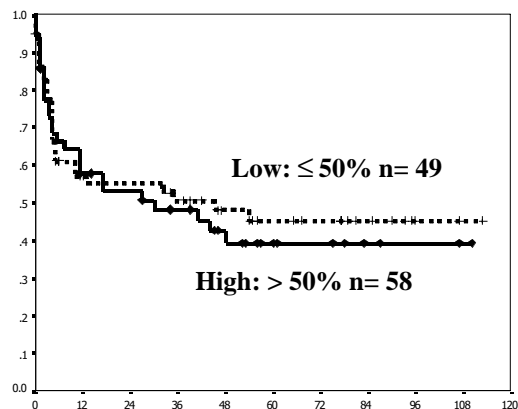
Characteristic	N	COX-1 expression		p value
		< 50%	>50%	
Age				
< 60	79	38 (48.1)	41 (51.9)	
≥ 60	28	11 (39.3)	17 (60.7)	0.42
Menopausal status				
premenopausal	51	21 (41.2)	30 (58.8)	
postmenopause	56	28 (50.0)	28 (50.0)	0.36
Residual tumor				
none	56	26 (46.4)	30 (53.6)	
present	51	23 (45.1)	28 (54.9)	0.89
Histology				
mucinous	25	16 (64.0)	9 (36.0)	
non-mucinous	82	33 (40.2)	49 (59.8)	0.04
Tumor grade				
G1-2	53	25 (47.2)	28 (52.8)	
G3	54	24 (44.4)	30 (55.6)	0.78
FIGO Staging				
I-II	54	25 (46.3)	29 (53.7)	
III-IV	53	24 (45.3)	29 (54.7)	0.92

Data are n (%)

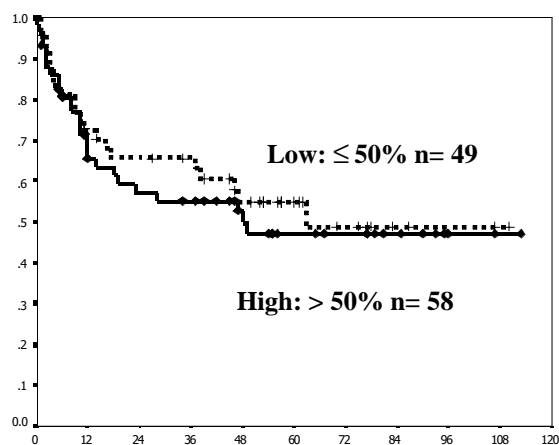
area of COX-1 expression; 58 of which (54.2%) had positive area > 50 %. We then studied these association according to the degree or level of low versus high COX-1 expression (Table 2). There was no significant association between the degree of COX-1 expression and the clinicopathological factors of age, menopausal status, residual disease, FIGO staging, and tumor grade. Only the factor of tumor histology showed different degree of COX-1 expression; significant lesser numbers of mucinous tumors showed high levels of immunostaining than non-mucinous tumors (p=0.04). Regarding the response to first-line chemotherapy, the patients whose tumors showed high levels of COX-1 IHC expression had overall response rates of 64.0% compared to 60.5% of those whose tumors had low levels of expression (p=0.74).

*Survival analysis*

To study the association of COX-1 immunoexpression and survival, Kaplan-Meier survival analyses were carried out; the results are shown in Figure 1 for PFS and Figure 2 for OS. Low level of COX-1 tended to associate with longer PFS, median of 45 months and 30 months in low and high level of expression, respectively. However, the difference was not statistical significant. Similar to the association with PFS, low COX-1 expression was associated with better both 2-year and 5-year survivals



**Figure 1. Association between COX-1 Immunostaining and Progression-free Survival.** Low COX-1 expression cases showed longer PFS, but without statistical significance



**Figure 2. Association between COX-1 Immunostaining and Overall Survival.** Low COX-1 expression was associated with better both 2-year and 5-year survivals than high expression

than those with high level of expression: 2-year survival rate was 65.5% (95% CI, 51.8-79.2%) compared to 57.3% (95% CI, 43.9-70.7%) and 5-year survival rate of 54.9% (95% CI, 39.9-69.9%) compared to 47.0% (95% CI, 32.7-61.3%) respectively. Again, these differences had no statistical significance.

## Discussion

Because of the less than satisfactory result in the treatment of EOC, more knowledge about ovarian carcinogenesis is certainly needed. Gupta et al (2003) studied COX-1 expression in EOC by several methods of RNA isolation and Northern Blot analysis, Western Blot analysis, In Situ hybridization, and IHC. The authors reported correlation among the four former methods and IHC, with over-expression of COX-1 of EOC compared to normal ovarian tissue. High expression was found in regions with high level of vascular endothelial growth factors and prominent angiogenesis. From these findings, they proposed the theory that COX-1 may contribute to ovarian carcinogenesis. This hypothesis was supported by other studies (Daikoku et al., 2005; Kino et al., 2005; Urlick and Johnson, 2006). Kino et al (2005) reported significant increases of COX-1 by mRNA polymerase chain reaction in EOC compared to normal ovarian tissues. Urlick and Johnson (2006) reported similar results of COX-1 overexpression from mRNA polymerase chain reaction and IHC study. The other preclinical study by Daikoku et al (2005) studied the activity of selective COX-1 inhibitor in EOC cell lines with COX-1 expression, and found that the substance could reduce tumor growth by attenuation of cellular proliferation and promotion of apoptosis. With these preclinical data, the role of COX-1 inhibitor in EOC prevention and therapeutic strategies are of interest. Before reaching the phase of clinical implementation, more basic knowledge and clinical evidences on the expression of COX-1 markers in EOC are crucial.

In this study, we demonstrated 83.2% COX-1 expression in our patients with EOC. This figure was slightly higher than previous studies which reported COX-

1 expression in approximately 69-75% (Denkert et al., 2002; Li et al., 2004). The discrepancies may depend on difference in subject materials, methods being used, or different criteria set for a positive result. Denkert et al (2002) roughly defined positive staining of COX-1 when there was either diffuse area of staining or focal expression in several cell clusters while Li et al (2004) used a "quickscore" which was obtained from a multiplication the area and intensity of expression of positive staining. We defined positive result when the area of marker expression was >5% and the intensity must be > 1, to exclude those non-specific or equivocal stainings.

To date, there have been only a few studies reported the association between expression of COX-1 and clinicopathological factors (Denkert et al., 2002; Li et al., 2004). The two studies of Denkert et al.21 and Li et al.28 reported no significant correlation between COX-1 expression and various clinicopathological factors of age, stage, histology, and tumor grade. In this study, we could not either demonstrate any association between age, FIGO stage, tumor grade, and residual tumor after primary surgery. Only histologic subtype of tumors showed significant association with COX-1 expression; mucinous tumors showed significant low level of COX-1 expression than non-mucinous tumors, 64.0% compared to 40.2% respectively (p=0.04). The difference may be due to the differential proportion of mucinous histologic subtype in each study. Only 5/137 tumors (3.6%) in study of Li et al.28 were mucinous tumor while 25/107 tumors (23.4%) in our study were mucinous. The small number of this histologic subgroup in their study might limit the detection of significant difference. Another study of Denkert et al.2002 categorized tumor histology as three subtypes of serous, undifferentiated, and non-serous tumors. They could not identify any significant association of these histologic subgroups and COX-1 expression. We tried to subgroup tumor histology to serous and non-serous type as in Denkert's study, and could not identify any significant association to be clinical useful either (data not shown).

The survival outcome of EOC patients in our study was similar to other previous studies which reported overall 5-year survival rates ranging from 25-60% (Jemal et al., 2006; van Houwelingen et al., 1989; Pecorelli et al., 1998). The overall 5-year survival rate of our EOC patients was 50.8% (95% CI, 40.5%-61.1%). We studied degree of COX-1 expression and survival outcomes but found inconclusive result. Our patients with high level of COX-1 expression had shorter PFS and OS than those of the patients with low level of expression, but the differences did not reach statistical significance. This may be due to the small number of our patients to detect any statistical significance (p=0.17 for PFS and p=0.23 for OS). Compare to the study of Denkert et al. which was the only study which reported on COX-1 expression and survival, they could not either demonstrate any significant association of COX-1 expression and median survival (2002). Of note, despite the inconclusive result in both studies of ours and Denkert's, the results were in the opposite direction. Their patients with positive expression

had longer median survival than that of the negative expression. Again, many differences between the two studies were observed: IHC techniques; criteria of interpretation for positive result, and low versus high level of expression as mentioned earlier; and the characteristics of patients and diseases such as more number of our patients had stage I disease, grade 3 tumor, and less number of serous tumors than those corresponding features in their study. We could not confidently conclude whether these discrepancies were the only reason for the difference in COX-1 expression and clinical outcomes until more number of studies would support either finding.

As mentioned earlier about the impact of COX-1 in EOC carcinogenesis, data of the marker expression would be important before a clinical implementation for target therapy for the prevention and treatment of EOC. Although our study could not show significant association between the level of COX-1 expression and clinicopathological features and outcomes, more number of studies with more patients as well as other methods to identify COX-1 expression in EOC is warranted because of the availability and the lower cost of COX-1 inhibitor agent than the chemotherapeutic agents.

Our study showed high rate of COX-1 expression in epithelial ovarian cancer, especially in non-mucinous tumors. No significant association of COX-1 expression and any of the clinicopathologic factors were found. The prognostic role of COX-1 to determine survival outcomes could not be demonstrated in our study, with no significant differences in progression-free survival and overall survival between those patients whose tumors showed high or low level of COX-1 expression.

## Acknowledgements

This work was supported by Bangkok Metropolitan Administration Research Fund. We thank technicians of department of anatomical pathology for their expert technical assistance.

## References

Auersperg N, Wong AS, Choi KC, Kang SK, Leung PC (2001). Ovarian surface epithelium: biology, endocrinology, and pathology. *Endocr Rev*, **22**, 255-88.

Barnes NL, Boland GP, Davenport A, Knox WF, Bundred NJ (2005). Relationship between hormone receptor status and tumour size, grade and comedo necrosis in ductal carcinoma in situ. *Br J Surg*, **92**, 429-34.

Crofford LJ (1997). COX-1 and COX-2 tissue expression: implications and predictions. *J Rheumatol*, **24** (Suppl 49), 15-9.

Davis BJ, Lennard DE, Lee CA (1999). Anovulation in cyclooxygenase-2 deficiency mice is restored by prostaglandin E2 and interleukin 1b. *Endocrinology*, **140**, 2685-95.

Daikoku T, Wang D, Tranguch S, et al (2005). Cyclooxygenase-1 is a potential target for prevention and treatment of ovarian epithelial cancer. *Cancer Res*, **65**, 3735-44.

Denkert C, Kobel M, Pest S, et al (2002). Expression of cyclooxygenase 2 is an independent prognostic factor in human ovarian carcinoma. *Am J Pathol*, **160**, 893-903.

Gasparini G, Longo R, Sarmiento R, Morabito A (2003). Inhibitors of cyclo-oxygenase 2: a new class of anticancer agents? *Lancet Oncol*, **4**, 605-15.

Gupta RA, Tejada LV, Tong BJ, et al (2003). Cyclooxygenase-1 is overexpressed and promotes angiogenic growth factor production in ovarian cancer. *Cancer Res*, **63**, 906-11.

Hwang D, Scollard D, Byrne J (1998). Expression of cyclooxygenase-1 and cyclooxygenase-2 in human breast cancer. *J Natl Cancer Inst*, **90**, 455-60.

Jemal A, Siegel R, Ward E, et al (2006). Cancer statistics, 2006. *CA Cancer J Clin*, **56**, 106-30.

Kino Y, Kojima F, Kiguchi K, et al (2005). Prostaglandin E2 production in ovarian cancer cell lines is regulated by cyclooxygenase-1, not cyclooxygenase-2. *Prostaglandins Leukot Essent Fatty Acids*, **73**, 103-11.

Koki AT, Masferrer JL (2002). Celecoxib: a specific COX-2 inhibitor with anticancer properties. *Cancer Control*, **9** (2 Suppl), 28-35.

Li S, Miner K, Fannin R, Barrett JC, Davis BJ (2004). Cyclooxygenase-1 and 2 in normal and malignant human ovarian epithelium. *Gynecol Oncol*, **92**, 622-7.

Mantel N (1996). Evaluation of survival data and two new rank order statistics arising in its consideration. *Cancer Chemother Rep*, **50**, 163-70.

Ness RB, Cottreau C (1999). Possible role of ovarian epithelial inflammation in ovarian cancer. *J Natl Cancer Inst*, **91**, 1459-67.

Ness RB, Grisso JA, Cottreau C, et al (2000). Factors related to inflammation of the ovarian epithelium and risk of ovarian cancer. *Epidemiology*, **11**, 111-7.

NIH Consensus Development Panel on Ovarian Cancer (1995). NIH consensus conference. Ovarian cancer. Screening, treatment, and follow-up. *JAMA*, **273**, 491-7.

Parkin DM, Bray F, Ferlay J, Pisani P (2005). Global cancer statistics, 2002. *CA Cancer J Clin*, **55**, 74-108.

Pecorelli S, Odicino F, Maisonneuve P (1998). Carcinoma of ovary. Annual report on the results of treatment of gynaecologic cancer, vol 23. International Federation of Gynecology and Obstetrics. *J Epidemiol Biostat*, **3**, 75-102.

Riman T, Nilsson S, Persson IR (2004). Review of epidemiological evidence for reproductive and hormonal factors in relation to the risk of epithelial ovarian malignancies. *Acta Obstet Gynecol Scand*, **83**, 783-95.

Ristimaki A, Honkanen N, Jankata H (1997). Expression of cyclooxygenase-2 in human gastric carcinoma. *Cancer Res*, **57**, 1276-80.

Seo SS, Song YS, Kang D, et al (2004). Expression of cyclooxygenase-2 in association with clinicopathological prognostic factors and molecular marker in epithelial ovarian cancer. *Gynecol Oncol*, **92**, 927-35.

Tsuji M, Kawano S, Tsuji S (1998). Cyclooxygenase regulates angiogenesis induced by colon cancer cells. *Cell*, **93**, 705-16.

Urick ME, Johnson PA (2006). Cyclooxygenase 1 and 2 mRNA and protein expression in the *Gallus domesticus* model of ovarian cancer. *Gynecol Oncol*, **103**, 673-8.

Vane JR, Bakhle YS, Botting RM (1998). Cyclooxygenases 1 and 2. *Annu Rev Pharmacol Toxicol*, **38**, 97-120.

van Houwelingen JC, ten Bokkel Huinink WW, van der Burg ATM (1989). Predictability of the survival of patients with ovarian cancer. *J Clin Oncol*, **7**, 769-73.

Whittemore AS (1994). Characteristics relating to ovarian cancer risk: implications for prevention and detection. *Gynecol Oncol*, **55**, S15-9.

Wolff H, Saukkonen K, Anttila S (1998). Expression of cyclooxygenase-2 in human lung carcinoma. *Cancer Res*, **58**, 4997-5001.

Zimmermann KC, Sarbia M, Weber AA (1999).  
Cyclooxygenase-2 expression in human esophageal  
carcinoma. *Cancer Res*, **59**, 198-204.