

## RESEARCH COMMUNICATION

# Fine Needle Aspiration Biopsy, Core Needle Biopsy or Excision Biopsy to Diagnose Breast Cancer - Which is the Ideal Method?

Teck-Meng Tham<sup>1</sup>, Krishnan Rangaswamy Iyengar<sup>2</sup>, Nur Aishah Taib<sup>1</sup>, Cheng-Har Yip\*<sup>1</sup>

### Abstract

**Background:** The ideal method for diagnosis of breast cancer is debatable. **Methods:** The methods of diagnosis of 436 new cases of breast adenocarcinoma presenting from Jan 2005 till Dec 2006 at the University Malaya Medical Centre (UMMC) were examined in this study. **Results:** A total of 388 cases presented to the breast unit in UMMC primarily and 48 cases were diagnosed in non-breast units in other hospitals and referred for management. Fine needle aspiration cytology (FNAC) was the commonest mode of initial diagnosis in 278 cases followed by core needle biopsy and surgical excision. In UMMC, FNAC was the commonest initial method (68.3%) compared to cases diagnosed outside UMMC, where 37.5% of cases were diagnosed by excision. Tumours less than 2cm were more likely to be diagnosed by excision biopsy. **Conclusion:** The biopsy method used to confirm the diagnosis is influenced by where the patient first presents, and by the size of the tumour.

**Key Words:** Breast cancer - fine needle aspiration cytology - core needle biopsy - excision biopsy

*Asian Pacific J Cancer Prev*, 10, 155-158

### Introduction

Breast cancer is the commonest cancer in Malaysian women. (Yip et al., 2006). Hence breast cancer management consumes a huge portion of the nation's healthcare resources. An effective, accurate and cost effective method of breast cancer diagnosis will help to reduce the patient's morbidity and mortality, and to reduce costs as well.

Fine needle aspiration cytology (FNAC) is a relevant and important diagnostic method in the management of breast cancer. It has high sensitivity and specificity in determining the pathology of breast lumps (Furnival et al., 1975; Nicosia et al, 1993; Ballo & Sneige, 1996; Yeoh & Chan, 1998; Chaiwun et al, 2002). Most of these studies were done in conjunction with triple assessment which includes clinical assessment, and radiological and cytological findings besides biopsy (Lau et al, 2004; Medina-Franco et al, 2005; Shyyan et al, 2006; Chaiwun & Thorner, 2007).

Core needle biopsy (CNB) is increasingly replacing FNAC in many centres in developed countries (Ballo & Sneige, 1996; Pilgrim & Ravichandran, 2005) and this is mainly attributed to the inability of FNAC to distinguish carcinoma in-situ from invasive carcinoma (Litherland, 2002). In addition, the lack of experienced cytopathologists at individual centres, leading to more diagnostic errors and higher number of insufficient samples also play a role (Wells et al, 1999).

The main objective of this study is to look into the methods of pathological diagnosis for breast cancers in University Malaya Medical Centre (UMMC), and to determine whether the current practice is adequate for the management of breast cancer.

### Materials and Methods

This is a two- year retrospective study done in UMMC, Kuala Lumpur from Jan 2005 till Dec 2006. FNAC was performed with a 21G or 22G needle that was attached to a 10cc or 20cc syringe mounted on an aspirator (Cameco). The palpable lesion was immobilized and the needle inserted into the lesion. Multidirectional sampling was done by moving the needle back and forth. Negative pressure was applied during this time and released prior to removing the needle. At least 3 passes were made. The sample obtained was ejaculated onto a glass slide and smeared. At least 4 slides were prepared. 2 slides were air-dried and 2 were fixed with 95% alcohol. The air-dried smears were stained rapidly with Diff-Quik® stain and adequacy of aspiration assessed by a cytopathologist. If inadequate, the FNAC procedure was repeated. These 2 slides were then restained with May Grünwald-Giemsa stain, while the alcohol-fixed slides were stained with Papanicolaou stain in the cytopathology laboratory..

Core needle biopsies (CNB) were carried out with a 14 gauge needle with a 23mm throw that is mounted on an automatic spring loaded gun (Magnum). Lignocaine

<sup>1</sup>Dept of Surgery and <sup>2</sup>Dept of Pathology, University Malaya Medical Centre, Kuala Lumpur, Malaysia \*For correspondence: yipch@um.edu.my

1% was used as local anaesthesia to reduce discomfort. A small skin nick was made with size 12 scalpel and needle introduced through the wound. At least 2 good strips of tissue were taken. Non-palpable and very small lesions considered difficult to biopsy percutaneously were referred to the radiologist for selection of the most suitable method of image-guided biopsy i.e. FNAC or CNB, with the most appropriate guidance. Usually 2 passes of needle were made for FNAC and 2 strips of tissue obtained with CNB.

All biopsies taken were discussed at a weekly multidisciplinary team meeting and definitive diagnoses were reached with the agreement of all team members. If a definitive diagnosis could not be reached, a decision was made to repeat FNAC, CNB or open surgical excision biopsy. Excision biopsy was done either as an initial method of diagnosis, or after triple assessment was equivocal. Non-palpable lesions were subjected to biopsy using hook wire localization.

All cases were followed up until the ultimate pathological diagnosis was known. The mode of diagnosis was analyzed with regards to the place of diagnosis (UMMC or non-UMMC), size of the lesion and age of the patient. Chi-square test was used in the analysis. The reason for the initial choice of biopsy method (FNAC, CNB or Excision biopsy) was not recorded in this study. The cytopathology and/or histology was reported by different pathologists.

## Results

A total of 436 cases of malignant breast lesions were studied. 388 cases presented to the breast unit in UMMC for primary investigation, and 48 cases were diagnosed outside (non-UMMC) and later referred to our unit for subsequent definitive surgical treatment. The non-UMMC group were seen by general surgeons in private practice where there was no breast unit. All subjects involved were female. There were 5 subjects with bilateral breast carcinoma. Each of these lesions was investigated separately and each contributed as a case.

For those diagnosed in UMMC, the age at diagnosis ranged from 22 years old to 86 years old. The mean age was 54 years old. The size ranged from 2mm to 300mm, with a mean size of 41.7mm. Non-UMMC cases had a mean age of 52 years with a range from 30 to 76 years old, and the size ranged from 15mm to 180mm, with a mean size of 39mm. The majority of patients (42%) presented with a T2 tumour (2.1 to 5 cm) in UMMC. For the non-UMMC group, the majority of cases (56%) were T2 tumours (Table 1), with no significant difference between the two groups.

FNAC was the final method of biopsy in 242 lesions (55.5%), CNB in 112 lesions (25.7%) and surgical excision in 82 cases (18.8%) (Table 2).

FNAC was the initial biopsy method in 278 cases. It was accurate in 242 cases (accuracy rate of 87%). CNB diagnosed 104 out of 106 breast cancers (accuracy rate of 99%), while initial surgical excision diagnosed all the 52 lesions excised as the initial method of biopsy (accuracy rate 100%). For lesions that failed to be diagnosed with FNAC, 8 lesions were diagnosed by CNB while 28 went

**Table 1. Size of tumour**

Size	UMMC	Non-UMMC	Total
T1 ( $\leq 2$ cm)	136 (35%)	13 (27%)	149
T2 (2.1-5 cm)	162 (42%)	27 (56%)	189
T3 ( $>5$ cm)	90 (23%)	8 (17%)	98
Total	388 (100%)	48 (100%)	436

**Table 2. Initial and Final Method of Pathological Diagnosis**

Method	Initial			Final		
	UMMC	NonUMMC	Total	UMMC	Non-UMMC	Total
FNAC	265 (68)	13 (27)	278 (64)	231 (60)	11 (23)	242 (56)
CNB	89 (23)	17 (35)	106 (24)	95 (25)	17 (35)	112 (26)
Excision	34 (9)	18 (38)	52 (12)	62 (16)	20 (42)	82 (19)
Total	388(100)	48(100)	436(100)	388(100)	48(100)	436(100)

**Table 3. Correlation between Size of Lesion and Method of Diagnosis (P<0.05)**

	$\leq 2$ cm	$>2$ cm	Total
FNAC	66 (44.3%)	176 (61.3%)	242
CNB	34 (22.8%)	78 (27.2%)	112
Excision Biopsy	49 (32.9%)	33 (11.5%)	82
Total	149	287	436

on to have surgical excision. The only 2 cases which were missed by CNB had the cancer diagnosed by surgical excision.

In UMMC, FNAC was the commonest initial method (265 lesions, 68.3%) followed by CNB (89 lesions, 22.9%) and least common was excision biopsy (34 lesions, 8.8%). For breast cancers that were investigated and diagnosed in other hospitals, the commonest initial method of biopsy was the excision biopsy (18 lesions, 37.5%), followed by CNB (17 lesions, 35.4%). FNAC was the least common method of biopsy (13 lesions, 27.1%). The differences in the choice of method of pathological diagnosis between the UMMC and non-UMMC group was significant. ( $p < 0.05$ ) (Table 2). Correlation between tumor size and methods of pathological diagnosis showed that tumours 2 cm or less were more likely to be diagnosed by excision biopsy (32.9%) compared with tumours more than 2 cm. (11.5%) ( $p < 0.05$ ) (Table 3) However the method of biopsy had no correlation with the age of the patient ( $p > 0.05$ ).

## Discussion

### *The need for preoperative pathological diagnosis*

An early and accurate benign or malignant diagnosis for a breast lesion is important. It should be achieved preoperatively before embarking on any invasive surgical procedure (Shyyan et al, 2006) A reliable cytological or pathological diagnosis allows preoperative counseling of a patient with malignancy and aid in the planning of definitive surgery including management of the axilla for invasive lesions. This reduces a 2- stage procedure to a one stage definitive operation. It also allows the patient to "come to terms" with the entirety of her management plan and also reduce the cost of treatment. A definite diagnosis of a benign breast lesion will alleviate patient's

anxiety, although this does not mean that an excision biopsy is not necessary; however this will reduce the number of operations needed for those who do not have malignant disease. (Litherland, 2001; Litherland, 2002; Chuo & Corder, 2003)

It is the aim of the clinician to choose a method of pathological diagnosis with high sensitivity and specificity. In the actual clinical setting, this is difficult to come by. When a tool is too sensitive, it will produce a lot of false positive results and reduces specificity. False positive results can cause over-treatment and increase anxiety and morbidity to the patient. Fortunately false positives in breast biopsies are low. (Chaiwun & Thorner, 2007) Conversely, when it is too specific, sensitivity will drop with high rate of false negative. False negative results will cause delay in diagnosis and subsequent morbidity to patient.

#### *Mode of presentation of breast carcinoma*

In developed nations, breast carcinoma is detected via a breast screening program for asymptomatic women at an early stage, whereas women in developing nations often present with symptomatic breast lumps. This delay is mainly attributed to inadequacy of health care infrastructure and standards, sociocultural barriers, economical realities and illiteracy. (Agarwal et al, 2007)

In our study, most of the breast cancers presented to UMMC primarily with a palpable breast lumps. 94% of the lumps assessed had pathological size more than 1cm. The pathological mean size was 41.7mm. For breast cancers diagnosed outside and then referred to UMMC for further management, the pathological mean size of 39mm.

Our findings are consistent with other previous studies. In a study done in UMMC from 1993 to 2004 by Yip et al, a lump in a breast was the commonest presentation of breast carcinoma and this occurred in 90% of cases, and the lump was felt by the woman herself (Yip et al., 2006).

#### *FNAC in breast carcinoma*

In a previous study in UMMC, fine needle aspiration cytology was shown to have a sensitivity of 91.7% with a false negative rate of 11% (Yip et al., 2000) From the present 2-year data collection, FNAC was the initial investigation in 278 cases. The diagnostic accuracy of 87% in this study compares well to previous reported data. (Yip et al, 2000; Chaiwun et al, 2002). We found that FNAC is reliable in the diagnosis of breast cancer for symptomatic breast lumps, and it is quick, can be performed in an out patient clinic setting, with a low complication rate and high patient acceptance. These findings are also expressed by other authors (Ballo & Sneige, 1996; Yeoh & Chan, 1998; Chaiwun & Thorner, 2007; He et al., 2007).

#### *Changing from FNAC to CNB*

For the last 10 years, there is an evolution from the use of FNAC as a diagnostic tool of choice in breast lesion to the use of CNB (Ballo & Sneige, 1996; Chaiwun & Thorner, 2007). In comparison with FNAC, CNB is less operator dependent, does not require expertise in cytology

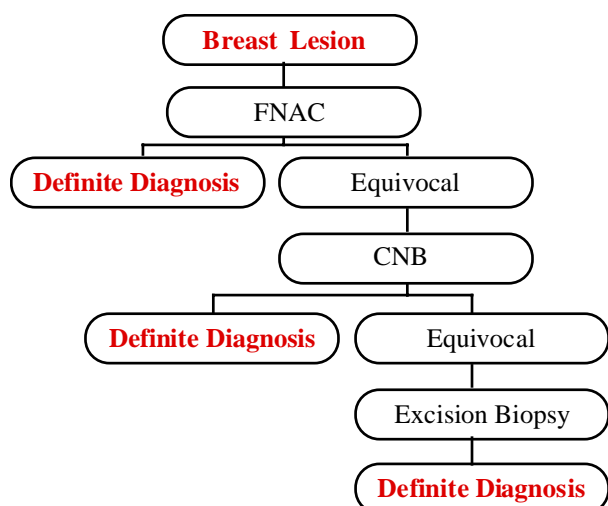
and diagnosis of microcalcification is improved, as specimen radiography is available to demonstrate the presence of suspected microcalcification. The introduction of 14G core biopsy needle and automated large core biopsy gun improves the diagnostic yield and make the procedure easier. (Litherland, 2001). CNB is reported to have a higher sensitivity and specificity compared with FNAC in some studies (Chuo & Corder, 2003; Pilgrim & Ravichandran, 2005), while others maintain the FNAC was more sensitive and more cost-effective than CNB (Ballo & Sneige, 1996). Each individual unit should make a decision which method is appropriate based on its audited results (Litherland, 2002). Fine needle aspiration continues to be an acceptable and reliable procedure for the preoperative diagnosis of breast lesions, particularly in developing countries, and when used as part of the 'triple test'. Clinicians should be mindful of the limitations of each technique and the choice between fine needle aspiration and core biopsy should be individualized for the patient. (Chaiwun & Thorner, 2007)

#### *Relevance of excision biopsy*

There are some lesions which are suspicious and cannot be determined preoperatively with non-invasive methods even with radiological guidance. Excision biopsy is the method of choice here. In equivocal cases, it is performed as a diagnostic as well as a definitive therapeutic procedure, i.e. formal cancer excision (Beitler et al, 1997) This is termed wide local excision with particular attention to surgical margins. Total excision with a clear margin eliminates the need of subsequent resection in case of malignancy. In some cases where a lesion is not palpable, especially screen detected lesions, hookwire localization under radiological guidance (stereotactic or ultrasound-guided) can be employed. If a specimen is removed for microcalcification, it can be radiographed to confirm accurate excision.

For cases diagnosed outside UMMC, more than one-third (37.5%) had the initial diagnosis of breast cancer made on excision biopsy, compared to only 8.8% with an initial diagnosis of breast cancer in UMMC. This is likely to be due to the unavailability of a preoperative non-invasive diagnostic service outside of a breast unit. FNAC needs a trained cytopathologist which is rarely available outside of tertiary healthcare centre. CNB utilizing an automated core needle biopsy set may not be available especially in small private institutions. In the private hospitals, breast lumps are managed by general surgeons, some of whom may not be well versed in the management of breast lumps and omit the importance of preoperative non-invasive pathological diagnosis. However this approach will subject the patient to another surgical trauma if it turns out to be malignant.

Excision biopsy is also more effective in small lumps which are 2 cm or less as FNAC and CNB, especially if performed free-hand may miss the lesion and a false negative result is obtained. The sensitivity of CNB increases with the size of the cancer, and approached 94% in lumps more than 2.5 cm. (Minkowitz et al, 1986) In small lumps, it is recommended that FNAC or CNB be performed under stereotactic or ultrasound guidance.



**Figure 1. Algorithm for Biopsy of Breast Lesions**

(Ballo & Sneige, 1996)

Open surgical excision biopsy remains the diagnostic “gold standard” to which other methods must be compared, with almost 100% sensitivity (Pruthi, 2001) However, compared to FNAC and CNB, excision biopsy is expensive and associated with a greater degree of patient morbidity. Open biopsy leaves a visible scar which is cosmetically undesirable and may complicate mammographic follow up. In addition, open biopsy is associated with a significantly longer “turn-around” time than that which accompany FNAC.

The “ideal” method of biopsy to diagnose breast cancer is debatable and should depend on the expertise available in the unit, as well as the physical characteristics of the lump. Fine needle aspiration cytology (FNAC) is a reliable and relevant method for the pathological diagnosis of breast carcinoma in a developing nation like Malaysia. It is highly useful as an initial method of pathological assessment for palpable breast lumps. If the initial FNAC is inadequate, core needle biopsy (CNB) can be a useful second line method of pathological diagnosis. Excision biopsy should be the last option to obtain a pathological diagnosis. This should be performed as a diagnostic as well as a therapeutic measure i.e. with a formal cancer excision (Figure 1). With small lumps, CNB or FNAC should ideally be performed under image guidance to improve sensitivity.

## References

- Agarwal G, Pradeep PV, Aggarwal V, Yip CH, Cheung PS (2007). Spectrum of breast cancer in Asian women. *World J Surg*, **31**, 1031-40.
- Ballo MS, Sneige N (1996). Can core needle biopsy replace fine-needle aspiration cytology in the diagnosis of palpable breast carcinoma. A comparative study of 124 women. *Cancer*, **78**, 773-7.
- Beitler AL, Hurd TC, Edge SB (1997). The evaluation of palpable breast masses: common pitfalls and management guidelines. *Surg Oncol*, **6**, 227-34.
- Chaiwun B, Settakorn J, Ya-In C, et al (2002). Effectiveness of fine-needle aspiration cytology of breast: analysis of 2,375 cases from northern Thailand. *Diagn Cytopathol*, **26**, 201-5.

- Chaiwun B, Thorner P (2007) Fine needle aspiration for evaluation of breast masses. *Curr Opin Obstet Gynecol*, **19**, 48-55.
- Chuo CB, Corder AP (2003). Core biopsy vs fine needle aspiration cytology in a symptomatic breast clinic. *Eur J Surg Oncol*, **29**, 374-8.
- Furnival CM, Hocking MA, Hughes HE, Reid MM, Blumgart LH (1975). Aspiration cytology in breast cancer. Its relevance to diagnosis. *Lancet*, **2**, 446-9
- He Q, Fan X, Yuan T, et al (2007). Eleven years of experience reveals that fine-needle aspiration cytology is still a useful method for preoperative diagnosis of breast carcinoma. *Breast*, **16**, 303-6.
- Lau SK, McKee GT, Weir MM, et al (2004). The negative predicative value of breast fine-needle aspiration biopsy: the Massachusetts General Hospital experience. *Breast J*, **10**, 487-91.
- Litherland J (2001) The role of needle biopsy in the diagnosis of breast lesions. *Breast*, **10**, 383-7.
- Litherland JC (2002). Should fine needle aspiration cytology in breast assessment be abandoned? *Clin Radiol*, **57**, 81-4.
- Medina-Franco H, Abarca-Perez L, Cortes-Gonzalez R, et al (2005). Fine needle aspiration biopsy of breast lesions: institutional experience. *Rev Invest Clin*, **57**, 394-8.
- Minkowitz S, Moskowitz R, Khafif RA, Alderete MN (1986). TRU-CUT needle biopsy of the breast. An analysis of its specificity and sensitivity. *Cancer*, **57**, 320-3
- Nicosia SV, Williams JA, Horowitz SA, et al (1993). Fine needle aspiration biopsy of palpable breast lesions. Review and statistical analysis of 1875 cases. *Surg Oncol*, **2**, 145-60.
- Pilgrim S, Ravichandran D (2005). Fine needle aspiration cytology as an adjunct to core biopsy in the assessment of symptomatic breast carcinoma. *Breast*, **14**, 411-4.
- Pruthi S (2001). Detection and evaluation of a palpable breast masses. *Mayo Clin Proc*, **76**, 641-7; quiz 647-8.
- Shyyan R, Masood S, Badwe RA, et al (2006). Breast cancer in limited-resource countries: diagnosis and pathology. *Breast J*, **12 Suppl 1**, S27-37
- Wells CA, Perera R, White FE, Domizio P (1999). Fine needle aspiration cytology in the UK breast screening programme: a national audit of results. *Breast*, **8**, 261-6.
- Yeoh GP, Chan KW (1998). Fine needle aspiration of breast masses: an analysis of 1,533 cases in private practice. *Hong Kong Med J*, **4**, 283-8.
- Yip CH, Jayaram G, Alhady SF (2000). The experience with fine needle aspiration cytology in the management of palpable breast lumps in the University Hospital Kuala Lumpur. *Med J Malaysia*, **55**, 363-7
- Yip CH, Taib NA, Mohamed I (2006) Epidemiology of breast cancer in Malaysia. *Asian Pac J Cancer Prev*, **7**, 369-74.