

RESEARCH COMMUNICATION

Comparing Visual Inspection with Acetic Acid Plus Random Cervical Biopsy Plus Endocervical Curettage to Colposcopic Directed Biopsy Plus Endocervical Curettage in Detecting Cervical Lesions in Low-resource Settings

Pongsun Puntachai^{1*}, Darigar Darojn¹, Bandit Chumworathayi², Wichian Chaousrikul¹

Abstract

Objective: To compare the sensitivity, specificity, positive and negative predictive values of visual inspection with acetic acid directed cervical biopsy (VDB) in combination with random cervical biopsy (VRB) and endocervical curettage (ECC) to colposcopic directed biopsy (CDB) plus ECC in detecting cervical lesions (HSIL or more) in Thailand. **Materials and Methods:** A diagnostic-test study was carried out on 164 women with abnormal Pap smear at a tertiary care teaching hospital from March 2011 to June 2011. The women with abnormal Pap smears had further investigations such as; VDB and/or VRB, and CDB plus ECC, and/or loop electrosurgical excision procedure (LEEP). Either VDB plus VRB plus ECC or CDB plus ECC, sometimes LEEP, were used to diagnose cervical lesions. Severest histopathology from any means was taken as the gold standard. **Results:** There were 158 patients included in analyses. The sensitivity of VDB plus VRB plus ECC to detect cervical lesions was 95.9% (95% CI, 91.4%-98.1%) compared to the sensitivity of CDB plus ECC of 97.3% (95% CI, 93.2%-98.9%). The two were very similar (mean difference -1.4%, 95% CI, -5.4%-2.6%, by Z-test). **Conclusions:** Thus VDB plus VRB plus ECC can substitute for CDB plus ECC in detecting cervical lesions in low-resource settings.

Keywords: Cervical cancer - early detection - VDB - VRB - CDB - ECC - LEEP - LSIL - HSIL - Thailand

Asian Pacific J Cancer Prev, 12, 2665-2668

Introduction

In Thailand, cervical cancer is the most common gynecologic cancer with the age-standardized incidence rate of 18.1 in 100,000 women and new-case number of more than 6,000 women per year (Khuhaprema et al., 2010). Papanicolaou (Pap) smear was standard method of screening cervical cancer. The developed countries had target women having Pap smear about 80% compared to Thailand whose target women having Pap smear in less than 30% because they had problems of transportation or finance. The women who have abnormal Pap smears should be referred to a specialist for colposcopy. Paradoxically, those problems caused the patients loss to follow-up. Are there any procedures we can do for them instead of colposcopy?

In 1982, Ottaviano and La Torre reported a procedure for detecting cervical lesion by using 3-5% acetic acid painted on cervical epithelium, at 1 minute after acetic

acid have coagulative reaction with intracellular protein, acetowhite lesion occurs and can be detected by naked-eyed visual examination at the squamocolumnar junction (SCJ). Then we called this procedure visual inspection with acetic acid or VIA (Ottaviano and La Torre, 1982; Lancet 1999). Since 2000, VIA has been used to detect cervical lesions (preinvasives and invasives) in Thailand. (RTCOC/Jhpiego, 2003) It has many advantages over Pap smear because this procedure has low cost, but high sensitivity, high cost-effectiveness, and does not need colposcopy to identify where the lesion is. In 2009, there was a study reporting that the procedure of colposcopic directed biopsy (CDB) plus random cervical biopsy (VRB) plus ECC should be used as the expanded gold standard in detecting CIN (Cagle et al., 2009), but unfortunately, this procedure can not be generally done in low-resource settings (Pakhee et al., 2010).

Until now, there has been no study reporting the sensitivity of VDB plus VRB plus ECC compared to that

¹Department of Obstetrics and Gynecology, Sappasithiprasong Hospital, Ubon Ratchathani, ²Division of Gynecologic Oncology, Department of Obstetrics and Gynecology, Faculty of Medicine, Srinagarind Hospital, Khon Kaen University, Khon Kaen, Thailand
*For correspondence: puntachai401@hotmail.com

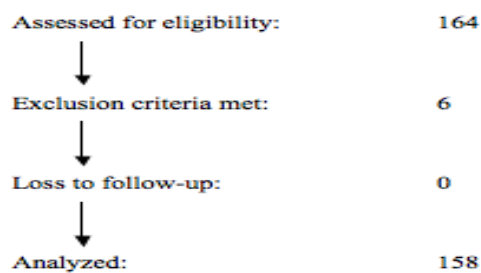


Figure 1. Flow of Study Participants

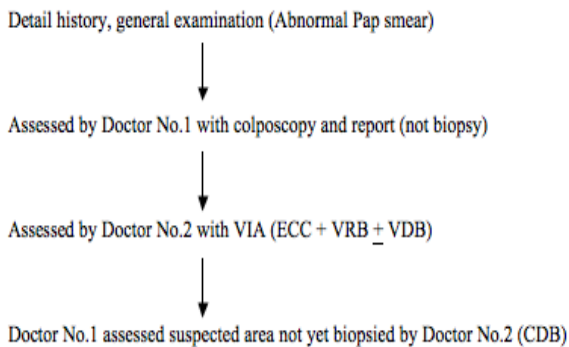


Figure 2. Conduct of the Study

of CDB plus ECC in detecting cervical lesions (HSIL or more) in low-resource settings. Therefore, this study was done to compare the sensitivity, specificity, and predictive values, to determine if the VDB plus VRB plus ECC can substitute the CDB plus ECC in low-resource settings.

Materials and Methods

The study was carried out in the outpatient department of a tertiary care hospital in Ubon Ratchathani, Thailand over a period of 4 months, March to June, 2011. The inclusion criteria were that a woman; 1) had abnormal Pap smear > ASC-US, 2) gave an informed consent. The exclusion criteria were that a woman; 1) had pregnancy, 2) had abnormal uterine bleeding, 3) had absent cervix, 4) had visible gross cervical lesion of suspected malignancy, 5) loss to follow up. The study was approved by the institutional ethics committee in human research.

The flow of study participants is shown in Figure 2 and the conduct of the study is as depicted in Figure 2.

For the study, prepared 5% acetic acid was used. Acetic acid was applied over the cervix, which was inspected after 1 minute using colposcopy by doctor No.1 (gynecologic oncologist). This doctor reported the result of colposcopic findings and planned sites of biopsy after doctor No.2 (general practitioner) finished VIA and biopsy (VDB or VRB). VIA was done by doctor No.2 after doctor No.1 finished and moved colposcopy out of area and both doctors did not discuss their findings to each other. If VIA negative, doctor No.2 would do random cervical biopsies (VRB) on the SCJ at 2, 4, 8, and 10 o'clock position plus ECC. If any lesions presented (VIA positive), doctor No.2 would do VDB plus ECC from any abnormal areas, in addition, VRB were also obtained where the quadrants did not appear to be any neoplastic abnormalities, in this step, doctor No.1 observed the points of doctor No.2 biopsies but no discussion was made and specimens were

Table 1. Characteristics of 158 patients

	Number of patient	Percent
Age (years-old)		
17-20	4	2.6
21-30	22	13.9
31-40	52	32.9
41-50	54	34.2
51-60	24	15.1
61-62	2	1.3
Occupation		
Farmer	89	56.3
Employee	24	15.2
Public servant	9	5.7
Housewife	18	11.4
Student	2	1.3
Others	16	10.1
Marital status		
Single	4	2.5
Married	145	91.8
Widow	6	3.8
Divorcee	3	1.9
Parity		
G0	9	5.7
G1	15	9.5
G2	44	27.8
G3	45	28.5
G4	25	15.8
Grandmultipara	20	12.7
Age of first SI (years-old)		
14-20	110	69.6
21-30	42	26.6
31-39	6	3.8

separated in each bag labeled ECC, VDB, VRB, (VDB & CDB), (VRB & CDB), for pathologist's reports. Next step, doctor No.1 assessed the cervical area again for CDB in site where doctor No.2 did not do biopsy. The patient to whom doctor No.1 suggested LEEP will be appointed again after 4 weeks and LEEP specimen was then sent to the pathologist.

For histology, each slide was read by the pathologist who was blinded from findings of study. A 10% of random samples of negative histology specimens were also sent for reading again to assess the level of agreement. Expanded gold standard of this study was the severest report of specimens from either VDB, VRB, ECC, CDB, or LEEP.

To determine the sensitivity, specificity, positive predictive value (PPV), and negative predictive value (NPV) between VDB plus VRB plus ECC and CDB plus ECC when both were compared to the expanded gold standard, statistical analyses were carried out using Statistical Package for the Social Sciences (SPSS) version 18. If the 95% confidence intervals (CI) of the sensitivity were found to be overlapped, mean difference and its 95% CI would be then calculated by Z-test.

Results

From March to June, 2011, there were 164 patients underwent outpatient department with abnormal Pap smear (> ASC-US) in Sappasithiprasong Hospital. Of these 164 patients, 6 patients were excluded, 158 patients were further investigated. Most of the patients were in

Table 2. Results of Pap Smear in 158 Patients

Results of Pap smear	Number of patient	Percent
ASC-US	47	29.7
ASC-H	3	1.9
LSIL	39	24.7
HSIL	50	31.6
SCCA	7	4.4
AGC-NOS	9	5.7
AGC-FN	2	1.3
AIS	1	0.6

Table 3. Results of Visual Inspection with Acetic Acid (VIA) in 158 Patients

	Number of patient	Percent
Visual inspection with acetic acid (VIA)		
Positive	127	80.4
Negative	31	19.6
Squamocolumnar junction		
Satisfactory	151	95.6
Unsatisfactory	7	4.4
Visual inspection with acetic acid directed cervical biopsy (VDB) In 127 patients		
Negative	26	20.5
CIN I	38	29.9
CIN II	24	18.9
CIN III	27	21.3
AIS/CIS	3	2.4
SCCA	9	7.1

Table 4. Results of VDB Plus VRB Plus ECC in 158 Patients

VDB plus VRB plus ECC	Number of patient	Percent
Negative	17	10.8
CIN I	61	38.6
CIN II	32	20.3
CIN III	31	19.6
AIS/CIS	5	3.2
SCCA	12	7.6

Table 5. Expanded Gold Standard Versus VDB Plus VRB Plus ECC in 158 Patients

	Expanded gold standard	
	Positive	Negative
VDB plus VRB plus ECC		
Positive	141	0
Negative	6	11
	Mean	95% CI
Sensitivity	95.9%	91.4-98.1
Specificity	100%	74.1-100
Positive predictive value	100%	97.3-100
Negative predictive value	64.7%	41.3-82.7

Table 6. Results of CDB Plus ECC in 158 Patients

VDB plus VRB plus ECC	Number of patient	Percent
Negative	15	9.5
CIN I	60	38
CIN II	30	19
CIN III	35	22.2
AIS/CIS	4	2.5
SCCA	14	8.9

Table 7. Expanded Gold Standard Versus CDB Plus ECC in 158 Patients

	Expanded gold standard	
	Positive	Negative
CDB plus ECC		
Positive	143	0
Negative	4	11
	Mean	95% CI
Sensitivity	97.3%	93.2-98.9
Specificity	100%	74.1-100
Positive predictive value	100%	97.4-100
Negative predictive value	73.3%	48.0-89.1

Table 8. Expanded Gold Standard Versus VDB in 127 Patients

	Expanded gold standard	
	Positive	Negative
VDB		
Positive	101	0
Negative	17	9
	Mean	95% CI
Sensitivity	85.6%	78.1-90.8
Specificity	100%	70.1-100
Positive predictive value	100%	96.3-100
Negative predictive value	73.3%	19.4-53.8

Table 9. Results of Expanded Gold Standard in 158 Patients

Expanded gold standard	Number of patient	Percent
Negative	11	7
CIN I	59	37.3
CIN II	27	17.1
CIN III	35	22.2
AIS/CIS	5	3.2
SCCA	20	12.7
Adenocarcinoma	1	0.6

the age of 17-62 (mean 40.8) years-old (Table 1). Table 2 showed the cytologic results of these 158 patients. The reports of VIA are shown in Table 3.

The pathological reports of VDB plus VRB plus ECC are shown in Table 4, corresponding to the expanded gold standard in 132 cases (83.5%), not corresponding to expanded gold standard in 26 cases (16.5%). The sensitivity, specificity, and predictive values, compared to the expanded gold standard, were shown in Table 5. The pathological reports of CDB plus ECC are shown in Table 6, corresponding to the expanded gold standard in 141 cases (89.2%), not corresponding to the expanded gold standard in 17 (10.8%). The sensitivity, specificity, and predictive values are shown in Table 7.

The sensitivity, specificity, and predictive values of VDB only, compared to the expanded gold standard, were shown in Table 8. LEEP was done in 76 patients (48.1%). The results of the expanded gold standard (CDB plus VRB plus ECC or LEEP), as shown in Table 9, Table 5, and Table 7, showed overlapped 95% CIs of sensitivity but 95% CI of sensitivity from Table 8 was not overlapped. The sensitivity of VDB plus VRB plus ECC was very similar to the sensitivity of CDB plus ECC (mean difference -1.4%, 95% CI, -5.4%-2.6%, by Z-test).

Discussion

Colposcopic examination has been widely used as a procedure to obtain tissue for pathological diagnosis in patients with abnormal cytology from cervical cancer screening for many decades but not the most appropriate method available in the place of low-resource settings. In our study, we have performed the procedure of VDB plus VRB plus ECC for detecting cervical lesions to determine if it could substitute CDB plus ECC.

In this study, the sensitivity of in each procedure meant the ability of each combination of the tests to detect the cervical lesions that related to preinvasive and invasive cervical cancers, compared to the expanded gold standard, (Cagle et al., 2009) not each other procedure. To our knowledge, there has been no study in the medical literature investigating this procedure, with its potential to be used in low-resource settings, this is the first one.

Our study demonstrated that 95%CI of the sensitivity of VDB plus VRB plus ECC was 95.9% (95%CI, 91.4-98.1), comparable to 95%CI of the sensitivity of CDB plus ECC which was 97.3% (95%CI, 93.2-98.9) (mean difference -1.4%, 95%CI, -5.4%-2.6%, by Z-test), but significantly higher than 95%CI of the sensitivity of VDB only which was 85.6% (95%CI, 78.1-90.8). This means that only VDB can not substitute CDB plus ECC in detecting cervical lesions, while VDB plus VRB plus ECC can. In low-resource settings, where colposcopy is not available, VDB plus VRB plus ECC can be used instead.

References

- Benlinson JL, Pretorius RG, Zhang WH, et al (2001). Cervical cancer screening by simple visual inspection after acetic acid. *Am J Obstet Gynecol*, **98**, 441-4
- Cagle AJ, Hu SY, Sellors JW, et al. Use of an expanded gold standard to estimate the accuracy of colposcopy and visual inspection with acetic acid. *Int J Cancer* 2009; 126: 156-61.
- Chumworathayi B, Eamratsameekool W, Kularbkaew C, Chumworathayi P (2008). Visual inspection with acetic acid test qualities in a secondary setting. *J Obstet Gynaecol Res*, **34**, 909-13.
- Julia C, Vivien W, Kim A, et al (2006). Number of cervical biopsies and sensitivity of colposcopy. *Am J Obstet Gynecol*, **108**, 264-72.
- Khuhaprema T, Srivatanakul P, Attasara P, et al (2010). Cancer in Thailand Vol. V, 2001-2003. Bangkok: Ministry of Public Health and Ministry of Education.
- Ottaviano M, La Torre P (1982). Examination of the cervix with the naked eye using acetic acid test. *Am J Obstet Gynecol*, **143**, 139-42.
- Pakhee A, Swaraj B, Gauri G, Vijay Z (2010). Can visual inspection with acetic acid under magnification substitute colposcopy in detecting cervical intraepithelial neoplasia in low-resource settings? *Arch Gynecol Obstet*.
- Robert G, Yan-Ping B, Jerome L, et al (2007). Inappropriate gold standard bias in cervical cancer screening studies. *Int J Cancer*, **121**, 2218-24.
- RTCOC/Jhpiego (2003). Safety, acceptability, and feasibility of a single-visit approach to cervical-cancer prevention in rural Thailand: a demonstration project. *Lancet*, **361**, 814-20.
- Stewart L, Jeronimo J, Schiffman M (2008). Interobserver agreement in the assessment of components of colposcopic grading. *Am J Obstet Gynecol*, **111**, 1279-84.

University of Zimbabwe/Jhpiego Cervical Cancer Project (1999). Visual inspection with acetic acid for cervical-cancer screening: Test qualities in a primary-care setting. *Lancet*, **353**, 869-73.