

RESEARCH COMMUNICATION

High Expression of Stem Cell Marker ALDH1 is Associated with Reduced BRCA1 in Invasive Breast Carcinomas

Zahra Madjd^{1,2*}, Babak Ramezani¹, Saadat Molanae³, Mohsen Asadi-Lari²

Abstract

Background: Cancer stem cells (CSC) have been described in a variety of malignancies, including breast carcinomas. Among several markers, aldehyde dehydrogenase 1 (ALDH1) has been identified as reliable for breast cancer stem cells. Knockdown of BRCA1 in primary breast epithelial cells leads to an increase in cells expressing ALDH1. **Methods:** We examined 127 breast carcinomas for expression of ALDH1, using immunohistochemistry and correlated with clinicopathological parameters as well as the BRCA1 status. **Results:** Comparing the results for both ALDH1 and BRCA1 expression showed a significant inverse association between the two, indicating that reduced BRCA1 was more often seen in breast cancer cells expressing ALDH1 (p-value = 0.044). A total of 24/110 (22%) of tumours displayed the ALDH1 + / BRCA1 -/low phenotype, which showed a trend for a relation with a high grade (p-value= 0.056). Cytoplasmic expression of ALDH1 was not correlated with tumour characteristics. **Conclusion:** Taken together, our findings suggest that increased ALDH1 is inversely correlated with decreased BRCA1 in a series of unselected breast carcinomas. Therefore, ALDH1 positive (cancer stem) cells with reduced BRCA1 phenotype may indicate a subset of patients for whom specific targeting of the CSC marker ALDH1 and more aggressive adjuvant treatment is appropriate.

Keywords: Breast cancer - cancer stem cells - ALDH1

Asian Pacific J Cancer Prev, 13, 2973-2978

Introduction

According to cancer stem cell (CSC) model, cancers are driven by a small subpopulation of stem cells with ability of self-renewal and give rise to multipotent progenitor cells that eventually differentiate into all cell types within the tumour (Visvader and Lindeman, 2008). Cancer stem cells have been identified in various malignancies including breast, brain, prostate, colon, pancreatic, and head and neck cancers, melanoma and multiple myeloma (Matsui et al., 2004; Collins et al., 2005; Fang et al., 2005; Costa et al., 2006; Li et al., 2007). As cancer stem cells are resistance to current radiation and chemotherapy (Diehn and Clarke, 2006; Phillips et al., 2006; Eyler and Rich, 2008; Li et al., 2008), it is crucial to identify markers specific to CSC, which allow targeted therapies directed against this population to cure cancer. In 2003, Al-Hajj et al. for the first time distinguished tumorigenic from non-tumorigenic cancer cells using cell surface markers CD44 and CD24 in breast tumours (Al-Hajj et al., 2003; Nalwoga et al., 2010).

Consequently, Ginestier et al. described that ALDH (aldehyde dehydrogenase) 1 may be a better marker for characterisation of breast cancer stem cells as fewer ALDH1+ tumour cells than CD44+ and CD24- tumour cells were required to produce tumours in immunodeficient mice. They found that ALDH1 is a marker of normal and malignant human mammary stem cells and a predictor

of poor clinical outcome (Balicki, 2007; Ginestier et al., 2007). Therefore, determination of ALDH1 cancer stem cells may be clinically useful for patient's prognosis. CSC positive breast cancers, particularly ALDH1 positive cancers have been showed that to be more likely negative for ER and PR, but positive for HER2 and Ki67 correlating with more aggressive breast cancer subtypes (Morimoto et al., 2009; Zhou et al., 2010). Expression of ALDH1 was seen in stromal cells as well as epithelial cells of breast tumours which is associated with good outcome, concluding that tumour environment play a crucial role in determining the prognostic impact of stem cells (Neumeister and Rimm, 2010; Resetkova et al., 2010). Furthermore, it has been showed that knockdown of BRCA1 in primary breast epithelial cells leads to accumulation of cells expressing ALDH1 (Liu et al., 2008).

In the present study, we evaluated both epithelial and stromal expression of ALDH1 to examine its relation with the clinicopathological characteristics of tumours in unselected series of breast carcinomas using immunohistochemistry. For further characterization of the phenotype of breast cancer stem cells, the BRCA1 status of ALDH1+ tumour cells was investigated in the same collection of breast cancers. To our knowledge, this is the first cross sectional study to evaluate relationship between expression of CSC marker ALDH1 and BRCA1 mutation in unselected series (either family or sporadic) of breast carcinomas.

¹Department of Pathology, ²Oncopathology Research Centre, Tehran University of Medical Sciences, ³Department of Pathology, Milad Hospital, Tehran, Iran *For correspondence: Zahra.madjd@yahoo.com, z-madjd@tums.ac.ir

Materials and Methods

Patients and breast tumour tissues

Tumour tissue samples were obtained from 127 primary breast cancer patients who underwent breast surgery or biopsy between 2006 and 2007 at Milad Hospital, a major public referral centre in Tehran, Iran. Surgical specimens were obtained before systemic treatment and paraffin-embedding was performed within the framework of diagnostic procedures. The following data were sought from patients medical records as part of the study: age, tumour size, vascular invasion (Pinder et al., 1994), tumour grade (Elston and Ellis, 1991; Balicki, 2007), stage/lymph node status and tumour type (Ellis et al., 1992). Since not all demographic and clinical data was recorded for this collection, available data were used for the study purpose. This study was approved by the university Ethical Committee. Patients' data were kept fully anonymous. This collection of primary operable breast carcinomas was previously used to study CD44, Bcl2 (Madjd et al., 2009), and BRCA1 expression (Madjd et al., 2011).

Immunohistochemical staining

Expression of ALDH1 was analyzed using rabbit polyclonal ALDH1 antibody (abcam, Cambridge, UK) by immunohistochemistry method as described previously (Madjd et al., 2009). Briefly, 4 µm formalin-fixed paraffin embedded tissue sections were deparaffinised with xylene and then rehydrated in descending concentrations of alcohol. Endogenous peroxidase activity was blocked by incubation in a 0.3% hydrogen peroxide/methanol buffer for 15 minutes. The tissues were treated with antigen retrieval by autoclaving for 10 minutes in sodium citrate buffer (pH 6.0). The slides were then incubated with ALDH1 antibody (1:250) for 45 min at room temperature. After washing, the sections were incubated with Novolink polymer RE7 140-K (Novocastra) for 1 hour. The staining was visualized using DAB plus (Dako, DakoCytomation) and haematoxylin (DakoCytomation) counterstain. Finally, all sections dehydrated in alcohol, cleared in xylene and mounted for examination. Human liver tissue was used as positive control to confirm the specificity of staining and negative control consisted of replacement of the primary antibody by PBS.

Expression of BRCA1 was studied in our previous study using BRCA1 monoclonal antibody (clone MxH GLK2, Dako) in the same series of breast carcinomas (Madjd et al., 2011).

Evaluation of staining

Semi-quantitative scoring system which relies on the subjective assessment of multiple independent observers was used in this study. The staining of the tissue sections was evaluated by two investigators on two separate occasions after the series were examined on a double-headed microscope blinded to patient's outcome and other clinical findings. The controversy cases were reviewed by the third investigator to achieve a final consensus.

ALDH1 expression in the epithelial component of the tumours as well as the tumoral stroma was recorded.

Cytoplasmic expression of ALDH1 was evaluated, whereas nuclear staining alone was considered nonspecific and was not included in the analysis.

Intensity of staining was scored as 0 (no expression), 1 (weak expression), 2 (moderate expression), and 3 (strong expression). Percentage of cells with positive ALDH1 was graded as: 0, no staining, 1 (<10% positive cells), 2 (10-50% positive cells), 3 (>50% positive cells). The overall score was obtained by H-score (McCarty et al., 1985) for each case by multiplying the intensity of staining by the percentage of positive cells (Ginestier et al., 2007; Jiang et al., 2009; Madjd et al., 2009). The cut-off value for overall score was chosen to classify the samples as ALDH1 positive or negative.

Cytoplasmic expression in epithelial cells was scored as described above, whereas stromal ALDH1 expression was categorized as none or weak, moderate, and strong. (Resetskova et al., 2010)

Statistical analysis

Statistical analysis of data was performed using SPSS software version 16 (Chicago, IL). The significance of the association between ALDH1 expression and clinicopathological parameters was analyzed using Pearson's chi-square and Pearson's R tests. To obtain effect sizes and to look at the independence of effects, overall staining of ALDH1 was classified as a binary outcome as negative and positive and effects of clinicopathological parameters were assessed using multiple logistic regressions to calculate adjusted odds ratios with 95% confidence intervals. P values less than 0.05 were considered statistically significant.

Results

Study population

Of 127 breast tumour sample which included in the present study, 110 (86.6%) of cases were invasive ductal carcinoma (IDC, NOS type), 4 (3.1%) cases of IDC with associated ductal carcinoma in situ (DCIS), 2 (1.6%) medullary carcinoma, 1 (0.8%) mucinous carcinoma, 4 (3.1%) invasive lobular carcinoma (ILC), and 6 (4.7%) cases of pure (DCIS). Excluding DCIS cases, among the remaining cases, 53 (44%) were grade 3, 50 (41%) were grade 2, and only 18 (15%) cases were grade 1. Tumour size was categorised in two main groups based on TNM classification of human breast cancers: group 1 tumours were 2.0 cm or less in greatest dimension (T1) comprising 43 (34%) tumours and group 2 tumours were larger than 2.0 cm in greatest dimension (T2, T3 and T4) including 84 (66%) tumours. Of the patients with known lymph node status, 63% of the tumours were lymph node positive (one or two auxiliary nodes involved), whereas 37% of the tumours were node negative. Among tumours with available data on vascular invasion (VI), 39% of the tumours showed vascular invasion whereas the remaining 61% were without any vascular invasion.

The patients ranged in age from 25 to 82 years old (mean of 48 years), of whom, 28 (22%) patients were younger than 40, whereas 99 (78%) patients were over 40 years of age. Patient and tumour characteristics are

summarized in Table 1.

Expression of ALDH1 in breast carcinomas

Expression of ALDH1 in breast carcinomas was determined using immunohistochemistry. Liver biopsy tissue which used as positive control showed strong and uniform staining of ALDH1 (Figure 1). Within the adjacent normal breast tissue, wherever present, ALDH1 expression was noted in cytoplasm of rare luminal epithelial cells (data not shown). In contrast, within the breast tumours the expression was broadly heterogenous;

Table 1. Association Between Cytoplasmic Expression of ALDH1 and Clinicopathological Parameters of Breast Carcinomas

	ALDH1- No. (%)	ALDH1+ No. (%)	Total No.	P- value, Pearson X ²
Patients and tumour characteristics				
Age (year)				
≤40	14 (50)	14 (50)	28	0.49
>40	52 (52.5)	47 (47.5)	99	
Histological Grade				
Grade 1	8 (44)	10 (56)	18	0.207
Grade 2	22 (44)	28 (56)	50	
Grade3	32 (60)	21 (40)	53	
Lymph Node metastasis				
Negative	13 (45)	16 (55)	29	0.18
Positive	29 (58)	21 (42)	50	
Vascular invasion				
Negative	20 (42)	28 (58)	48	0.26
Positive	16 (52)	15 (48)	31	
Tumour size (cm)				
≤ 2	21 (49)	22 (51)	43	0.36
>2	46 (55)	38 (45)	84	
Tumour type				
Invasive ductal carcinoma (NOS)				
	58 (53)	52 (42)	110	0.43
Other tumour type (Invasive lobular Ca, Medulary Ca, and Mucinous Ca)				
	8 (47)	9 (53)	17	

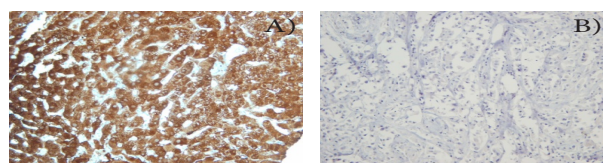


Figure 1. A) Strong and Uniform Staining of ALDH1 in Human Liver Biopsy Tissue used as Positive Control. B) Negative Control Consisting of Replacement of the Primary Antibody by PBS

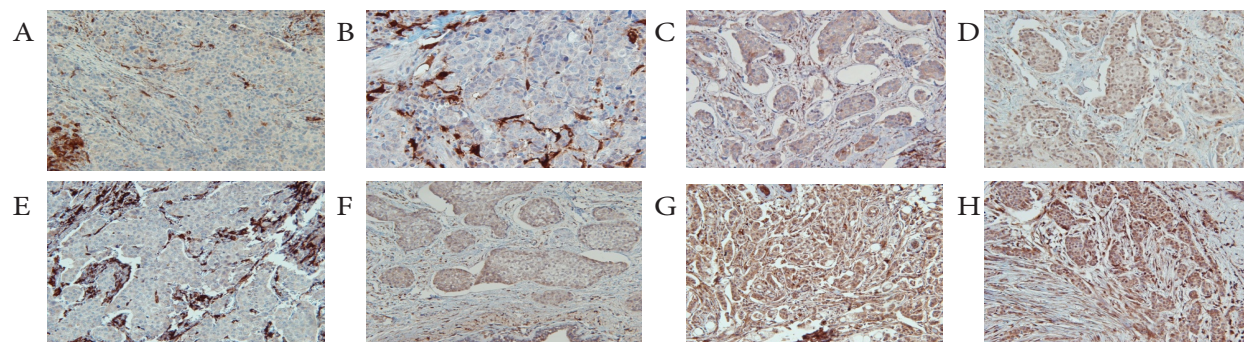


Figure 2. The Expression of ALDH1 within the Tumour Cells and Stroma. A, B, C) No Staining of Breast Tumour Cells with Strong Staining of Stroma. D) Weak E, F) Moderate and G, H) Strong Staining of Invasive Breast Carcinomas

i.e in most of cases cytoplasmic expression of ALDH1 was noted in dispersed tumour cells, whereas in some cases the expression was seen in the majority of tumour cells. The expression of ALDH1 within the tumours showed wide variation, ranging from weak to very strong expression (Figure 2). The percentage of ALDH1 positive cells was also found to be variable: 18 out of 127 breast tumours (14%) were 0 (no staining), whereas 18 (14%) cases were +1 (<10% positive cells), 19 (15%) were 2 (10-50% positive cells), and 72 (57%) were 3 (>50% positive cells). For overall staining (H-score determination), the cut-off value (median) was calculated to define groups showing ALDH1 negative (H-score <80) and ALDH1 positive (H-score >80).

Sixty out of 127 (52%) breast tumours that were stained with ALDH1, were considered to be ALDH1

Table 2. Logistic Regression Analysis of ALDH1 Cytoplasmic Expression Categorized as Positive and Negative

Prognostic Factors	Odds Ratio (95% CI)	Test for trend (linear by linear)	
Age:	≤40 years	1	0.813
	>40 years	0.904 (0.390-2.092)	
Histological Grade:	Grade 1	1	0.205
	Grade 2	1.018 (0.344-3.012)	
	Grade 3	0.525 (0.178-1.547)	
LN metastasis:	Negative	1	0.258
	Positive	0.588 (0.234-1.480)	
Vascular Invasion:	Negative	1	0.386
	Positive	0.670 (0.270-1.661)	
Tumour size:	≤2	1	0.597
	>2	0.814 (0.379-1.747)	
Tumour type:			
Invasive ductal carcinoma (NOS)	1		0.663
Other tumour type*		1.255 (0.451 -3.491)	

*Invasive lobular Ca, Medulary Ca, and Mucinous Ca

Table 3. Relationship between Expression of ALDH1 and BRCA1

	ALDH1- Tumours n (%)*	ALDH1+ Tumours n (%)*	Total (n)	P-value (chi 2 test)
Nuclear BRCA1 expression				
Loss/reduced	19 (17.3)	24 (21.8)	43	0.044
strong	42 (38.2)	25 (22.7)	67	
Total	61	49	110	

*% of Total

negative (H-score <80) , while 48% of cases (61) were ALDH1 positive (H-score >80) .

The expression of ALDH1 was not only restricted to epithelial component of tumour cells but also noted in tumour stromal cells (Figure 2). In this series of breast tumours, moderate to strong stromal expression of ALDH1 was observed in the majority (74%) of cases.

Relationship of ALDH1 expression with clinicopathological parameters

In univariate analysis, we were unable to verify significant correlations between intratumoural epithelial expression of ALDH1 and patient's age (p-value= 0.49), tumour grade (p-value= 0.207), lymph node metastasis (p-value= 0.18), vascular invasion (p-value =0.26) or tumour size (p-value= 0.36) (Table 1). In multiple logistic regressions, overall cytoplasmic expression of ALDH1 was reclassified as a binary outcome as negative and positive based on cut-off value. The odds ratio for positivity of ALDH1 in high grade tumours compared to well-differentiated tumours was 0.525 (95% CI, 0.178-1.547) (Table 2). Stromal expression of ALDH1 was not correlated with any tumour characteristics.

Association of ALDH1 and BRCA1 expression

To evaluate the relationship between expression of ALDH1 and BRCA1, the overall cytoplasmic staining of ALDH1 correlated with nuclear BRCA1 accumulation obtained from our previous study (Madjd et al., 2011). Comparing results of 110 breast tumours with common data for both ALDH1 and BRCA1, a significant inverse association was found between expression of ALDH1 and BRCA1 (p-value=0.044, Table 3).

Analysis of the ALDH1-/- BRCA1 high phenotype

Combined analysis of the two markers indicated that a total of 19/110 tumours (17%) displayed the ALDH1-/- BRCA1-low phenotype, whereas 38 percent (42/110) of tumours expressed ALDH1 -/- BRCA1 high phenotype. Twenty-two percent (24/110) of cases were ALDH1 +/- BRCA1 -/low phenotype, while 23 percent (25/110) tumours expressed ALDH1 +/- BRCA1 high phenotype. In univariate analysis, a trend for correlation between combined ALDH1+ /BRCA1 low phenotype with high grade tumours was found, indicating that this phenotype tends to be more probable in high grade tumours. (p-value= 0.056)

Discussion

Among several markers which have been identified for the characterization of cancer stem cells, ALDH1 is one of the most widely reported ones (Balicki, 2007; Ginestier et al., 2007; Neumeister et al., 2010; Resetkova et al., 2010; Zhou et al., 2010). Epithelial ALDH1 expression by immunohistochemistry has been suggested as a workable definition for CSC in fixed tissues (Ginestier et al., 2007; Neumeister and Rimm, 2010). ALDH1 is a cytosolic detoxifying enzyme responsible for the oxidation of (retin) aldehydes into retinoids (Vasiliou et al., 2000), which has been introduced as a marker of both normal and cancer

stem cells of breast. The main role of ALDH1 in stem cells is appearing to be in cellular differentiation, particularly through the retinoid signalling pathway (Ginestier et al., 2007). It has been also suggested that knockdown of BRCA1 function in primary breast epithelial cells leads to an increase in cells expressing CSC marker ALDH1 (Liu et al., 2008).

The aim of this study was to investigate the expression of putative stem cell marker ALDH1 and its prognostic value in breast cancers and their possible associations with mutated BRCA1 in a collection of unselected breast tumour samples from an Iranian population (Madjd et al., 2011).

In a series of 127 breast carcinomas we were unable to verify correlations between ALDH1 cytoplasmic expression and histological grade, although previous studies stated that ALDH1 positive cells (CSC) were significantly associated with high grade tumours and poor overall survival indicating that ALDH1 status maybe an indicator of aggressive breast carcinomas (Ginestier and Wicha, 2007; Morimoto et al., 2009; Nalwoga et al., 2010; Neumeister et al., 2010; Yoshioka et al., 2011).

This is probably due to the fact that the study was restricted to limited sample size and therefore warrants further investigation with a larger number of samples. The other problem is that there is no agreement on the scoring method and cut- off used for ALDH1 positivity, although majority of studies scored both intensity and percentage of positive cells as we did.

In line with previous studies, tumour cell expression of ALDH1 was not correlated with a number of examined parameters including age, tumour size, lymph node metastasis, and tumour type (Resetskova et al., 2010; Zhou et al., 2010), although Yoshioka et al (Yoshioka et al., 2011) in a study performed on 257 invasive ductal carcinomas (IDCs) showed that ALDH1 expression was correlated with larger tumour size in node-positive breast cancers.

Contradictory with the association between epithelial (cytoplasmic) ALDH1 expression and poor prognosis in previous studies, intratumoural stromal expression of ALDH1 was associated with the best outcome (Resetskova et al., 2010). Therefore, it is postulated that epithelial and stromal ALDH1 expression may be responsible for different process of carcinogenesis, since in both our study and literature (Heerma et al., 2011) there was no association between epithelial and stromal ALDH1 expression. Tumour stroma can be a reasonable place for presence of stem cells, and it is noted that the stromal microenvironment of a tumour may contribute to the malignant features of epithelial tumours.(Trimboli et al., 2009; Neumeister et al., 2010). The biological role of ALDH1 apart from its potential role in stem cells and cellular differentiation might be another explanation for diverse effects of epithelial and stromal ALDH1 expression (Heerma et al., 2011). Similar to literature (Resetskova et al., 2010; Heerma et al., 2011) majority of our cases showed moderate to strong ALDH1 expression in intratumoural stroma, although it was not correlated with tumour parameters.

Other studies have suggested that frequency of cancer

stem cells within breast tumours may correspond to the risk of distant metastases (Abraham et al., 2005; Glinsky et al., 2005; Trimboli et al., 2009). Due to the lack of information on distant metastases, we could not investigate its correlation with the prevalence of ALDH1+ tumour cells.

To evaluate the relationship between expression of ALDH1 and BRCA1, the overall cytoplasmic staining of ALDH1 correlated with nuclear BRCA1 accumulation (Madjd et al., 2011). Consistent with prior published data, we found a significant inverse association between expression of ALDH1 and BRCA1 indicating that ALDH1 positive tumours are more likely to loss or express low level of BRCA1. Liu et al suggested that loss of BRCA1 function in primary breast epithelial cells leads to accumulation of cells expressing ALDH1 (Liu et al., 2008). These finding was emphasized by Heerma van voss et al (Heerma et al., 2011), pointing out ALDH1 tumour cell expression was an independent predictor of BRCA1 mutation status. In a case-control study, they compared ALDH1 expression in malignant tissue of 41 BRCA1 related breast cancers with 41 age-matched sporadic breast cancers, whereas our cross sectional study was performed in a series of 127 unselected breast tumour samples including either hereditary or sporadic breast cancer with a mean age of 48 years, demonstrating that higher expression of ALDH1 significantly correlated with altered expression of BRCA1. This supports the idea that BRCA1 mutated breast cancers contain an enlarged CSC component.

ALDH1 has been suggested to serve as a biomarker for BRCA1 mutation carriers and therapeutic target (Heerma et al., 2011). Moreover, Kunju et al (2011) in very recent study presented primary evidence that epithelial and stromal ALDH1 detection in benign breast biopsies may predict increased risk for breast cancer, which may have implications for breast cancer prevention.

Further to previous studies, we established a phenotype with combination of positive cytoplasmic ALDH1 expression and negative nuclear BRCA1 expression in breast cancer and found a trend for correlation between this population (ALDH1+ /BRCA1 low tumours) with high grade tumours, indicating that this phenotype more tends to occur in high grade tumours. Therefore, a population of patients was described for whom exclusively targeting CSC marker ALDH1 and more aggressive adjuvant treatment is indicated.

In conclusion, a high prevalence of ALDH1 staining in this series of unselected invasive breast carcinomas was significantly associated with reduced BRCA1. Therefore, evaluation of ALDH1 and BRCA1 expression may help to identify a high-risk subgroup of breast cancer cells providing useful prognostic information. Our present observation needs to be confirmed by a future study including a larger number of patients.

Acknowledgements

This research was conducted as a medical specialty dissertation and granted by Tehran University of Medical Sciences (grant number 694). We are grateful to Dr

Gohari for his statistical advice and Mrs. Sharzavi for her technical assistance. There is no conflict of interest in this article.

References

- Abraham BK, Fritz P, McClellan M, et al (2005). Prevalence of CD44+/CD24-/low cells in breast cancer may not be associated with clinical outcome but may favor distant metastasis. *Clin Cancer Res*, **11**, 1154-9.
- Al-Hajj M, Wicha MS, Benito-Hernandez A, Morrison SJ, Clarke MF (2003). Prospective identification of tumorigenic breast cancer cells. *Proc Natl Acad Sci USA*, **100**, 3983-8.
- Balicki D (2007). Moving forward in human mammary stem cell biology and breast cancer prognostication using ALDH1. *Cell Stem Cell*, **1**, 485-7.
- Collins AT, Berry PA, Hyde C, Stower MJ, Maitland NJ (2005). Prospective identification of tumorigenic prostate cancer stem cells. *Cancer Res*, **65**, 10946-51.
- Costa FF, Le Blanc K, Brodin B (2007). Cancer/testis antigens, stem cells and cancer. *Stem Cells*, **25**, 707-11.
- Diehn M, Clarke MF (2006). Cancer stem cells and radiotherapy: new insights into tumor radioresistance. *J Natl Cancer Inst*, **98**, 1755-7.
- Ellis IO, Galea M, Broughton N, et al (1992). Pathological prognostic factors in breast cancer. II. Histological type. Relationship with survival in a large study with long-term follow-up. *Histopathology*, **20**, 479-89.
- Elston CW, Ellis IO (1991). Pathological prognostic factors in breast cancer. I. The value of histological grade in breast cancer: experience from a large study with long-term follow-up. *Histopathology*, **19**, 403-10.
- Eyler CE, Rich JN (2008). Survival of the fittest: cancer stem cells in therapeutic resistance and angiogenesis. *J Clin Oncol*, **26**, 2839-45.
- Fang D, Nguyen TK, Leishear K, et al (2005). A tumorigenic subpopulation with stem cell properties in melanomas. *Cancer Res*, **65**, 9328-37.
- Ginestier C, Hur MH, Charafe-Jauffret E, et al (2007). ALDH1 is a marker of normal and malignant human mammary stem cells and a predictor of poor clinical outcome. *Cell Stem Cell*, **1**, 555-67.
- Ginestier C, Wicha MS (2007). Mammary stem cell number as a determinant of breast cancer risk. *Breast Cancer Res*, **9**, 109.
- Glinsky GV, Berezovska O, Glinskii AB (2005). Microarray analysis identifies a death-from-cancer signature predicting therapy failure in patients with multiple types of cancer. *J Clin Invest*, **115**, 1503-21.
- Heerma van Voss MR, Van der Groep P, Bart J, Van der Wall E, Van Diest PJ (2011). Expression of the stem cell marker ALDH1 in BRCA1 related breast cancer. *Cell Oncol*, **34**, 3-10.
- Jiang F, Qiu Q, Khanna A, et al (2009). Aldehyde dehydrogenase 1 is a tumor stem cell-associated marker in lung cancer. *Mol Cancer Res*, **7**, 330-8.
- Kunju LP, Cookingham C, Toy KA, et al (2011). EZH2 and ALDH-1 mark breast epithelium at risk for breast cancer development. *Mod Pathol*, **24**, 786-93.
- Li C, Heidt DG, Dalerba P, et al (2007). Identification of pancreatic cancer stem cells. *Cancer Res*, **67**, 1030-7.
- Li X, Lewis MT, Huang J, et al (2008). Intrinsic resistance of tumorigenic breast cancer cells to chemotherapy. *J Natl Cancer Inst*, **100**, 672-9.
- Liu S, Ginestier C, Charafe-Jauffret E, et al (2008). BRCA1 regulates human mammary stem/progenitor cell fate. *Proc Natl Acad Sci USA*, **105**, 1680-5.

- Madjd Z, Mehrjerdi AZ, Sharifi AM, et al (2009). CD44+ cancer cells express higher levels of the anti-apoptotic protein Bcl-2 in breast tumours. *Cancer Immun*, **9**, 4.
- Madjd Z, Karimi A, Molanae S, Asadi-Lari M (2011). BRCA1 protein expression level and CD44+ phenotype in breast cancer patients. *Cell Journal*, **13**, 155-62.
- Matsui W, Huff CA, Wang Q, et al (2004). Characterization of clonogenic multiple myeloma cells. *Blood*, **103**, 2332-6.
- McCarty KS Jr, Miller LS, Cox EB, Konrath J, McCarty KS Sr (1985). Estrogen receptor analyses. Correlation of biochemical and immunohistochemical methods using monoclonal antireceptor antibodies. *Arch Pathol Lab Med*, **109**, 716-21.
- Morimoto K, Kim SJ, Tanei T, et al (2009). Stem cell marker aldehyde dehydrogenase 1-positive breast cancers are characterized by negative estrogen receptor, positive human epidermal growth factor receptor type 2, and high Ki67 expression. *Cancer Sci*, **100**, 1062-8.
- Nalwoga H, Arnes JB, Wabinga H, Akslen LA (2010). Expression of aldehyde dehydrogenase 1 (ALDH1) is associated with basal-like markers and features of aggressive tumours in African breast cancer. *Br J Cancer*, **102**, 369-75.
- Neumeister V, Agarwal S, Bordeaux J, Camp RL, Rimm DL (2010). In situ identification of putative cancer stem cells by multiplexing ALDH1, CD44, and cytokeratin identifies breast cancer patients with poor prognosis. *Am J Pathol*, **176**, 2131-8.
- Neumeister V, Rimm D (2010). Is ALDH1 a good method for definition of breast cancer stem cells? *Breast Cancer Res Treat*, **123**, 109-11.
- Phillips TM, McBride WH, Pajonk F (2006). The response of CD24(-/low)/CD44+ breast cancer-initiating cells to radiation. *J Natl Cancer Inst*, **98**, 1777-85.
- Pinder SE, Ellis IO, Galea M, et al (1994). Pathological prognostic factors in breast cancer. III. Vascular invasion: relationship with recurrence and survival in a large study with long-term follow-up. *Histopathology*, **24**, 41-7.
- Resetskova E, Reis-Filho JS, Jain RK, et al (2010). Prognostic impact of ALDH1 in breast cancer: a story of stem cells and tumor microenvironment. *Breast Cancer Res Treat*, **123**, 97-108.
- Trimboli AJ, Cantemir-Stone CZ, Li F, et al (2009). Pten in stromal fibroblasts suppresses mammary epithelial tumours. *Nature*, **461**, 1084-91.
- Vasiliou V, Pappa A, Petersen DR (2000). Role of aldehyde dehydrogenases in endogenous and xenobiotic metabolism. *Chem Biol Interact*, **129**, 1-19.
- Visvader JE, Lindeman GJ (2008). Cancer stem cells in solid tumours: accumulating evidence and unresolved questions. *Nat Rev Cancer*, **8**, 755-68.
- Yoshioka T, Umekita Y, Ohi Y, et al (2011). Aldehyde dehydrogenase 1 expression is a predictor of poor prognosis in node-positive breast cancers: a long-term follow-up study. *Histopathology*, **58**, 608-16.
- Zhou L, Jiang Y, Yan T, et al (2010). The prognostic role of cancer stem cells in breast cancer: a meta-analysis of published literatures. *Breast Cancer Res Treat*, **122**, 795-801.