

RESEARCH ARTICLE

Expression of P-glycoprotein is Positively Correlated with p53 in Human Papilloma Virus Induced Squamous Intraepithelial Lesions of Uterine Cervix: Poor Prognosis Association

Madhulika Singh¹, Uma Singh², Neeraj Mathur³, Yogeshwer Shukla^{1*}

Abstract

This study was conducted to assess the predictive value of p-glycoprotein (p-gp) and p53 immunoreactivity in human papillomavirus (HPV) infected cases of cervical dysplasia. Expression of both p-gp and p53 proteins was detected in cervical smears from 177 squamous intraepithelial lesions (SIL) cases along with 183 “atypical squamous cells of unknown significance” (ASCUS) and 150 normal cases. HPV 16 and 18 infection was detected by polymerase chain reaction using type-specific primers for HPV sub-types. There were no significant detectable p53 and p-gp expression in the normal cervix smears ($p > 0.05$). In the ASCUS group 10 cases were positive for both p53 and p-gp immunoreactivity. In cervical dysplasia cases, p53 was positive in 86 (48.58%) while p-gp was positive in 93 (52.54%) and the two markers showed a highly significant correlation ($r = 0.92$, $p < 0.001$). Expression of p53 and p-gp was associated with grade of SIL ($p < 0.001$). A positive correlation between the presence of HPV and expression of proteins p53 and p-gp in smears of patients with cervical lesions was also noted ($p < 0.001$). Thus, p53 and p-gp immunostaining in cervical smears may act as an auxiliary biomarker for detection of HPV-associated cervical lesions. Additionally, a significant positive correlation between ascending grades of SIL and labeling indices of markers suggests that p53 and p-gp can be used as an adjunct to cytomorphological interpretation of conventional cervical Pap smears.

Keywords: Cervical dysplasia - human papilloma virus - p-glycoprotein - p53 - SIL/CIN - cervical smear

Asian Pacific J Cancer Prev, 13 (12), 6039-6045

Introduction

Cancer of the uterine cervix is the second most common and the fifth most deadly cancer among women worldwide, and it is the principal cancer among women in most developing countries (Kent, 2010). With an overall poor survival rate cervical cancer continues to remain a key international health problem (Ferlay et al., 2002). Accomplishment of Papanicolaou (Pap) screening program to reduce the incidence of cervical cancer is successful among the developed nations (Canavan and Doshi, 2000). However, the extent of cervical cancer incidence reduction and the cost-effectiveness of such programs still remains the subject of debate in most of the developing countries. Together with these, due extremely variable natural history of cervical intraepithelial neoplasia (CIN), till date it is not possible to predict which cases of CIN will progress and which will persist or regress. Objective biomarkers which allow unambiguous identification of truly dysplastic cells and/or predict disease progression is required.

Human papillomavirus (HPV) infection is associated with the overwhelming majority of invasive squamous

cell carcinoma cases and has also been found in a high proportion of CIN cases. Evidence from *in-vitro* cell transformation experiments indicates that DNA from high-risk HPV sub-types (e.g. 16 and 18) are capable of epithelial cells transformation in cooperation with activated cellular oncogenes, thus impersonating multi-step carcinogenesis (Stoler, 2000). Viral proteins E6/E7 functionally interfere with cell-cycle control by inactivating tumor-suppressor gene p53 and the retinoblastoma (Scheffner et al., 1990; Bremer et al., 1995) therefore; cells expressing high risk HPV are deprived of p53 tumor-suppressor activities. Aberration of p53 gene which is among the most frequent alteration in human malignancies, additionally, plays an important role in determining the resistance of cancer cells to chemotherapy (Linn et al., 1996; Perego et al., 1996). In cervical carcinoma over expression of p53 protein and its correlation with aggressive biological behavior is documented (Helland et al., 1993; Oh et al., 2004; Singh et al., 2009).

Over-expression of the multidrug resistance gene (*MDR1*) product p-glycoprotein (p-gp), an energy-dependent drug efflux pump, has been shown as oncogene

¹Proteomics Laboratory, ³Department of Epidemiology, Indian Institute of Toxicology Research (Council of Scientific and Industrial Research), ²Department of Obstetrics and Gynecology, Chhatrapati Shahuji Maharaj Medical University, Lucknow, India *For correspondence: yogeshwer_shukla@hotmail.com

activation, tumor aggressiveness, and predictor and prognosticator chemoresistance in cancer cells (Pinedo and Giaccone, 1995; Ralhan et al., 1997; Yakirevich et al., 2006). According to Johnstone et al. (2000) p-gp potentially regulates apoptosis, immune cell function and, cellular differentiation, proliferation and survival also. Chin et al. (1992) have indicated that the *MDR1* gene could be activated during tumor progression associated with mutations in p53 and ras. Additionally, p53 regulates the function of transport proteins like p-gp. According to Sampath et al. (2001) mutant p53 activates the *MDR-1* promoter activity, whereas wild-type p53 reported to represses this activity. Certainly, p53 mutations appear the most common genetic alterations in human tumors (Linn et al., 1996; Perego et al., 1996). However, if mutational inactivation of p53 is correlated with the occurrence of the *MDR* phenotype during tumor progression, other factors such as HPV E6 oncoprotein modulating the function of wild-type p53 protein could also influence the tumor cells (Scheffner et al., 1990; Bremer et al., 1995). Earlier studies that have focused on clinical specimens to investigate the impact of the co-expression of p53 and p-gp proteins on disease prognosis, showed the differential expression of both proteins as individual molecular markers of cancer and their correlation with clinicopathological parameters (Linn et al., 1996; Ralhan et al., 1999; Park et al., 2001). So far, the clinical significance of co-expression of p53 and p-gp expression in cervical carcinogenesis remains to be ascertained. A study by Schneider et al. (1994) reported that *MDR1* protein expression in cervical tumors tissue is associated with HPV presence and the functional state of p53 protein. However, no systematic investigation regarding the role of p-gp as a marker for lesions aggressiveness has been carried out in cervical cancer.

Therefore, present study was aimed to determine the relationship between the expression of p-gp, and p53 proteins in presence or absence of HPV (16 and 18) in different cytological stages of cervix and the impact of their concomitant expression on the clinical course of the disease.

Materials and Methods

Study participants and collection of cervical smear samples

From year 2005-2008, women receiving routine cytological screening at Queen Mary Hospital (Chhatrapati Shahuji Maharaj Medical University, Lucknow, India) were recruited for the present study. Informed consent was obtained under the prevailing institutional review board guidelines. All subjects were at or above 25 years of age (range 25-67 years; median 35±12.6 years). Participants underwent a routine pelvic examination by an expert gynecologist. Obtained criteria for selecting the women to be those were: above the age of 25 years with three or more children, above the age of 35 years irrespective of parity, unexplained persistent vaginal discharge, post-coital bleeding, post-menopausal bleeding, inter-menstrual bleeding, menstrual irregularity of any sort, any naked eye abnormality of cervix like hypertrophic, eroded or

ulcerated cervix and cervix bleeding on touch.

Experienced clinicians prepared two ethanol-fixed Pap smear slides for each subject using an Ayer's spatula and cytobrush. Cell samples that were left over after slide preparation were collected in cytotube for DNA extraction and processed for HPV testing.

Follow-up

A cytological control examination was done after every 3 or 6 months from the date of registration and the cases were categorized as "returned to normal" after the cytological morphology normalized. Samples were also tested for the p53 and p-gp immunoexpression. Once treated, women were censored and were not included in the denominator of women at risk in subsequent time-intervals.

Cytopathology

Pap stained smears were reported using a classification of Bethesda 2001 terminology (Solomon et al 2002). Cytologic interpretations for smears was as: (i) "normal" or "negative for intraepithelial lesion or malignancy", (ii) "severe reactive atypia, possibly dysplasia" or "possible koilocytotic or condylomatous atypia" as "atypical squamous cells of unknown significance" (ASCUS), (iii) low-grade squamous intraepithelial lesions (mild dysplasia; LSILs) (iv) high-grade squamous intraepithelial lesions (moderate dysplasia and severe dysplasia; HSILs) and (v) carcinoma-in-situ (CIS). Histologic diagnoses were converted into CIN nomenclature for dysplasia cases. Specifically, severe dysplasia and CIS were categorized as CIN3.

Procedure for immunostaining

Pap stained smears were de-stained in 1% acid alcohol (10 min) and then carried out with xylene followed by hydration. After bringing them at room temperature, slides were incubated in 0.3% hydrogen peroxide (H₂O₂): methanol for 10 min to block endogenous activity and afterward epitope retrieval was performed (heating the slides for 90 min in 10 mM citrate buffer pH 6.0). This was followed by blocking of non-specific binding of primary antibodies to epitopes by a preincubation step with 5% normal goat serum for 30 min at room temperature. Smears were then incubated overnight with the respective primary monoclonal anti-bodies namely anti-p53 (clone DO-7 recognizes both mutant and wild form of p53, Serotech; pre-diluted) and anti-p-gp (clone JSB-1; Boehringer Mannheim GmbH, Germany; dilution 1: 50). The reaction products were visualized by using streptavidin biotin immunoperoxidase complex (Serotech) as secondary antibody complex with diaminobenzidine. All smears were counterstained with hematoxylin and mounted with DPX. Smears without primary antibody were used as negative control.

Assessment of immunoreactivity

Immunoreactivity assessment was based on the percentage of positive epithelial cells (brown color) by microscopic evaluation of 100 cells in every smear by using *Leica Q Win500* image analysis system. For p53

positivity characteristic nuclear reactivity in at least 10% of the dysplastic cells was considered. Similarly, p-gp expression was measured significant when plasma membrane and cytoplasmic immunoreactivity was evident in at least 10% of the dysplastic cells. Immunopositivity was graded on bases of expression as mild (>10-25%), moderate (>25-50%) and intense (>50%) expressions. If the percentage of immunopositive cells was <10% then it was considered as “insignificant” or “no expression”.

HPV detection in cervical smear samples

DNA was extracted by using *UltraClean* DNA extraction kit (Imperial Bio-Medic) and the quality and quantity of extracted DNA was checked by agarose gel electrophoresis and spectrophotometry, respectively. PCR was performed for general (GP-PCR, for HPV genotypes 6, 11, 16, 18, 31, 33 and unsequenced types) and type-specific (TS-PCR for HPV subtype -16 and -18) HPVs in all adequate cytological smears. Details of primers and PCR conditions for general (GP5 and GP6) and type specific HPVs (HPV16: product size 152bp and 18: product size 216bp) were as earlier mentioned by van den Brule et al. (1992). In brief, GP-PCR reaction was performed in 50 μ l volume containing KCl (50 mM), MgCl₂ (3.5 mM), deoxynucleoside triphosphate (dNTP; 200 μ M of each), general primer (25 pmol of each), *Taq* DNA polymerase (1U) (procured from Bangalore Genei; Bangalore, India), and 10 μ l of genomic DNA. The samples were subjected to 40 cycles (annealing temperature 40°C for 2 min) of amplification in a DNA thermal cycler and product (150 bp) was analyzed in 1.5% agarose gel. The TS-PCR was performed as described for GP-PCR, except that 1.5mM MgCl₂, 25 pmol of each TS-primer, and an annealing temperature of 55°C were used. DNA viability of the negative samples was checked by a PCR with primers complementary to the human β -globin gene. Samples positive for HPV but negative for the tested HPV sub-types were referred as “not identified HPV type” (NI).

Data analysis

The significance of HPV positive cases in different cytopathological stages was tested using Chi Square (χ^2) test after ascertaining that expected cell frequencies in each cell were more than 5. Similarly, the association of p53 and p-gp proteins expression in different cytopathological stages and with HPV was also tested by χ^2 tests. The significance of mean intensities of p53 and p-gp proteins in different stages were analyzed separately using one way analysis of variance (ANOVA) after ascertaining the homogeneity of variance between the stages. Post hoc analysis was carried out by calculating least significant differences. Pearson correlation coefficient between p53 and p-gp expression was calculated and its significance was tested using t' test. Level of significance was considered to be 5 percent.

Results

Cytology

Out of 577 collected smears only 525 (91%) smears

were found adequate in cytodiagnosis test while rest 53 (9%) smears were inadequate for evaluation. Adequate cervical smears were classified as normal (n=150), ASCUS (n=183), LSIL (n= 114), HSIL (n=63) and CIS (n=15).

Presence of HPV DNA in different cytological grades of cervical smear

HPV-DNA detection in cervical smears by PCR showed that 92% cases in normal and in 85% cases in ASCUS were negative for HPV presence (Table-1). Incidence of HPV presence was significantly higher in SIL and CIS groups when compared with normal and ASCUS groups (p<0.001). Among the HPV positive cases 5 normal and 15 ASCUS smears showed presence of HPV 16 and, 3 normal and 6 ASCUS smears showed presence of HPV 18 subtype. In SIL groups a marked increase in HPV presence was noted, as 40% (46/114) and 78% (49/63) cases from LSIL and HSIL groups were positive for HPV, respectively. In CIS group 87% (13/15) smears were showing the presence of HPV-DNA. HPV prevalence was notable higher in HSIL group as compared to LSIL (p<0.001) and was similar to CIS group. Among the HPV positive cases, distribution of HPV subtypes was similar in the ASCUS, SIL and CIS groups, with the majority being positive for HPV 16 subtype i.e. 55%, 57% and 77% cases, respectively. A significant association between cervical disease (SIL and CIS) and HPV presence was confirmed by data analysis using χ^2 test where p<0.001 for HPV 16 and p<0.01 for HPV 18 as compared to normal (Table 1).

Expression of p53 protein in cervical smears

In analyzed normal and ASCUS smears only 3% (4/15) and 9% (16/183) cases were positive for p53 immunoreactivity, respectively. In CIS group, all the samples showed positive expression (100%, 15/15) while 87% (55/63) of HSIL and 27% (31/114) LSIL cases had p53 expression (Table 2). Significantly increased expression of p53 in CIS and dysplasia groups was observed (for mild expression: p<0.001; moderate to intense expression: p<0.001) as compared to normal and ASCUS groups. Furthermore, CIS and HSIL both were also noted to have higher p53 expression (moderate to high Intensity) in comparison of LSIL cases (Table 2).

Mean intensity of p53 immunoreactivity was 7.69 \pm 0.80 (range 0-18%; median 5.0%) in normal, 9.90 \pm 0.98 (range 0-38%; median 7.0%) in ASCUS, 13.02 \pm 1.37 (range 0-66%; median 15.0%) in LSIL,

Table 1. Presence of HPV 16 and 18 in Different Cytopathological Stages of Cervical Smears

Cytology (n=525)	HPV negative n(%)		HPV positive n(%)		
			HPV-16	HPV-18	HPV-NI
Normal (n=150)	138 (92.00)	5 (3.30)	3 (2.00)	4 (2.60)	
ASCUS (n=183)	156 (85.25)	15 (8.20)	6 (3.30) ^{NS}	6 (3.30) ^{NS}	
LSIL (n=114)	68 (59.65)	23 (20.20)**	10 (8.80)	13(11.40)**	
HSIL (n=63)	14 (22.20)	31 (49.20)**	8 (12.69)*	10(15.87)**	
CIS (n=15)	2 (13.30)	10 (66.66)**	2 (13.30)*	1 (6.60)**	
χ^2 (4 d.f.)	157.3	108	15.6	20.4	
p value	p<0.001	p<0.001	p<0.01	p<0.01	

*Numbers of cases (%) are shown

Table 2. Association of p53 and p-gp Expression with Different Cytopathological Stages of Cervical Smears

Cytology (n=525)	No expression		Mild expression		Moderate to intense expression	
	p53	p-gp	p53	p-gp	p53	p-gp
Normal (n=150)	146 (97.30%)	148 (98.70%)	4 (2.70%)	2 (1.30%)	-	-
ASCUS (n=183)	167 (91.30%)	173 (94.50%)	9 (4.90%)	8 (4.40%)	7 (3.80%)	2 (1.09%)
LSIL (n=114)	83 (72.80%)	74 (64.90%)	17 (14.90%)	21 (18.40%)	14(12.30%)	19 (16.66%)
HSIL (n=63)	8 (12.70%)	10 (15.90%)	19 (30.20%)	14 (22.20%)	36(57.10%)	39 (61.90%)
CIS (n=15)	0	0	4 (26.70%)	3 (20.00%)	11(73.30%)	12 (80.00%)
χ^2 (4 d.f.)	-	-	49.9	42.9	193.5	228.6
P value			p<0.001	p<0.001	p<0.001	p<0.001

*Numbers of cases (%) are shown. Average number of positive cells per 100 cells are given. No expression: <10%; Mild expression: >10-25%; Moderate expression: >25-50% and Intense expression: >50%

Table 3. Association of HPV 16 and 18 with p53 and p-gp Immunoexpression

HPV (n=525)	p53			p-gp		
	No expression	Mild expression	Moderate to intense expression	No expression	Mild expression	Moderate to intense expression
HP negative (n=378)	360 (95.20%)	14 (3.70%)	4 (1.10%)	362 (95.80%)	8 (2.10%)	8 (2.10%)
HPV 16 (n=84)	20 (23.80%)	27 (32.14%)	37 (44.05%)	19 (22.60%)	25 (29.80%)	40 (47.60%)
HPV 18 (n=29)	10 (34.50%)	7 (24.10%)	12 (41.40%)	10 (34.50%)	12 (41.40%)	7 (24.10%)
NI- HPV (n=34)	14 (41.17%)	5 (14.70%)	15 (44.12%)	14 (41.20%)	3 (8.80%)	17 (50.00%)
χ^2 (3 d.f.)	-	69.1	169.5	-	101.7	165.0
P value		p<0.001	p<0.001		p<0.001	p<0.001

*Numbers of cases (%) are shown. Average number of positive cells per 100 cells are given. No expression: <10%; Mild expression: >10-25%; Moderate expression: >25-50% and Intense expression: >50%

Table 4. Association between Coexpression of p53 and P-gp in Cervical Smears

p-gp	p53			
	No expression	Mild expression	Moderate expression	Intense expression
No expression	403	2	0	0
Mild expression	1	31	16	0
Moderate	0	20	39	5
Intense expression	0	0	0	8

*Average number of positive cells per 100 cells are given.No expression: <10%; Mild expression: >10-25%; Moderate expression: >25-50% and Intense expression: >50%. r=0.92 (p<0.001)

26.63±2.22 (range 9-67%; median 36.5%) in HSIL and 46.84±2.17 (range19-90%; median 45%) in CIS groups (p<0.001).

Relation between presence of HPV and p53 immunoexpression

In HPV negative (n=378) smears, 95.2% (n=360) were negative for p53 expression and remaining (n=18) showed mild (3.7%) to moderate (1.1%) expression. Among HPV16 positive smears p53 expression was negative in 23.8% (20/84) cases and positive in 76.2% (64/84). Amongst the HPV18 positive smears p53 immunoreactivity was 65.5%. Similarly, in NI-HPV cases 59% smears were positive for p53 immunoreactivity (Table 3). Prevalence of moderate to intense expression of p53 was found significantly higher (p<0.001) in HPV positive groups as compared to HPV negative group.

Expression p-gp protein in cervical smears

In cytological normal smears 99% (148/150) cases were negative for p-gp expression. All the CIS cases (15/15) were positive for p-gp expression (Table 2). Among the dysplasia group, 35% (40/114) of LSIL and 84% (53/63) of HSIL cases were positive for p-gp

expression. Only 5.5% cases (10/183) from ASCUS group were showing p-gp expression. Significant increase p-gp expression was found in dysplasia and CIS groups (for mild expression: p<0.001; moderate to intense expression: p<0.001) when compared with normal and ASCUS groups. However, in cervical diseased groups HSIL and CIS cases were showing more positivity for p-gp protein when compared with LSIL group (p<0.05).

Mean intensity of p-gp expression in normal and ASCUS groups was 4.57±1.15 (range 0-12%; median 4.0%) and 7.0±1.85 (range 0-27%; median 8.6%), respectively. In dysplasia groups significant (p<0.001) increase in intensity of p-gp immunoexpression were noted as 12.57±3.50 (range 0-45%; median 10.8%) in LSIL, 26.58±5.36 (range 6-65%; median 22.6%) in HSIL and 30.55±5.69 (range15-80%; median 35%) in CIS group (p<0.001).

Relation between presence of HPV and p-gp immunoexpression

Amongst the HPV negative cases, 96% (362/378) were negative for p-gp expression rest 4% (16/378) was showing positive expression. In the HPV 16 and 18 infected cases 77% (65/84) and 65.5% (19/29) smears were showing positive expression for p-gp, respectively. 20 (59%) cases those infected with other types of HPVs were showing p-gp expression (Table 3). Among HPV positive groups high intensity (moderate to intense expression) of p-gp expression was noted and was statistically significant (p<0.001) in comparison to HPV negative group.

Correlation between p53 and p-gp proteins expression in cervical smear samples

The data for p53 protein expression were analyzed against the data for p-gp protein expression and all the 525 studied subjects were included for statistical analysis. Out of 404 cases with negative p53 expression 403 were also

negative for p-gp expression (99%). In 53 cases with mild expression of p53: 2 cases with no expression, 31 with mild expression and 20 cases with moderate expression of p-gp protein (Table 4). Among the 55 cases with moderate p53 expression 39 cases showed moderate expression and 16 showed mild expression of p-gp. Correlation analysis revealed a highly significant positive correlation ($r=0.92$, $p<0.001$) between p53 and p-gp expression in both cervical dysplasia and cancer stages (Table 4).

Outcome of patients' follow-up

Enrolled cases with ASCUS and dysplasia were clinically followed up to 3 years at 6 (LSIL and ASCUS) and 3 (HSIL) months intervals, in order to study the behavior of disease. Out of these 23 available cases from ASCUS group, 15 cases had smears that returned to normal cytology, 5 cases remained at ASCUS and 3 showed signs of progression to CIN I stage. Seven cases

with no change/progressed samples were positive for presence of HPV and reactivity of p53 and p-gp proteins, however, 1 was positive for p53 and p-gp.

As cases from LSIL group were followed at 6 months of interval up to 30 months of study period, out of 54 available cases, 6 reported to developed CIN II and 23 remained with LSIL in the cytological (CIN I in histopathological) diagnosis. Among progressed/no change cases, 25 cases were positive for p53, p-gp and HPV in their initial study. In 25 LSIL cases that had returned to normal cytology, 17 cases were negative for p53, p-gp and HPV in first study.

In HSIL group, 20 patients were presented for follow-up and rests were undergone for prescribed treatments. Twelve patients out of 20 who were diagnosed with HSIL (CIN II) and were positive for p53, p-gp and HPV remained with CIN II after 3 months of follow-up. Together with these 4 patients were diagnosed with CIS, who were also positive for all studied parameters. Among 4 cases those were negative for studied molecular determinant, 2 patients remained with CIN II and rest 2 showed regression of the disease. Registered CIS cases were not considered for follow-up because all of them were underwent for treatment. In all progressed/no change cases p53 and p-gp expression intensity was ranged from mild to intense grade.

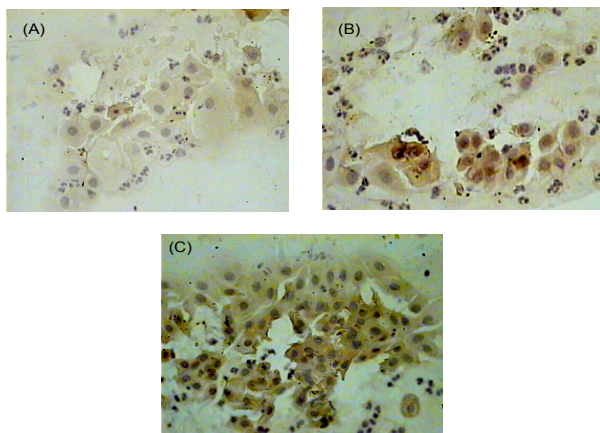


Figure 1. Showing Representative Images of Cervical Smear Cells. Nucleus of cells stained with anti-p53 antibody (magnification: 40X) (A) No staining in normal smear (B) mild staining in mild dysplasia (LSIL/CIN I) smear and (C) intense staining in cells of moderate dysplasia (HSIL/CIN II) smear. LSIL-low grade squamous intraepithelial lesion; HSIL-high grade squamous intraepithelial lesion; CIN-Cervical intraepithelial neoplasia

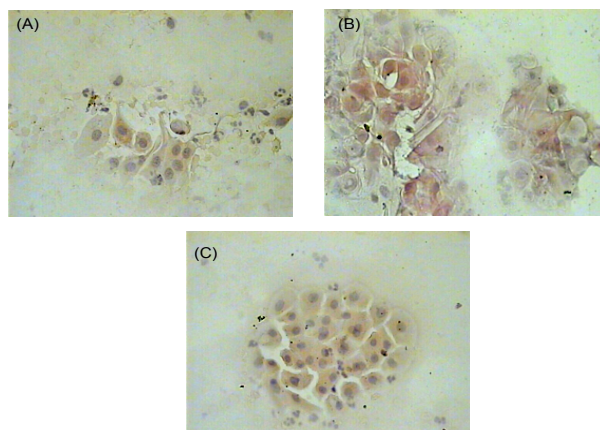


Figure 2. Showing Representative Images of Cervical Smear Cells. Cytoplasm of stained with anti-p-gp antibody (magnification: 40X) (A) No staining in normal smear (B) mild staining in mild dysplasia (LSIL/CIN I) smear and (C) intense staining in cells of moderate dysplasia (HSIL/CIN II) smear. LSIL-low grade squamous intraepithelial lesion; HSIL-high grade squamous intraepithelial lesion; CIN-cervical intraepithelial neoplasia

Discussion

Results of the present study revealed that the immunodetection of p53 and p-gp expression in high-risk HPV infected cervical smears may act as sensitive and non-invasive mean to augment the detection as well as severity of cervical lesion. It also demonstrated that determination of expression pattern of both proteins p53 and p-gp will allow unambiguous identification of truly dysplastic cells and also predict the disease progression state.

In our study, majority of HPV infections were detected in CIS cases (13/15), followed by HSIL (49/63), LSIL (46/114) and ASCUS (27/183). HPV-16 was the most frequently detected HPV sub-type, representing 57% (84/147) of all HPV infections (Table 1). Among HPV-16 and -18 positive samples, majority of cases corresponded to HSIL group (37%) and LSIL group (35%), respectively (Table 1). Similarly in NI-HPV types cases ($n = 34$), most of the cases were from HSIL group ($n=10$) followed by LSIL ($n=13$), which suggested that other HPV types are also involved in progression of SILs. According to earlier reports HPV infection is frequently detectable in SIL and CIS cases (Schlecht et al., 2003; Evans et al., 2006) and HPV-16 and 18 are considered as most aggressive HPV subtypes (Singh et al., 2009). Precursor lesions of the uterine cervix those with oncogenic HPV-16 and 18 infections persist longer and progress more quickly than with non-oncogenic infections or without HPV (Schlecht et al., 2003).

Several biological markers identified in cervical cancer appear to have their diagnostic or prognostic importance. Among these, accumulation of p53 protein has been described as a prognosticator of poor disease outcomes

(Bremer et al., 1995; Huang et al., 2001; Bahnassy et al., 2006). Studies have shown the over-expression of p53 not only in primary and recurrent CIS cases but also in pre-malignant dysplastic lesions (Bremer et al., 1995; Park et al., 1999; Oh et al., 2004; Singh et al., 2009). In this study, both frequency and intensity of p53 expression was gradually increased along with the severity of lesion and was associated with HPV presence (Tables 2 and 3). We noted mild to moderate expression (>10-50%) of p53 in normal (3% cases), ASCUS (5% cases) and LSIL (27% cases) groups. In addition to this over-expression of p53 was noted up to intense grade (>50%) in HSIL and CIS cases (Table 2). It appears from the results that presence of lesion as well as grade both could be characterized by expression intensity of p53 (Table 2). Besides the mutation, inactivation of p53 protein by interaction and complex formation with HPV E6 oncoprotein is suggested as key event of cervical carcinogenesis (Scheffner et al., 1990). In this study association between p53 over-expression and HPV infection was noted (Table 3), confirming the inactivation of p53 protein by complex formation with E6 oncoprotein and subsequent stabilization. Altered expression and inactivation of p53 protein in HPV infected cases is well associated with disease progression (Singh et al., 2009; Oh et al., 2004) and reflects the presence of HPV in cervical cells (Scheffner et al., 1990; Nair et al., 2000), thus, could be a useful parameter for clinical interpretations of HPV presence in low resource hospital settings. Along with these, in some of the HPV negative cases also p53 over-expression was noted in our study (Table 3); this might be evoked via pathways other than HPV infection through gene mutation, hypomethylation or hypermethylation, which suggested that some of the observed cervical preneoplastic and neoplastic lesions could be induced in a heterogeneous way.

In this study we investigated p-gp expression pattern during cervical oncogenesis to assess its role as a biological marker for disease and progression and/or its implication with outcome of disease. It was noted that both positivity and intensity of p-gp expression was increased with grade of lesion as ASCUS followed by dysplasia and dysplasia by CIS (Table 2). A significant difference in terms of p-gp positivity status was observed between LSIL to HSIL ($p < 0.001$), indicating that alteration in p-gp expression in dysplastic lesions may account for innate drug resistance and/or may be an early event in cervical carcinogenesis. Differential immunoeexpression of p-gp protein in normal, dysplastic and malignant lesions has been reported and was associated with lesions aggressiveness, clinicopathologic prognostic factors and efficacy of therapy (Jain et al., 1997; Hayashida et al., 1997; Ralhan et al., 1997; Konishi et al., 1998). Additionally, patients with p-gp positive cervical carcinoma tend to show a lower survival rate (Konishi et al., 1998). The accumulative survival rate in the group positive for p-gp was significantly lower than that in the group negative for p-gp in stage II cervical cancer (Hayashida et al., 1997).

According to several studies co-overexpression of mutant p53 and p-gp is among a series of molecular events resulting in inhibition of apoptosis, more aggressive phenotype, drug resistance and poor prognosis of disease

(Linn et al., 1996; Ralhan et al., 1999). p53 mutation and its accumulation has been shown to activate the *MDR1* promoter (Chin et al., 1992) and correlates with poor response to cisplatin-based chemotherapy (Rusch et al., 1995; Righetti et al., 1996). In that way, p-gp expression observed in a sub set of cervical lesions (ASCUS and dysplastic) and cancer cases in the present study may be a consequence of HPV induced p53 alteration/mutation in these cases. Since this process is dependent on functional state of p53, mutations affecting this gene function could be resulting in to drug resistance among studied cases. Another most important finding from our follow-up study is the notable increase/no change in both p53 and p-gp expression status in progressed cervical lesions as compared with regressed lesions. Besides these, all progressed lesions were co-positive for p53 and p-gp in their initial study and follow-up as well. Earlier it has been reported that p-gp and p53 positivity is associated with innate drug resistance in several other cancers (Wattel et al., 1994; Riou et al., 1995) and their correlation with clinicopathological parameters (Jain et al., 1997; Ralhan et al., 1997; 1999).

Thus, this study indicates that easily measured cellular factors may be important predictors of outcome in patients both undergoing treatment for malignancies as well as participating in cytological screening.

In conclusion, the magnitude of disease progression seen with co-overexpression of p53 and p-gp indicates that these may ultimately be clinically useful for patients being considered for strict follow-up, timely treatment of cervical cancer and also in making treatment decisions. Alternatively, data may indicate a pattern of drug resistance specific for HPV induced cervical cancer in the Indian population. Our findings merit future investigations to evaluate the exact role of p53 and p-gp in conferring resistance to current treatment modalities in cervical cancer.

Acknowledgements

Authors are thankful to Dr. K.C. Gupta, Director Indian Institute of Toxicology Research, Lucknow for his keen interest in the study. Authors are also thankful to Indian Council of Medical Research (India) for providing fellowship to MS.

References

- Bahnassy AA, Zekri AR, Madbouly MS, et al (2006). The correlation between FHIT, P53 and MMR genes in human papillomavirus-associated cervical carcinoma. *J Egypt Natl Canc Inst*, **18**, 191-202.
- Bremer GL, Tieboschb A TMG, Van der putten HWHM, Haan JD, Arends JW (1995). P53 tumor suppressor gene protein expression in cervical cancer: relationship to prognosis. *Eur J Obstet Gynecol Reprod Biol*, **63**, 55-9.
- Canavan TP, Doshi NR (2000). Cervical cancer. *Am Fam Physician*, **61**, 1369-76.
- Chin KV, Ueda K, Pastan I, Gottesman MM (1992). Modulation of activity of the promoter of the human *MDR1* gene by Ras and p53. *Science*, **255**, 459-62.

- Evans MF, Adamson CS, Papillo JL, et al (2006). Distribution of human papillomavirus types in ThinPrep Papanicolaou tests classified according to the Bethesda 2001 terminology and correlations with patient age and biopsy outcomes. *Cancer*, **106**, 1054-64.
- Ferlay J, Bray F, Pisani P, Parkin DM, eds. *Globocan 2002: Cancer Incidence, Mortality, and Prevalence Worldwide, Version 2.0*. Lyon, France: IARC Press; 2004. IARC Cancer Base No. 5.
- Hayashida M, Nakajima H, Ishimaru T, Yamabe T (1997). Immunohistochemical expression of P-glycoprotein in cases of uterine cervical cancer. *Int J Clin Oncol*, **2**, 103-10.
- Helland A, Holm R, Kristensen G, et al (1993). Genetic alterations of the TP53 gene, p53 protein expression and HPV infection in primary cervical carcinomas. *J Pathol*, **171**, 105-14.
- Huang LW, Chou YY, Chao SL, Chen TJ, Lee TTY (2001). p53 and p21 Expression in Precancerous Lesions and Carcinomas of the Uterine Cervix: Overexpression of p53 Predicts Poor Disease Outcome. *Gynecol Oncol*, **83**, 348-54.
- Jain V, Das SN, Luthra K, Shukla NK, Ralhan R (1997). Differential expression of multidrug-resistance-gene product, p-glycoprotein in normal, dysplastic and malignant oral mucosa in India. *Int J Cancer*, **74**, 128-33.
- Johnstone RW, Ruefli AA, Tainton KM, Smyth MJ (2000). A role for P-glycoprotein in regulating cell death. *Leuk Lymphoma*, **38**, 1-11.
- Kent A (2010). HPV Vaccination and Testing. *Reviews in Obstetrics and Gynecology*, **3**, 33-4.
- Konishi I, Nanbu K, Mandai M, et al (1998). Tumor response to neoadjuvant chemotherapy correlates with the expression of P-glycoprotein and PCNA but not GST-pi in the tumor cells of cervical carcinoma. *Gynecol Oncol*, **70**, 365-71.
- Linn SC, Honkoop AH, Hoekman K, et al (1996). p53 and P-glycoprotein are often co-expressed and are associated with poor prognosis in breast cancer. *Br J Cancer*, **74**, 63-8.
- Nair P, Jayaprakash PG, Nair MK, Pillai MR (2000). Telomerase, p53 and human papillomavirus infection in the uterine cervix. *Acta Oncol*, **39**, 65-70.
- Oh MJ, Choi JH, Lee YH, et al (2004). Mutant p53 protein in the serum of patients with cervical carcinoma: correlation with the level of serum epidermal growth factor receptor and prognostic significance. *Cancer Lett*, **203**, 107-12.
- Park CS, Soo IS, Song SY, et al (1999). An immunohistochemical analysis of heat shock protein 70, p53 and estrogen receptor status in carcinoma of the uterine cervix. *Gynecol Oncol*, **74**, 53-60.
- Park YB, Kim HS, Oh JH, et al (2001). The co-expression of p53 protein and P-glycoprotein is correlated to a poor prognosis in osteosarcoma. *Int Orthop*, **24**, 307-10.
- Perego P, Giarola M, Righetti SC, et al (1996). Association between cisplatin resistance and mutation of p53 gene and reduced bax expression in ovarian carcinoma cell systems. *Cancer Res*, **56**, 556-62.
- Pinedo HM, Giaccone G (1995). P-glycoprotein--a marker of cancer-cell behavior. *N Engl J Med*, **333**, 1417-9.
- Ralhan R, Narayan M, Salotra P, Shukla NK, Chauhan SS (1997). Evaluation of P-glycoprotein expression in human oral oncogenesis: correlation with clinicopathological features. *Int J Cancer*, **72**, 728-34.
- Ralhan R, Swain RK, Agarwal S, et al (1999). P-glycoprotein is positively correlated with p53 in human oral pre-malignant and malignant lesions and is associated with poor prognosis. *Int J Cancer*, **84**, 80-5.
- Righetti SC, Della Torre G, Pilotti S, et al (1996). A comparative study of p53 gene mutations, protein accumulation, and response to cisplatin-based chemotherapy in advanced ovarian carcinoma. *Cancer Res*, **56**, 689-93.
- Riou G, Barrois M, Prost S, et al (1995). The p53 and mdm-2 genes in human testicular germ-cell tumors. *Mol Carcinog*, **12**, 124-31.
- Rusch V, Klimstra D, Venkatraman E, et al (1995). Aberrant p53 expression predicts clinical resistance to cisplatin-based chemotherapy in locally advanced non-small cell lung cancer. *Cancer Res*, **55**, 5038-42.
- Sampath J, Sun D, Kidd VJ, et al (2001). Mutant p53 cooperates with ETS and selectively up-regulates human *MDR1* not *MRP1*. *J Biol Chem*, **276**, 39359-67.
- Scheffner M, Werness BA, Huibregste JM, Levin AJ, Howley PM (1990). The E6 oncoprotein encoded papillomavirus types 16 and 18 promotes the degradation of p53. *Cell*, **63**, 1129-36.
- Schlecht NF, Platt RW, Duarte-Franco E, et al (2003). Human papillomavirus infection and time to progression and regression of cervical intraepithelial neoplasia. *J Natl Cancer Inst*, **95**, 1336-43.
- Schneider J, Rubio MP, Barbazan MJ, et al (1994). P-glycoprotein, HER-2/neu, and mutant p53 expression in human gynecologic tumors. *J Natl Cancer Inst*, **86**, 850-55.
- Singh M, Srivastava S, Singh U, Mathur N, Shukla Y (2009). Co-expression of p53 and Bcl-2 proteins in human papillomavirus-induced premalignant lesions of the uterine cervix: correlation with progression to malignancy. *Tumour Biol*, **30**, 276-85.
- Solomon D, Davey D, Kurman R, et al (2002). Forum Group Members; Bethesda 2001 Workshop. The 2001 Bethesda System: terminology for reporting results of cervical cytology. *JAMA*, **287**, 2114-19.
- Stoler MH (2000). Human papillomaviruses and cervical neoplasia: a model for carcinogenesis. *Int J Gynecol Pathol*, **19**, 16-28.
- van den Brule AJ, Snijders PJ, Raaphorst PM, et al (1992). General primer polymerase chain reaction in combination with sequence analysis for identification of potentially novel human papillomavirus genotypes in cervical lesions. *J Clin Microbiol*, **30**, 1716-21.
- Wattel E, Preudhomme C, Hecquet B, et al (1994). p53 mutations are associated with resistance to chemotherapy and short survival in hematologic malignancies. *Blood*, **84**, 3148-57.
- Yakirevich E, Sabo E, Naroditsky I, et al (2006). Multidrug resistance-related phenotype and apoptosis-related protein expression in ovarian serous carcinomas. *Gynecol Oncol*, **100**, 152-9.