

RESEARCH ARTICLE

Cyclooxygenase-2 Expression in Urinary Bladder Transitional Cell Carcinoma and its Association with Clinicopathological Characteristics

Hedieh Moradi Tabriz, Golrokh Olfati*, Seyed Ali Ahmadi, Sudabeh Yusefnia

Abstract

Background: Transitional cell carcinoma (TCC) is the most predominant type of urinary bladder tumor. As cyclooxygenase (COX)-2 is recently introduced as an attractive target molecule in bladder TCC, we evaluated the immunohistochemical expression of this marker and its association with several clinicopathological characteristics. **Materials and Methods:** This cross-sectional study was performed in the Pathology department of Sina Hospital in Tehran, Iran during 2006-2011. Ninety-two paraffin embedded blocks were selected from patients with urinary bladder TCC who underwent cystectomy or transurethral resection (TUR). Then, we assessed COX-2 expression by immunohistochemical staining using antibody against COX-2. Staining in more than 5% of tumor cells was considered as positive expression. **Results:** COX-2 was expressed in 50% of our patients. This marker was markedly expressed in high grade bladder TCC (62.1%) versus other grades and there was statistically a significant difference in COX-2 expression between various grades ($p=0.008$). In addition, patients' age, lymphatic and perineurial invasion were associated with the expression of COX-2 ($p=0.001$, 0.015 and 0.039 , respectively). However, other parameters such as stage, tumor size, venous invasion and lymph node metastasis did not show any significant relationship with this marker (all, $p>0.05$). **Conclusions:** COX-2 was expressed in urinary bladder TCC especially in high grade forms, advocating its probable role in the differentiation of this tumor. Accordingly, COX-2 could be a valuable biological target molecule in the evaluation and treatment of patients with bladder TCC.

Keywords: Cyclooxygenase-2 - urinary bladder - transitional cell carcinoma - immunohistochemistry

Asian Pac J Cancer Prev, 14 (8), 4539-4543

Introduction

Bladder cancer is the ninth most common cancer world-wide (Parkin, 2008) and it is also the fourth frequent one in males in Iran (Sadjadi et al., 2005). Transitional cell carcinoma (TCC) is the most predominant histological type of bladder tumor (Bulbul et al., 2005). Molecular targeted therapy in this tumor has been received more attention in recent years. One of these attractive targets is cyclooxygenase (COX)-2 (Pruthi et al., 2004; Meric et al., 2006).

Cox-2 is a key enzyme in prostaglandins production which is up-regulated in many human tumors such as bladder cancer (Koki and Masferrer, 2002; Pruthi et al., 2004; Meric et al., 2006; Raspollini and Taddei, 2007). It has an important role in cancer initiation and development through the activation of carcinogens, decrease in apoptosis, immunosuppression, angiogenesis and metastasis induction (Pruthi et al., 2004; Meric et al., 2006).

Recently, Cox-2 polymorphism is considered as a risk factor for development and invasion of urinary bladder carcinoma (Gangwar et al., 2011).

COX-2 expression in bladder TCC is reported between 13.6-98% by different studies (Matsuzawa et al., 2002; Eschwege et al., 2003; Gurocak et al., 2006). Some authors also revealed that the expression of this marker was associated with higher grade and stage of bladder tumor (Matsuzawa et al., 2002; Wadhwa et al., 2005; Jang and Lee, 2009). Moreover, several studies suggest the effective role of selective COX-2 inhibitors in human bladder cancer (Pruthi, 2004; Okamoto et al., 2008; Dhawan et al., 2010). Zhu et al. (2012) reviewed the publications about the influence and activation of inflammatory mediators including Cox-2 in bladder cancer and emphasis on the potential role of therapeutic targets. MicroRNAs, such as miR-143 which negatively regulate Cox-2 in urinary bladder cancer are also introduced as a new target for therapeutic modalities (Song et al., 2011).

However, to our knowledge no study has evaluated the expression of COX-2 marker and its association with clinicopathological parameters in bladder cancer in Iran. We therefore plan this study to determine the immunohistochemical expression of this marker in bladder TCC and its relationship with some clinicopathological characteristics especially tumor grade and stage.

Department of Pathology, Sina Hospital, Tehran University of Medical Sciences, Tehran, Iran *For correspondence: dr.olfati@gmail.com

Materials and Methods

Patient selection

Cases were obtained from the surgical pathology archive at Sina Hospital Department of Pathology, Tehran University of Medical Sciences. After reviewing the pathology reports from April 2006 up to April 2011, 92 patients with bladder TCC including 40 cases who had undergone transurethral resection (TUR) and 52 with a history of radical or partial cystectomy were found. Then all their hematoxylin/Eosin-stained slides were re-examined by blinded review to achieve assurance about diagnosis, grade, stage and other histopathological characteristics. We used WHO/International Society of Urological Pathology (WHO/ISUP) classification for tumor grading (Epstein et al., 1998) and pathological T staging (PT, depth of invasion) was also assessed according to American Joint Committee on Cancer (AJCC) Classification (Edge et al., 2010). Finally, the appropriate formalin-fixed paraffin-embedded blocks were selected for immunohistochemical (IHC) study.

Immunohistochemistry

Paraffin-embedded blocks were cut into 3- μ m sections and then mounted on Poly-L-Lysine coated slides. After overnight incubation at 37°C, the specimens were deparaffinized in xylene and rehydrated in a graded series of alcohol. They were washed with phosphate buffered saline (PBS) and then endogenous peroxidase was inactivated by hydrogen peroxide 3% for 30 min. Also, antigen retrieval was done by immersing the slides in 0.01M Tris buffer (PH 9.0) and performing autoclaving for 20 min.

After washing with PBS, the slides were incubated with protein Block serum-free (code X0909, Dako, Denmark) for 10 minutes at room temperature to decrease nonspecific antibody binding.

Monoclonal mouse anti-Human antibody for COX-2 (clone: CX-294, Dako, Denmark) was then applied in a dilution of 1:100 for 1 hour. After washing with PBS, for staining detection, slides incubated with peroxidase-conjugated Envision Dual link reagent (Rabbit/mouse. Horseradish peroxidase, code K4061, DAKO, Denmark) for 30 min. We also used diaminobenzidine as a chromogen for color development. Finally, the sections were counterstained with hematoxylin. As a positive control, colonic adenocarcinoma was used in each run. For negative controls, we omitted anti-COX-2 antibody.

All slides were reviewed by light microscopy, independently by two experienced pathologists in blinded fashion. The specimens were considered as COX-2 positive if at least 5% of tumor cells revealed light brown cytoplasmic immunostaining (Shirahama, 2000; 2001; Kim et al., 2002; Wadhwa et al., 2005; Jang and Lee, 2009).

Statistical analysis

We analyzed our results by using Pearson's Chi-square, Fisher exact test and t-test (performed with SPSS software, Version 17.0). We considered $p < 0.05$ as a statistically significant value.

Results

Ninety-two patients with definite diagnosis of urinary bladder TCC were evaluated. The patients mean age (\pm SD) was 62.7 (\pm 12.5) years ranging from 33 to 106 years. There were 86 males (93.5%) and 6 females (6.5%). Of all 92 patients, 46 (50%) underwent radical cystectomy, 6 (6.5%) had a history of partial cystectomy and TUR had been performed on 40 (43.5%). Overall, COX-2 positive immunoreactivity was 50% (46/92).

The patients mean age (\pm SD) in COX-2 positive specimens was 66.7 (\pm 12.6) years and in the other group with COX-2 negative immunoreactivity was 58.6 (\pm 11) years. There was a statistically significant difference between the above groups ($p=0.001$).

There was no significant relationship between sex of the patients and COX-2 expression ($p=0.677$).

Positive immunoreactivity for COX-2 among patients with radical cystectomy, partial cystectomy and TUR group was 47.8%, 50% and 52.5%, respectively. COX-2 expression was not associated with the type of surgery ($p=0.945$).

We also assessed the size of tumor. The tumor mean size was 4.2 (\pm 2.01) cm. The tumor mean size was 4.4 (\pm 2.27) cm in COX-2 positive specimens versus 4.16 (\pm 1.8) cm in COX-2 negative ones. No statistically significant association was seen between the tumor size and COX-2 expression ($p=0.632$).

We summarized several pathological characteristics of the tumor in association with COX-2 expression in Table 1.

As shown in Table 1, a statistically significant

Table 1. Cyclooxygenase-2 Expression in Urinary Bladder Transitional Cell Carcinoma and its Association with Clinicopathological Characteristics

Characteristic		No. Pts (%)	COX-2 expression		p value ^a
			Positive No (%)	Negative No (%)	
Grade	Punlmp	10 (10.9)	4 (40)	6 (60)	
	Low	24 (26.1)	6 (25)	18 (75)	
Stage	High	58 (63)	36 (62.1)	22 (37.9)	0.008
	Ta	11 (12)	4 (36.4)	7 (63.6)	
	T1	31 (33.7)	14 (45.2)	17 (54.8)	
	T2a	13 (14.1)	7 (53.8)	6 (46.2)	
	T2b	12 (13.0)	8 (66.7)	4 (33.3)	
	T3a	11 (12.0)	5 (45.5)	6 (54.5)	
	T3b	6 (6.5)	5 (83.3)	1 (16.7)	
	T4a	7 (7.6)	3 (42.9)	4 (57.1)	
	T4b	1 (1.1)	0 (0)	1 (100)	0.513
	Ta-T1	42 (45.7)	18 (42.9)	24 (57.1)	
Multiplicity ^b	T2a-T4b	50 (54.3)	28 (56)	22 (44)	0.209
	Yes	17 (32.7)	7 (41.2)	10 (58.8)	
Venous invasion	No	35 (67.3)	18 (51.4)	17 (48.6)	0.488
	Yes	17 (18.5)	11 (64.7)	6 (35.3)	
Lymphatic invasion	No	75 (81.5)	35 (46.7)	40 (53.3)	0.179
	Yes	31 (33.7)	21 (67.7)	10 (32.3)	
Perineurial invasion	No	61 (66.3)	25 (41)	36 (59)	0.015
	Yes	27 (29.3)	18 (66.7)	9 (33.3)	
Lymph node ^{b,c} metastasis	No	65 (70.7)	28 (43.1)	37 (56.9)	0.039
	Yes	12 (30)	8 (66.7)	4 (33.3)	
	No	28 (70)	11 (39.3)	17 (60.7)	0.112

*PUNLMP: Papillary Urothelial Neoplasm of Low Malignant Potential, ^acalculated by Chi-square and Fisher exact tests, ^bOnly assessed in cystectomy specimens, ^cLymph node was not available in 12 patients

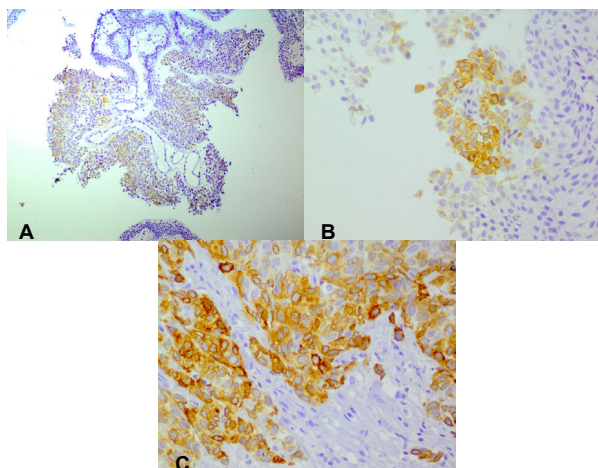


Figure 1. Positive immunohistochemical staining of COX-2. A) Papillary urothelial neoplasm of low malignant potential ($\times 100$); B) Low grade papillary urothelial carcinoma ($\times 400$) and; C) High grade papillary urothelial carcinoma ($\times 400$)

difference was observed between different grades of the urinary bladder TCC ($p=0.008$). High grade tumors revealed a higher expression of COX-2 (62.1%) versus other grades.

Figure 1 shows positive COX-2 immunoreactivity in various grades of urinary bladder TCC.

In contrast, no significant association was detected between COX-2 expression and individual stages from Ta to T4b ($p=0.513$). When we compared muscle-invasive tumors (T2a-T4b) to non-muscle invasive ones (Ta-T1), there was also no statistical difference in COX-2 expression ($p=0.209$).

Although, lymphatic and perineurial invasion showed a statistically significant association with COX-2 expression ($p=0.015$ and 0.039 respectively). The other pathological parameters including multicentricity, venous invasion and lymph node metastasis were not associated with this marker (all $p>0.05$, Table 1).

Discussion

COX-2 has been introduced in recent years as a novel target in many human tumors such as bladder cancer (Koki and Masferrer, 2002; Pruthi et al., 2004; Meric et al., 2006; Raspollini et al., 2007). Several studies have been performed to assess the association of this marker with clinicopathological characteristics in bladder cancer (Shirahama et al., 2001; Shariat et al., 2003a; 2003b; Wulfing et al., 2004; Gurocak et al., 2006; Margulis et al., 2007). In the current study, we found COX-2 expression in 50% of our patients which is in range of the previous reports (Matsuzawa et al., 2002; Eschwege et al., 2003; Gurocak et al., 2006). Moreover; we demonstrated the marked association between COX-2 expression and patients' age, tumor grade, lymphatic and perineurial invasion.

In accordance with some of the past studies (Komhoff et al., 2000; Matsuzawa et al., 2002; Wadhwa et al., 2005; Yulizar et al., 2008; Jang and Lee, 2009), we found that COX-2 expression was markedly related to the grade of bladder tumor. In the present study COX-2 expression

was seen in 62.1% of high grade tumors in comparison with the other grades but not in a gradual increase pattern from Low Malignant Potential (LMP) to high grade. Higher expression of COX-2 in LMP grade (40%) versus low grade (25%) may be due to the limited number of our patients in LMP group. Matsuzawa and colleagues reported COX-2 expression in 98% of the patients with urinary bladder TCC (Matsuzawa et al., 2002). In their study, a significant correlation between COX-2 expression and tumor grade was detected with an increased expression in a stepwise manner from grade 1 to 3. Furthermore; Wadhwa and associates found that degree of COX-2 expression correlated with the grade of bladder TCC (Wadhwa et al., 2005). Similarly, Jang and colleagues demonstrated COX-2 expression in 15% and 72% of the low grade and high grade bladder TCCs respectively and they revealed a closed correlation between COX-2 expression and tumor differentiation like our study (Jang and Lee, 2009). Komhoff and associates also detected COX-2 expression in 38% of the high grade bladder TCCs. However, they did not find this marker in low grade ones (Komhoff et al., 2000).

In another study by comparing low grade and high grade bladder carcinomas in COX-2 expression, they found a significant difference between two groups (Yulizar et al., 2008).

On the other hand, other observations did not confirm any association between COX-2 expression and grade in bladder TCC (Ristimaki et al., 2001; Shirahama et al., 2001; 2003a; 2003b; Wulfing et al., 2004; Margulis et al., 2007). These contradictory results could be related to different causes such as limited number of cases or just selecting invasive bladder TCCs with grade 2 and 3 (Yamada et al., 2008; Naruse et al., 2010).

Our study failed to show any association between COX-2 expression and any individual pathological stages (Ta-T4b). This finding is consistent with some previous studies (Komhoff et al., 2000; Wulfing et al., 2004; Yamada et al., 2008; Naruse et al., 2010) and incompatible with the others (Matsuzawa et al., 2002; Shariat et al., 2003b; Wadhwa et al., 2005; Gurocak et al., 2006; Margulis et al., 2007; Jang and Lee, 2009). We also investigated whether there was any difference between muscle invasive tumors ($\geq P$ T2) and non-muscle invasive ones (Ta-T1) in the expression of COX-2, but we did not find any significant difference. This result is opposed to some past reports (Shirahama, 2000; Matsuzawa et al., 2002; Shariat et al., 2003b; Jang and Lee, 2009; Mohamed and Mohamed, 2012). However, similar to our study, Ristimaki et al. (2001) did not detect any significant difference in the rate of COX-2 positivity between invasive and noninvasive bladder TCCs.

Along with considering different stages and grades of the bladder tumor, we also assessed several clinicopathological characteristics in association with COX-2 expression. To our knowledge, none of the previous studies reported age as a parameter associated with COX-2. In our study, there is a significant difference between the mean age of COX-2 negative and positive patients. However, because of their age range fall and numerical proximity, this difference should have little

or no pathological significance. We further showed that both lymphatic and perineurial invasion were significantly related to COX-2 expression. Although we did not find any previous report about perineurial invasion and COX-2 in our searches, there were few studies supporting our finding on the association between lymphatic invasion and COX-2 positivity (Shirahama et al., 2001; Margulis et al., 2007). However, the others did not confirm it (Shariat et al., 2003a; 2003b; Gurocak et al., 2006). In the present study, no association was detected between lymph node metastasis and COX-2 expression in accordance with some previous reports (Shirahama et al., 2001; Shariat et al., 2003b; Wulfing et al., 2004), although two studies found this correlation (Margulis et al., 2007; Naruse et al., 2010).

We also have some limitations in our study including the low number of patients in LMP category and the absence of cases with Insitu carcinoma. In addition, because of our restrictions; we could not follow up the patients.

Overall, the mentioned discrepancies in findings of several studies may be related to different sample sizes, selection of different cut off values for COX-2 expression, applying different antibodies and technical methods and the use of different criteria for classification of clinicopathological parameters.

In conclusion, as our study showed, COX-2 was expressed in bladder TCC, especially high grade forms which reveals that this marker can be involved in tumor differentiation and may be induced in high grade bladder TCC; however this need to be confirmed by further follow up studies. Higher COX-2 expression which was detected in specimens with perineurial and lymphatic invasion also supported the role of this marker in cell motility and invasion via down-modulation of some adhesion molecules and activation of matrix metalloproteinases (Pruthi et al., 2004; Meric et al., 2006). According to the expression of COX-2 in our patients and the previous reports on the effective role of selective COX-2 inhibitors in human bladder cancer (Pruthi et al., 2004; Okamoto et al., 2008; Dhawan et al., 2010), this marker could be a valuable biological target in the evaluation and treatment of patients with bladder TCC.

Acknowledgements

This research has been done as Residency thesis and was supported by Tehran University of Medical Sciences; the grant number is 89-10459.

References

- Bulbul MA, Husseini N, Houjaji A (2005). Superficial bladder cancer epidemiology, diagnosis and management. *J Med Liban*, **53**, 107-13.
- Dhawan D, Craig BA, Cheng L, et al (2010). Effects of short-term celecoxib treatment in patients with invasive transitional cell carcinoma of the urinary bladder. *Mol Cancer Ther*, **9**, 1371-7.
- Edge SB, Byrd DR, Compton CC, et al (2010). AJCC cancer staging manual, 7th ed., Springer, New York, 497-50.
- Epstein JI, Amin MB, Reuter VR, Mostofi FK (1998). The world Health Organization/International Society of Urological Pathology consensus classification of urothelial (transitional cell) neoplasms of the urinary bladder. Bladder Consensus Conference Committee. *Am J Surg Pathol*, **22**, 1435-48.
- Eschwege P, Ferlicot S, Droupy S, et al (2003). A histopathologic investigation of PGE (2) pathways as predictors of proliferation and invasion in urothelial carcinomas of the bladder. *Eur Urol*, **44**, 435-41.
- Gangwar R, Mandhani A, Mittal RD (2011). Functional polymorphisms of cyclooxygenase-2 (COX-2) gene and risk for urinary bladder cancer in North India. *Surgery*, **149**, 126-34.
- Gurocak S, Sozen S, Erdem O, et al (2006). Relation between cyclooxygenase-2 expression and clinicopathologic parameters with patient prognosis in transitional cell carcinoma of the bladder. *Urol Int*, **76**, 51-6.
- Jang TJ, Lee KS (2009). The expression of cyclooxygenase-2 and survivin in urinary bladder transitional cell carcinoma. *Korean J Pathol*, **43**, 206-11.
- Kim SI, Kwon SM, Kim YS, Hong SJ (2002). Association of cyclooxygenase-2 expression with prognosis of stage T1 grade 3 bladder cancer. *Urology*, **60**, 816-21.
- Koki AT, Masferrer JL (2002). Celecoxib: a specific cox-2 inhibitor with anticancer properties. *Cancer Control*, **9**, 28-35.
- Komhoff M, Guan Y, Shappell HW, et al (2000). Enhanced expression of cyclooxygenase-2 in high grade human transitional cell bladder carcinomas. *Am J Pathol*, **157**, 29-35.
- Margulis V, Shariat SF, Ashfaq R, et al (2007). Expression of cyclooxygenase-2 in normal urothelium, and superficial and advanced transitional cell carcinoma of the bladder. *J Urol*, **177**, 1163-8.
- Matsuzawa I, Kondo Y, Kimura G, et al (2002). Cyclooxygenase-2 expression and relationship to malignant potential in human bladder cancer. *J Health Sci*, **48**, 42-7.
- Meric JB, Rottey S, Olausson K, et al (2006). Cyclooxygenase-2 as a target for anticancer drug development. *Crit Rev Oncol Hematol*, **59**, 51-64.
- Mohamed SF, Mohamed HAD (2012). The expression of cyclooxygenase-2 and survivin in urinary bladder transitional cell carcinoma. *Egypt J Pathol*, **32**, 150-4
- Naruse K, Yamada Y, Nakamura K, et al (2010). Potential of molecular targeted therapy of HER-2 and COX-2 for invasive transitional cell carcinoma of the urinary bladder. *Oncol Rep*, **23**, 1577-83.
- Okamoto A, Shirakawa T, Bito T, et al (2008). Etodolac, a selective cyclooxygenase-2 inhibitor, induces upregulation of E-Cadherin and has antitumor effect on human bladder cancer cells *in vitro* and *in vivo*. *Urology*, **71**, 156-60.
- Parkin DM (2008). The global burden of urinary bladder cancer. *Scand J Urol Nephrol Suppl*, **218**, 12-20.
- Pruthi RS, Derksen E, Gaston K, Wallen EM (2004). Rationale for use of cyclooxygenase-2 inhibitors in prevention and treatment of bladder cancer. *Urology*, **64**, 637-42.
- Raspollini MR, Taddei GL (2007). Cyclooxygenase -2: a novel target in human solid tumors. *Curr Oncol Rep*, **9**, 96-101.
- Ristimaki A, Nieminen O, Saukkonen K, et al (2001). Expression of cyclooxygenase-2 in human transitional cell carcinoma of the urinary bladder. *Am J Pathol*, **158**, 849-53.
- Sadjadi A, Nouraie M, Mohagheghi M, et al (2005). Cancer Occurrence in Iran in 2002, an International Perspective. *Asian Pac J Cancer Prev*, **6**, 359-63.
- Shariat SF, Kim JH, Ayala GE, et al (2003a). Cyclooxygenase-2 is highly expressed in carcinoma in situ and T1 transitional cell carcinoma of the bladder. *J Urol*, **169**, 938-42.
- Shariat SF, Matsumoto K, Kim J, et al (2003b). Correlation

- of cyclooxygenase-2 expression with molecular markers, pathological features and clinical outcome of transitional cell carcinoma of the bladder. *J Urol*, **170**, 985-9.
- Shirahama T (2000). Cyclooxygenase-2 expression is up-regulated in transitional cell carcinoma and its preneoplastic lesions in the human urinary bladder. *Clin Cancer Res*, **6**, 2424-30.
- Shirahama T, Arima J, Akiba S, Sakakura C (2001). Relation between cyclooxygenase-2 expression and tumor invasiveness and patient survival in transitional cell carcinoma of the urinary bladder. *Cancer*, **92**, 188-93.
- Song T, Zhang X, Wang C, et al (2011). Expression of miR-143 reduces growth and migration of human bladder carcinoma cells by targeting cyclooxygenase-2. *Asian Pac J Cancer Prev*, **12**, 929-33.
- Wadhwa P, Goswami AK, Joshi K, Sharma SK (2005). Cyclooxygenase -2 expression increases with the stage and grade in transitional cell carcinoma of the urinary bladder. *Int Urol Nephrol*, **37**, 47-53.
- Wulfing C, Eltze E, Von Struensee D, et al (2004). Cyclooxygenase-2 expression in bladder cancer : correlation with poor outcome after chemotherapy. *Eur Urol*, **45**, 46-52.
- Yamada Y, Nakamura K, Inoue Y, et al (2008). Cyclooxygenase-2 expression in invasive transitional cell carcinoma of the urinary bladder. *Mol Med Report*, **1**, 791-5.
- Yulizar DR, Hardjowijoto S, Djatisoesanto W, Soemarno T (2008). Difference in cyclooxygenase-2 (COX-2) expression between low and high grade papillary carcinoma in human bladder cancer. *Folia Medica Indonesiana*, **44**, 71-5.
- Zhu Z, Shen Z, Xu C (2012). Inflammatory pathways as promising targets to increase chemotherapy response in bladder cancer. *Mediators Inflamm*, **528690**, 11.