

## RESEARCH ARTICLE

# Two-Week Combination Chemotherapy with Gemcitabine, High-Dose Folinic Acid and 5 Fluorouracil (GEMFUFOL) as First-Line Treatment of Metastatic Biliary Tract Cancers

Olcun Umit Unal<sup>1\*</sup>, Ilhan Oztop<sup>2</sup>, Ilkay Tugba Unek<sup>3</sup>, Ahmet Ugur Yilmaz<sup>4</sup>

### Abstract

**Background:** The aim of this study was to evaluate the efficacy and tolerability of a gemcitabine, 5-fluorouracil and leucovorin (GEMFUFOL) chemotherapy regimen as first line treatment of metastatic biliary tract cancer. **Materials and Methods:** All patients received folinic acid 400 mg/m<sup>2</sup> on day 1, 5-fluorouracil bolus 400 mg/m<sup>2</sup> on day 1, IV infusion of 5-fluorouracil 2400 mg/m<sup>2</sup> over 46 hours, and gemcitabine 1250 mg/m<sup>2</sup> on day 1. **Results:** A total of 29 patients with metastatic biliary tract cancer received GEMFUFOL regimen as the first-line treatment. The mean follow-up was 22.1 months (95% CI, 12.5-31.8). One patient (3.4%) achieved complete response, 5 (17.2%) had partial response, and 4 (13.8%) had stable disease. The median progression-free survival was 3.3 months (95% CI, 2.9-3.7), and the median overall survival was 8.8 months (95% CI, 3.5-14). The 1-year and 2-year survival rates were 58.6% and 30%, respectively. Grade 3 and 4 toxicity included neutropenia in 4 patients (13.7%), thrombocytopenia in 2 (6.8%), anemia in 2 (6.8%), and alopecia in 1 (3.4%). Two patients (6.8%) developed febrile neutropenia. A dose reduction was achieved in 8 patients (27.6%) while 5 patients had extended-interval dosage (17.2%) for toxicity. **Conclusions:** The GEMFUFOL chemotherapy regimen was generally efficacious and tolerable as a first-line treatment of metastatic biliary tract cancer.

**Keywords:** Metastatic biliary tract cancer - gemcitabine - 5-fluorouracil - high-dose folinic acid

*Asian Pac J Cancer Prev*, 14 (9), 5263-5267

### Introduction

Although biliary tract cancers are rarely seen tumors, they have a higher rate of mortality. While resection represents the curative therapeutic option, less than 25% of patients are likely to undergo resection (Hamdani et al., 2012; Tan et al., 2013). Otherwise, most of the patients present with unresectable or metastatic disease. Palliative chemotherapy is used for advanced disease with a median survival of 3 to 6 months.

Biliary tract cancers are a heterogeneous group of malignancies, consisting of two main groups: gallbladder cancers and bile duct cancers. Bile duct cancers are further divided into two groups: intrahepatic and extrahepatic bile duct cancers. Gallbladder and bile duct cancers are distinctive both in clinical behavior and molecular traits (Qu et al., 2012; Kameda et al., 2013), which leads to challenges in evaluation of the efficacy of chemotherapeutic regimens used, and stratification in randomized trials. A meta-analysis of 104 chemotherapy studies reported that gallbladder and bile duct cancers showed a distinctive response to the treatment (34.4% and 20.2%, respectively), however the higher response seen in gall bladder cancers were not reflected in the survival (the median survival, 7.2 and 9.3 months, respectively,

p=0.048) (Eckel and Schmid, 2007). These results were further supported by a retrospective study in Japan (Yonemoto et al., 2007).

A standard approach is difficult in this group of patients with biliary tract cancers as both they are rare malignancies and there is a restricted number of randomized studies for their treatment. It has been reported in the literature that several chemotherapeutic agents, mainly 5-fluorouracil and gemcitabine are administered either as monotherapy or as combination therapy. When compared with the best supportive care, fluoropyrimidine-based therapy was reported to both prolong survival and improve quality of life (Glimelius et al., 1996). A randomised phase II study showed that in patients with biliary tract cancer, combination of cisplatin and 5-fluorouracil achieved better outcomes both in response rate and median survival compared to 5-fluorouracil alone, but this superiority didn't reach statistical significance (18.5% vs 7.1% and 8.0 vs 5.0 months, respectively) (Ducreux et al., 2005). Similarly, a recent large randomized study (UK ABC-02) compared the cisplatin/gemcitabine combination with gemcitabine alone in advanced disease/metastatic biliary tract cancers, and reported favorable response and survival advantage for the combination arm (24% vs 15 and 11.7 vs 8.3 months, respectively, p=0.002) (Valle et al., 2010).

Department of Medical Oncology, <sup>1</sup>Medical Faculty, Ataturk University, Erzurum, <sup>2</sup>Medical Faculty, Dokuz Eylul University, <sup>3</sup>Tepecik Education and Research Hospital, <sup>4</sup>Medical Faculty, Izmir University, Izmir, Turkey \*For correspondence: drolcun@hotmail.com

Although there is no randomised study to show the efficacy of combination of 5-fluorouracil and gemcitabine in metastatic biliary tract cancers, it has been established as an effective regimen used for pancreatic cancer. Furthermore, it has been reported that combination of gemcitabine with capecitabine had better outcomes compared to gemcitabine alone in metastatic pancreatic cancer (HR: 0.8,  $p=0.026$ ) (Cunningham et al., 2005). A meta-analysis of 112 non-randomized studies by Eckel and Schmid (2007) that was published in 2007 found that gemcitabine combined with 5 fluorouracil and/or platinum compounds showed a higher response rate.

Gemcitabine, which is a pyrimidine analogue, is an antimetabolite chemotherapeutic agent, and it is metabolized intracellularly by nucleoside kinases to the active diphosphates and triphosphates. Gemcitabine exerts a cytotoxic effect on DNA through diphosphates and triphosphates (Gesta et al., 2012). In addition, gemcitabine combined with 5-fluorouracil displays *in vivo* and *in vitro* synergistic activity. Gemcitabine enhances the inhibition of thymidylate synthase, resulting in increased efficacy of 5-fluorouracil. On the other hand, modulation of 5-fluorouracil by folinic acid potentiates the antitumor activity of 5-fluorouracil (Kim et al., 2013). Therefore, combination of gemcitabine with fluoropyrimidines represents one of the ideal combination chemotherapy regimens.

The objective of present study was to evaluate efficacy and tolerability of gemcitabine combined with infusional 5- fluorouracil and high-dose folinic acid (GEMFUFOL) in treatment of metastatic biliary tract cancers.

## Materials and Methods

A total of 29 patients who received GEMFUFOL as first-line treatment for diagnosis of metastatic biliary tract cancer at the Medical Oncology Department of the Medical Faculty of Dokuz Eylul University between June 2007 and December 2012 were enrolled in this study for retrospective analysis. Biliary tract cancers included gallbladder and bile duct cancers. All patients had measurable lesions. The inclusion criteria were as follows: ECOG performance status  $\leq 2$ ; age  $\geq 18$  years; absence of another organ malignity (all skin cancers excluded except for melanoma) and uncontrollable medical condition; adequate bone marrow reserves (PLT  $> 100.000/mm^3$ , neutrophils  $> 1500/mm^3$ , leucocytes  $> 4000/mm^3$ ); liver function tests (AST and ALT should be less than 3 times the upper limit of normal and total bilirubin  $< 2$  mg/dl); and a creatinine clearance above 50 ml/min.

### Treatment regimen

All patients received the GEMFUFOL regimen, consisting of intravenous infusion of gemcitabine 1250 mg/m<sup>2</sup> for 30 minutes on day 1, infusion of folinic acid 400 mg/m<sup>2</sup> for 2 hours on day 1, 5-fluorouracil bolus 400 mg/m<sup>2</sup> on day 1, and IV infusion of 5-fluorouracil 2400 mg/m<sup>2</sup> over 46 hours. Each chemotherapy cycle was repeated every two weeks. The routine prophylactic granulocyte colony stimulating factor was not used. A 5-HT<sub>3</sub> receptor antagonist (granisetron or palonosetron) was used as

antiemetic prophylaxis. All infusions were administered through the central venous port. The treatment was continued until patient's withdrawal, disease progression or unacceptable toxicity. All patients were informed about the treatment.

### Assessment of efficacy and toxicity

The efficacy of treatment was assessed at cycle 6 using a thoracic and abdominal computed tomography. The responses were evaluated according to the Response Evaluation Criteria published by the World Health Organization (WHO), and toxicity was evaluated and graded according to the NCI-CTC version 3.0. The dose of chemotherapy was reduced by 25% in subsequent cycles in case of Grade 3-4 toxicities except for alopecia. The chemotherapy cycle was postponed by one week in cases where laboratory work prior to each cycle showed Hb  $< 10$ gr/dl or PLT  $< 100.000/mm^3$  or Neutrophils  $< 1500/mm^3$ .

### Statistical analysis

Statistical analysis was made using the software SPSS 15.0. The progression-free survival (PFS) was calculated based on the period from the first day of chemotherapy cycle to the progression. The overall survival (OS) was calculated based on the period from the first day of chemotherapy to the last visit or exitus. The overall survival and PFS were evaluated by the Kaplan-Meier method.

## Results

### Patient characteristics

A total of 29 patients with metastatic biliary tract cancer received the GEMFUFOL regimen as first-line treatment. The male-female ratio was 18/11, and the median age was 58 years. None of the patients had received prior chemotherapy for metastatic disease, but 12 patients had received adjuvant chemotherapy (5-fluorouracil-based). In patients who had received adjuvant treatment, the time from the last adjuvant chemotherapy was more than 6 months. The tumor was localized in the gallbladder in 9

**Table 1. Patient Characteristics**

Total		29
Sex	Male	18 (62.1%)
	Female	11 (37.9%)
Age (median, interquartile range)		58 (35-74)
ECOG performance score	0	9 (31%)
	1	10 (34.5%)
	2	10 (34.5%)
Stage	Metastatic disease	29 (100%)
Histopathological type	Adenocarcinoma	29 (100%)
Initial diagnostic stage	1	2 (6.9%)
	2	7 (24.1%)
	3	2 (6.9%)
	4	18 (62.1%)
Primary tumor site	Gall bladder	9 (31%)
	Biliary tract	9 (31%)
	Ampulla of Vater	11 (38%)
Number of metastases	1	14
	2	13
	3	2

\*ECOG=Eastern Cooperative Oncology Group

patients (31%), and in the bile duct in 20 patients (69%). The most common sites of metastasis were liver, lung and peritoneum, respectively. The patient characteristics are shown in Table 1 in detail.

#### Efficacy and survival

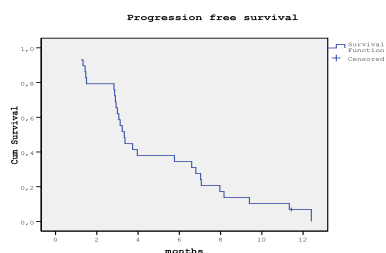
The mean follow-up was 22.1 months (95%CI, 12.5-31.8). One patient (3.4%) achieved complete response, 5 patients (17.2%) had partial response, and 4 patients (13.8%) had stable disease. The total clinical benefit was observed in 10 patients (34.5%). Nineteen patients (65.5%) had progressive response. The median progression-free survival was 3.3 months (95%CI, 2.9-3.7) (Figure 1), and the median overall survival was 8.8 months (95%CI, 3.5-14) (Figure 2). The 1-year and 2-year survival rates were 58.6% and 30%, respectively.

#### Toxicity

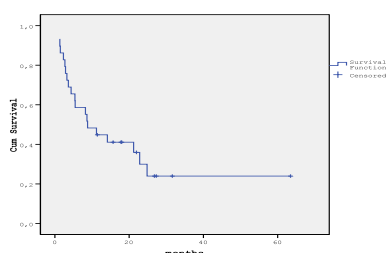
The total number of cycles of chemotherapy administered was 217. The median number of chemotherapy cycles was 7.4 (range, 2-18). The most common Grade 3-4 toxicity was hematologic toxicity, including neutropenia as the most common one, and 2 patients (6.8%) developed febrile neutropenia. Fatigue and nausea were among the most common non-hematological toxicities. A dose reduction was achieved in 8 patients (27.6%) due to Grade 3-4 toxicity while 5 patients (17.2%) extended the interval between the chemotherapy cycles.

**Table 2 Toxicity (N=29)**

Toxicity		Grades	
		All	3 and 4
		n (%)	n (%)
Hematologic toxicity	Neutropenia	9 (31%)	4 (13.8%)
	Thrombocytopenia	7 (24.1%)	2 (6.8%)
	Anemia	17 (58.6%)	2 (6.8%)
Non-hematologic toxicity	Fatigue	11 (37.9%)	0
	Nausea	5 (17.2%)	0
	Elevated liver enzyme	3 (10.3%)	0
	Diarrhea	2 (6.8%)	0
	Mucositis	2 (6.8%)	0
	Alopecia	1 (3.4%)	1 (3.4%)
	Hand-foot syndrome	1 (3.4%)	0



**Figure 1. Mean Progression Free Survival Curve of the Patients**



**Figure 2. Mean Survival Curve of the Patients**

No toxic death was observed. Chemotherapy-associated toxicities are shown in Table 2 in detail.

## Discussion

This retrospective study evaluated the efficacy and tolerability of the GEMFUFOL chemotherapy as first-line treatment in 29 patients with metastatic biliary tract cancer. One patient (3.4%) achieved complete response, 5 patients (17.2%) had partial response, and 4 patients (13.8%) had stable disease, with a total clinical benefit of 34.5%.

At present, there is no established standard chemotherapy regimen for advanced biliary tract cancers. In general, gemcitabine, 5-fluorouracil and cisplatin are used as monotherapy or in combination depending on the performance status and organ functions of the patient. The response rates to 5-fluorouracil, when used as single agent bolus or in prior combination studies, range from 0-34% (Falkson et al., 1984; Harvey et al., 1984; Kajanti et al., 1994; Gebbia et al., 1996; Croitoru et al., 2012). On the other hand, infusional schemes of 5-fluorouracil were shown to have higher response rates in biliary tract cancers (Chen et al., 1998; Lim et al., 2012). Additionally, it has been reported that the infusional schemes of 5-fluorouracil had a more advantageous side effect profile, and they were better tolerated than bolus administration.

Gemcitabine represents a milestone in the treatment of pancreatic and biliary tract cancers, which share a common embryonic origin. The response rate to gemcitabine as a single agent in biliary tract cancers ranges from 7-27% (Park et al., 2005; Valle et al., 2009; Suzuki et al., 2010; Valle et al., 2010). Phase II studies reported that gemcitabine combined with an oral fluoropyrimidine, capecitabine or S1, provided promising results (response rate, 25-34% and median survival, 11.6-14.0 months) (Cho et al., 2005; Sasaki et al., 2010; Kanai et al., 2011; Santini et al., 2012). The UK ABC-02 trial made comparison between a combination of cisplatin and gemcitabine and gemcitabine alone in biliary tract cancers, and reported that the response rate and survival rate were in favor of the combination arm (24% vs 15% and 11.7 vs 8.3 months,  $p=0.002$ ). Furthermore, when gemcitabine was combined with cisplatin, the clinical benefit rate was increased from 71-81% (Valle et al., 2010). However, there is no study to show whether gemcitabine combined with platinum or 5-fluorouracil would provide more benefit.

No study of gemcitabine combined with 5-fluorouracil modulated by high-dose folinic acid in metastatic biliary tract cancers called our attention in the literature. Recently, a randomized study by Sharma et al. (2010) compared modified gemcitabine/oxaliplatin/5-fluorouracil/folinic acid combination with the best supportive care in unresectable gall bladder cancer, and showed that the response, PFS and OS rates were in favor of chemotherapy (Sharma et al., 2010). It was also indicated that chemotherapy reduced episodes of obstructive jaundice and cholangitis. In this study, the treatment included maximum 6 cycles of 5-fluorouracil 425 mg/m<sup>2</sup> and folinic acid 20 mg/m<sup>2</sup> administered as intravenous bolus weekly, gemcitabine 900 mg/m<sup>2</sup> and oxaliplatin 80 mg/m<sup>2</sup> on days 1 and 8, every three weeks. A study by Wagner

et al. (2009) investigated the efficacy of gemcitabine/oxaliplatin/5-fluorouracil combination in advanced gall bladder and bile duct cancers, and showed a response rate of 19% and 23%, and a median survival of 9.9 months and 10.0 months, respectively, however indicated that the triple-drug regimen was more toxic. In this study, the treatment included gemcitabine 900 mg/m<sup>2</sup> over 30 min, oxaliplatin (65 mg/m<sup>2</sup>) and 5-fluorouracil 1500 mg/m<sup>2</sup> over 24 h on days 1 and 8 every 21 days 1. In the present study, 5-fluorouracil was administered as a 46-hour infusion. We inspired it from the de Gramont regimen that has been widely used for treatment of colorectal cancers, and obtained the GEMFUFOL regimen combining with gemcitabine. Apart from these studies, two studies combining capecitabine, an oral fluoropyrimidine resembling the infusional 5-fluorouracil both in efficacy and toxicity, and gemcitabine reported that the combination was efficacious and well-tolerated (Cho et al., 2005, Iqbal et al., 2011). The results from both present study and studies showing the efficacy and tolerability of GEMFUFOL regimen in metastatic pancreatic cancer (Louvet et al., 2001; Oztop et al., 2004) make this combination regimen attractive in treatment of metastatic biliary tract cancer.

The major side effect of administering gemcitabine is hematologic suppression. In a study by Okusaka et al. using a combination of cisplatin and gemcitabine, neutropenia occurred in 82.9%, and thrombocytopenia in 80.5% of patients while Sasaki et al. observed 35% Grade 3-4 neutropenia and 15% Grade 3-4 thrombocytopenia (Okusaka et al., 2010; Sasaki et al., 2011). In the present study, the rate of neutropenia and thrombocytopenia was 31% and 24.1%, respectively, similar to other gemcitabine plus 5-fluorouracil combination chemotherapies (8), and relatively lower than cisplatin-gemcitabine combination studies. On the other hand, the rate of febrile neutropenia was as low as 6.8% while it was 17-25% in the ABC-02 trial of gemcitabine plus cisplatin (Valle et al., 2010). It was noted that the hematological toxicities are higher when gemcitabine is combined with a platinum, but lower when combined with 5 fluorouracil. The non-hematological toxicities were low with a neglectable toxicity of Grade 4 alopecia.

In conclusion, the GEMFUFOL regimen can be considered as an effective treatment with a reasonable toxicity profile for treatment of metastatic biliary tract cancers. This group of tumors requires effective chemotherapy regimens to enhance survival and quality of life. To conduct large clinical studies or randomized studies is difficult since biliary tract cancer is a rare malignant tumor. Studies achieving a good collaboration and using both available chemotherapeutic agents and novel targeted agents would contribute to improved results in this group of patients with a poor prognosis.

## References

- Chen JS, Jan YY, Lin YC, et al (1998). Weekly 24 h infusion of high-dose 5-fluorouracil and leucovorin in patients with biliary tract carcinomas. *Anticancer Drugs*, **5**, 393-7.
- Cho JY, Paik YH, Chang YS, et al (2005). Capecitabine combined with gemcitabine (CapGem) as first-line treatment in patients with advanced/metastatic biliary tract carcinoma. *Cancer*, **104**, 2753-8.
- Croitoru A, Gramaticu I, Dinu I, et al (2012). Fluoropyrimidines plus cisplatin versus gemcitabine/gemcitabine plus cisplatin in locally advanced and metastatic biliary tract carcinoma - a retrospective study. *J Gastrointest Liver Dis*, **21**, 277-84.
- Cunningham D, Chau I, Stocken DD, et al (2005). Phase III randomized comparison of gemcitabine (gem) vs gemcitabine plus capecitabine (Gem-CAP) in patients with advanced pancreatic cancer. *Eur J Cancer*, **3**, 11.
- Ducreux M, Van Cutsem E, Van Laethem JL, et al (2005). A randomised phase II trial of weekly high-dose 5-fluorouracil with and without folinic acid and cisplatin in patients with advanced biliary tract carcinoma: results of the 40955 EORTC trial. *Eur J Cancer*, **41**, 398-403.
- Eckel F, Schmid RM (2007). Chemotherapy in advanced biliary tract carcinoma: a pooled analysis of clinical trials. *Br J Cancer*, **6**, 896-902.
- Falkson G, MacIntyre JM, Moertel CG (1984). Eastern Cooperative Oncology Group experience with chemotherapy for inoperable gallbladder and bile duct cancer. *Cancer*, **54**, 965.
- Gebbia V, Majello E, Testa A, et al (1996). Treatment of advanced adenocarcinomas of the exocrine pancreas and the gallbladder with 5-fluorouracil, high dose levofolinic acid and oral hydroxyurea on a weekly schedule. Results of a multicenter study of the Southern Italy Oncology Group (G.O.I.M.). *Cancer*, **78**, 1300-7.
- Gesto DS, Cerqueira NM, Fernandes PA, et al (2012). Gemcitabine: a critical nucleoside for cancer therapy. *Curr Med Chem*, **19**, 1076-87.
- Glimelius B, Hoffman K, Sjoden PO, et al (1996). Chemotherapy improves survival and quality of life in advanced pancreatic and biliary cancer. *Ann Oncol*, **7**, 593-600.
- Hamdani NH, Qadri SK, Aggarwalla R, et al (2012). Clinicopathological study of gall bladder carcinoma with special reference to gallstones: our 8-year experience from eastern India. *Asian Pac J Cancer Prev*, **13**, 5613-7.
- Harvey JH, Smith FP, Schein PS (1984). 5-Fluorouracil, mitomycin, and doxorubicin (FAM) in carcinoma of the biliary tract. *J Clin Oncol*, **2**, 1245-8.
- Iqbal S, Rankin C, Lenz HJ, et al (2011). A phase II trial of gemcitabine and capecitabine in patients with unresectable or metastatic gallbladder cancer or cholangiocarcinoma: Southwest Oncology Group study S0202. *Cancer Chemother Pharmacol*, **6**, 1595-602.
- Kajanti M, Pyrhonen S (1994). Epirubicin-sequential methotrexate-5-fluorouracil-leucovorin treatment in advanced cancer of the extrahepatic biliary system. A phase II study. *Am J Clin Oncol*, **17**, 223.
- Kanai M, Yoshimura K, Tsumura T, et al (2011). A multi-institution phase II study of gemcitabine/S-1 combination chemotherapy for patients with advanced biliary tract cancer. *Cancer Chemother Pharmacol*, **67**, 1429-34.
- Kameda R, Ando T, Kobayashi S, et al (2013). A retrospective study of chemotherapy with cisplatin plus gemcitabine after the failure of gemcitabine monotherapy for biliary tract cancer. *Jpn J Clin Oncol*, **6**, 636-40.
- Kim JY, Kim YJ, Lee KW, et al (2013). Practical outcome of adjuvant FOLFOX4 chemotherapy in elderly patients with stage III colon cancer: single-center study in Korea. *Jpn J Clin Oncol*, **43**, 132-8.
- Lim KH, Han SW, Oh DY, et al (2012). Outcome of infusional 5-fluorouracil, doxorubicin, and mitomycin-C (iFAM) chemotherapy and analysis of prognostic factors in patients with refractory advanced biliary tract cancer. *Oncol*, **83**,

57-66.

- Louvet C, Andre T, Hammel P (2001). Phase II trial of bimonthly leucovorin, 5-fluorouracil and gemcitabine for advanced pancreatic adenocarcinoma (FOLFUGEM). *Ann Oncol*, **12**, 675-9.
- Okusaka T, Nakachi K, Fukutomi A, et al (2010). Gemcitabine alone or in combination with cisplatin in patients with biliary tract cancer: a comparative multicentre study in Japan. *Br J Cancer*, **10**, 469-74.
- Oztop I, Yilmaz U, Yavuzsen T, et al (2004). Gemcitabine combined with infusional 5-Fluorouracil and High-Dose leucovorin for the treatment of advanced carcinoma of the pancreas. *Chemotherapy*, **50**, 127-32.
- Park JS, Oh SY, Kim SH, et al (2005). Single-agent gemcitabine in the treatment of advanced biliary tract cancers: a phase II study. *Jpn J Clin Oncol*, **35**, 68-73.
- Qu K, Liu SN, Chang HL, et al (2012). Gallbladder cancer: a subtype of biliary tract cancer which is a current challenge in China. *Asian Pac J Cancer Prev*, **13**, 1317-20.
- Santini D, Virzi V, Vasile E, et al (2012). A phase II trial of fixed-dose rate gemcitabine plus capecitabine in metastatic/advanced biliary tract cancer patients. *Oncology*, **82**, 75-82.
- Sasaki T, Isayama H, Nakai Y, et al (2010). Multicenter, phase II study of gemcitabine and S-1 combination chemotherapy in patients with advanced biliary tract cancer. *Cancer Chemother Pharmacol*, **65**, 1101-7.
- Sasaki T, Isayama H, Nakai Y, et al (2011). Feasibility study of gemcitabine and cisplatin combination chemotherapy for patients with refractory biliary tract cancer. *Invest New Drugs*, **6**, 1488-93.
- Sharma A, Dwary AD, Mohanti BK, et al (2010). Best supportive care compared with chemotherapy for unresectable gall bladder cancer: a randomized controlled study. *J Clin Oncol*, **28**, 4581-6.
- Suzuki E, Furuse J, Ikeda M, et al (2010). Treatment efficacy/safety and prognostic factors in patients with advanced biliary tract cancer receiving gemcitabine monotherapy: an analysis of 100 cases. *Oncol*, **79**, 39-45.
- Tan JW, Hu BS, Chu YJ, et al (2013). One-stage resection for bismuth type IV hilar cholangiocarcinoma with high hilar resection and parenchyma-preserving strategies: a cohort study. *World J Surg*, **3**, 614-21.
- Valle JW, Wasan H, Johnson P, et al (2009). Gemcitabine alone or in combination with cisplatin in patients with advanced or metastatic cholangiocarcinomas or other biliary tract tumours: a multicentre randomised phase II study - The UK ABC-01 Study. *Br J Cancer*, **101**, 621-7.
- Valle J, Wasan H, Palmer DH, et al (2010). Cisplatin plus gemcitabine versus gemcitabine for biliary tract cancer. *N Engl J Med*, **362**, 1273-81.
- Wagner AD, Buechner-Steudel P, Moehler M, et al (2009). Gemcitabine, oxaliplatin and 5-FU in advanced bile duct and gallbladder carcinoma: two parallel, multicentre phase-II trials. *Br J Cancer*, **101**, 1846-52.
- Yonemoto N, Furuse J, Okusaka T, et al (2007). A multi-center retrospective analysis of survival benefits of chemotherapy for unresectable biliary tract cancer. *Jpn J Clin Oncol*, **37**, 843-51.