

RESEARCH ARTICLE

Expression of Ki-67, p53 and VEGF in Pediatric Neuroblastoma

Elmira Gheytnchi¹, Mitra Mehrazma^{1,2*}, Zahra Madjd^{1,2}

Abstract

Background: Neuroblastoma (NB), is a neuroectodermal tumor derived from neural crest cells, and it is the second most common pediatric malignant tumor. The biological and clinical behavior of NB is very heterogeneous. This study was conducted to evaluate the expression of Ki-67, p53 and VEGF markers in tissues obtained from NB patients with different histologic types and stage. **Materials and Methods:** Tissue microarray (TMA) blocks were constructed from paraffin blocks of the NB tissues. Immunohistochemical staining was performed on TMA sections to detect the expression of Ki-67, p53 and VEGF markers. The association between the expression of these markers and clinicopathological parameters were then analyzed. **Results:** We had 18 patients with NB, one patient with ganglioneuroblastoma (GNB) and one with ganglioneuroma. Ki-67 was expressed in 13 (65%) tumors, and negatively correlated with age, prognosis, histologic type and stage of NB (all $p < 0.05$). High and moderate expression of VEGF was found in 5% (1/20) and 65% (13/20) of the tumors, respectively; and it was positively correlated with age, prognosis and histologic types (all $p < 0.05$) and negatively correlated with MKI (mitosis-karyorrhexis index). p53 expression was observed in 10% (2/20) of the tumors, which showed a relative correlation with MKI (p value=0.07). **Conclusions:** VEGF as a candidate for anti-angiogenic targeted therapy was correlated with the development and progression of NB; therefore, VEGF along with Ki-67 can serve as a valuable marker for the prognosis of this tumor type.

Keywords: Ki-67 - p53 - VEGF - neuroblastoma

Asian Pac J Cancer Prev, 15 (7), 3065-3070

Introduction

Neuroblastoma (NB) is the second most common pediatric malignant tumor and the most common solid tumor of childhood consisting of neural crest-derived tumors with cellular heterogeneity and different clinical behaviors (Tong et al., 2008; Owens and Irwin, 2012; Pistoia et al., 2013; Zhang et al., 2013). It arises in the paraspinal ganglia or the adrenal medulla, whereas disseminated disease appears in the bone marrow (71% of patients), bones (56%), lymph nodes (31%), lungs (3%), and other internal organs (15-45%) (Teitz et al., 2013).

Despite advances in intensive multi-modal therapies, neuroblastoma accounts for 8-10% of pediatric cancers and is fatal in almost half of the patients (Modak and Cheung, 2010; Castel et al., 2013). On the other hand, in the USA, 15% of childhood cancer deaths occur in NB, and it accounts for 6-10% of all pediatric cancers (Patterson et al., 2011; Castel et al., 2013; Mehdiabadi et al., 2013). NB mainly occurs in patients under 5 years of age (Castel et al., 2013; Mehdiabadi et al., 2013). Several factors including age at diagnosis, histopathologic features, tumor stage, MKI (mitosis-karyorrhexis index), genetic and molecular characteristics such as MYCN oncogene amplification (first described prognostic gene) are applied as prognostic factors in NB (Modak and Cheung, 2010; Inandiklioğlu

et al., 2012). Over the past decades, different approaches such as second line chemotherapy, immunotherapy and targeted therapies have been introduced to improve the treatment and survival of patients with high-risk NB (Modak and Cheung, 2010). Increased tumor angiogenesis occurs in high-risk NB tumors which is supported by vascular endothelial growth factor (VEGF), fibroblast growth factor (FGF), transforming growth factor alpha (TGF- α) and platelet-derived growth factor A (PDGF-A) (Modak and Cheung, 2010). Previous studies have shown that VEGFR-1 and VEGFR-2 are overexpressed in different malignant tumors (Ferrara et al., 2003; Maae et al., 2011). VEGF is also overexpressed within the tumor and its expression is associated with tumor growth, advanced stage, metastasis and poor prognosis (Nikiteas et al., 2007). VEGF-A belongs to the PDGF gene family called as angiogenic growth factor which interacts with two related receptor tyrosine kinases (RTKs) including VEGFR-1 (flt-1) and VEGFR-2 (flk-1 or KDR) (Ferrara et al., 2003; Maae et al., 2011). Other VEGF ligands include placental growth factor (PLGF), VEGF-B, VEGF-C and VEGF-D (Ferrara et al., 2003). VEGF also interacts with the neuropilins (a family of coreceptors), but does not interact with VEGFR-3 (fms-like-tyrosine kinase, flt-4) (Ferrara et al., 2003). Therefore, VEGF could be applied as a prognostic

¹Oncopathology Research Center, ²Department of Pathology, Iran University of Medical Sciences, Tehran, Iran *For correspondence: mitmehr@yahoo.com

marker in human malignancies and its inhibition might be helpful in the prevention of angiogenesis, tumor growth and tumor induced neoangiogenesis (Ferrara, 2002; Nikiteas et al., 2007). Some previous studies applied anti-angiogenic therapies via VEGF inhibition to cure different carcinomas such as adult glioblastoma, renal, colorectal and non-small cell lung carcinomas (p value <0.001). NB also referred to as a p53 wild-type with highly vascular, aggressive tumors frequently relapses after successful chemotherapy and is usually resistant to anti-angiogenesis therapies (Tweddle et al., 2003; Patterson et al., 2011). Previous studies demonstrated that p53 inactivation occurs in a large number of cell lines and tumors including lymphomas, leukemias, lung (Miller et al., 1992), breast, gastrointestinal, thyroid and brain carcinomas (Hollstein et al., 1991; Imamura et al., 1993). p53 is a nuclear phosphoprotein and a tumor suppressor gene (Levine et al., 1991; Imamura et al., 1993), and it is usually mutated in NB via the amplification of N-myc gene (Hollstein et al., 1991). There is strong evidence from previous studies that the p53 protein is overexpressed in human neuroblastoma-derived cell lines and tumors as well as other human cell lines and primary adult cancers (Davidoff et al., 1992; Imamura et al., 1993) which is associated with undifferentiated phenotype (Sidell and Koeffler, 1988; Davidoff et al., 1992). In contrast, some other studies did not show p53 mutations in NB samples with N-myc amplification (Hollstein et al., 1991). Therefore, the evaluation of expression patterns of p53 in NB tumors could be crucial due to this difference. Moreover, it has been suggested that the proliferation markers such as Ki-67 index and mitosis can be applied in breast cancer in addition to other factors such as stage and grade (Goldhirsch et al., 2009; Jonat and Arnold, 2011). Ki-67 is a non histone and nuclear protein involved in cell proliferation which is not expressed in quiescent (G0) cells (Scholzen and Gerdes, 2000). Some studies have proposed that Ki-67 is associated with shorter survival in patients with malignancies including lung and breast cancer (Remvikos et al., 1989; Martin et al., 2004). Given that approximately half of the patients with high-risk NB experience a relapse after primary treatment and have poor prognosis (Mueller et al., 2013), it seems necessary to identify valuable diagnostic markers for the prognosis of NB and new targeted therapies. This study was conducted to evaluate the expression of the three molecular markers of Ki-67, p53 and VEGF in the tissues obtained from NB patients with different histologic types and staging and also to assess the association between the expressions of each marker with clinicopathologic characteristics.

Materials and Methods

Patients and tumor samples

A retrospective study was conducted on 20 children diagnosed with neuroblastoma tumor who underwent surgery between 2001 and 2010 at Ali-Asghar Children Hospital in Tehran, Iran. This hospital is a major referral center and is among the most reputable pediatric oncology centers in the country and is also one of the academic children's hospitals of Iran University of

Medical Sciences. Surgical specimens were obtained before systemic treatment. In this study, we reviewed the medical records of the patients, pathological reports and Hematoxylin and Eosin (H&E)-stained slides to confirm the diagnosis and clinicopathologic parameters including age, gender, tumor type, tumor size, tumor stage and degree of differentiation. The stage of tumors was recorded according to the INSS staging system as stage 1, 2, 3, 4 and 4S. The mitosis karyorrhexis index (MKI), the number of cells undergoing mitosis and karyorrhexis (number per 5000 cells) were evaluated according to the INPC (International Neuroblastoma Pathology Committee). MKI was determined as low (<100 mitotic/karyorrhetic figures), intermediate (100-200 figures) and high (>200 figures per 5000 cells were counted) (del Carmen Mejia et al., 2002). Neuroblastic tumors (NTs) were classified into 4 major groups based on the INPC classification: 1) NB (Schwannian stroma-poor NT) with three grades (Undifferentiated, Poorly differentiated and Differentiating); 2) GNB (Ganglioneuroblastoma) nodular (composite Schwannian stroma-rich/stroma-dominant and stroma-poor); 3) GNB intermixed (Schwannian stroma-rich); 4) GN (Ganglioneuroma) (Schwannian stroma-dominant) with maturing and mature subtypes (Shimada et al., 1999). This study was approved by Iran University of Medical Sciences Research Ethics Committee.

Construction of the tissue microarray blocks

The paraffin-embedded biopsy specimens were applied to construct tissue microarray blocks as described previously (Mehrazma et al., 2013; Mohsenzadegan et al., 2013; Taeb et al., 2014). Briefly, the regions of interest in paraffin-embedded tissues were identified and marked out using 3- μ m H&E slides to obtain the cores. Four representative tumor regions were selected from each corresponding paraffin-embedded block. Tissue cores with a diameter of 0.6 mm were removed from the selected areas of the "donor" block and were then accurately inserted in the recipient paraffin block using Tissue Arrayer Minicore (ALPHELYS, Plaisir, France). The TMA blocks were constructed in duplicates, each copy containing two samples from a different region of each tumor; the mean scoring of the cores was then calculated as the final score (Mehrazma et al., 2013). Microtome was used to cut the sections from the blocks. The sections were mounted on a microscope slides and then analyzed.

Immunohistochemistry (IHC)

Ki-67, VEGF and p53: IHC method was performed on TMA sections which were prepared from paraffin-embedded tissues using a protocol as previously described (Madjd et al., 2011). Briefly, Four- μ m sections were cut using a microtome and mounted onto Superfrost plus slides (Thermo Scientific, Germany). The slides were deparaffinized in xylene and rehydrated by immersion in decreasing grades of ethanol. To enhance antigen exposure, the slides were retrieved at TRIS/EDTA, pH: 9.0, (Dako, Denmark) for 20 minutes. After antigen-retrieval and cooling to room temperature, the slides were washed twice with distilled water. Then, endogenous peroxidase activity was blocked with 3% hydrogen

peroxide for 10 minutes. After blocking, the slides were incubated with a primary mouse monoclonal anti-human anti-body (Ki-67, clone MIB 1, DAKO, Denmark) at a dilution of 1:200 with a factory thinner (S2022 Antibody diluent, DAKO, Denmark) for 30 minutes. The slides were subsequently incubated with 10% normal rabbit serum (Dako, Denmark) in PBS for 15 minutes, and the secondary antibody EnVision HRP anti-mouse K 4001 (Dako, Denmark) for 60 minutes at room temperature and were washed again in PBS.

Biotin Streptavidin amplified immunohistochemical technique was used for the staining of the sections prepared on polylysine gap impregnated slides against p53 (Clone DO7, Dako®, Denmark) and VEGF (Clone VG1, Dako®, Denmark) (Bukhari et al., 2008). The slides were retrieved by microwave treatment with 10mM citrate buffer and were incubated with 10% normal goat serum in phosphate- buffered saline (PBS) to eliminate nonspecific staining. Monoclonal antibodies were used against p53 (dilution 1:200) and VEGF (dilution 1:25). The antigen-bound primary antibodies were detected using a standard secondary antibody detection kit (LSAB+kit, Dako, Denmark).

The antigens bound to each antibody were visualized by a 10- minute incubation with the addition of 3, 3'-diaminobenzidine (DAB, Dako, Denmark). After immunostaining, the sections were counterstained with haematoxylin (Dako), dehydrated in growing concentrations of alcohol, cleared in xylene (Dako) and mounted with Canada balsam for visualization. The slides were evaluated using an Olympus BX41 light microscope. The cells with brown nuclear staining were considered positive.

Scoring system

Ki-67 expression was defined as a percentage of positive cells, by counting at least 1000 tumor cells in 10 randomly selected fields. A cutoff proliferation index of <5% was considered as negative. For VEGF, the cytoplasmic staining intensity of the tumor cells was scored according to the following scale (Maae et al., 2011): 0 (no staining), 1 (weak staining), 2 (moderate staining) and 3 (strong staining). The percentage of positive cells for VEGF antibody was graded as: 1 (<10% of tumor with SI (Strong Intensity), 2 (10%≤SI<1/3 of tumor), 3 (1/3≤SI<2/3 of tumor), 4 (SI≥2/3 of tumor). Strong intensity was defined as the strongest intensity relative to weaker staining intensity within each tumor slide. The overall score was obtained by multiplying the intensity score of staining by quantitative information in four mentioned categories of the percentage (Maae et al., 2011). For p53 grading, the stained nuclear cells were considered to be positive and non-stained nuclear considered as negative.

Evaluation of immunostaining

The immunostained tissue arrays were evaluated using a semi-quantitative scoring system after a series of TMAs was observed on a multi-headed microscope by two observers (MM and ZM) in a coded manner without a previous knowledge of clinical and pathological

parameters of the patients. In difficult cases, the scoring was confirmed by the both observers and an agreement was reached.

Statistical analysis

Data were analyzed using the SPSS statistical software package version 20 (SPSS Inc, Chicago IL, USA). Pearson's χ^2 and Pearson's R tests were used to analyze the significance of the correlation between Ki-67, VEGF, p53 expression and clinicopathological parameters. A p value of <0.05 was considered as statistically significant for each antibody.

Results

Study population

In our series, 18 patients were diagnosed with NB, one patient with ganglioneuroblastoma (GNB) and one with ganglioneuroma. The age of the patients ranged from 1 month to 11 years, with an average age of 34 months. There were 14 male (70%) and 6 female (30%) patients, and male to female ratio was 2.3:1. According to the INSS, 2 patients (10%) showed stage 1, 5 patients (25%) stage 2, 5 patients (25%) stage 3, 5 patients (25%) stage 4 and 3 patients (15%) showed stage 4S. The surgical resection specimens were composed of 1 skin, 2 mediastinal, 3 lymph node and 14 adernal mass. Eighteen patients were classified as unfavorable histology (UFH) and 2 as favorable histology (FH).

Ki-67 expression and its correlation with clinicopathological parameters in NB tissues

In the 20 tumor tissues stained with Ki-67, 13 (65%) showed brown nuclear positive staining and 7 (35%) showed no staining in the nuclear area of the tumor cells (Table 1, Figure 1). The pattern of expression was considered as negative when there were <5% positive cells and as positive when there were ≥5% positive cells. Ki-67 was expressed mainly in unfavorable NB and a significant correlation was observed with patients' age (p value=0.015), prognosis (UFH/FH) (p value=0.042),

Table 1. The Expression of Ki-67, VEGF and p53 in Neuroblastoma

Tumor type	Number of cases	Expression of					
		Ki-67		VEGF		p53	
		ve- n (%)	ve+ n (%)	ve- n (%)	ve+ n (%)	ve- n (%)	ve+ n (%)
NB	18	5 (25)	13 (65)	6 (30)	14 (70)	16 (80)	2 (10)
GNB	1	1 (5)	0 (0)	0 (0)	1 (5)	1 (5)	0 (0)
GN	1	1 (5)	0 (0)	0 (0)	1 (5)	1 (5)	0 (0)

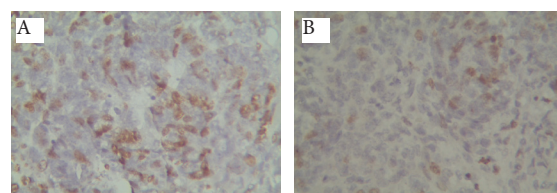


Figure 1. Immunohistochemical Staining with Ki67 Antibody Displays a Nuclear Localization Pattern. A) High versus; B) Low proliferation activity (40X, counterstained with hematoxylin)

tumor diagnosis (Histologic type based on INPC) (p value=0.059) and stage of NB (p value=0.050) indicating that the higher expression of Ki-67 was more often found in the poor prognosis of NB tumors (Table 2).

VEGF and its association with clinicopathologic parameters in NB tissues

Fourteen out of 20 cases expressed VEGF with brown granules in the cytoplasm of tumor cells (Figure 2). In terms of VEGF intensity, 12 (60%) cases showed moderate, 2 (10%) weak intensity and 6 (30%) cases were negative. Most of the specimens had positive tumor cells. In terms of VEGF percentage, 3 (15%) of the samples had 1-50% positive tumor cells with moderate staining intensity, 11 (55%) had 1-50% positive tumor cells with weak staining intensity and 6 (30%) had no positive tumor cells with negative VEGF immunoreactivity (Table 1). The overall score was obtained by assessing both the percentage and intensity of stained tumor cells (I×P=overall score) including 0-12, and the specimens were classified into 2 groups according to their overall score (cut off value of 2). Tumors were distinguished with high (2-12) and low (0-2) VEGF expression scores (Table 3). In terms of the overall score, the high expression of VEGF was found in 70% (14/20) of the cases, and 30% (6/20) of the tumors demonstrated low expression which was significantly correlated with age (p value=0.021), histologic types (based on INPC) (p value<0.001) and prognosis (p value=0.008) and negatively correlated with MKI (mitosis-karyorrhexis index) (p value=0.008).

p53 expression and its association with clinicopathologic parameters in NB tissues

The analysis of p53 protein revealed that 90% (18/20) of NBs showed negative staining, whereas 10% (2/20) of the cases showed positive staining in their nuclear area of the tumor cells (Figure 3). p53 expression was observed

Table 3. Immunoreactivity of VEGF, and the Number of Patients

Category	No (%)
Percentage of positive tumour cells (P)	
SI<10% of tumor	6 (30)
10% ≤ SI < 1/3 of tumor	11 (55)
1/3 ≤ SI < 2/3 of tumor	3 (15)
SI ≥ 2/3 of tumor	0 (0)
Staining intensity (I)	
Negative	6 (30)
Weak	2 (10)
Moderate	12 (60)
Strong	0 (0)
Expression score (I×P)	
Low (0-2)	6 (30)
High (2-12)	14 (70)

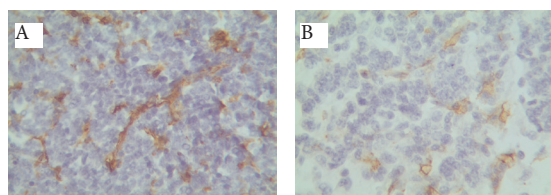


Figure 2. Positive Cytoplasmic Staining for VEGF. A) High and intense versus; B) Low and light expression, (40X, counterstained with hematoxylin)

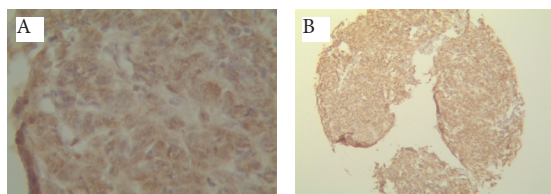


Figure 3. Tumor Cells Show Positive Nuclear Staining for p53. A) 40X and; B) 10X, counterstained with hematoxylin)

in only 2/20 (10%) of the tumors, showing a trend with MKI (p value=0.07) in NB. The clinicopathologic and demographic features of the patients, and tumor characteristics are summarized in Table 2.

Table 2. The Relations among Ki-67, VEGF and p53 Expression and Clinico-pathological Parameters in Neuroblastoma (Value in bold is significant)

	Number of cases (%)	Expression of				
		Ki-67* %**	VEGF* Intensity %** of staining	p53* Overall score	%**	
All cases	20					
Age (years)	<1.5	8 (40)	0.015	0.053	0.027	0.021
	1.5-5	7 (35)				
	>5	5 (25)				
Gender	Male	14 (70)	0.357	0.621	0.291	0.241
	Female	6 (30)				
MKI	0	5 (25)	0.577	0.027	0.022	0.008
	<100	6 (30)				
	100-200	9 (45)				
	>200	0 (0)				
Prognosis (Shimada)	Poor (UFH)	18 (90)	0.042	0.27	0.154	0.008
	Good (FH)	2 (10)				
Histology	NB	18 (90)	0.059	0.299	0.087	<0.001
	GNB	1 (5)				
	GN	1 (5)				
Stages	1-2	6 (30)	0.05	0.283	0.213	0.137
	3-4	11 (55)				
	4s	3 (15)				

*p value; Pearson χ^2 ; **Percentage of positive cells

Discussion

Previous studies have shown that high-risk NB with advanced-stage is resistant to various therapeutic approaches resulting in poor survival rates (Ishola and Chung, 2007; Jakovljevic et al., 2009, Cheung, 2012). Therefore, finding new molecular markers in NB is essential to improve targeted therapy via appropriate approach and to increase the survival rates of children. Tumor angiogenesis is mediated by increased VEGF in NB patients with advanced-stage (Modak and Cheung, 2010). VEGF as a prognostic marker is overexpressed in several cancers including breast, colorectal adenocarcinomas, gastrointestinal and gastric carcinomas and its expression is associated with advanced-stage and poor prognosis in patients (Chung et al., 1996; Yamamori et al., 2004; Jin et al., 2005; Meric, 2007; Sayed-Ahmed et al., 2013; Wang et al., 2013). In the present study, we found that the expression of VEGF in NB tumors was significantly associated with prognosis (p value=0.008) and histologic types (p value<0.001) supporting the previous findings that have revealed VEGF is a prognostic marker and, therefore, may play an important role in tumor progression

and prognosis. The relation between VEGF expression and worse prognosis has also been demonstrated in some previous studies. Ferrara et al. (2002) showed that the overexpression of VEGF *in vitro* and *in vivo* is related to tumor progression and metastasis (Ferrara, 2002). Wang et al. (2013) reported that the level of expression of VEGF-A and VEGF-C increases in gastric cancer and is correlated with poor prognosis (Wang et al., 2013). A study on novel biomarkers including VEGF conducted by Osman et al. (2013) showed that the expression of VEGF-B was correlated with bone marrow metastasis in neuroblastoma (Osman et al., 2013). Thus, antibody-based targeted therapy against VEGF could be an effective method to inhibit cancer progression and may become a novel strategy for the treatment of NB.

In our study, the expression of p53 protein was only observed in two NB specimens after immunochemical staining, and there was no correlation between the expression of p53 and other histopathologic parameters indicating that this protein is not an attractive marker for targeted therapy and prognosis in human NB. Previous studies also demonstrated that the p53 protein does not play a significant role in tumor progression in NB neurogenic cells (Mejia et al., 1999). It has been reported that the p53 gene mutations are few or rare in primary NB (unlike other cancers), especially at the time of disease diagnosis. Our finding regarding the low expression of p53 in NB is inconsistent with the findings of previous studies (Hollstein et al., 1991; Modak and Cheung, 2010).

Several studies have been conducted to evaluate Ki-67 as a predictive and prognostic marker in breast cancer, while few reports are available on the expression of Ki-67 in neuroblastoma. Our study showed the expression of Ki67 in 65% of the cases. In contrast to other studies that revealed a significant correlation between Ki-67 and MKI (del Carmen Mejia et al., 2002; Mejia et al., 2003), our results did not show any statistically significant association between Ki67 and MKI. In agreement with the previous studies, we found a significant relationship between ki-67 expression and other clinicopathologic variables. Mejia et al. suggested that Ki-67 is involved in the cellular proliferation of NB and can be used as a prognostic marker when associated with other clinicopathological factors (Mejia et al., 2003). Although little evidence exists on Ki-67 expression in NB, its prognostic value in NB patients has already been proven. Our results support that Ki-67 are closely relevant to poor prognosis in patients with high stage of disease; therefore, it can be served as a valuable marker of prognosis in NB. Due to the limited number of patients in the current study, it would be cost effective to investigate the expression of these prognostic markers and confirm these findings using TMA technique in a larger cohort of NBs.

In conclusion, our study was the first to evaluate these prognostic markers on TMA of NB and revealed that the level of expression of VEGF and Ki-67 correlated with the development and progression of NB. Therefore, these markers could be considered as prognostic markers particularly in patients with unfavorable histology and advanced stage of NB. In contrast to some previous studies, we found no correlation between Ki-67 and MKI.

References

- Bukhari MH, Niazi S, Anwar M, Chaudhry NA, Naeem S (2008). Prognostic significance of new immunohistochemistry scoring of p53 protein expression in cutaneous squamous cell carcinoma of mice. *Ann N Y Acad Sci*, **1138**, 1-9.
- Castel V, Segura V, Berlanga P (2013). Emerging drugs for neuroblastoma. *Expert Opin Emerg Drugs*, **18**, 155-71.
- Cheung R (2012). Poor treatment outcome of neuroblastoma and other peripheral nerve cell tumors may be related to under usage of radiotherapy and socio-economic disparity: a US SEER data analysis. *Asian Pac J Cancer Prev*, **13**, 4587-91.
- Chung YS, Maeda K, Sowa M (1996). Prognostic value of angiogenesis in gastro-intestinal tumours. *Eur J Cancer*, **32**, 2501-5.
- Davidoff AM, Pence JC, Shorter NA, Iglehart JD, Marks JR (1992). Expression of p53 in human neuroblastoma- and neuroepithelioma-derived cell lines. *Oncogene*, **7**, 127-33.
- Del Carmen Mejia M, Navarro S, Pellin A, et al (2002). Study of proliferation and apoptosis in neuroblastoma. Their relation with other prognostic factors. *Arch Med Res*, **33**, 466-72.
- Ferrara N (2002). VEGF and the quest for tumour angiogenesis factors. *Nat Rev Cancer*, **2**, 795-803.
- Ferrara N, Gerber HP, LeCouter J (2003). The biology of VEGF and its receptors. *Nat Med*, **9**, 669-76.
- Goldhirsch A, Ingle JN, Gelber RD, et al (2009). Thresholds for therapies: highlights of the St Gallen International Expert Consensus on the primary therapy of early breast cancer 2009. *Ann Oncol*, **20**, 1319-29.
- Hollstein M, Sidransky D, Vogelstein B, Harris CC (1991). p53 mutations in human cancers. *Science*, **253**, 49-53.
- Imamura J, Bartram CR, Berthold F, et al (1993). Mutation of the p53 gene in neuroblastoma and its relationship with N-myc amplification. *Cancer Res*, **53**, 4053-8.
- Inandiklioğlu N, Yilmaz S, Demirhan O, Erdoğan S, Tanyeli A (2012). Chromosome imbalances and alterations of AURKA and MYCN genes in children with neuroblastoma. *Asian Pac J Cancer Prev*, **13**, 5391-7.
- Ishola TA, Chung DH (2007). Neuroblastoma. *Surg Oncol*, **16**, 149-56.
- Jakovljevic G, Culic S, Stepan J, Bonevski A, Seiwerth S (2009). Vascular endothelial growth factor in children with neuroblastoma: a retrospective analysis. *J Exp Clin Cancer Res*, **143**, 1-11.
- Jin Q, Hemminki K, Enquist K, et al (2005). Vascular endothelial growth factor polymorphisms in relation to breast cancer development and prognosis. *Clin Cancer Res*, **11**, 3647-53.
- Jonat W, Arnold N (2011). Is the Ki-67 labelling index ready for clinical use? *Ann Oncol*, **22**, 500-2.
- Levine AJ, Momand J, Finlay CA (1991). The p53 tumour suppressor gene. *Nature*, **351**, 453-6.
- Maee E, Nielsen M, Steffensen KD, et al (2011). Estimation of immunohistochemical expression of VEGF in ductal carcinomas of the breast. *J Histochem Cytochem*, **59**, 750-60.
- Madjd Z, Karimi A, Molanae S, Asadi-Lari M (2011). BRCA1 protein expression level and CD44(+) phenotype in breast cancer patients. *Cell J*, **13**, 155-62.
- Martin B, Paesmans M, Mascaux C, et al (2004). Ki-67 expression and patients survival in lung cancer: systematic review of the literature with meta-analysis. *Br J Cancer*, **91**, 2018-25.
- Mehdiabadi GB, Arab E, Rafsanjani KA, Ansari S, Moinzadeh AM (2013). Neuroblastoma in Iran: an experience of 32 years at a referral childrens hospital. *Asian Pac J Cancer Prev*, **14**, 2739-42.
- Mehrazma M, Madjd Z, Kalantari E, et al (2013). Expression of stem cell markers, CD133 and CD44, in pediatric solid

- tumors: a study using tissue microarray. *Fetal Pediatr Pathol*, **32**, 192-204.
- Mejia C, Navarro S, Pellin A, et al (2003). Prognostic significance of cell proliferation in human neuroblastoma: comparison with other prognostic factors. *Oncol Rep*, **10**, 243-7.
- Mejia C, Pellin A, Navarro S, Castel V, Llombart-Bosch A (1999). A new mutation of the p53 gene in human neuroblastoma, not correlated with N-myc amplification. *Int J Surgical Pathol*, **7**, 149-54.
- Meric JB (2007). Angiogenesis targeting in gastro-intestinal cancers. *Bull Cancer*, **94**, 207-15.
- Miller CW, Simon K, Aslo A, et al (1992). p53 mutations in human lung tumors. *Cancer Res*, **52**, 1695-8.
- Modak S, Cheung NK (2010). Neuroblastoma: Therapeutic strategies for a clinical enigma. *Cancer Treat Rev*, **36**, 307-17.
- Mohsenzadegan M, Madjd Z, Asgari M, et al (2013). Reduced expression of NGEP is associated with high-grade prostate cancers: a tissue microarray analysis. *Cancer Immunot*, **62**, 1609-18.
- Mueller S, Bhargava S, Molinaro AM, et al (2013). Poly (ADP-Ribose) polymerase inhibitor MK-4827 together with radiation as a novel therapy for metastatic neuroblastoma. *Anticancer Res*, **33**, 755-62.
- Nikiteas NI, Tzanakis N, Theodoropoulos G, et al (2007). Vascular endothelial growth factor and endoglin (CD-105) in gastric cancer. *Gastric Cancer*, **10**, 12-7.
- Osman J, Galli S, Hanafy M, Tang X, Ahmed A (2013). Identification of novel biomarkers in neuroblastoma associated with the risk for bone marrow metastasis: a pilot study. *Clin Transl Oncol*, **15**, 953-8.
- Owens C, Irwin M (2012). Neuroblastoma: the impact of biology and cooperation leading to personalized treatments. *Crit Rev Clin Lab Sci*, **49**, 85-115.
- Patterson DM, Gao D, Trahan DN, et al (2011). Effect of MDM2 and vascular endothelial growth factor inhibition on tumor angiogenesis and metastasis in neuroblastoma. *Angiogenesis*, **14**, 255-66.
- Pistoia V, Morandi F, Bianchi G, et al (2013). Immunosuppressive microenvironment in neuroblastoma. *Front Oncol*, **3**, 1-8.
- Remvikos Y, Beuzeboc P, Zajdela A, et al (1989). Correlation of pretreatment proliferative activity of breast cancer with the response to cytotoxic chemotherapy. *J Natl Cancer Inst*, **81**, 1383-7.
- Sayed-Ahmed MM, Hafez MM, Al-Shabanah OA, et al (2013). Increased expression of biological markers as potential therapeutic targets in Saudi women with triple-negative breast cancer. *Tumori*, **99**, 545-54.
- Scholzen T, Gerdes J (2000). The Ki-67 protein: from the known and the unknown. *J Cell Physiol*, **182**, 311-22.
- Shimada H, Ambros IM, Dehner LP, et al (1999). Terminology and morphologic criteria of neuroblastic tumors: recommendations by the International Neuroblastoma Pathology Committee. *Cancer*, **86**, 349-63.
- Sidell N, Koeffler HP (1988). Modulation of Mr 53,000 protein with induction of differentiation of human neuroblastoma cells. *Cancer Res*, **48**, 2226-30.
- Taeb J, Asgari M, Abolhasani M, Farajollahi MM, Madjd Z (2014). Expression of prostate stem cell antigen (PSCA) in prostate cancer: A tissue microarray study of Iranian patients. *Pathol Res Pract*, **210**, 18-23.
- Teitz T, Inoue M, Valentine MB, et al (2013). Th-MYCN mice with caspase-8 deficiency develop advanced neuroblastoma with bone marrow metastasis. *Cancer Res*, **73**, 4086-97.
- Tong QS, Zheng LD, Tang ST, et al (2008). Expression and clinical significance of stem cell marker CD133 in human neuroblastoma. *World J Pediatr*, **4**, 58-62.
- Tweddle DA, Pearson AD, Haber M, et al (2003). The p53 pathway and its inactivation in neuroblastoma. *Cancer Lett*, **197**, 93-8.
- Wang X, Chen X, Fang J, Yang C (2013). Overexpression of both VEGF-A and VEGF-C in gastric cancer correlates with prognosis, and silencing of both is effective to inhibit cancer growth. *Int J Clin Exp Pathol*, **6**, 586-97.
- Yamamori M, Sakaeda T, Nakamura T, et al (2004). Association of VEGF genotype with mRNA level in colorectal adenocarcinomas. *Biochem Biophys Res Commun*, **325**, 144-50.
- Zhang J, Liu Y, Bao P, Wang Y, Zhang Y (2013). Rare coexistence of metastatic neuroblastoma of liver and solid pseudo papillary tumor of pancreas: Case report and literature review. *J Cancer Res Ther*, **9**, 308-10.