

RESEARCH ARTICLE

Low Expression of the FoxO4 Gene may Contribute to the Phenomenon of EMT in Non-small Cell Lung Cancer

Ming-Ming Xu^{1&}, Guo-Xin Mao^{2&}, Jian Liu², Jian-Chao Li¹, Hua Huang³, Yi-Fei Liu^{3*}, Jun-Hua Liu^{1*}

Abstract

Because of its importance in tumor invasion and metastasis, the epithelial-mesenchymal transition (EMT) has become a research focus in the field of cancer. Recently, evidence has been presented that FoxO4 might be involved in EMT. Our study aimed to detect the expression of FoxO4, E-cadherin and vimentin in non-small cell lung cancers (NSCLCs). We also investigated clinical features and their correlations with the markers. In our study, FoxO4, E-cadherin and vimentin were assessed by immunohistochemistry in a tissue microarray (TMA) containing 150 cases of NSCLC. In addition, the expression level of FoxO4 protein was determined by Western blotting. The percentages of FoxO4, E-cadherin and vimentin positive expression in NSCLCs were 42.7%, 38.7% and 55.3%, respectively. Immunoreactivity of FoxO4 was low in NSCLC when compared with paired normal lung tissues. There were significant correlations between FoxO4 and TNM stage ($P < 0.001$), histological differentiation ($P = 0.004$) and lymph node metastasis ($P < 0.001$), but no significant links with age ($P = 0.323$), gender ($P = 0.410$), tumor size ($P = 0.084$), smoking status ($P = 0.721$) and histological type ($P = 0.281$). Our study showed that low expression of FoxO4 correlated with decreased expression of E-cadherin and elevated expression of vimentin. Cox regression analysis indicated FoxO4 to be an independent prognostic factor in NSCLC ($P = 0.046$). These data suggested that FoxO4 might inhibit the process of EMT in NSCLC, and might therefore be a target for therapy.

Keywords: FoxO4 - E-cadherin - vimentin - epithelial-mesenchymal transition - NSCLC

Asian Pac J Cancer Prev, 15 (9), 4013-4018

Introduction

Lung cancer, one of the most common malignant tumors in the world with high morbidity and mortality (Jemal et al., 2008). In a recent survey across China, the mortality of lung cancer rose by 465% in the past 30 years, which became the main cause of urban residents' death (WenDehnel 2011). NSCLC accounts for approximately 80% of lung cancer, which is mainly classified as squamous carcinoma and adenocarcinoma. Comparing to other cancers, such as breast or colorectal cancers, the 5-year survival rate of lung cancer is the lowest (15%). As one of the ten hallmarks of cancer, metastasis is the main lethal cause of lung cancer patients. However, the molecular mechanisms of metastasis is still unclear. Hence, identification of new metastasis genes and the molecular mechanisms underlying the metastatic progression still need more efforts.

Epithelial-mesenchymal transition (EMT), which participates in multiple physiological and pathological processes of human body, was first proposed in 1982. EMT pathway was found to play important roles in regulating the transcription of genes involved in embryonic

development (Thiery et al., 2009), inflammatory response (Foroni et al., 2012), tissue regeneration (KalluriWeinberg 2009), organ fibrosis (Lopez-NovoaNieto 2009; Liu 2010), tumor invasion and tumor metastasis (Lopez-NovoaNieto 2009). Particularly, the activation of EMT pathway often precedes cancer metastasis for tumors of the epithelial origin (Wells et al., 2008). Epithelial cells lead to loosen and even loss of cell-cell adhesion throughout EMT. Besides, at the molecular level, EMT is characterized by loss or downregulation of E-cadherin and cytokeratins, with the exception of mesenchymal proteins like Vimentin, fibronectin and N-cadherin, whose expression are often upregulated (Wells et al., 2008; Ivaska 2011; SatelliLi 2011; Vaid et al., 2011). It has been shown that EGF and resultant EGFR activation could promote EMT in HCC cell lines by altered the expression and morphology of EMT-associated markers (E-cadherin/ β -catenin complex) (Fan et al., 2014). Recently, Lee et al suggested that in cholangiocarcinoma cells, EGF-mediated phosphorylated FoxO4 could negatively regulate the transcription of ANXA8, leading to the morphologic changes similar to epithelial-mesenchymal transition (EMT) (Lee et al., 2009). Based on current knowledge, growth factor or

¹Department of Cardiothoracic Surgery, ²Department of Oncology, ³Department of Pathology, Affiliated Hospital of Nantong University, Nantong, China [&]Equal contributors *For correspondence: blueflime@qq.com

insulin inhibits the transcription activity of FoxO4 by phosphorylated via phosphatidylinositol-3-kinase (PI3K)/AKT signaling (Kops et al., 1999). It implied that FoxO4 might be an inhibitor for EMT in cholangiocarcinoma. However, no data of FoxO4 are available for NSCLC until now.

FoxO (Forkhead box O) transcription factors consists of FoxO1, FoxO3, FoxO4 and FoxO6. They are becoming an important and major target in inhibiting tumorigenesis (Katoh 2004; Burgering 2008; CalnanBrunet 2008). The functional role of FoxO4 gene is largely determined by its DNA-binding domain (DBD) (Silhan et al., 2009). DBD is characterized by three α helices, three stranded β sheet and two wing-like loops, and is thought to play important roles interacting with other proteins (Boura et al., 2007). The interaction with 14-3-3 proteins affected FoxO4 binding to the target DNA and prevented FoxO4 from entering the nucleus by interfering with the function of nuclear localization sequence (NLS) (Obsilova et al., 2005; Boura et al., 2007). Human FoxO4 gene is located on chromosome Xq13.1 and encodes a protein of 65KD. FoxO4 participates in many cellular processes, including regulation of cell cycle, proliferation, differentiation, apoptosis, ageing, metabolism, response to stress and tumorigenesis (Tran et al., 2002). Another Fox family member—FoxK1, promoted cell proliferation by inhibiting the transcription activity of FoxO4, and the repression of FoxO4 resulted in down-regulation of P21 expression in myogenic progenitor cell (MPC) (Shi et al., 2012). In the study of diabetic nephropathy, an advanced glycation endproducts (AGE)-RAGE (a receptor for AGEs) interaction promoted podocyte apoptosis by activating FoxO4 transcription factor (Chuang et al., 2007). In addition, FoxO4 was shown to play a critical role in lifespan extension, and the function was correlated with FoxO4's role in reactive oxygen species (ROS) scavenging (Dansen et al., 2009). As a transcription repressor, FoxO4 plays a particularly important role in tumorigenesis. The cell cycle dependent kinase inhibitor P27, activated by FoxO4, affects cell cycle dependent kinase (CDK), which blocks tumors' G1 cell cycle progression (Yang et al., 2005). Earlier study showed that FoxO4 inhibited tumor growth by reducing tumor size in HER-2 overexpression tumor cells (Yang et al., 2005). Recently, Chen L found that miR-421 promoted tumor proliferation and antiapoptosis by down-regulating FoxO4 downstream molecules such as cyclin dependent kinase inhibitors P21, P27, Bim (BCL-2 family) and FasL (Fas ligand) in nasopharyngeal carcinoma (Chen et al., 2013). In addition, chemotherapy experiments in colorectal cancer and liver cancer, it showed that FoxO4 sensitized colorectal and liver cancer cells to doxorubicin-mediated cytotoxicity (Lupertz et al., 2008). In tumor hypoxic environment, FoxO4 reduces the level of hypoxia-inducible factor 1 α (HIF-1 α) protein, thereby inhibiting responses to hypoxia, such as the expression of glucose transporter type 1 (GLUT-1), erythropoietin (EPO) and vascular epithelial growth factor (VEGF). These processes are involved in the procession of glucose metabolism, erythropoiesis and angiogenesis, and are essential for tumor development (TangLasky 2003). Down regulation of FoxO4 also significantly associates

with low-grade, lymph node metastases and TNM III,IV tumors in colorectal cancer (Xiang-qiang et al., 2011). In colorectal SW480 cancer cells, miR-499-5p which was involved in metastasis could specifically bind to the 3'-UTR of FoxO4 and decreased the expression level of FoxO4 mRNA and protein (Liu et al., 2011).

However, the correlation between the expression of FoxO4 and EMT in NSCLC is still unclear. In this study, we investigated the expression of FoxO4 in 8-paired NSCLC cases. Immunohistochemistry was used to characterize the expression of FoxO4 and EMT indicators. In addition, we analyzed the relationship between the expression of FoxO4 and clinicopathologic parameters, EMT indicators and patients' survival.

Materials and Methods

Materials

Surgically resected 150 NSCLC samples between 2005 and 2007 from the Affiliated Hospital of Nantong University were formalin-fixed and paraffin-embedded for histopathologic diagnosis. The histological type, differentiated degree, lymph node metastasis, tumor size and TNM stage (according to the 7th Edition) (Groome et al., 2007) were showed in the Table 1. Another 10 cases of normal lung tissues were set as control. All specimens were fixed with 10% formaldehyde, dehydration, conventional paraffin embedding, made into tissue microarray (TMA) sections. In addition, we took the 8 freshly frozen NSCLC tissues and matched adjacent tissues for Western blot analysis. This study was approved by Ethics Committee of the Affiliated Hospital of Nantong University.

Immunohistochemistry

We adopted conventional immunohistochemical SP method in this study. Tissue microarray (TMA) sections of 4 μ m were cut, deparaffinized and rehydrated. Endogenous peroxidase was blocked for 15 min by 3% hydrogen peroxide. Antigen retrieval was conducted by microwave for 15 min within citrate buffer solution (PH=6.0). The sections were blocked with 2% normal goat serum for 30 min. The slides were then incubated with the diluted following antibodies: rabbit monoclonal anti-FoxO4 (Abcam, USA), mouse monoclonal anti-E-cadherin (Bioworld, USA) and mouse monoclonal anti-Vimentin (Bioworld, USA) overnight at 4°C. Subsequently, HRP-labeled goat anti-rabbit immunoglobulins, the secondary antibody was used for 30 min at 37°C. The 3, 3'-diaminobenzidine (DAB, Bioworld) solution was used as a chromogen. The slides were washed by water, and then counterstained with hematoxylin. Positive and negative controls were conducted throughout.

Immunohistochemical evaluation

Immunohistochemical evaluation was conducted independently by two pathologists unaware of clinical data. The expression of FoxO4 was based on the presence of cytoplasm with or without nucleus staining in NSCLC, while in normal lung tissues the expression of FoxO4 was mainly in nucleus. The expression of FoxO4 was evaluated by the ratio of staining intensity and positive

Table 1. Correlation Between FoxO4 Expression and Clinicopathologic Parameters in 150 NSCLC Specimens

Parameters	Total FoxO4 expression			P-value
	Low	High		
Age (year)				
≤60	56	35	21	0.323
>60	94	51	43	
Gender				
Male	122	68	54	0.41
Female	28	18	10	
Tumor size (cm)				
≤3	45	21	24	0.084
>3	105	65	40	
Smoking status				
Yes	54	32	22	0.721
No	96	54	42	
Histological type				
Adenocarcinoma	41	27	14	0.281
Squamous cell carcinoma	97	51	46	
Adenosquamous carcinoma	12	8	4	
Clinical stage				
I	40	9	31	<0.001*
II	69	39	30	
III	41	38	3	
Histological differentiation				
Well	16	6	10	0.004*
Mod	82	41	41	
Poor	52	39	13	
Lymph node status				
0	40	8	32	<0.001*
>0	110	78	32	
E-cadherin expression				
Positive	58	22	36	<0.001*
Negative	92	64	28	
Vimentin expression				
Positive	83	56	27	0.005*
Negative	67	30	37	

Note, Statistical analyses were performed by the Pearson χ^2 test. * $P < 0.05$ was considered significant

cells per specimen. The percentage of positive tumor cells (<1%, 0; 2~25%, 1; 26~50%, 2; 51~75%, 3; >75%, 4) and staining intensity (0, negative; 1, weak; 2, moderate; 3, strong;) were evaluated at five areas at 4X10 and 10X magnification. At last, FoxO4 staining score was defined as follows: 0~3, -; 4~6, +; 7~9, ++; 10~12, +++ (Xiang-qiang et al., 2011). E-cadherin expression was defined as positive when >70% of tumor cells showed membranous staining in the entire tumors (Awaya et al., 2005). Vimentin expression was often found in tumor cytoplasm, and more than 20% of tumor cells showed that cytoplasm staining was positive (Xu et al., 2013).

Western blot

Tissue proteins were resolved by 10% SDS-PAGE and transferred on to a polyvinylidene fluoride (PVDF) membrane. The membranes were blocked by 5% nonfat milk for 1h and incubated with primary antibody (rabbit monoclonal anti-FoxO4) for 1h at 37°C and washed with PBST. At last, membranes were incubated with a horseradish peroxidase-conjugated secondary antibody for 1h at room temperature. The signals were visualized

with ECL detection reagent. The density on the film were measured using ImageQuant image analysis system. GAPDH was detected using mouse anti-GAPDH antibody as a loading control. The experiment was repeated for three times.

Statistical methods

The expression level of FoxO4 protein in freshly frozen NSCLC tissues and matched adjacent tissues were normalized to GAPDH and analyzed. The Chi-square was used to analyze the statistical significance of the relationship respectively between FoxO4, E-cadherin, Vimentin and clinical pathological features. The survival curve of FoxO4's expression was computed by the method of Kaplan-Meier. The prognostic influence of factors on survival was analyzed by using a multivariate Cox regression model. A P value of less than 0.05 was considered as statistically significant. Spss 17.0 software was used for statistical analysis.

Results

Expression of FoxO4, E-cadherin and Vimentin in NSCLC

Immunohistochemistry (IHC) was used to confirm the expression of FoxO4, E-cadherin and Vimentin in NSCLC tissues. Positive staining FoxO4 was mainly localized in NSCLC cells in nucleus and /or cytoplasm at different levels. Low expression of FoxO4 was detected in 42.67% of NSCLC tissues and was in 90.00% of matched adjacent normal tissues. Positive staining of E-cadherin and Vimentin were respectively localized in cell membrane and cytoplasm. E-cadherin immunoreactivity was identified in 58 cases (38.67%) of NSCLC tissues, while positive staining of Vimentin was detected in 83 cases (55.34%).

To investigate the difference expression of FoxO4 in paired NSCLC tissues, eight pairs of representative cases were tested by western blot. The results showed that FoxO4 protein was overexpressed in normal lung tissues compared with NSCLC tissues.

Relationship between the expression of FoxO4 protein and clinicopathological factors in NSCLC

By analyzing the NSCLC clinicopathological features, we found that there was statistically significant difference in expression of FoxO4 protein between different TNM stages ($P < 0.001$), histological differentiation ($P = 0.004$) and lymph node metastasis ($P < 0.001$). In contrast, no significant association was seen in patient gender, age, histological type, tumor diameter. The association between expression of FoxO4 protein and clinicopathological features was shown in Table 1.

Relationship between FoxO4 protein and EMT representative proteins

The relationships between them were shown in Table 1. We found that positive staining of epithelial protein E-cadherin was detected in 58 cases (38.67%). However, the mesenchymal protein expression was 55.34% in the same samples. We noted that the low expression of FoxO4 correlated with a loss of E-cadherin expression ($P < 0.001$)

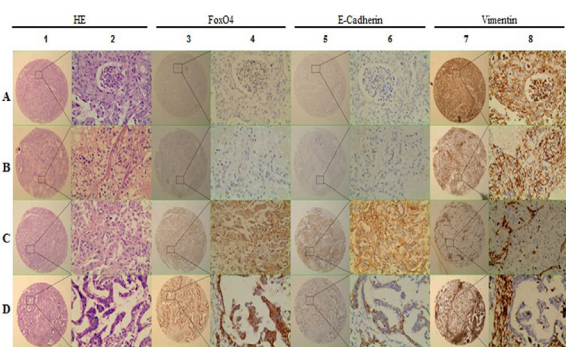


Figure 1. Expression Profiles of FoxO4 in NSCLC and Non-tumorous Adjacent Tissues. Western blot was performed to study the levels of FoxO4 in 8 representative paired samples of NSCLC tissue (T) and non-tumorous adjacent tissues (N). GAPDH was used as a loading control. The same experiment was repeated at least 3 times

Table 2. Contribution of Various Potential Prognostic Factors to Survival by Cox Regression Analysis on 150 NSCLC Specimens

	Hazard ratio	95.0% Confidence interval	P
Age	1.277	0.878-1.856	0.2
Gender	1.088	0.639-1.853	0.755
Tumor size	1.322	0.862-2.026	0.2
Smoking status	0.922	0.616-1.378	0.691
Histological type	1.217	0.873-1.697	0.247
Clinical stage	3.609	2.463-5.286	<0.001*
Histological differentiation	0.771	0.563-1.056	0.105
Lymph node status	0.744	0.435-1.274	0.282
FoxO4 expression	1.529	1.008-2.320	0.046*
E-cadherin expression	1.916	1.258-2.918	0.002*
Vimentin expression	0.58	0.389-0.867	0.008*

Note, Statistical analyses were performed by the Cox regression analysis. * $P < 0.05$ was considered significant

and highly positive staining of Vimentin ($P=0.005$) in NSCLC samples

High expression of FoxO4 correlated with better overall survival rate

Survival analysis was restricted to 150 patients with follow-up data until death. After all variable were compared separately with survival status, we found FoxO4 ($P=0.046$), E-cadherin ($P=0.002$), Vimentin ($P=0.008$) and clinical stage ($P<0.001$) significantly influenced survival (Table 2). Kaplan-Meier survival curves showed that high expression of FoxO4 correlated with better survival with statistical significance ($P<0.001$; Figure 3). In conclusion, multivariate analysis using the Cox’s proportional hazards model proved that FoxO4 ($P=0.046$; Table 2) was a prognostic factor for patients’ overall survival.

Discussion

In this study, we used a TMA to identify that FoxO4 played an important role in the progression of EMT. In addition, through measuring the expression of FoxO4 in NSCLC tissues, we revealed strong association between the expression of FoxO4 and several clinicopathologic

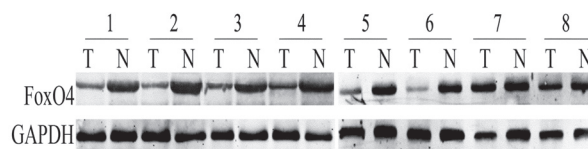


Figure 2. Representative IHC Images Showing Expression of FoxO4 and EMT-related Biomarkers in TMA Sections of NSCLC. (A) 1 and 2: lung squamous cell carcinoma tissue pattern with HE staining; 3 and 4: low expression of FoxO4; 5 and 6: loss of E-cadherin expression; 7 and 8: strong Vimentin-positive staining. (B) 1 and 2: lung adenocarcinoma tissue pattern with HE staining; 3 and 4: negative IHC for FoxO4; 5 and 6: loss of E-cadherin expression; 7 and 8: positive staining for Vimentin. (C) 1 and 2: lung squamous cell carcinoma tissue pattern with HE staining; 3 and 4: high expression of FoxO4; 5 and 6: up-regulated expression of E-cadherin; 7 and 8: negative IHC for Vimentin. (D) 1 and 2: lung adenocarcinoma tissue pattern with HE staining; 3 and 4: strong immunological of FoxO4; 5 and 6: high expression of E-cadherin; 7 and 8: negative for Vimentin

parameters such as histological differentiation, TNM stage and EMT indicators. Lastly, multivariate analysis showed that FoxO4 might be used as a prognostic factor for NSCLC.

Unfortunately, at the first diagnosis, almost 56% lung cancer patients are diagnosed at advanced stage. Metastasis predicts a poor prognosis and is the main cause of NSCLC patients’ death. Through metastasis, NSCLC cells are easily found in the bone, adrenal glands, liver, brain and regional lymph nodes. The progression of metastasis, namely metastatic cascade contains many steps including invasion, EMT, angiogenesis, vessels transportation, MET and secondary tumors growth (GeigerPeeper 2009). The important bases of molecular and cellular mechanisms are the diminished capacity of tumor cells adhesion while increasing cells’ motility (GeigerPeeper 2009). Therefore, EMT becomes the essential role in the process of tumor invasion and metastasis, and is often considered as a prelude to tumor metastasis (Wells et al., 2008). Importantly, advanced tumor cells show an obvious down-regulation of epithelial markers like E-cadherin, cytokeratin, resulting in the reduced cell adhesion. However, over-expression of the mesenchymal proteins like Vimentin and N-cadherin are responsible for increasing cells’ motility (SatelliLi 2011). E-cadherin was significantly related to the degree of EMT and tumor malignancy, for example in lung cancer (Bremnes et al., 2002), gastric cancer (JooRewChoi et al., 2002), skin cancer (McGary et al., 2002), breast cancer (BexxVan Roy 2001), pancreatic cancer (JooRewPark et al., 2002) and nasopharyngeal cancer (Tsao et al., 2003). Recently, studies have demonstrated that the positive expression rate of E-cadherin in NSCLC tissue without lymphatic metastasis was significantly higher than that with lymphatic metastasis (47.2% vs. 21.6%) (Su et al., 2014). Earlier studies showed that expression of E-cadherin was associated with the patients’ survival in NSCLC (Wang et al., 2011). For many years, we just know Vimentin is a marker for EMT, however, its function of taking part in the process of EMT is still unclear (Ivaska 2011). Some researches showed that over-expression of Vimentin

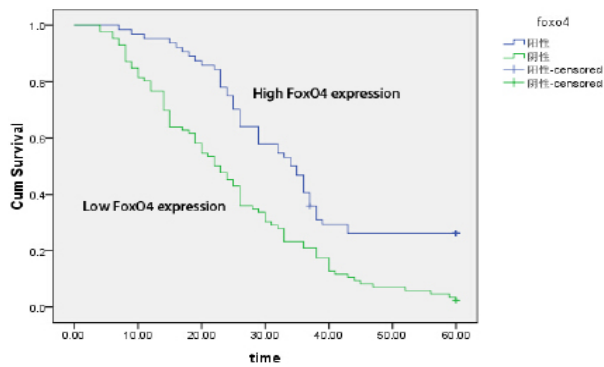


Figure 3. Correlation Between FoxO4 Expression and Patients' Survival. Kaplan-Meier survival curves for low versus high FoxO4 expression on 150 patients with NSCLC showed a highly significant separation between curves ($P<0.001$)

indicated poor prognosis (Soltermann et al., 2008). In our study, E-cadherin and Vimentin both correlated with survival in NSCLC in our multivariate analysis.

Recently, Lee et al suggested FoxO4 might play an important role in inhibiting the process of EMT in cholangiocarcinoma (Lee et al., 2009). But there is no report to state the relationship between FoxO4 and EMT in NSCLC. By contrast, TIAM2 could promote EMT in NSCLC cells by down-regulating the expression of E-cadherin, and up-regulating the expression of Twist, MMP-3 and Snail (Zhao et al., 2013). In this study, FoxO4 and two EMT markers were detected in NSCLC TMA tissues by immunohistochemistry on 150 paraffin-embedded slices. Interestingly, we found that the low level of expression for FoxO4 correlated with decreased expression of E-cadherin and elevated expression of Vimentin. Besides, FoxO4 significantly associated with the histological differentiation ($P=0.004$), TNM stage ($P<0.001$) as well as the lymph node metastasis ($P<0.001$; Table 1). The results were correlated with the expression of FoxO4 in colorectal cancer (Xiang-qiang et al., 2011). What's more, FoxO4 was lowly-expressed in NSCLC fresh frozen tissues as compared with adjacent normal tissues by western blot (Figure 1). Multivariate analysis using the Cox's proportion hazards model, indicated that FoxO4 might be an independent prognostic factor in NSCLC ($P=0.046$; Table 2). Survival curve showed that low expression of FoxO4 correlated with poor prognosis with strong statistical significance ($P<0.001$).

To our knowledge, we were the first to study the relation between FoxO4 and EMT in NSCLC. Our findings suggested that FoxO4 might inhibit the process of EMT in NSCLC and be a potentially therapeutic target for NSCLC. The exact molecular mechanisms of FoxO4 in NSCLC pathogenesis remain to be revealed.

References

- Awaya H, Takeshima Y, Amatya VJ, et al (2005). Loss of expression of E-cadherin and beta-catenin is associated with progression of pulmonary adenocarcinoma. *Pathol Int*, **55**, 14-8.
- Berx G, Van Roy F (2001). The E-cadherin/catenin complex: an important gatekeeper in breast cancer tumorigenesis and malignant progression. *Breast Cancer Res*, **3**, 289-93.
- Boura E, Silhan J, Herman P, et al (2007). Both the N-terminal loop and wing W2 of the forkhead domain of transcription factor Foxo4 are important for DNA binding. *J Biol Chem*, **282**, 8265-75.
- Bremnes RM, Veve R, Hirsch FR, Franklin WA (2002). The E-cadherin cell-cell adhesion complex and lung cancer invasion, metastasis, and prognosis. *Lung Cancer*, **36**, 115-24.
- Burgering BM (2008). A brief introduction to FOXology. *Oncogene*, **27**, 2258-62.
- Calnan DR, Brunet A (2008). The FoxO code. *Oncogene*, **27**, 2276-88.
- Chen L, Tang Y, Wang J, Yan Z, Xu R (2013). miR-421 induces cell proliferation and apoptosis resistance in human nasopharyngeal carcinoma via downregulation of FOXO4. *Biochem Biophys Res Commun*, **435**, 745-50.
- Chuang PY, Yu Q, Fang W, Uribarri J, He JC (2007). Advanced glycation endproducts induce podocyte apoptosis by activation of the FOXO4 transcription factor. *Kidney Int*, **72**, 965-76.
- Dansen TB, Smits LM, van Triest MH, et al (2009). Redox-sensitive cysteines bridge p300/CBP-mediated acetylation and FoxO4 activity. *Nature Chem Biol*, **5**, 664-72.
- Fan FT, Shen CS, Tao L, et al (2014). PKM2 Regulates hepatocellular carcinoma cell epithelial-mesenchymal transition and migration upon EGFR activation. *Asian Pac J Cancer Prev*, **15**, 1961-70.
- Faroni C, Broggin M, Generali D, Damia G (2012). Epithelial-mesenchymal transition and breast cancer: role, molecular mechanisms and clinical impact. *Cancer Treat Rev*, **38**, 689-97.
- Geiger TR, Peeper DS (2009). Metastasis mechanisms. *Biochim Biophys Acta-Reviews on Cancer*, **1796**, 293-308.
- Groome PA, Bolejack V, Crowley JJ, et al (2007). The IASLC Lung Cancer Staging Project: validation of the proposals for revision of the T, N, and M descriptors and consequent stage groupings in the forthcoming (seventh) edition of the TNM classification of malignant tumours. *J Thorac Oncol*, **2**, 694-705.
- Ivaska J (2011). Vimentin: Central hub in EMT induction? *Small Gtpases*, **2**, 51-3.
- Jemal A, Siegel R, Ward E, et al (2008). Cancer statistics, 2008. *CA Cancer J Clin*, **58**, 71-96.
- Joo YE, Rew JS, Choi SK, et al (2002). Expression of E-cadherin and catenins in early gastric cancer. *J Clin Gastroenterol*, **35**, 35-42.
- Joo YE, Rew JS, Park CS, Kim SJ (2002). Expression of E-cadherin, alpha-and beta-catenins in patients with pancreatic adenocarcinoma. *Pancreatol*, **2**, 129-37.
- Kalluri R, Weinberg RA (2009). The basics of epithelial-mesenchymal transition. *J Clin Invest*, **119**, 1420.
- Katoh M (2004). Human FOX gene family (Review). *Int J Oncol*, **25**, 1495-500.
- Kops GJ, de Rooter ND, De Vries-Smits AM, et al (1999). Direct control of the Forkhead transcription factor AFX by protein kinase B. *Nature*, **398**, 630-4.
- Lee MJ, Yu GR, Yoo HJ, et al (2009). ANXA8 down-regulation by EGF-FOXO4 signaling is involved in cell scattering and tumor metastasis of cholangiocarcinoma. *Gastroenterology*, **137**, 1138-50, 50 e1-9.
- Liu X, Zhang Z, Sun L, et al (2011). MicroRNA-499-5p promotes cellular invasion and tumor metastasis in colorectal cancer by targeting FOXO4 and PDCD4. *Carcinogenesis*, **32**, 1798-805.
- Liu Y (2010). New insights into epithelial-mesenchymal transition in kidney fibrosis. *J Am Soc Nephrol*, **21**, 212-22.
- Lopez-Novoa JM, Nieto MA (2009). Inflammation and EMT:

- an alliance towards organ fibrosis and cancer progression. *EMBO Mol Med*, **1**, 303-14.
- Lupertz R, Chovolou Y, Unfried K, et al (2008). The forkhead transcription factor FOXO4 sensitizes cancer cells to doxorubicin-mediated cytotoxicity. *Carcinogenesis*, **29**, 2045-52.
- McGary EC, Lev DC, Bar-Eli M (2002). Cellular adhesion pathways and metastatic potential of human melanoma. *Cancer Biol Ther*, **1**, 459-65.
- Obsilova V, Vecer J, Herman P, et al (2005). 14-3-3 Protein interacts with nuclear localization sequence of forkhead transcription factor FoxO4. *Biochemistry*, **44**, 11608-17.
- Satelli A, Li S (2011). Vimentin in cancer and its potential as a molecular target for cancer therapy. *Cell Mol Life Sci*, **68**, 3033-46.
- Shi X, Wallis AM, Gerard RD, et al (2012). Foxk1 promotes cell proliferation and represses myogenic differentiation by regulating Foxo4 and Mef2. *J Cell Sci*, **125**, 5329-37.
- Silhan J, Vacha P, Strnadova P, et al (2009). 14-3-3 protein masks the DNA binding interface of forkhead transcription factor FOXO4. *J Biol Chem*, **284**, 19349-60.
- Soltermann A, Tischler V, Arbogast S, et al (2008). Prognostic significance of epithelial-mesenchymal and mesenchymal-epithelial transition protein expression in non-small cell lung cancer. *Clin Cancer Res*, **14**, 7430-7.
- Su CY, Li YS, Han Y, Zhou SJ, Liu ZD (2014). Correlation between expression of cell adhesion molecules CD44 v6 and E-cadherin and lymphatic metastasis in non-small cell lung cancer. *Asian Pac J Cancer Prev*, **15**, 2221-4.
- Tang TT, Lasky LA (2003). The forkhead transcription factor FOXO4 induces the down-regulation of hypoxia-inducible factor 1 alpha by a von Hippel-Lindau protein-independent mechanism. *J Biol Chem*, **278**, 30125-35.
- Thiery JP, Acloque H, Huang RY, Nieto MA (2009). Epithelial-mesenchymal transitions in development and disease. *Cell*, **139**, 871-90.
- Tran H, Brunet A, Grenier JM, et al (2002). DNA repair pathway stimulated by the forkhead transcription factor FOXO3a through the Gadd45 protein. *Science*, **296**, 530-4.
- Tsao S, Liu Y, Wang X, et al (2003). The association of E-cadherin expression and the methylation status of the E-cadherin gene in nasopharyngeal carcinoma cells. *Eur J Cancer*, **39**, 524-31.
- Vaid M, Singh T, Katiyar SK (2011). Grape seed proanthocyanidins inhibit melanoma cell invasiveness by reduction of PGE2 synthesis and reversal of epithelial-to-mesenchymal transition. *PLoS One*, **6**, e21539.
- Wang G, Dong W, Shen H, et al (2011). A comparison of Twist and E-cadherin protein expression in primary non-small-cell lung carcinoma and corresponding metastases. *European J Cardio-Thoracic Surg* **39**, 1028-32.
- Wells A, Yates C, Shepard CR (2008). E-cadherin as an indicator of mesenchymal to epithelial reverting transitions during the metastatic seeding of disseminated carcinomas. *Clin Exp Metastasis*, **25**, 621-8.
- Wen C, Dehnel T (2011). China wrestles with lung cancer. *Lancet Oncol*, **12**, 15.
- Xiang-qiang L, Shan-hong T, Zhi-yong Z, Hai-feng J (2011). [Expression and clinical significance of FOXO4 in colorectal cancer]. *Xi Bao Yu Fen Zi Mian Yi Xue Za Zhi*, **27**, 969-71.
- Xu B, Jin DY, Lou WH, Wang DS (2013). Lipocalin-2 is associated with a good prognosis and reversing epithelial-to-mesenchymal transition in pancreatic cancer. *World J Surg*, **37**, 1892-900.
- Yang H, Zhao R, Yang HY, Lee MH (2005). Constitutively active FOXO4 inhibits Akt activity, regulates p27 Kip1 stability, and suppresses HER2-mediated tumorigenicity. *Oncogene*, **24**, 1924-35.
- Zhao ZY, Han CG, Liu JT, et al (2013). TIAM2 enhances non-small cell lung cancer cell invasion and motility. *Asian Pac J Cancer Prev*, **14**, 6305-9.