

## RESEARCH ARTICLE

# Comparative Evaluation of Two-dimensional Radiography and Three Dimensional Computed Tomography Based Dose-volume Parameters for High-dose-rate Intracavitary Brachytherapy of Cervical Cancer: A Prospective Study

Renu Madan<sup>1</sup>, Sushmita Pathy<sup>1\*</sup>, Vellaiyan Subramani<sup>1</sup>, Seema Sharma<sup>1</sup>, Bidhu Kalyan Mohanti<sup>1</sup>, Subhash Chander<sup>1</sup>, Sanjay Thulkar<sup>2</sup>, Lalit Kumar<sup>3</sup>, Vatsla Dadhwal<sup>4</sup>

### Abstract

**Background:** Dosimetric comparison of two dimensional (2D) radiography and three-dimensional computed tomography (3D-CT) based dose distributions with high-dose-rate (HDR) intracavitary radiotherapy (ICRT) for carcinoma cervix, in terms of target coverage and doses to bladder and rectum. **Materials and Methods:** Sixty four sessions of HDR ICRT were performed in 22 patients. External beam radiotherapy to pelvis at a dose of 50 Gray in 27 fractions followed by HDR ICRT, 21 Grays to point A in 3 sessions, one week apart was planned. All patients underwent 2D-orthogonal and 3D-CT simulation for each session. Treatment plans were generated using 2D-orthogonal images and dose prescription was made at point A. 3D plans were generated using 3D-CT images after delineating target volume and organs at risk. Comparative evaluation of 2D and 3D treatment planning was made for each session in terms of target coverage (dose received by 90%, 95% and 100% of the target volume: D90, D95 and D100 respectively) and doses to bladder and rectum: ICRU-38 bladder and rectum point dose in 2D planning and dose to 0.1cc, 1cc, 2cc, 5cc, and 10cc of bladder and rectum in 3D planning. **Results:** Mean doses received by 100% and 90% of the target volume were  $4.24 \pm 0.63$  and  $4.9 \pm 0.56$  Gy respectively. Doses received by 0.1cc, 1cc and 2cc volume of bladder were  $2.88 \pm 0.72$ ,  $2.5 \pm 0.65$  and  $2.2 \pm 0.57$  times more than the ICRU bladder reference point. Similarly, doses received by 0.1cc, 1cc and 2cc of rectum were  $1.80 \pm 0.5$ ,  $1.48 \pm 0.41$  and  $1.35 \pm 0.37$  times higher than ICRU rectal reference point. **Conclusions:** Dosimetric comparative evaluation of 2D and 3D CT based treatment planning for the same brachytherapy session demonstrates underestimation of OAR doses and overestimation of target coverage in 2D treatment planning.

**Keywords:** Cervical cancer - image based brachytherapy - dose-volume parameter

*Asian Pac J Cancer Prev*, 15 (11), 4717-4721

### Introduction

Cervical cancer is the fourth most common cancer in women, and the seventh overall, with an estimated 528,000 new cases in 2012 (Forman et al., 2013). Radiotherapy is an important modality in treatment of cervical cancer and includes external beam radiotherapy (EBRT) and brachytherapy. Therefore brachytherapy is an integral component in the management of cervical cancer. It is indicated after EBRT in locally advanced disease and also in early stage disease (Logsdon and Eifel, 1999; Nag et al., 2000). Conventional brachytherapy is based on clinical examination and 2D point based planning using

fixed bony landmarks and orthogonal x-ray images for dose calculations and prescriptions irrespective of size or shape of tumour. This leads to inadequate target coverage and insufficient dose delivery and treatment failure for larger asymmetrical tumours. Newer advances in imaging including computed tomography, magnetic resonance imaging and F-fluorodeoxyglucose positron emission tomography has significant role in cancer staging and management (Petsuksiri et al., 2012). Given the limitation of two dimensional (2D) treatment planning, three-dimensional (3D) image based intracavitary brachytherapy (ICRT) visualizes tumour and adjacent organ and provides improved target coverage, local control and reduced late

<sup>1</sup>Department of Radiation Oncology, <sup>2</sup>Department of Radiodiagnosis, <sup>3</sup>Department of Medical Oncology, Dr. B. R. Ambedkar Institute Rotary Cancer Hospital, <sup>4</sup>Department of Obstetrics and Gynecology, All India Institute of Medical Sciences, New Delhi, India \*For correspondence: drspathy@gmail.com

toxicity (Petsuksiri et al., 2012; Sadozye and Reed, 2012).

In 2D treatment planning the dose to organs at risk (OAR) is calculated from International Commission on Radiation Units and Measurement (ICRU 38) reference points. However this does not provide volumetric information and spatial relationship between applicator and OAR. Dose calculation and target coverage inaccuracy may occur due to anatomical variation and tumor size thus compromising target coverage and tumor control (Tharavichitkul et al., 2011). Complete coverage of target is important to encompass the entire tumor volume which can result in better local control and clinical outcome. Dose to bladder and rectal reference points may not correspond to maximum bladder and rectal dose. Evaluation of doses to bladder and rectum are crucial because of close proximity of these organs to cervix and associated late toxicities (Eifel et al., 1995; Nakano et al., 2005). Compared to conventional 2-D planning, image based treatment planning is beneficial for evaluating dose volume parameters to target and OAR. Therefore image based brachytherapy technique can optimize and individualize treatment planning. Previous studies have shown that CT based brachytherapy is feasible and several guidelines for image based brachytherapy have already been published in the literature (Nag et al., 2004; Potter et al., 2006).

It was hypothesised that therapeutic ratio including target coverage and sparing of organs at risk can be significantly improved, if the radiation dose is prescribed to 3D image based CTV taking into account dose volume constraints for OARs.

Our center currently practices the 2D radiography based ICRT. The comparison between 2D and 3D CT based treatment planning was made to ascertain the potential benefit of target coverage, sparing of OAR and treatment outcome. Though magnetic resonance imaging (MRI) has been clearly established to be superior to any other imaging in cervical cancer for tumor delineation and adjacent soft tissue, MRI based treatment planning is not possible in our center due to logistic reasons: different building location and patient burden. This prompted us to carry out the study based on 3D-CT based brachytherapy, and subsequently changing over to CT based 3D planning in future. The present study was aimed to evaluate doses to target, bladder and rectum using 3D CT based dose volume parameter and to compare this with conventional 2D radiography based point dose to target and ICRU bladder and rectum reference points.

## Materials and Methods

### Patient characteristics

Between January 2009 to January 2010, 78 patients were registered in Gynecologic Oncology and Radiotherapy clinic in Dr. B. R. Ambedkar Institute Rotary Cancer Hospital, All India Institute of Medical Sciences. Twenty two patients with biopsy proven cervical cancer were prospectively enrolled in the study protocol approved by Institutes Ethics Committee (Figure 1). Written informed consent was obtained from all patients prior to treatment initiation. A total of 64 sessions of ICRT were performed

in 22 patients.

Pre-treatment evaluation included detailed history and physical examination, routine haematological and biochemical investigations, chest radiograph, computed tomography of abdomen and pelvis, cystoscopy and sigmoidoscopy to assess local spread and to rule out distant metastasis. CT scan of abdomen and pelvis was repeated after completion of EBRT for assessment of gross tumor response. Clinical staging was completed as per FIGO staging system. A baseline detailed pelvic examination was done and findings were depicted with diagram.

### Treatment details

In all patients, EBRT was given after simulation using four field box technique by Theratron 780C (Best Theratronics, Ottawa Canada) or by 6MV/15 MV photon using Linear accelerator (Elekta Medical Systems Crawley, UK). EBRT was given to a dose of 50 Gy in 27 fractions, five days in a week with concurrent Cisplatin weekly (40mg/m<sup>2</sup>) during the course of external beam radiotherapy.

ICRT was delivered after one week of completion of EBRT by Microselectron HDR unit, Nucletron an Elekta company (Elekta AB, Stockholm, Sweden). Dose prescription was 21 Gray to point A in 3 sessions one week apart.

### Brachytherapy application

Each application was made under general anesthesia or spinal anesthesia, with a detail gynecological evaluation under anesthesia. Foleys catheter was inserted and fixed against the bladder neck. Bladder balloon was filled with 7cc of non- ionic contrast. CT/MRI compatible Fletcher-Suit applicator consisting of uterine tandem with various angles (150, 300, 450) and a pair of ovoids with various diameter (20, 25, 30 mm) were used for brachytherapy. Adequate vaginal packing was made and stability of the applicator was ensured.

### Brachytherapy planning and treatment

All patients underwent 2D-orthogonal and 3D-CT simulation for each session. Treatment plan were generated using 2D-orthogonal images and dose prescription was made at point A. After evaluation of dose distribution obtained with 2D-orthogonal simulation, patients were shifted to treatment room. Treatment was carried out by

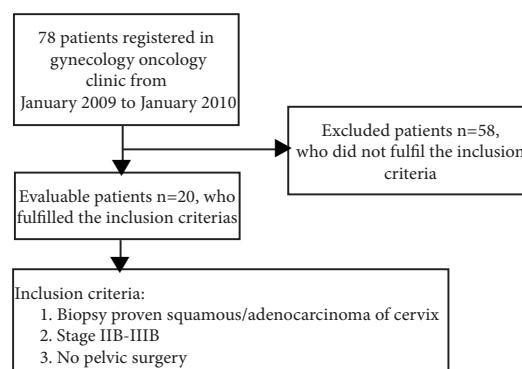


Figure 1. Study Protocol

Microselectron-HDR as per the conventional planning. Subsequently, 3D plan was generated using CT images after delineating target volume and critical structures. All parameters like source loading pattern, optimization were kept constant for the true comparison.

### 2D-Orthogonal (Conventional) planning

To identify the catheters in 2D treatment planning, dummy markers were placed into catheters. For rectal points dummy marker with multiple radiopaque balls was inserted into the rectum. For bladder points, 7cc contrast material was administered to Foleys bulb. Orthogonal films were taken using simulator (Nucletron an Elekta company). After simulation images were sent to Plato treatment planning system (Nucletron an Elekta company) via DICOM RT network. After importing images in treatment planning system (TPS), catheters were reconstructed using tracking method at 2.5mm step size. ICRU bladder and rectum points were marked. (Fig 2&3) Dose prescription was made at point A. Plan evaluation as per ICRU-38 guidelines was made and doses to bladder and rectum were noted. Attempts were made to keep these doses below 70% of prescribed dose for each fraction. In few cases dwell weight optimization was used as per clinical requirement.

### 3D CT based planning

CT simulation was made using, Brilliance Big Bore CT simulator (Phillips Medical System Cleveland, OH, USA) with radio-opaque markers at 3mm slice thickness. The images were transferred to PLATO TPS, (Elekta AB, and Stockholm, Sweden) by DICOM RT network.

### After importing images in TPS

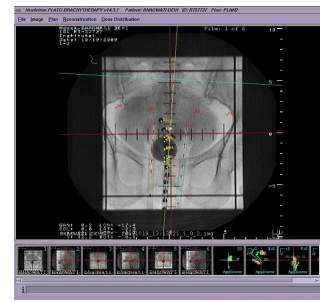
Target was contoured using CT images, based on clinical findings and CT information considering Vishwanathan et al guidelines (Vishwanathan et al., 2007). Target delineation included residual disease, entire cervix with 1 cm margin taking into account the clinical examination under anaesthesia at time of brachytherapy application. The rectum was contoured from 1 cm above anus, up to the recto-sigmoid junction. The bladder was contoured as an entire organ included the outer wall of the bladder up to the beginning of urethra (Figure 4).

The applicators were reconstructed by selecting and tracking dummies on each slice of CT images. Sources were loaded for both ovoid and tandem in a similar way as used for 2D planning. Optimization and all other planning parameters were kept same as in 2D planning.

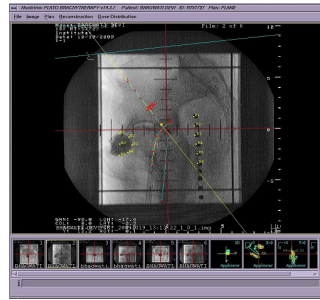
For plan evaluation, the dose received by 0.1cc, 1cc, 2cc, 5cc and 10 cc of bladder and rectum were noted. The target coverage for 100%, 95% and 90% (D100, D95 and D90 respectively) of prescribed dose were calculated for each session (Figure 5). The volumetric bladder and rectum doses were compared with corresponding ICRU reference points.

### Statistical analysis

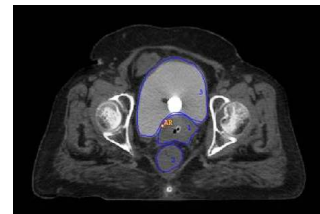
Paired t-test using STATA 11.2 version was used to compare 2D radiography and 3D -CT based treatment planning for target coverage and dose to organ at risk.



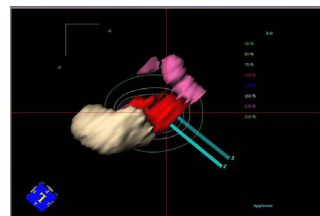
**Figure 2. Antero-posterior Film 2 D Planning**



**Figure 3. Lateral Film 2 D Planning**



**Figure 4. Cross Sectional Image of 3D CT Based Treatment Planning**



**Figure 5. Target Coverage in 3D Planning- Cross-Sectional Image on Treatment Planning System**

## Results

The median age of the patients was 56 years. Majority of the patients were presented in FIGO stage IIIB (64%). The median Karnofsky performance status (KPS) was 80. Table 1 shows the distribution of patient characteristics. All patients received pelvic EBRT with concurrent cisplatin followed by 3 sessions of ICRT.

The mean dose to point A in each sessions was 7 Gy in radiography based treatment planning. However when the 2-D plan was compared with the CT based 3D planning, it showed that mean dose received by 100%, 95% and 90% of the target volume (D100, D95 and D90 respectively) was only  $4.24 \pm 0.63$ ,  $4.6 \pm 0.56$  and  $4.9 \pm 0.56$  Gy respectively (Table 2)

The dosimetric results for bladder and rectum are shown in Table 3. It demonstrates the difference of doses received by 0.1cc, 1cc, 2 cc volume of bladder and ICRU bladder reference point was 4.76 Gy (95% CI 4.42, 5.10, p 0.001), 3.76 Gy (95% CI 3.46, 4.07, p-0.001) and 3.06

**Table 1. Patient Characteristics**

Patient characteristics		No of patients
Age	<60	14
	>60	8
FIGO Stage	IIB	8
	IIIB	14
KPS	>80	12
	<80	10
Histology	SCC	22
	Others	0

\*KPS: Karnofsky performance status; FIGO: International Federation of Gynecology and Oncology; SCC: Squamous cell carcinoma

**Table 2. Target Coverage in Three Dimensional (3D) CT Based Treatment Planning**

Mean dose (Gray)	4.24±0.63	6±0.56	4.9±0.56
------------------	-----------	--------	----------

\*D100: Dose received by 100% of target volume; D95: Dose received by 95% of target volume; D90: Dose received by 90% of target volume

**Table 3. Summary of Doses to ICRU Bladder and Rectal Reference Points in 2D Treatment Planning and Doses to 0.1cc, 1cc, 2cc, 5cc and 10cc of Bladder and Rectum using 3D DVH Parameters for OAR**

Column1	ICRU point dose	D <sub>0.1cc</sub>	D <sub>1cc</sub>	D <sub>2cc</sub>	D <sub>5cc</sub>	D <sub>10cc</sub>
Bladder (Gray)	2.62	7.14	6.1	5.56	5.01	4.35
Rectum (Gray)	3.53	6.25	5.13	4.68	3.96	3.22

**Table 4. Ratio of D<sub>0.1cc</sub>, D<sub>1cc</sub> and D<sub>2cc</sub> Doses and ICRU Point Dose for Rectum and Bladder**

	D <sub>0.1cc</sub> /ICRU point dose	D <sub>1cc</sub> /ICRU point dose	D <sub>2cc</sub> /ICRU point dose
Bladder	2.88±0.72	2.5±0.65	2.2±0.57
Rectum	1.80±0.5	1.48±0.41	1.35±0.37

**Table 5. Difference between D<sub>0.1cc</sub>, D<sub>1cc</sub> and D<sub>2cc</sub> Doses and ICRU Point Dose for Rectum and Bladder**

	Bladder	Rectum	p value
D <sub>0.1cc</sub> & ICRU	4.76 Gy (95% CI 4.42, 5.10)	2.69 Gy (95% CI 2.34, 3.03)	0.001
D <sub>1cc</sub> & ICRU	3.76 Gy (95% CI 3.46, 4.07)	1.58 Gy (95% CI 1.29, 1.86)	0.001
D <sub>2cc</sub> & ICRU	3.06 Gy (95% CI 2.27, 3.34)	1.11 Gy (95% CI 0.84, 1.38)	0.001

Gy (95% CI 2.27, 3.34, p 0.001) respectively. Similarly difference of doses received by 0.1cc, 1cc, 2 cc volume of rectum and ICRU rectal reference point was 2.69 Gy (95% CI 2.34, 3.03, p 0.001), 1.58 Gy (95% CI 1.29, 1.86, p 0.001) and 1.11 Gy (95% CI 0.84, 1.38, p 0.001) respectively (Table 4).

The ratio of dose received by bladder D<sub>0.1cc</sub>, D<sub>1cc</sub> and D<sub>2cc</sub> to Bicu was 2.88±0.72, 2.5±0.65 and 2.2±0.57 respectively. Similarly ratio of dose received by rectum D<sub>0.1cc</sub>, D<sub>1cc</sub> and D<sub>2cc</sub> to Ricu was 1.80±0.5, 1.48±0.41 and 1.35±0.37 respectively (Table 5).

## Discussion

The present study was carried out to evaluate doses to target, bladder and rectum based on 3D CT based treatment planning and to compare this with conventional 2D radiography based point dose to target, bladder and rectal reference point.

We report that 100%, 95% and 90% of the target volume is receiving only 4.24±0.63, 4.6±0.56 and 4.9±0.56 Gy respectively, when we are prescribing 7 Gy to point A in 2D plan.

Similar results were reported by Gao M et al. They reported mean target coverage of 5.4±0.9 Gy and 79.9±13.2% in terms of D90 and V100 (Volume receiving 100% of the prescribed dose) respectively (Gao et al., 2010).

Other studies have also reported suboptimal coverage of target by 2D radiography based planning (Kim et al., 2003; Shin et al., 2006). Kim et al. (2003) observed that the mean volume of gross tumor volume (GTV) that received the prescribed dose was higher in early stage disease as compared to advanced stage, and demonstrated that target coverage varied from 98.5% in stage IB1 to 59.5% in stage IIIB cervical cancer (Kim and Pareekh, 2003). This explains poor geometry with increasing clinical stage and inadequate target coverage by the 2-D planning. Large tumor size itself impairs adequate GTV and CTV treatment due to potential toxicity to bladder and rectum (Pelloski et al., 2005). However, Fellner et al observed that an average of 83% of CTV was covered with the prescribed dose of 7 Gy (Fellner et al., 2001). The difference in observation in our study could be attributed to the large number of stage IIIB patients in our study group. Tyagi et al. (2012) have compared ICRU point based planning with volumetric planning in cervical cancer and concluded that bladder doses are underestimated by orthogonal film based method but rectal doses were found similar to D<sub>2cc</sub> doses (Tyagi et al., 2012). Several other studies have also confirmed such a finding (Kim et al., 2003; Pelloski et al., 2005). Our study has revealed that the dose received by 0.1cc, 1cc and 2 cc volume of bladder is 2.88±0.72, 2.5±0.65 and 2.2±0.57 times more than ICRU bladder reference point. Similarly, dose received by 0.1cc, 1cc and 2 cc of rectum is 1.80±0.5, 1.48±0.41 and 1.35±0.37 times higher than ICRU rectal reference point. Similar observations have been made by Georg p et al. It was reported that higher rectal toxicity was seen for those group of patients who received significantly high dose to all DVH parameters (0.1cc, 1cc and 2cc). But dose to 0.1cc was not a predictor of major toxicity. In contrast for bladder, all DVH parameters were predictors of only for major toxicity (George et al., 2011). These findings also strengthens earlier observations of maximum doses to both bladder and rectum higher than corresponding ICRU reference points and the significance of doses to OAR which can be estimated by three dimensional image based brachytherapy (Fellner et al., 2001; Kim et al., 2003). Combination of image based brachytherapy and intensity-modulated radiotherapy can also improve dose distribution in target volume and overdose to organs at risk (Tharavichitkul et al., 2013). Few studies have concluded that in centers where MRI based brachytherapy is not feasible due to logistics reasons, OAR and target may be contoured with CT which gives comparable results to MRI for dose volume estimation if clinical findings and baseline MRI findings are applied in contouring of CT images (Eskander et al., 2010; Krishnatry et al., 2012). A descriptive survey of European brachytherapy practices



observed MRI is being used by 20% for planning (Gueda et al., 2010).

The limitation of our study included small sample size and lack of MRI based brachytherapy planning as CT may have overestimated the clinical target volume as compared to MRI. So, the findings should be interpreted with caution. As the incidence and presentation in advanced stage remains a challenge despite screening by cervical cytology, policy makers in India should organize hospital based screening for all women attending hospital for early diagnosis, therapeutic intervention (Kulkarni et al., 2013). Health education towards awareness, risk factors and disease symptoms in women is also important for early detection (Shruti et al., 2014).

In conclusion, three dimensional image based brachytherapy allows precise identification and dose optimization of target volume and OAR. The study demonstrates suboptimal target coverage and underestimation of dose to OAR by two-dimensional radiography based treatment planning. As it would be difficult to perform MRI based brachytherapy for logistic reasons in our country CT based image planning for gynecologic brachytherapy is a reasonable substitute. A larger study is similar to determine the clinical outcome, tumor control and toxicity to organs at risk will be worthwhile for resource-appropriate practice.

## References

- Eifel PJ, Levenback C, Wharton JT, Oswald MJ (1995). Time course and incidence of late complications in patients treated with radiotherapy for FIGO stage IB carcinoma of uterine cervix. *Int J Radiat Biol Phys*, **32**, 1289-300.
- Eskander RN, Scanderbeg D, Saenz CC Brown M, Yashar C (2010). Comparison of computed tomography and magnetic resonance imaging in cervical cancer brachytherapy target and normal tissue contouring. *Int J Gynecol Cancer*, **20**, 47-5.
- Fellner C, Potter R, Knocke TH, Wambersie A (2001). Comparison of radiography and computed tomography based treatment planning in cervix cancer in brachytherapy with specific attention to some quality assurance aspects. *Radiother Oncol*, **58**, 53-62.
- Forman D, Bray F, Brewster DH, et al (2013). Cancer Incidence in Five Continents, Vol. X (electronic version) Lyon, IARC.
- Gao M, Albuquerque K, Chi A, Rusu I (2010). 3D CT-based volumetric dose assessment of 2D plans using GEC-ESTRO guidelines for cervical cancer brachytherapy. *Brachytherapy*, **9**, 55-60.
- Georg P, Lang S, Dimopoulos JC, et al (2011). Dose-volume histogram parameters and late side effects in magnetic resonance image-guided adaptive cervical cancer brachytherapy. *Int J Radiat Oncol Biol Phys*, **79**, 356-6.
- Guedea F, Venselaar J, Hoskin P, et al (2010). Patterns of care for brachytherapy in Europe: updated results. *Radiother Oncol*, **97**, 514-20.
- Kim RY, Pareek P (2003). Radiography-based treatment planning compared with computed tomography (CT) based treatment planning for intracavitary brachytherapy in cancer of the cervix: analysis of dose-volume histograms. *Brachytherapy*, **2**, 200-6.
- Krishnatry R, Patel FD, Singh P, et al (2012). CT or MRI for image-based brachytherapy in cervical cancer. *Jpn J Clin Oncol*, **42**, 309-13.
- Kulkarni PR, Rani H, Vimalambike MG, Ravishankar S (2013). Opportunistic screening for cervical cancer in a tertiary hospital in Karnataka, India. *Asian Pac J Cancer Prev*, **14**, 5101-5.
- Logsdon MD, Eifel P (1999). FIGO IIB squamous cell carcinoma of the cervix: an analysis of prognostic factors emphasizing balance between external beam and intracavity radiation therapy. *Int J Radiat Oncol Biol Phys*, **43**, 763-75.
- Nag S, Erickson B, Thomadsen B, et al (2000). The American Brachytherapy Society recommendations for high-dose-rate brachytherapy for carcinoma of the cervix. *Int J Radiat Oncol Biol Phys*, **48**, 201-11.
- Nag S, Cardenes H, Chang S, et al (2004). Proposed guidelines for image-based intracavitary brachytherapy for cervical carcinoma: report from image-guided brachytherapy working group. *Int J Radiat Oncol Biol Phys*, **60**, 1160-72.
- Nakano T, Kato S, Ohno T, et al (2005). Long term results of high-dose-rate intracavitary brachytherapy for squamous cell carcinoma of uterine cervix. *Cancer*, **103**, 92-101.
- Pelloski CE, Palmer M, Chronowski GM, et al (2005). Comparison between CT-based volumetric calculations and ICRU reference-point estimates of radiation doses delivered to bladder and rectum during intracavitary radiotherapy for cervical cancer. *Int J Radiat Oncol Biol Phys*, **62**, 131-7.
- Petsuksiri J, Jaishuen A, Pattaranutaporn P, Chansilpa Y (2012). Advanced imaging applications for locally advanced cervical cancer. *Asian Pac J Cancer Prev*, **13**, 1713-8.
- Potter R, Haie-Meder C, Van Limbergen E, et al (2006). Recommendations from gynecological (GYN) GEC ESTRO working group (II); concepts and terms in 3D image based treatment planning in cervix cancer brachytherapy-3D dose volume parameters and aspects of 3D image based anatomy, radiation physics, radiobiology. *Radiother Oncol*, **78**, 67-77.
- Sadozye AH, Reed N (2012). A review of recent developments in image-guided radiation therapy in cervix cancer. *Curr Oncol Rep*, **14**, 519-26.
- Shin KH, Kim TH, Cho JK et al (2006). CT-guided intracavitary radiotherapy for cervical cancer: comparison of conventional point A plan with clinical target volume-based three dimensional plan using dose-volume parameters. *Int J Radiat Oncol Biol Phys*, **64**, 197-204.
- Shruti PS, Kalyani R, Kai LJ, Narayanaswami M (2014). Clinicopathological correlation of cervical carcinoma: a tertiary hospital based study. *Asian Pac J Cancer Prev*, **15**, 1671-4.
- Tharavichitkul E, Mayurasakorn S, Lorvidhaya V et al (2011). Preliminary results of conformal computed tomography (CT)-based intracavitary brachytherapy (ICBT) for locally advanced cervical cancer. A single institution's experience. *J Radiat Res*, **52**, 634-40.
- Tharavichitkul E, Wanwilairat S, Chakrabandhu S, et al (2013). Image-guided brachytherapy (IGBT) combined with whole pelvic intensity-modulated radiotherapy (WP-IMRT) for locally advanced cervical cancer: a prospective study from Chiang Mai University Hospital, Thailand. *J Contemp Brachytherapy*, **5**, 10-16.
- Tyagi K, Mukundan H, Mukherjee D, Semwal M, Sarin A (2012). Non isocentric film-based intracavitary brachytherapy planning in cervical cancer: a retrospective dosimetric analysis 6with CT planning. *J Contemp Brachytherapy*, **4**, 129-34.
- Vishwanathan AN, Dimopoulos J, Kirists C, Berger D, Pötter R (2007). Computed tomography versus magnetic resonance imaging based contouring in cervical cancer brachytherapy: result of a prospective trial and preliminary guidelines for standardized contours. *Int J Radiat Oncol Biol Phys*, **68**, 491-8.