

## RESEARCH ARTICLE

# Clinical Value of Real Time Elastography in Patients with Unexplained Cervical Lymphadenopathy: Quantitative Evaluation

Ying Fu<sup>1</sup>, Yun-Fei Shi<sup>2</sup>, Kun Yan<sup>1\*</sup>, Yan-Jie Wang<sup>1</sup>, Wei Yang<sup>1</sup>, Guo-Shuang Feng<sup>3</sup>

## Abstract

Ultrasonography is non-invasive and can give useful clues in the diagnosis of cervical lymphadenopathy. However, differential diagnosis is difficult in some situations even combined with color Doppler imaging. The present study was conducted to evaluate the clinical value of real time elastography in patients with unexplained cervical lymphadenopathy using a quantitative method. From May 2011 to February 2012, 39 enlarged lymph nodes from 39 patients with unexplained cervical lymphadenopathy were assessed. All the patients were examined by both B-mode ultrasound, color Doppler flow imaging and elastography. The method of analyzing elasto-graphic data was the calculation of the 10 parameters ("mean", "sd", "area%", "com", "kur", "ske", "con", "ent", "idm", "asm") offered by the software integrated into the Hitachi system. The findings were then correlated with the definitive tissue diagnosis obtained by lymph node dissection or biopsy. Final histology revealed 10 cases of metastatic lymph nodes, 11 cases of lymphoma, 12 cases of tuberculosis and 6 cases of nonspecific lymphadenitis. The significant distinguishing features for conventional ultrasound were the maximum short diameter ( $p=0.007$ ) and absent of echogenic hilum ( $p=0.0293$ ). The diagnostic accuracy was 43.6% (17/39 cases) and there were 17 patients with equivocal diagnosis. For elastography, "mean" ( $p=0.003$ ), "area%" ( $p=0.009$ ), "kurt" ( $p=0.0291$ ), "skew" ( $p=0.014$ ) and "cont" ( $p=0.012$ ) demonstrated significant differences between groups. With 9 of the 17 patients with previous equivocal diagnoses (52.9%) definite and correct diagnoses could be obtained. The diagnostic accuracy for conventional ultrasound combined elastography was 69.2% (27/39 cases). There were differences in the diagnostic sensitivity of the two methods ( $p=0.0224$ ). Ultrasound combined with elastography demonstrated higher rates of conclusive and accurate diagnoses in patients with unexplained cervical lymphadenopathy than conventional ultrasound. The quantitative program showed good correlation with the pathology of different lymph node diseases.

**Keywords:** Ultrasonography - elastography - cervical - differential diagnosis - lymphadenopathy

*Asian Pac J Cancer Prev*, 15 (13), 5487-5492

## Introduction

A person with enlarged lymph nodes (LNs) is a common situation faced by clinicians. In primary care of this situation, only 1% of patients with an unexplained lymphadenopathy have a malignancy. Common diseases included reactive hyperplasia/lymphoma, lymphadenitis/granuloma, metastasis, tuberculosis, etc (Habermann and Steensma, 2000). Correct diagnosis the nature of cervical lymph nodes is extremely important from the therapeutic viewpoint. One of the major treatment choices for metastatic cervical nodes is neck dissection, which may lead to complications, whereas the treatment for tuberculosis lymphadenitis is anti-tuberculosis medication, which is far less complicated than surgery (Krüger et al., 2011).

Ultrasonography (US) is noninvasive and can give useful clues in the diagnosis of cervical lymphadenopathy, however, the differential diagnosis is difficult in some situations even combined with color Doppler imaging (Khanna et al., 2011). Real time elastography (RTE) is a newly developing technique that can reflect the stiffness of organs and has very good results in differentiating tumors of the breast, thyroid, prostate, pancreas and lymph nodes (Dewall, 2013). For lymph nodes evaluation, most research focused on the differentiation of benign and malignant superficial lymph nodes, and malignant lymph nodes usually refer to metastasis (Ying et al., 2012). Few studies have reported lymphoma and tuberculosis (T.B.) of lymph nodes to the best of our knowledge.

Strain (compression) RTE is the commonest technique that allows real-time visualization of the image on the

<sup>1</sup>Department of Ultrasound, <sup>2</sup>Department of Pathology, Key laboratory of Carcinogenesis and Translational Research (Ministry of Education), Peking University Cancer Hospital & Institute, <sup>3</sup>National Center for Public Health Surveillance and Information Services, Chinese Center for Disease Control and Prevention, Beijing, China \*For correspondence: [yankun201314@163.com](mailto:yankun201314@163.com)

screen. The strain of each area is compared with the remaining tissue within the elastogram, so the elastogram is a relative image available for visual comparison. However, the major problem in strain RTE is the lack of quantitative measurements (Drakonaki et al., 2012). For now, the semi-quantitative measurement method includes patterns, scores or grades (Alam et al., 2008; Parajuly et al., 2012; Teng et al., 2012). This has led to considerable confusion in the interpretation of the findings, a lack of reproducibility, operator-dependent and difficulty in comparing the results from different studies.

In our study, we used a quantitative software integrated into the Hitachi system which can provide 10 parameters of selected area ("mean", "sd", "area%", "com", "kur", "ske", "con", "ent", "idm", "asm"). The software was usually used in the noninvasive assessment of liver stiffness in patients with chronic hepatitis C before (Sandulescu et al., 2013). For the software is convenient, objective, and quantitative, our aim is to explore the clinical value of quantitative RTE in differentiating cervical lymphadenopathy with various reasons.

## Materials and Methods

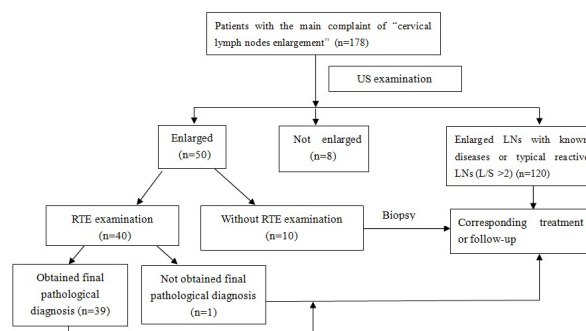
The prospective study protocol was approved by the Research Ethics Committee of our hospital, and informed consents were obtained from patients.

### Patients

From May 2011 to February 2012, consecutive patients with cervical lymphadenopathy underwent ultrasound examination. Subjectively, referred to Ying and Ahuja et al, LNs with a short-axis diameter  $\geq 8$ mm were defined as 'enlarged' (Ahuja and Ying, 2003). Patients met the following inclusion criteria were included in this study. The inclusion criteria were: (1) "cervical lymph nodes enlargement" was the main complain, without significant associated signs and symptoms; (2) underwent conventional ultrasound, color Doppler ultrasound and RTE; (3) received final diagnosis, which was based on histopathological findings after biopsy or surgical resection. For patients with benign LNs on biopsy, one-year follow up was performed to confirm the results. The exclusion criteria were: (1) patients who had a history of malignancy or related lymphadenopathies resulting from known diseases (e.g. cervical T.B. lymphadenitis or infectious mononucleosis) (2) incomplete ultrasound data; (3) without final diagnosis. In the case of multiple enlarged LNs in an individual patient, only the largest one on each side of neck would be enrolled in this study. Finally, the ultrasound data of 39 patients with 39 LNs were included in the study and were analyzed. The flow chart is shown in (Figure 1).

### Ultrasound techniques

US examinations were performed by the same radiologist with more than 5 years experience of small parts sonography. The equipments for conventional US included Logic 9 (General Electric Healthcare, WI, USA), iU22 (Philips Medical Systems, Bothell, WA, USA) and the Hitachi Preirus (Hitachi Medical Corporation,



**Figure 1. Flowchart of RTE Results for Patients with the Main Complaint of "Cervical Lymph Nodes Enlargement".** RTE=real time elastography, LNs=lymph nodes, L/S=the long axis to short axis ratio

Tokyo, Japan) with 5-17MHz broad-band linear array probes. Standard equipment settings dedicated for small parts were used, and Doppler gain was set at low wall filter and low velocity scale, the color gain was set at the highest sensitivity to show blood vessels in the absence of any noise. For each enrolled LN, US features including shape, hilum, echotexture, border, matting, cystic necrosis, calcification and vascular pattern were evaluated. A node with a ratio of long to short diameter (L/S)  $< 2$  was defined as round shape, and a ratio of  $L/S \geq 2$  as oval shape. The widely-accepted US criteria for identifying a malignant LN includes round shape ( $L/S < 2$ ), absence of hyperechoic hilum, peripheral or mixed vascular patterns (Vassallo et al., 1992; Ahuja and Ying, 2003). LNs who met one of the above criteria will do RTE for further diagnosis.

### RTE examination

All the RTE examinations were performed by the same radiologist with experience of more than 50 cases of small parts RTE. The machine used was the Hitachi Preirus (Hitachi Medical Corporation, Tokyo, Japan) with a quantitative software ('Str. Histo') integrated into the Hitachi system. RTE was performed at the index LN by using a freehand technique. Elastography imaging was obtained on transverse and longitudinal planes. Images were obtained by applying light repetitive compression at the skin above the index LN. A square sampling frame positioning the lesion at the center of the box was set for elastography acquisition. The sampling frame was usually two times of the lesion. The superior margin was set to include subcutaneous fat, and the inferior margin, to include the longus colli muscle. A visual indicator displayed on the screen alongside sonographic images ranging from 3-4 for a time is appropriate. After obtaining a cine loops of at least three compression, the radiologist chosen one static image for analysis. The static image was usually chosen at the compression phase and in the middle of each cycle (Drakonaki et al., 2012). Elastogram image is displayed at the left side and the corresponding conventional US image is on the right side. Red is used for encoding soft tissues, blue for hard tissues and yellow/green for tissue of intermediate stiffness for the used machine. Then the radiologist choose the strain histogram and draw a largest rectangle within the lesion site, the calculation of the 10 parameters of elastogram will be

offered by the integrated system ("mean", "sd", "area%", "com", "kur", "ske", "con", "ent", "idm", "asm"). To minimize observer variation and avoid transient temporal fluctuations, at least 3 optimal static image and 3 groups of characteristic parameters will be used for quantitative analysis.

### Statistics

The final reference was based on the histopathologic and corresponding follow-up result. All quantitative data are expressed as mean±S.D. and range unless otherwise indicated. Comparison of continuous variables was performed using analysis of variance or Kruskal-Wallis Test based on the distribution of data. Comparison of categorical variables was performed using the chi-square test (or Fisher's exact test where appropriate). The level of significance was set at 0.05 for all tests. All data were analyzed with SAS software (version 9.2; SAS Institute, Cary, NC).

## Results

### General features

There were 39 patients included in our group (19 men, 20 women; mean age, 54.5±16.8 years, range 19-82 years). There was no difference between groups as for the patients' age between different groups ( $p=0.386$ ). The mean diameter of lymph node was 2.5±1.0 (1.4-5.6) cm. At the time of writing, all patients were followed up for 27.0±2.3 months (22-31 months). Referred to the histopathologic and follow-up results, 10 patients were with metastasis (group A), 11 patients were with lymphoma (group B), 12 were with T.B. (group C), 6 were with nonspecific lymphadenitis (group D). For group A, 7 cases were metastatic adenocarcinoma, 2 were metastatic

squamous cell carcinoma and the remaining one was metastatic small cell carcinoma. For group B, 2 were Hodgkin's lymphoma, 9 were non-Hodgkin's lymphoma. For group D, there were 2 cases of granulomatous inflammation (negative for acid-fast staining) and 3 cases of reactive lymphadenitis and the remaining one case of reactive follicular hyperplasia accompanied with eosinophil infiltration.

### Conventional ultrasound features

Maximum short diameter ( $p=0.007$ ) and absent of echogenic hilum ( $p=0.0293$ ) between groups were statistically significant. Malignant lymph nodes tended to be shorter in the maximum short diameter and more likely to be absent of echogenic hilum compared with benign LNs. The mean diameter for LNs in group A and B were 1.78±0.44cm, 1.88±0.72 cm, respectively; while the diameter for group C and group D were 1.34±0.46 cm, 1.02±0.28 cm. Ninety percent of LNs in group A were absent of echogenic hilum (9/10 cases), while only 16.7% LNs in group D (1/6 cases) were absent of echogenic hilum.

There was no significant difference between groups as for the number of lymph nodes per patient, L/S, echogenicities, fusion or not, and presence of necrosis (Table 1).

Although resistance index (RI) values of malignant groups were higher than that of benign groups, there was no significant difference between groups ( $p=0.08$ ) (Table 1). The diagnostic accuracy of conventional US was 43.6% (17/39 cases). Five patients were with incorrect diagnoses and 17 patients were with equivocal diagnoses.

### RTE results

There was significant difference between groups as for

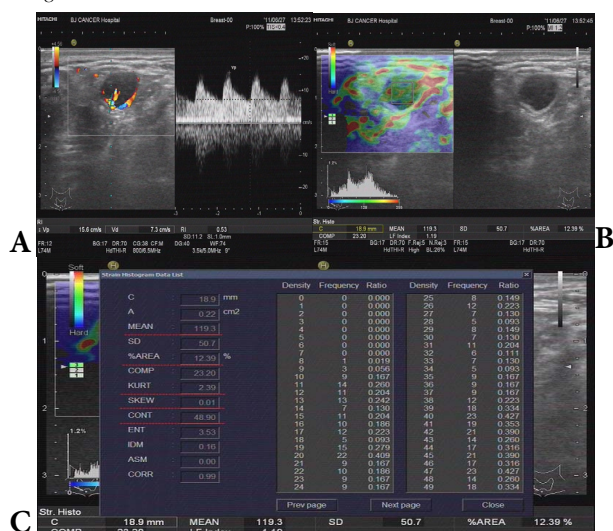
**Table 1. Ultrasonographic Findings Correlated with Pathologic Diagnosis in 39 Cervical Lymph Nodes**

Characteristics	Group A (n=10)	Group B (n=11)	Group C (n=12)	Group D (n=6)	P value
Single/multiple	1/9	1/10	0/12	2/4	0.1616
Echogenicities (Hypoechoic / Heterogeneous)	8/2	9/2	7/5	6/0	0.2628
Maximum short diameter	1.78 ±0.44	1.88 ±0.72	1.34 ±0.46	1.02 ±0.28	0.007
L/S	1.57 ±0.46	1.81 ±0.43	1.68 ±0.48	2.25 ±0.99	0.2677
Absent hilum (Y/N)	9/1	7/4	9/3	1/5	0.0293
Necrosis (Y/N)	1/9	2/9	2/10	0/6	0.8556
Fusion tendency (Y/N)	4/6	6/5	5/7	0/6	0.173
Resistance index(X±S)	0.78 ±0.09	0.74 ±0.14	0.67 ±0.11	0.65 ±0.12	0.08

**Table 2. The 10 Parameters of Real Time Elastography (RTE) Findings Correlated with Pathologic Diagnosis in 39 Cervical Lymph Nodes**

Parameters	Group A (n=10)	Group B (n=11)	Group C (n=12)	Group D (n=6)	Value	P value
MEAN	51.14±24.67	59.82±21.35	44.72±19.41	93.70±36.63	5.46	0.003
SD	41.08±16.69	47.85±13.61	42.83±15.41	59.83±15.22	2.21	0.104
AREA%	73.90±15.50	62.03±15.92	69.95±18.29	42.34±23.17	4.49	0.009
COMP	28.55±6.42	33.55±8.58	29.30±6.05	26.79±3.85	1.67	0.191
KURT	7.34±4.73	4.07±1.57	5.22±2.10	3.71±3.62	9.0181	0.0291
SKEW	1.61±0.60	1.07±0.28	1.31±0.47	0.66±0.92	4.09	0.014
CONT	31.33±16.50	37.93±23.00	24.42±14.64	58.75±26.93	4.21	0.012
ENT	2.81±0.48	3.07±0.32	2.86±0.36	3.17±0.46	1.54	0.223
IDM	0.43±0.12	0.37±0.09	0.41±0.09	0.31±0.13	1.87	0.153
ASM	0.04±0.04	0.02±0.02	0.04±0.04	0.03±0.04	1.9472	0.5834



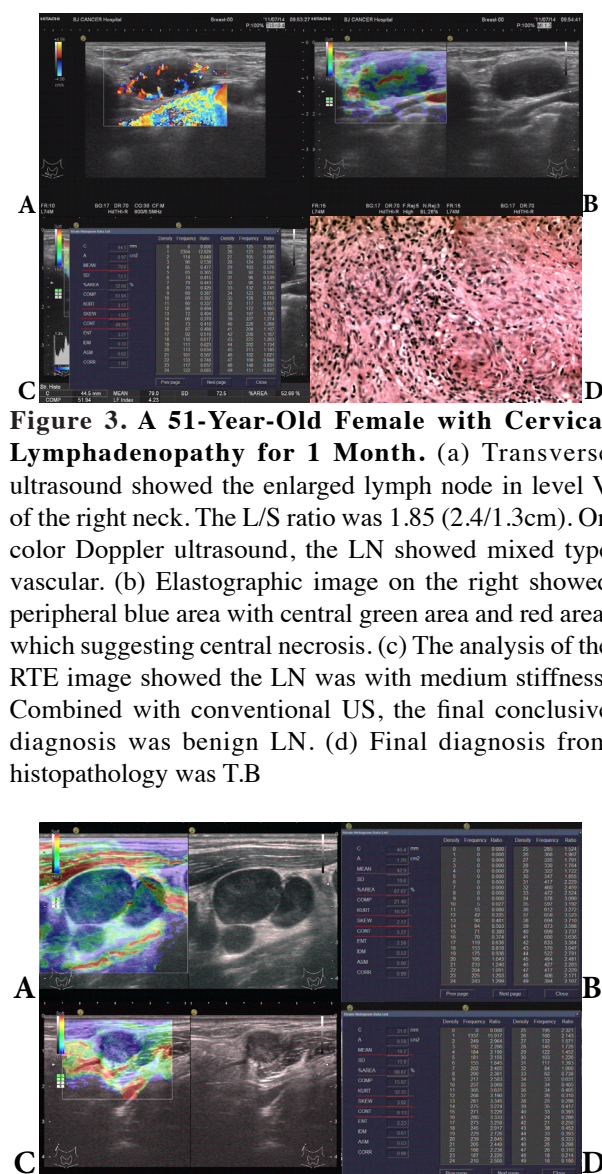


**Figure 2. A man of 55 Years Old, with Cervical Lymphadenopathy for Three Months.** (a) Transverse ultrasound showed multiple enlarged lymph nodes in level V and VI of the right neck. Features of  $L/S < 2$  (1.9/1.4cm), homogenously hypoechogenicity, well defined margin, absence of hilum were showed. On color Doppler US, multiple feeding vessels within the largest lymph node were found with resistance index (RI)=0.55. It was with equivocal diagnosis on conventional US. (b). Elastographic image on the right shows the LN was with predominantly green area with peripheral small blue area and scatted red area. (c). The analysis of data in RTE. The calculation of the parametres offered by the quantitative software were showed (the values of mean, area%, kurt, skew and cont were underlined in red). The “area%” value was 12.39% (less than 50%), which represented that the indexed LN was soft. The “mean” value was 119.3, which represented large tissue deformation. It was indirect evidence of the soft nature of the index LN. “Kurt” and “skew” represents the microstructure uniformity of the LN. From the result of our research, the index LN was with uniform texture. Combined RTE results and conventional US, the final conclusive diagnosis was benign LN. Final diagnosis from histopathology was nonspecific lymphadenitis

“mean” ( $p=0.003$ ), “area%” ( $p=0.009$ ), “kurt” ( $p=0.0291$ ), “skew” ( $p=0.014$ ) and “cont” ( $p=0.012$ ), the remaining five parameters were with no significant difference (Table 2). Nine of the 17 patients (52.9%) with equivocal diagnoses obtained definite and correct diagnosis. One patient with incorrect diagnosis on conventional ultrasound got correct diagnosis after RTE examination. The diagnostic accuracy of US combined RTE was 69.2% (27/39 cases). There were differences in the diagnostic sensitivity of the two methods ( $\chi^2=5.2139$ ,  $p=0.0224$ ). Typical examples are illustrated in (Figures 2-4).

## Discussion

Grey-scale and color Doppler images remain fundamental for effective nodal evaluation of the neck (Ahuja and Ying, 2002). Also, ultrasound is used for biopsy selection in the case of unexplained lymphadenopathy (Screaton et al., 2002).



**Figure 3. A 51-Year-Old Female with Cervical Lymphadenopathy for 1 Month.** (a) Transverse ultrasound showed the enlarged lymph node in level V of the right neck. The L/S ratio was 1.85 (2.4/1.3cm). On color Doppler ultrasound, the LN showed mixed type vascular. (b) Elastographic image on the right showed peripheral blue area with central green area and red area, which suggesting central necrosis. (c) The analysis of the RTE image showed the LN was with medium stiffness. Combined with conventional US, the final conclusive diagnosis was benign LN. (d) Final diagnosis from histopathology was T.B

**Figure 4. Two Typical Malignant Cases.** (a) A 51-year-old female with cervical lymphadenopathy for 1 month pathologically proved to be non-Hodgkin lymphoma. US scan showed multiple round, enlarged lymph nodes, with sharp margin, absent of hilum, and mixed vascularization. (b) The analysis of RTE image showed the LN was with moderately stiff. (c) Transverse US of lymph node in 78-year-old man with right submandibular lymphadenopathy. The size of the LN was 1.4x1.1 cm. Features of a round shape, uneven hypoechogenicity, well defined margin, absence of hilum, and no-matting were showed on the right side of the screen. (d) On elastography, the LN was entirely blue with the value of “area%” =98.87%. Final diagnosis from histopathology was low grade differentiated adenocarcinoma

Although no absolutely reliable criteria specific for malignant lymph node have been defined, there exist widely-accepted US features which suggest the presence of a malignant LN. The widely-accepted US criteria for identifying a malignant LN includes round shape ( $L/S < 2$ ), absence of hyperechoic hilum, peripheral or mixed vascular patterns (Vassallo et al., 1992; Ahuja and Ying,

2003). However, in our group, using the widely accepted criteria, all of the LNs were not typical benign. This failure of sonography calls for better-designed sonographic criteria.

The new RTE technique is helpful in differentiating reactive from metastasis LNs but it did not show ability to distinguish other situations such as lymphoma and T.B. (Ying, 2012). Theoretically and clinically, the degree of stiffness of these disorders was different, although rock-hard adenopathy is associated with metastatic cancer, Hodgkin disease, or T.B. (Habermann and Steensma, 2000). Clinical palpation was first used to reflect the node's stiffness, in general, metastatic lymph nodes are hard and lymph nodes of T.B. are of tough texture. However, numerous studies have showed palpation is an inaccurate technique for assessment of lesions in the neck and the result of clinical palpation was affected by various factors, such as the clinician's experience, the location of the lymph node, the scar of skin and the size of lymph node.

Biopsy is widely used in the assessment of patients with lymphadenopathy. Although this procedure is reliable and relatively safe, considerable post-operative complications and the possibility of sampling error may occur (Shaha, 2008).

Alam et al., (2008) first evaluated the diagnostic performance of sonographic elastography and B-mode sonography individually and combined in the differentiation of reactively and metastatically enlarged cervical lymph nodes. Their results indicated that the specificity, and accuracy of elastography were higher than that of B mode sonography (100% and 89% vs 59% and 84%) and the combined evaluation showed the highest specificity and accuracy. They also raised an elastographic pattern and scoring system which was determined on the distribution and percentage of blue area. The threshold for reactive versus metastatic was set at 45% (percentage of blue area), however, visual assessment alone is subjective and unlikely to be comparable from study to study (or physician to physician).

To remedy this deficit, Ishibashi et al., (2012) raised a modification of the previously reported scoring system by Alam et al., (2011). Score 1, no blue area; Score 2, small blue area; Score 3, half of LN colored blue; Score 4, more than half of the LN colored blue; and Score 5, a peripheral blue area and a central red, yellow or green area (indicating obvious central necrosis). The percentage of the blue area was measured automatically with RGB histogram by Image J image analysis software. There was 61.6% blue area in the target LN for the metastatic group and 36.7% for the non metastatic group by the software. Although this method is more accurate than visual assessment, the off-line operation is time consuming and troublesome and long waiting-time. Moreover, Teng et al., (2012) found that there were some differences about color. Light blue and dark blue showed different stiffness of LNs but the scores could be same. This would introduce false positive results.

In our study, the quantitative software we used was integrated into the Hitachi system, which made online measurement possible and without the influence of colour gradation. The software was first used in evaluating liver fibrosis and there was a good correlation with the

histologic stage (Sandulescu et al., 2013). For now, the "mean" value of the histogram was also used to differentiate liver metastases, hepatocellular carcinoma and benign liver tumors and successful results were achieved. Theoretically, the "mean" value represents the average value of strain on the region of interest classified in 256 scales from the average of strain. The bigger the mean value is, the softer the tissue gets. In our results, we found statistically significant differences between the "mean" values of the histogram analysis ( $p=0.003$ ). The values for metastasis (group A), lymphoma (group B), T.B. (group C), and group D were:  $44.72\pm19.41$ ,  $59.82\pm21.35$ ,  $51.14\pm24.67$ ,  $93.7\pm36.63$ , respectively. This is consistent with the experienced surgeon: metastases are stiff; T.B. and lymphoma are less rough and benign disease has a soft consistency.

The "area%" value was similar to scoring system. It means the area of blue parts. The mean area values of the histogram analysis for group A-D were:  $73.90\pm15.0$ ,  $62.03\pm15.92$ ,  $69.95\pm18.29$ ,  $42.34\pm23.17$ , respectively. Benign LNs had a lower hardness compared with malignant lesions (Ying et al., 2012). However, the value of metastasis was similar to that of group B and C. Our results were similar to previous published study. Bhatia et al., demonstrated that not only does lymphoma often produce false-negative findings but reactive or granulomatous lymphadenitis may also produce false positives (Bhatia et al., 2010). We hypothesize the reason for the similarity for metastasis and T.B. of granulomatous inflammation group may be (1) necrosis in metastasis decreased the mean value of group A; or (2) Most LNs of T.B. usually accompany with fibrosis from our result of pathology, which increased the mean value of group C? (3) Great variety of primary tumour sites, the metastatic state of LNs and the different amount of interstitial fibrosis may result in different stiffness in metastatic LNs.

"Kurt" is abbreviation for kurtosis. It means quartic center moment. This value gets bigger when a part of value is far from others. If all values near the average, this value gets smaller. In our results, metastasis LNs gets the most highest value of "kurt" ( $3.27-18.29$ ). It may reflect different state of metastasis. As is known to all, in the early time of micrometastatic foci, there is little necrosis. As the metastatic foci becomes larger, the displaced fatty hilus becomes localized and there will be more and more area of necrosis in the related LNs. The second highest value group was T.B.. The characteristics of T.B. on ultrasonography are variable according to clinical stage. The appearance of T.B. on ultrasonography was classified into four types: acute inflammation type, cheesy necrosis type, cold abscess type and concrement calcification type according to some authors (Zhao et al., 2008). The differential diagnosis between T.B. and malignant disease of LN is always the diagnostic dilemma of US and RTE. In a recent study (Teng et al., 2012), only 5 of 16 LNs of T.B. were diagnosed correctly by RTE, whereas the whole diagnosis accuracy of RTE was 66.3% in 89 lymph nodes which were suspected to be malignant.

The content of "skew" means tertiary center moment. It is used as a scale of asymmetry. We hypothesize clinical value of "skew" is similar to that of "kurt". They all

reflect the heterogeneity of lymph nodes. The mean values of “skew” for group A-D were:  $1.61 \pm 0.60$ ,  $1.07 \pm 0.28$ ,  $1.31 \pm 0.47$ ,  $0.66 \pm 0.92$ , respectively.

It is worth mentioning that 9 of the 17 patients (52.9%) with equivocal diagnoses obtained definite and correct diagnosis after RTE examination. RTE combined with conventional US could divide the lymph nodes into benign and malignant with accuracy of 69.2%, whereas the rate of US only was 43.6%. At least, RTE examination can provide a direction of diagnosis and may reduce unnecessary biopsy.

Several limitations in the present study should be addressed. (1) To ensure the elasticity image stabilization and to reduce the resulting error caused by the difference between the operators, all examinations were completed with the same physician. Thereby limited the result interpretation to personal practice. The same as RTE operation of breast, RTE requires training and practice (Parajuly et al., 2012). Perpendicular compression to the region of interest and slightly moving the probe upward and downward are the two key points to obtain a stable and reliable image (Tan et al., 2010). When the operators are well trained, the interobserver agreement for RTE may improve the objectivity and the diagnostic consistency; (2) There are some parameters with unknown clinical significance, such as “cont”. “Cont” means big concentration difference. This value gets bigger when matrix value is distributed far from main diagonal. Further study is warranted.

In conclusion, RTE can provide additional stiffness information to US operators and decrease equivocal diagnoses in the patients with cervical lymphadenopathy for unknown reason. Using the integrated software program, there was a good correlation between the histogram analysis and different lymph node disease. Significant difference between groups were mean, area%, kurt, skew and cont, although they also showed considerable overlap in the 4 groups. Further study is warranted to explore the relationship between various parameters and disease for cervical lymphadenopathy. It may open new perspectives in the noninvasive assessment of cervical lymphadenopathy.

## Acknowledgements

All authors contributed substantially to this manuscript and they have read and approved submission of the manuscript. This study was supported by grant of the Capital Medical Development Program (No. “2011-2015-01”) and Beijing Municipal Health System Special funds of High-Level Medical Personnel Construction (Commission No. 2013-3-086).

## References

Ahuja A, Ying M (2002). An overview of neck node sonography. *Invest Radiol*, **37**, 333-42.  
 Ahuja A, Ying M (2003). Sonography of neck lymph nodes. Part II: abnormal lymph nodes. *Clin Radiol*, **58**, 359-66.  
 Alam F, Naito K, Horiguchi J, et al (2008). Accuracy of sonographic elastography in the differential diagnosis

of enlarged cervical lymph nodes: comparison with conventional B-mode sonography. *Am J Roentgenol*, **191**, 604-10.  
 Bhatia KS, Cho CC, Yuen YH, et al (2010). Real-time qualitative ultrasound elastography of cervical lymph nodes in routine clinical practice: interobserver agreement and correlation with malignancy. *Ultrasound Med Biol*, **36**, 1990-7.  
 Dewart RJ (2013). Ultrasound elastography: principles, techniques, and clinical applications. *Crit Rev Biomed Eng*, **41**, 1-19.  
 Drakonaki EE, Allen GM, Wilson DJ (2012). Ultrasound elastography for musculoskeletal applications. *Br J Radiol*, **85**, 1435-45.  
 Habermann TM, Steensma DP (2000). Lymphadenopathy. *Mayo Clin Proc*, **75**, 723-32.  
 Ishibashi N, Yamagata K, Sasaki H, et al (2012). Real-time tissue elastography for the diagnosis of lymph node metastasis in oral squamous cell carcinoma. *Ultrasound Med Biol*, **38**, 389-95.  
 Krüger U, Kretschmer L, Thoms KM, et al (2011). Lymph node ultrasound during melanoma follow-up significantly improves metastasis detection compared with clinical examination alone: a study on 433 patients. *Melanoma Res*, **21**, 457-63.  
 Khanna R, Sharma AD, Khanna S, Kumar M, Shukla RC (2011). Usefulness of ultrasonography for the evaluation of cervical lymphadenopathy. *World J Surg Oncol*, **28**, 29.  
 Parajuly SS, Lan PY, Yun MB, Gang YZ, Hua Z (2012). Diagnostic potential of strain ratio measurement and a 5 point scoring method for detection of breast cancer: Chinese experience. *Asian Pac J Cancer Prev*, **13**, 1447-52.  
 Sandulescu L, Rogoveanu I, Ghenoea IA, Cazacu S, Saftoiu A (2013). Real-time elastography applications in liver pathology between expectations and results. *J Gastrointest Liver Dis*, **22**, 221-7.  
 Screaton NJ, Berman LH, Grant JW (2002). Head and neck lymphadenopathy: evaluation with US-guided cutting-needle biopsy. *Radiology*, **224**, 75-81.  
 Shaha AR (2008). Complications of neck dissection for thyroid cancer. *Ann Surg Oncol*, **15**, 397-9.  
 Tan R, Xiao Y, He Q (2010). Ultrasound elastography: Its potential role in assessment of cervical lymphadenopathy. *Acad Radiol*, **17**, 849-55.  
 Teng DK, Wang H, Lin YQ, et al (2012). Value of ultrasound elastography in assessment of enlarged cervical lymph nodes. *Asian Pac J Cancer Prev*, **13**, 2081-5.  
 Vassallo P, Wernecke K, Roos N, Peters PE (1992). Differentiation of benign from malignant superficial lymphadenopathy: the role of high-resolution US. *Radiology*, **183**, 215-20.  
 Zhao YW, Jin ZJ, Zheng Y, et al (2008). Characteristics and classification of cervical tuberculous lymphadenitis on ultrasonography. *Shanghai Medical Imaging*, **17**, 218-9. (in Chinese)  
 Ying L, Hou Y, Zheng HM, et al (2012). Real-time elastography for the differentiation of benign and malignant superficial lymph nodes: a meta-analysis. *Eur J Radiol*, **8**, 2576-84.