

## RESEARCH ARTICLE

# HER2 Expression in Ovarian Mucinous Carcinomas in Tunisia

Nabiha Missaoui<sup>1\*</sup>, Soumaya Ben Abdelkarim<sup>2</sup>, Malak Ayachi<sup>1</sup>, Sihem Hmissa<sup>1,2</sup>

### Abstract

**Background:** Ovarian mucinous carcinoma has a poor prognosis in advanced stages and a poor response to conventional chemotherapy. An efficient treatment is not yet available. We here investigated HER2 expression and the potential for trastuzumab therapy in ovarian mucinous tumors. **Materials and Methods:** Immunohistochemistry was performed in formalin-fixed, paraffin-embedded tissue from 27 ovarian mucinous tumors including 14 carcinomas and 13 borderline tumors diagnosed in the Pathology Department, Farhet Hached Hospital, Sousse, between 1993 and 2013. The HercepTest (DAKO) was used for immunohistochemistry. **Results:** HER2 expression was observed in only one borderline tumor (7.7%) and in 14.3% of mucinous carcinomas of the ovary. **Conclusions:** Our results suggest that trastuzumab therapy would be an option for patients with mucinous carcinoma when the tumor has HER2 overexpression.

**Keywords:** Ovary - mucinous carcinoma - HER2 expression - immunohistochemistry - trastuzumab therapy

*Asian Pac J Cancer Prev*, 15 (19), 8121-8125

### Introduction

The ovary cancer is the sixth most common cancer among Tunisian women (Missaoui et al., 2010). Mucinous carcinoma accounts for 2% to 5% of all epithelial ovarian cancers. This cancer continues to be diagnostically challenging, and many mucinous tumors involving the ovaries are metastases from other sites. It has a poor prognosis in the advanced stages and responds poorly to conventional chemotherapy (paclitaxel/carboplatin) (Kurman and Seidman, 2000; Hess et al., 2004; Gurung et al., 2013). An efficient treatment is not yet available (Pectasides et al., 2005).

The Human epidermal growth factor receptor 2 (HER2, c-erb-B2) gene, located on chromosome 17q11, encodes the HER2 protein, which is a 185-kDa transmembrane receptor tyrosine kinase with no identified physiological ligand. The HER2 gene is involved in intracellular signaling transduction pathways leading to cell growth and differentiation (Di Fiore et al., 1987; Kauraniemi et al., 2006; Unal et al., 2013). Studies have suggested that abnormal expression of HER2 gene by mutation or amplification may play an important role in tumor genesis (Auersperg et al., 2001; Garcia-Velasco et al., 2008; Cuadros and Villegras, 2009; Moatter et al., 2011; Duman et al., 2012; Pazhoomand et al., 2013; Unal et al., 2013).

HER2 has been reported to be overexpressed or amplified in a variety of human tumors (Nicholson et al., 2001; Rubin and Yarden, 2001; McAlpine et al., 2009; Ghaffari et al., 2011; Wang et al., 2011; Sardari et al., 2012; Duman et al., 2012; Panagiotou et al., 2012;

Pazhoomand et al., 2013; Unal et al., 2013; Ziaian et al., 2014). The clinical significance of HER2 status in many tumor types is not yet clear except for breast, gastric, or gastroesophageal junction cancer patients (Nicholson et al., 2001; Gravalos and Jimeno, 2008; Garcia-Velasco et al., 2008; Moatter et al., 2011; Wang et al., 2011; Duman et al., 2012; Pazhoomand et al., 2013; Tai et al., 2013; Unal et al., 2013). Amplification and overexpression of HER2 have been identified in breast cancer (Slamon et al., 1987; Slamon et al., 1989; Wolff et al., 2007; Ghaffari et al., 2011; Moatter et al., 2011; Pazhoomand et al., 2013; Tai et al., 2013; Unal et al., 2013) and are associated with a poor prognosis (Wilson et al., 2002; Erdogan et al., 2003; Nathanson et al., 2003).

Adjuvant therapy using a monoclonal antibody against HER2 protein (Trastuzumab) is effective alone and in combination with conventional cytotoxic chemotherapy in patients whose breast carcinomas have amplification of HER2 (Goldenberg, 1999; Shak et al., 1999; Piccart-Gebhart et al., 2005; Romond et al., 2005; Duman et al., 2012; Tai et al., 2013; Unal et al., 2013). However, the significance of HER2 overexpression and amplification in the initiation and progression of ovarian mucinous carcinoma is less well understood (Weroha et al., 2011), and the treatment with HER2 antagonists has been disappointing (Bookman et al., 2003; Frederick et al., 2009).

In the current study, we investigated the HER2 protein expression by immunohistochemistry in formalin-fixed, paraffin embedded tissues from 27 Tunisian women with mucinous tumors of the ovary.

<sup>1</sup>Research Unit UR14ES17, Cancer Epidemiology and Cytopathology in Tunisian Center, Faculty of Medicine, <sup>2</sup>Pathology Department, Farhet Hached Hospital, Sousse, Tunisia \*For correspondence: missaouinabiha@live.fr

## Materials and Methods

### Tissue samples

Twenty-eight specimens were retrieved from the surgical pathology files of Pathology Department, Farhet Hached University Hospital of Sousse, Tunisia. The cases studied were distributed into the following groups, according to the World Health Organization (WHO) Classification of Tumors of the Breast and Female Genital Organs, 2003 (Tavassoli and Devilee, 2003): ovarian mucinous carcinoma (n=14) and ovarian mucinous borderline tumor (n=13). In this study, a positive staining breast ductal carcinoma was used as positive control case.

Medical records were reviewed for data on age, marital status, tumor size, histopathology, and tumor stage and grade.

All tissues had been routinely fixed in 4% buffered formalin and paraffin embedded. The cases were selected randomly, and the slides were reviewed by two pathologists. The study was approved by the Human Ethics Committee at the Farhet Hached University Hospital of Sousse (Tunisia) and it conformed to the provisions of the Declaration of Helsinki.

One or two paraffin blocks containing representative portions of the tumors were selected for each case, and 4-µm-thick sections were obtained.

### Immunohistochemistry

Immunohistochemistry staining of HER2 protein was performed using HerceptTest kit (Dako, code K5204). Formalin-fixed, paraffin-embedded tissues were deparaffinized in xylene, rehydrated through serial dilutions of alcohol and washed in phosphate-buffered saline (pH 7.2). After pretreatment with Dako antigen retrieval solution in 10 mM citrate buffer (pH 6.0) at 95°C for 40 minutes in a streamer, endogenous peroxidase activity was blocked in 3% hydrogen peroxide. Slides were then incubated with the rabbit anti-human HER2 protein antibody at room temperature (20-25°C) for 30 min. Diaminobenzidine was used as the chromogen for the immunostaining. Finally, sections were counterstained with hematoxylin and mounted. Negative controls were obtained by excluding the primary antibody. The images were captured by the Olympus microscopic digital camera system for study comparison.

### Immunohistochemistry interpretation

In 2007, the American Society of Clinical Oncology and the College of American Pathologists (ASCO-CAP) established guidelines for the HER2 scoring algorithm for breast cancers. Although there is neither consensus nor valid data that correlate to clinical outcomes for ovarian cancers, we applied these current guideline recommendations to interpret the results of HER2 immunohistochemistry in this study (Wolff et al., 2007; Lin et al., 2011). The immunohistochemistry results was evaluated by two pathologists (Dr. Hmissa and Dr. Yacoubi).

Only membrane staining was evaluated for HER2 immunostaining in this study. We adopted the 2007 ASCO-CAP guideline recommendations for

immunohistochemistry result categories instead of the Dako Hercep-Test recommendations (Dako, Carpinteria, California). Therefore, “positive” is defined as strong, complete, homogenous membrane staining in >30% of tumor cells; “equivocal” is defined as either strong, complete, homogeneous membrane staining in <30% or weak, moderate heterogeneous complete membrane staining in >10% of tumor cells, and “negative” is defined as no staining (score 0 points), or weak, incomplete membrane staining (score 1+ points) in any percentage of cells.

## Results

### Clinicopathological features

Overall, the mean age at diagnosis was 52 years (ranging from 20 to 80 years). The mean age was 49.3 years among patients with ovarian mucinous carcinoma (20-72 years) and 55.5 years among women with ovarian mucinous borderline tumor (27-80 years).

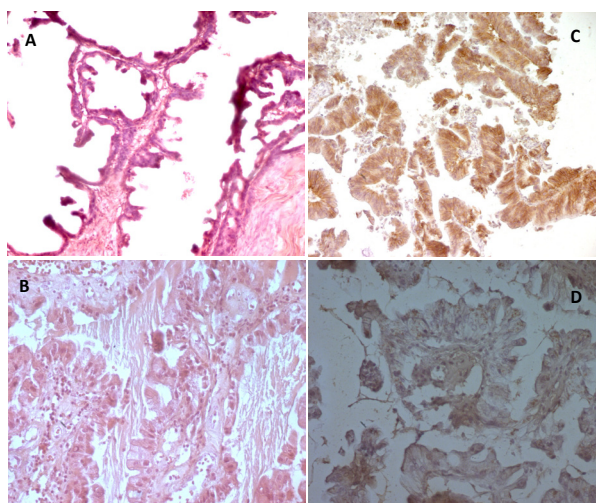
At the time of their ovarian tumor diagnosis, 88.9% of patients with mucinous carcinomas and 85.7% of patients with mucinous borderline tumors were married. All patients had no records regarding personal or family history of cancers.

The tumor size of ovarian mucinous carcinoma varied from 1.5 cm to 30 cm with a mean of 17.5 cm. For the mucinous borderline tumors, the tumor size varied from 10 to 28 cm with a mean tumor size of 17 cm.

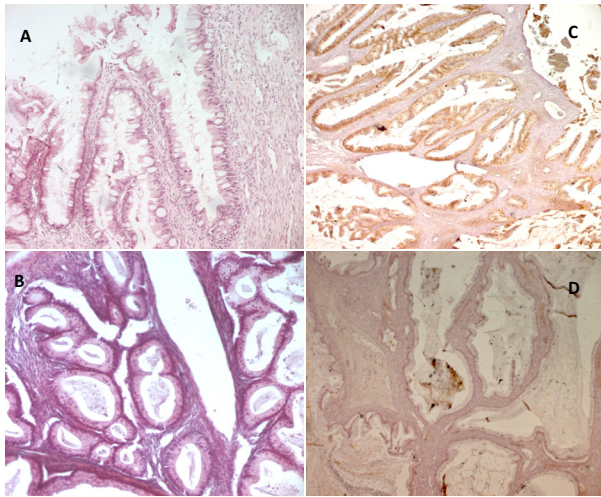
According to the International Federation of Gynecology and Obstetrics (FIGO, 1989) staging system, stage I was the most frequent (66.7%) followed by stages II and III with 11.1% and 22.2% respectively. All mucinous borderline tumors were localized.

### Immunohistochemistry

All 27 samples were analyzed for immunohistochemistry. Of the 14 mucinous carcinomas, HER2 3+ staining was observed in 2 samples (14.3%). HER2 expression of 0 was detected in the 12 remaining samples (85.7%) (Figure 1).



**Figure 1. Mucinous Epithelial Ovarian Carcinoma.** A-B, Hematoxylin and eosin staining, C, HER2 immunohistochemistry staining exhibits positive results (score 3), D, Negative expression of HER2 protein (score 0)



**Figure 2. Mucinous Borderline Ovarian Tumor.** A-B, Hematoxylin and eosin staining, C, HER2 immunohistochemistry staining exhibits positive results (score 3), D, Negative expression of HER2 protein (score 0)

HER2 overexpression was observed in only one mucinous borderline tumor (7.7%). The remaining samples were negatives (Figure 2).

## Discussion

HER2 gene amplification and expression have been extensively studied as the target for the cancer therapy. Normal ovarian surface epithelial cells express little or no HER2 (Wu et al., 2004). HER2 gene amplification and protein overexpression were reported in 18.3% to 35.3% mucinous carcinoma (Nicholson et al., 2001; Rubin and Yarden, 2001; McAlpine et al., 2009; Chay et al., 2013). In our study, HER2 expression was described in 14.3% of mucinous carcinomas. The variation in the rate of HER2 gene amplification and expression could be explained by several reasons including different detection methods used (immunohistochemistry, fluorescent in situ hybridization and chromogenic in situ hybridization), several types of biological material (blocks of tumors, tissue microarray), different immunohistochemical techniques (CB-11, HercepTest or non-commercial antibody), different staining protocols and subjective interpretation of stained samples. All these factors make difficult the comparison of HER2 status across research studies (Tuefferd et al., 2007).

In a previous study, McAlpine et al. investigated HER2 expression and amplification in 33 mucinous carcinomas and 16 mucinous borderline tumors of the ovary and they analyzed the potential use for trastuzumab therapy (McAlpine et al., 2009). Amplification of HER2 was observed in 18.2% mucinous carcinomas and 18.8% mucinous borderline tumors. HER2 amplification in primary mucinous carcinomas was not associated with an increased likelihood of recurrence. The prospectively identified recurrent mucinous carcinomas showed overexpression and amplification of HER2; one patient's tumor responded dramatically to trastuzumab in combination with conventional chemotherapy, while another patient experienced an isolated central nervous system recurrence after trastuzumab therapy. Thus, these

authors considered that in ovarian mucinous carcinomas, HER2 amplification not necessarily of prognostic significance and trastuzumab therapy provides a treatment option for patients when the tumor has HER2 amplification and overexpression (McAlpine et al., 2009).

Recently, in a large Asian retrospective cohort from Singapore, Chay et al. analyzed HER2 expression in 113 cases by immunohistochemistry and dual in situ hybridization (Chay et al., 2013). HER2 protein expression was described in 27.4% of mucinous epithelial ovarian cancer. They observed a lower HER2 positivity among Chinese and a higher HER2 expression among Malays patients (Chay et al., 2013). Previously, these authors analyzed HER2 expression in only 17 primary mucinous carcinomas in Singapore also. They described HER2 amplification and expression in 35.3% and 29.4%, respectively (Yan et al., 2011).

In a previous study, Anglesio et al. have demonstrated amplification of HER2 in 18.2% of mucinous ovarian carcinomas and presented anecdotal evidence of response with HER2-targeted treatment in a small series of women with recurrent HER2-amplified mucinous carcinomas (Anglesio et al., 2013). More recently, these authors explored HER2 amplification in an independent cohort of 189 mucinous carcinomas and 199 mucinous borderline ovarian tumors by immunohistochemistry, fluorescent in situ hybridization (FISH), and chromogenic in situ hybridization (CISH), and interpreted per ASCO/CAP guidelines (Anglesio et al., 2013). HER2 overexpression/amplification was reported in 18.8% of mucinous carcinomas and 6.2% of mucinous borderline tumors. In this study, there was excellent agreement between immunohistochemistry, FISH, and CISH assessment of HER2 status. HER2 amplification/overexpression was associated with decreased likelihood of disease recurrence. Thus, these authors supported the stratification of mucinous carcinomas for the testing of new treatments, with HER2-targeted therapy as a viable option for HER2+ advanced or recurrent disease (Anglesio et al., 2013).

HER2 expression has been analyzed across all histological subtypes of epithelial ovarian cancers and studies showed that HER2 status did not seem to be a significant event in nonmucinous epithelial ovarian cancers (Wu et al., 2004; Lin et al., 2011). Wu et al. showed previously that HER2 amplification is infrequent in early stage ovarian neoplasms: only 6.7% overall, including 3 serous carcinomas and one endometrioid carcinoma. None of the remaining 44 tumors (including clear cell carcinoma, transitional cell carcinoma, mixed epithelial carcinoma, carcinoma not otherwise specified) and 31 borderline tumors showed HER2 gene amplification or protein overexpression (Wu et al., 2004). However, Tuefferd et al. showed that the decision algorithm usually used in breast cancer (immunohistochemistry as a screening test, with equivocal results confirmed by FISH) is appropriate in ovarian cancer (Tuefferd et al., 2007).

In conclusion, HER2 expression is relatively common in mucinous epithelial carcinoma of the ovary, although not necessary of prognostic significance. Thus, trastuzumab therapy would be an option for patients with mucinous carcinoma when the tumor has HER2 overexpression.



## References

- Anglesio MS, Kommoss S, Tolcher MC, et al (2013). Molecular characterization of mucinous ovarian tumours supports a stratified treatment approach with HER2 targeting in 19% of carcinomas. *J Pathol*, **229**, 111-20.
- Auersperg N, Wong AS, Choi KC, et al (2001). Ovarian surface epithelium: biology, endocrinology, and pathology. *Endocr Rev*, **22**, 255-88.
- Bookman MA, Darcy KM, Clarke-Pearson D, et al (2003). Evaluation of monoclonal humanized anti-HER2 antibody, trastuzumab, in patients with recurrent or refractory ovarian or primary peritoneal carcinoma with overexpression of HER2: a phase II trial of the gynecologic oncology Group. *J Clin Oncol*, **21**, 283-90.
- Chay WY, Chew SH, Ong WS, et al (2013). HER2 amplification and clinicopathological characteristics in a large Asian cohort of rare mucinous ovarian cancer. *PLoS One*, **8**, 61565.
- Cuadros M and Villegas R (2009). Systematic review of HER2 breast cancer testing. *Appl Immunohistochem Mol Morphol*, **17**, 1-7.
- Di Fiore PP, Pierce JH, Kraus MH, et al (1987). erbB-2 is a potent oncogene when overexpressed in NIH/3T3 cells. *Science*, **237**, 178-82.
- Duman BB, Afsar CU, Gunaldi M, et al (2012). Retrospective analysis of neoadjuvant chemotherapy for breast cancer in Turkish patients. *Asian Pac J Cancer Prev*, **13**, 4119-23.
- Erdogan S, Ergin M, Tuncer I (2003). Comparison of differential PCR and immunohistochemistry for the evaluation of c-erbB-2 in breast carcinoma and relationship to other prognostic factors. *Neoplasma*, **50**, 326-30.
- Frederick PJ, Straughn JM Jr, Alvarez RD, et al (2009). Preclinical studies clinical utilization of monoclonal antibodies in epithelial ovarian cancer. *Gynecol Oncol*, **113**, 384-90.
- García-Velasco A, Mendiola C, Sanchez-Muñoz A, et al (2008). Prognostic value of hormonal receptors, p53, ki67 and HER2/neu expression in epithelial ovarian carcinoma. *Clin Trans Oncol*, **10**, 367-71.
- Ghaffari SR, Sabokbar T, Dastan J, et al (2011). Her2 amplification status in Iranian breast cancer patients: comparison of immunohistochemistry (IHC). and fluorescence in situ hybridisation (FISH). *Asian Pac J Cancer Prev*, **12**, 1031-4.
- Goldenberg MM (1999). Trastuzumab, a recombinant DNA-derived humanized monoclonal antibody, a novel agent for the treatment of metastatic breast cancer. *Clin Ther*, **21**, 309-18.
- Gravalos C, Jimeno A (2008). HER2 in gastric cancer: a new prognostic factor and a novel therapeutic target. *Ann Oncol*, **19**, 1523-9.
- Gurung A, Hung T, Morin J, et al (2013). Molecular abnormalities in ovarian carcinoma: clinical, morphological and therapeutic correlates. *Histopathology*, **62**, 59-70.
- Hess V, A'Hern R, Nasiri N, et al (2004). Mucinous epithelial ovarian cancer: a separate entity requiring specific treatment. *J Clin Oncol*, **22**, 1040-4.
- Kurman RJ, Seidman JD (2000). Ovarian serous borderline tumors: the citadel defended. *Hum Pathol*, **31**, 1439-42.
- Kauraniemi P, Kallioniemi A (2006). Activation of multiple cancer-associated genes at the ERBB2 amplicon in breast cancer. *Endocr Relat Cancer*, **13**, 39-49.
- Lin WL, Kuo WH, Chen FL, et al (2011). Identification of the coexisting HER2 gene amplification and novel mutations in the HER2 protein-overexpressed mucinous epithelial ovarian cancer. *Ann Surg Oncol*, **18**, 2388-94.
- McAlpine JN, Wiegand KC, Vang R, et al (2009). Overexpression and amplification is present in a subset of ovarian mucinous carcinomas and can be targeted with trastuzumab therapy. *BMC Cancer*, **9**, 433.
- Missaoui N, Trabelsi A, Parkin DM, et al (2010). Trends in the incidence of cancer in the Sousse region, Tunisia, 1993-2006. *Int J Cancer*, **127**, 2669-77.
- Moatter T, Aban M, Iqbal W, et al (2011). Status of HER2 amplification, polysomy 17 and histopathological features of 425 Pakistani breast cancer patients. *Asian Pac J Cancer Prev*, **12**, 3069-73.
- Nathanson DR, Nash GM, Chen B, et al (2003). Detection of HER-2/neu gene amplification in breast cancer using a novel polymerase chain reaction/ligase detection reaction technique. *J Am Coll Surg*, **197**, 419-25.
- Nicholson RI, Gee JM, Harper ME (2001). EGFR and cancer prognosis. *Eur J Cancer*, **37**, 9-15.
- Panagiotou I, Georgiannos SN, Tsiambas E, et al (2012). Impact of HER2 and PTEN simultaneous deregulation in non-small cell lung carcinoma: correlation with biological behavior. *Asian Pac J Cancer Prev*, **13**, 6311-8.
- Pazhoomand R, Keyhani E, Banan M, et al (2013). Detection of HER2 status in breast cancer: comparison of current methods with MLPA and real-time RT-PCR. *Asian Pac J Cancer Prev*, **14**, 7621-8.
- Pectasides D, Farmakis D, Koumariou A (2005). The role of neoadjuvant chemotherapy in the treatment of advanced ovarian cancer. *Oncology*, **68**, 64-70.
- Piccart-Gebhart MJ, Procter M, Leyland-Jones B, et al (2005). Trastuzumab after adjuvant chemotherapy in HER2-positive breast cancer. *N Engl J Med*, **353**, 1659-72.
- Romond EH, Perez EA, Bryant J, et al (2005). Trastuzumab plus adjuvant chemotherapy for operable HER2-positive breast cancer. *N Engl J Med*, **353**, 673-84.
- Rubin I, Yarden Y (2001). The basic biology of HER2. *Ann Oncol*, **12**, 3-8.
- Sardari Y, Pardis S, Tadbir AA, et al (2012). HER2/neu expression in head and neck squamous cell carcinoma patients is not significantly elevated. *Asian Pac J Cancer Prev*, **13**, 2891-6.
- Slamon DJ, Clark GM, Wong SG, et al (1987). Human breast cancer: correlation of relapse and survival with amplification of the HER-2/neu oncogene. *Science*, **235**, 177-82.
- Slamon DJ, Godolphin W, Jones LA, et al (1989). Studies of the HER3772/neu proto-oncogene in human breast and ovarian cancer. *Science*, **244**, 707-12.
- Shak S (1999). Overview of the trastuzumab (Herceptin). anti-HER2 monoclonal antibody clinical program in HER2-overexpressing metastatic breast cancer. Herceptin Multinational Investigator Study Group. *Semin Oncol*, **26**, 71-7.
- Tai CJ, Pan CK, Chen CS, et al (2013). Adjuvant trastuzumab for 6 months is effective in patients with HER2-positive stage II or III breast cancer. *Asian Pac J Cancer Prev*, **14**, 1981-4.
- Tavassoli FA, Devilee P (2003). Tumours of the breast and female genital organs. IARC, Lyon.
- Tuefferd M, Couturier J, Penault-Llorca F, et al (2007). HER2 status in ovarian carcinomas: a multicenter GINECO study of 320 patients. *PLoS One*, **2**, 1138.
- Unal B, Karaveli FS, Pestereli HE, et al (2013). Determination of HER2 gene amplification in breast cancer using dual-color silver enhanced in situ hybridization (dc-SISH). and comparison with fluorescence ISH (FISH). *Asian Pac J Cancer Prev*, **14**, 6131-4.
- Wang S, Zheng G, Chen L, et al (2011). Effect of HER-2/neu over-expression on prognosis in gastric cancer: a meta-analysis. *Asian Pac J Cancer Prev*, **12**, 1417-23.
- Weroha SJ, Oberg AL, Ziegler KL, et al (2011). Phase II trial of lapatinib and topotecan (LapTop). in patients with

- platinum-refractory/resistant ovarian and primary peritoneal carcinoma. *Gynecol Oncol*, **122**, 116-20.
- Wilson KS, Roberts H, Leek R (2002). Differential gene expression patterns in HER2/neu-positive and -negative breast cancer cell lines and tissues. *Am J Pathol*, **161**, 1171-85.
- Wolff AC, Hammond ME, Schwartz JN, et al (2007). American Society of Clinical Oncology/College of American Pathologists guideline recommendations guideline recommendations for human epidermal growth factor receptor 2 testing in breast cancer. *J Clin Oncol*, **25**, 118-45.
- Wu Y, Soslow RA, Marshall DS, et al (2004). Her-2/neu expression and amplification in early stage ovarian surface epithelial neoplasms. *Gynecol Oncol*, **95**, 570-5.
- Yan B, Choo SN, Mulyadi P, et al (2011). Dual-colour HER2/chromosome 17 chromogenic in situ hybridization enables accurate assessment of HER2 genomic status in ovarian tumours. *J Clin Pathol*, **64**, 1097-101.
- Ziaian B, Saberi A, Ghayyoumi MA, et al (2014). Association of high LDH and low glucose levels in pleural space with HER2 expression in non-small cell lung cancer. *Asian Pac J Cancer Prev*, **15**, 1617-20.