

RESEARCH ARTICLE

Diagnostic Aspects of Fine Needle Aspiration for Lung Lesions: Series of 245 Cases

Vladimir Kravtsov^{1,2}, Inna Sukmanov³, Dani Yaffe^{2,4}, David Shitrit^{2,5}, Maya Gottfried^{2,6}, Andreea Cioca⁷, Debora Kidron^{1,2*}

Abstract

Background: Transthoracic fine needle aspiration (FNA) is one of several methods for establishing tissue diagnosis of lung lesions. Other tissue or cell sources for diagnosis include sputum, endobronchial biopsy, washing and brushing, endobronchial FNA, transthoracic core needle biopsy, biopsy from thoracoscopy or thoracotomy. The purpose of this study was to compare the sensitivity and specificity of FNA and other diagnostic tests in diagnosing lung lesions. **Materials and Methods:** The population included all patients undergoing FNA for lung lesions at Meir Medical Center from 2006 through 2010. Information regarding additional tissue tests was derived from the electronic archives of the Department of Pathology, patient records and files from the Department of Oncology. Sensitivity, specificity, diagnostic accuracy, and positive and negative predictive values were calculated for each test. **Results:** FNA was carried out in 245 patients. Malignant tumors were diagnosed in 190 cases (78%). They included adenocarcinoma (43%), squamous cell carcinoma (15%), non-small cell carcinoma, not otherwise specified (19%), neuroendocrine tumors (7%), metastases (9%) and lymphoma (3%). The specificity of FNA for lung neoplasms was 100%; sensitivity and diagnostic accuracy were 87%. **Conclusions:** FNA is the most sensitive procedure for establishing tissue diagnoses of lung cancer. Combination with core needle biopsy increases the sensitivity. Factors related to the lesion (nature, degenerative changes, location) and to performance of all stages of test affect the ability to establish a diagnosis.

Keywords: FNA - lung neoplasm - diagnosis - immunohistochemistry - accuracy - specificity - sensitivity

Asian Pac J Cancer Prev, 15 (22), 9865-9869

Introduction

Tissue diagnosis of lung lesions is carried out by examining tissue taken from the lesions. The procedures include needle biopsy through skin (transthoracic), chest wall (thoracoscopy or thoracotomy), airways (bronchoscopy), or esophagus (trans- endoscopy). They are invasive and associated with complications.

Diagnosis of lung lesions is often carried out on cytological preparations. Diagnostic material can be derived from sputum, bronchoscopy brushings and washings, through the airways (endobronchial ultrasound (EBUS), pleural effusion. Fine needle aspiration (FNA) is used for getting cells through the skin (percutaneous transthoracic). The aspirated cells are used for preparation of smears and cell blocks. Immunohistochemical staining is carried out preferably on sections from cell blocks.

FNA of lung lesion is an old method, first described in 1886 by Menetrier. FNA of lung lesions under CT was first described in 1976 (Haaga and Alfid, 1976). Today, the procedure is performed under CT or ultrasound (US) guidance. In many instances, core needle biopsy is

performed simultaneously with the FNA.

The purpose of this study was to compare the sensitivity and specificity of FNA for diagnosis of lung lesions with transcutaneous core needle biopsy, sputum, endobronchial brushing and washing, and open biopsy or resection.

Materials and Methods

Cytological reports of FNA for lung lesions performed between 2006 and 2010 in Meir Medical Center, Kfar Sava, Israel were retrieved from the digital archives of the Department of Pathology.

The following data were extracted from the reports: age, gender, location of lesion, cytological diagnosis, diagnosis on cell block, immunohistochemical stains. Data regarding additional relevant cytological and histopathological tests were recorded: results of sputum analyses, bronchoscopy brushings and washings, needle biopsies and excisional procedures, including lesions in other organs (primary and metastatic). The gold standard was the histological diagnosis of the lesion (biopsy or

¹Department of Pathology, ⁴Department of Radiology, ⁵Department of Pulmonology, ⁶Department of Oncology, Meir Medical Center, Kfar Saba, ²Sackler School of Medicine, Tel Aviv University, ³Clalit Health Services, Tel Aviv, Israel, ⁷Department of Pathology, Iuliu Hatieganu University of Medicine and Pharmacy, Cluj-Napoca, Romania *For correspondence: dkidron@clalit.org.il

resection when available).

The diagnostic categorization of lesions undergoing FNA was based on cytological features and immunohistochemical expression. Immunohistochemical stains included pancytokeratin (AE1/AE3), cytokeratin 7, cytokeratin 20, p63, TTF1, chromogranin, synaptophysin and lymphoid markers, if indicated. Diagnostic categories were adenocarcinoma, squamous cell carcinoma, non-small cell lung cancer not otherwise specified (NSCLC, NOS), neuroendocrine tumors, including small cell lung cancer (SCLC) and carcinoid, metastasis, lymphoma, benign tumor, negative for tumor. The data were recorded on Excel spreadsheets.

Sensitivity, specificity, diagnostic accuracy, positive and negative predictive values of FNA and other tissue tests for diagnosis of lung lesions were calculated.

Results

In the five year period from 2006 through 2010, 245 CT guided percutaneous FNA for diagnosis of lung lesions were performed at Meir Medical Center.

Average age of the patients was 67.6 ± 11.3 years (range 28-89). There were 154 males and 91 females (M/F ratio = 1.7). The cytological diagnoses are detailed in Table 1. Neoplastic lesions were diagnosed in 191 FNA (78%). They included 190 malignant lesions and 1 benign lesion. The type and relative frequency of malignant tumors is seen in Figure 1.

Additional tissue tests performed for diagnosis of lesions and their diagnostic sensitivity in establishing the diagnosis are detailed in Table 2.

Adenocarcinoma

Adenocarcinoma was diagnosed by FNA in 82 cases. Morphological features alone were sufficient to establish the diagnosis in 29 cases. Immunohistochemical stains were carried out in 42 cases. They included cytokeratin intermediate filaments (pancytokeratin (AE1/AE3), cytokeratin 20, cytokeratin 7, cytokeratin 8/18,) p63 and TTF1. The immunohistochemical stains helped confirm the diagnoses and differentiate from squamous cell carcinoma. Only one case had to be differentiated from SCLC by neuroendocrine markers (synaptophysin and chromogranin).

Additional tissue tests were performed in 53 cases. Bronchial washings and brushings were diagnostic in 6/27 cases (22%). Needle biopsies were diagnostic for adenocarcinoma in 9/17 cases (53%). Resection specimens were available in 15 cases (confirming the FNA diagnosis).

Squamous cell carcinoma

Squamous cell carcinoma was diagnosed by FNA in 31 cases. Morphological features alone were sufficient to determine the diagnosis in 18 cases. Immunohistochemical stains (including cytokeratin 7, p63 and TTF1) were carried out in 11 cases. As in the case of adenocarcinoma, the immunohistochemical stains helped confirm the diagnosis.

Additional tissue tests were performed in 11 cases. Bronchial washings and brushings were done in 7 cases. None was diagnostic. Needle biopsies were diagnostic for squamous cell carcinoma in 5 out 8 cases (62%). Resection specimens were available in 4 cases (confirming the FNA diagnosis).

False negative diagnosis of squamous cell carcinoma by FNA occurred in 2 cases. The cytological smears had blood only whereas the needle biopsy contained diagnostic material.

Non-small cell lung cancer, not otherwise specified

The diagnosis NSCLC by FNA was set in 39 cases,

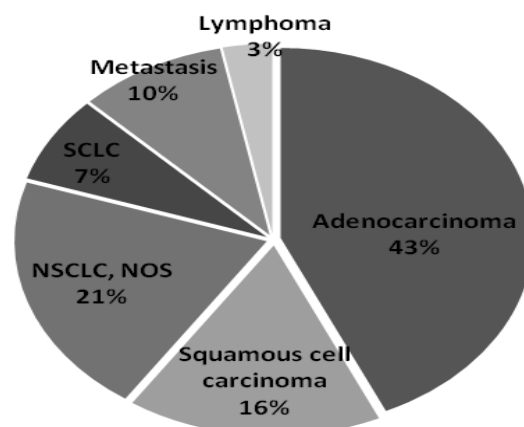


Figure 1. Type and Relative Frequency of 190 Malignant Lung Lesions

Table 1. The Cytological Diagnoses in Males and Females in 245 FNA of Lung Lesions

Diagnosis	Males	Females	Total
Adenocarcinoma	52	30	82
Squamous cell carcinoma	22	9	31
NSCLC, NOS	28	11	39
SCLC	12	2	14
Metastasis	4	14	18
Lymphoma	3	3	6
Benign tumors	1	0	1
Tumors (total)	122	69	191
Negative for tumor	32	22	54

Table 2. Diagnostic Sensitivity of Tests in Establishing the Diagnosis of Malignant Lung Tumors

Diagnosis	No. of cases	FNA	Sputum, bronchial washings and brushing	Endobronchial biopsies	True-cut biopsies	Open biopsy/resection
Adenocarcinoma	82	82/82	15/15	9/17	6/27	6/27
Squamous cell carcinoma	31	29/31	4/4	5/8	0/7	0/7
NSCLC, NOS	39	38/39	1/4	2/8	1/12	1/12
SCLC	14	14/14	1/2	6/6	2/5	2/5
Metastasis	18	16/18	7/7	6/7	0/0	0/1
Lymphoma	6	2/6	2/2	4/4	0/1	0/0

where no obvious, glandular, squamous or neuroendocrine differentiation was demonstrated, either morphologically or by immunohistochemical techniques. Negative immunohistochemical stains for cytokeratin 7, p63 and TTF1 were shown in 10 cases. The aspirated material was insufficient for immunohistochemical stains in 22 cases.

Additional tissue tests were performed in 15 cases. Bronchial washings and brushings were diagnostic in 1/12 cases (8%). Needle biopsies were diagnostic 2/8 cases (25%). Resection procedures were performed in 4 cases.

Neuroendocrine tumors

SCLC by FNA was diagnosed in 13 cases. The remaining case was typical carcinoid. No false negative diagnosis was made in this group. Cytological smears alone (without sufficient material for immunohistochemical studies) were diagnostic in 5 cases. Immunohistochemical stains were performed in 9 cases. They included the neuroendocrine markers (synaptophysin and chromogranin), as well as cytokeratins (AE1/AE3, 7, 20 and CAM 5.2), Ki67, p63 and TTF1.

Additional tissue tests for the diagnosis were available in 7 cases. Needle biopsies (with the same diagnosis) were performed in 5 cases. Resection procedures were performed in 4 cases (including typical carcinoid).

Metastasis

FNA from lung metastases was positive in 16 out of 18 cases (89%). They included breast cancer (5 cases), colorectal cancer (5 cases), renal cell carcinoma (2 cases), malignant melanoma (2 cases), prostate cancer (2 cases), gastric carcinoma (1 case) and leiomyosarcoma (1 case). The FNA failed to show tumor cells in 2 cases due to scanty cellular material. The diagnosis in these cases was performed on needle biopsies.

The diagnosis was based on typical cytomorphic features with similarity to primary tumor) in 6 cases. Immunohistochemical studies were performed in order to rule out primary lung tumor. They included cytokeratin 7, p63, and TTF1.

Lymphoma

Malignant lymphoma by FNA was diagnosed in 2/6 cases (33%) in this series. They were previously diagnosed cases of Hodgkin's lymphoma and mantle cell lymphoma of the stomach.

The remaining 4 cases were not diagnostic for lymphoma by FNA. The diagnosis was done with needle biopsy (2 cases) and open biopsy (2 cases). The diagnoses were pulmonary involvement by advanced stage large B cell lymphoma (2 cases), large B cell lymphoma of lung (1 case), and MALT lymphoma of lung (1 case).

Benign tumors

Bronchial hamartoma was diagnosed in 1 case.

FNA negative for tumor

The FNA was negative for tumor cells in 66/245 (27%) cases. Tissue diagnosis of tumor was determined by other tests in 12 (18%) cases. Negative FNA with negative other tissue tests were present in 54 cases. A neoplastic process

Table 3. True and False Positive and Negative Cases by FNA, Needle Biopsies, Bronchial Washings and Brushings and Simultaneous FNA + Needle Biopsies

Diagnostic Test	Patients with tumors	Patients without tumors
Positive FNA	180	0
Negative FNA	30	35
Positive needle biopsy	30	0
Negative needle biopsy	12	21
Positive (FNA + needle biopsy)	47	0
Negative (FNA + needle biopsy)	5	11
Positive brushings and washings	8	0
Negative brushings and washings	44	10

Table 4. Sensitivity and Specificity for FNA, Needle Biopsies, Bronchial Washings and Brushings and Simultaneous FNA + Needle Biopsies in the Diagnosis of Lung Masses

Sample Source	Sensitivity	Specificity
FNA	85.70%	100%
Needle biopsy	71.00%	100%
Simultaneous FNA and needle biopsy	90.40%	100%
Brushings and washings	15.70%	100%

was discovered in later stages in 19 cases. They included 11 (58%) cases of NSCLC, 6 (31.5%) cases of metastasis and 2 (10.5%) cases of lymphoma. These lesions involved the left lung in 67.7% of the cases, predominantly the left upper lobe.

Sensitivity, specificity, accuracy, positive and negative predictive values of FNA

True and false positive and negative cases by FNA, needle biopsies, bronchial washings and brushings and simultaneous FNA and needle biopsies are shown in Table 3. The sensitivity and specificity for FNA, needle biopsies, bronchial washings and brushings and simultaneous FNA and needle biopsies in the diagnosis of lung masses are shown in Table 4. The positive predictive value of FNA for the diagnosis of lung tumors was 100% in our series. The negative predictive value of FNA was 53.8%. The diagnostic accuracy of FNA in our series was 87%.

Discussion

Lung cancer is a major cause of morbidity and mortality throughout the world with variation among nations and ethnicities (Demirci et al., 2013). The pathological classification of lung cancer was recently updated (Travis et al., 2013). Accurate pathologic diagnosis is crucial for selecting appropriate treatment.

The ability to reach a conclusive diagnosis with FNA depends on optimal performance of all stages of the procedure. Sampling: The FNA is performed by a radiologist under imaging, usually CT. The sampling equipment and technique, location of the lesion, its size, texture, necrosis and amount of aspirated material are important factors, as discussed elsewhere (Hiraki et al., 2009).

Cytological evaluation provides an provisional

diagnosis (Mullan et al., 2004).

The complications associated with the procedure gave rise to efforts to develop alternative methods for tissue sampling. Among recent methods are: a. Endobronchial US guided sheath (EBUS GS) transbronchial lung biopsy. The procedure was first described in 2003. It helps increase sensitivity and reduces the incidence of pneumothorax. It is effective for lesions in vicinity of large bronchi (Herth et al., 2002; Senturk et al., 2014). b. Endoscopic ultrasound guided FNA (EUS-FNA). This approach is effective for mediastinal lesions, including lymph node sampling for staging of NSCLC. The sensitivity of this technique is 93% and specificity 100% (Yasufuku et al., 2008).

Processing: The utilization of the entire sample for preparation of cytological smears, cell block, and optimal staining are important factors. Specific antibodies for immunohistochemistry help increase the diagnostic accuracy. Cell block can provide enough tissue sections for immunohistochemical stains. The cytoscraps technique has been described for cases with scanty material (Nga et al., 2005; Skov et al., 2009).

Interpretation: The experience, proficiency and confidence of the cytotechnologists and cytopathologist affect the results.

The role of genetic markers in the diagnosis, subclassification, anticipated response to specific drugs and the prognosis of lung cancer is increasing. The distinction of benign from malignant lesions can be supported by FISH markers (Gill et al., 2008; Guber et al., 2010; Savic and Bubendorf 2012).

Sensitivity and specificity of FNA for lung lesions: The specificity of FNA in this series was 100%. The specificity of needle biopsy and bronchial washings was 100%. Since false positive cases are rare (0-1%), the specificity is around 100% in similar series (Layfield et al., 1996; Afify and Davila 1999; Arslan et al., 2002; Kim et al., 2002; Gong et al., 2006).

The sensitivity in this series was 87.5%. The range of sensitivity in series from the last 15 years is 74-95%. In this series, 30 of 245 cases (12%) were false negative. The sensitivity of NSCLC is lower than that of SCLC. The nature of SCLC may facilitate aspiration of sufficient diagnostic material. Among 6 cases of malignant lymphoma, 4 (66%) were false negative. Contributing factors for this low sensitivity can be related to difficulty in establishing diagnosis of malignant lymphoma on cytological material and low index of suspicion for extra-nodal lymphoma.

Possible causes for low sensitivity of FNA for lung lesions arranged by stages are: a. Inadequate sampling: few cells, abundant necrosis or hemorrhages. Interestingly, 51% of false negative cases were left upper lobe lesions. It is possible that this location affects the ability to aspirate enough cellular material. Sufficient amount of representative cells from the lesion is required for cytological smears, as well as immunohistochemical stains and molecular studies. b. Suboptimal preservation and preparation of smears. c. Interpretation: The experience, proficiency, confidence and diligence of the cytotechnologists and cytopathologist.

The diagnostic accuracy of FNA in diagnosing lung

lesions in this series was 87%. The positive predictive value of FNA in lung lesions was 100%, owing to 0% false positive cases. The negative predictive value was 53.8%.

FNA of lung masses is an invasive procedure, associated with complications. Nevertheless, it is an effective procedure for establishing tissue diagnosis of lung neoplasms. In this series, the diagnostic accuracy of this test was 87%. Its specificity was 100%. The sensitivity was higher than that of needle biopsy (71%). The combination of needle biopsy and FNA raised the sensitivity to 90%.

Factors related to sampling, preparation and interpretation of the test are crucial for establishing the diagnosis. The nature of the lesion, degenerative changes involved, location within the lung, amount of aspirated material, ability to perform ancillary studies, experience and proficiency of personnel, all affect the final result. A continuous learning process is essential for improving these skills. It can be achieved by regular meetings, interdepartmental consultations and participation in specialty conferences.

On one hand, the emergence of molecular tests for diagnosis and prediction of response to specific treatment (Unal et al., 2013) emphasize the importance of the FNA, as a means of getting representative material from lung neoplasms. The new treatment modalities, including targeted biological therapies and specific chemotherapeutic agents dictate the need for unquestionably accurate diagnoses, with optimal use of immunohistochemical stains and maximal preservation of representative tissue (Montezuma et al., 2013). FNA, side by side with other diagnostic and prognostic assays (Kaya et al., 2013) help in achieving these goals.

References

- Afify A and Davila RM (1999). Pulmonary fine needle aspiration biopsy. Assessing the negative diagnosis. *Acta Cytol*, **43**, 601-4.
- Arslan S, Yilmaz A, Bayramgürler B et al (2002). CT-guided transthoracic fine needle aspiration of pulmonary lesions: accuracy and complications in 294 patients. *Med Sci Monit*, **8**, 493-7.
- Demirci E, Daloglu F, Gundogdu C, et al (2013). Incidence and clinicopathologic features of primary lung cancer: a North-Eastern Anatolia region study in Turkey (2006-2012). *Asian Pac J Cancer Prev*, **14**, 1989-93.
- Gill RK, Vazquez MF, Kramer A, et al (2008). The use of genetic markers to identify lung cancer in fine needle aspiration samples. *Clin Cancer Res*, **14**, 7481-7.
- Gong Y, Sneige N, Guo M, Hicks ME, Moran CA (2006). Transthoracic fine-needle aspiration vs concurrent core needle biopsy in diagnosis of intrathoracic lesions: a retrospective comparison of diagnostic accuracy. *Am J Clin Pathol*, **125**, 438-44.
- Guber A, Greif J, Rona R, et al (2010). Computerized analysis of cytology and fluorescence in situ hybridization (FISH) in induced sputum for lung cancer detection. *Cancer Cytopathol*, **118**, 269-77.
- Haaga JR, Alfidi RJ (1976). Precise biopsy localization by computer tomography. *Radiology*, **118**, 603-7.
- Herth FJ, Ernst A, Becker HD (2002). Endobronchial ultrasound-guided transbronchial lung biopsy in solitary pulmonary

- nodules and peripheral lesions. *Eur Respir J*, **20**, 972-4.
- Hiraki T, Mimura H, Gobara H, et al (2009). CT fluoroscopy-guided biopsy of 1,000 pulmonary lesions performed with 20-gauge coaxial cutting needles: diagnostic yield and risk factors for diagnostic failure. *Chest*, **136**, 1612-17.
- Kaya V, Yildirim M, Demirpence O, Yildiz M, Yalcin AY (2013). Prognostic significance of basic laboratory methods in non-small-cell-lung cancer. *Asian Pac J Cancer Prev*, **14**, 5473-6.
- Kim HK, Shin BK, Cho SJ, et al (2002). Transthoracic fine needle aspiration and core biopsy of pulmonary lesions. A study of 296 patients. *Acta Cytol*, **46**, 1061-8.
- Layfield LJ, Coogan A, Johnston WW, Patz EF (1996). Transthoracic fine needle aspiration biopsy. Sensitivity in relation to guidance technique and lesion size and location. *Acta Cytol*, **40**, 687-90.
- Montezuma D, Azevedo R, Lopes P, et al (2013). A panel of four immunohistochemical markers (CK7, CK20, TTF-1, and p63) allows accurate diagnosis of primary and metastatic lung carcinoma on biopsy specimens. *Virchows Arch*, **463**, 749-54.
- Mullan CP, Kelly BE, Ellis PK, et al (2004). CT-guided fine-needle aspiration of lung nodules: effect on outcome of using coaxial technique and immediate cytological evaluation. *Ulster Med J*, **73**, 32-6.
- Nga ME, Lim GL, Barbro N, Chan NH (2005). Successful retrieval of fine-needle aspiration biopsy material from previously stained smears for immunocytochemistry: a novel technique applied to three soft tissue tumors. *Mod Pathol*, **18**, 728-32.
- Savic S and Bubendorf L (2012). Role of fluorescence in situ hybridization in lung cancer cytology. *Acta Cytol*, **56**, 611-21.
- Senturk A, Babaoglu E, Kilic H, et al (2014). Endobronchial ultrasound-guided transbronchial needle aspiration in the diagnosis of lymphoma. *Asian Pac J Cancer Prev*, **15**, 4169-73.
- Skov BG, Kiss K, Ramsted J, Linnemann D (2009). A technique to improve diagnostic information from fine-needle aspirations: immunohistochemistry on cytoscape. *Cancer*, **117**, 120-7.
- Travis WD, Brambilla E, Riely GJ (2013). New pathologic classification of lung cancer: relevance for clinical practice and clinical trials. *J Clin Oncol*, **31**, 992-1001.
- Unal OU, Oztop I, Calibasi G, et al (2013). Relationship between epidermal growth factor receptor gene mutations and clinicopathological features in patients with non-small cell lung cancer in western Turkey. *Asian Pac J Cancer Prev*, **14**, 3705-9.
- Yasufuku K, Nakajima T, Fujiwara T, et al (2008). Role of endobronchial ultrasound-guided transbronchial needle aspiration in the management of lung cancer. *Gen Thorac Cardiovasc Surg*, **56**, 268-76.