

RESEARCH ARTICLE

Expression of Cytoplasmic 8-oxo-Gsn and MTH1 Correlates with Pathological Grading in Human Gastric Cancer

Wen-Jie Song¹, Ping Jiang², Jian-Ping Cai², Zhi-Qiang Zheng^{1*}

Abstract

Background: Cancers have dysfunctional redox regulation resulting in production of reactive oxygen species (ROS), damaging DNA, RNA and free NTPs, and causing the accumulation of oxidative nucleic acids in cytoplasm. The major types are 8-oxo-7,8-dihydroguanine(8-oxoGsn) in RNA and 8-oxo-7,8-dihydro-2' deoxyguanosine(8-oxodGsn) in Mt-DNA. The MTH1 protein sanitizes oxidized nucleotide pools from NTPs to monophosphates, preventing the occurrence of transversion mutations. This study concerned cytoplasmic 8-oxodGsn/Gsn and MTH1 expression in gastric cancer and para-cancer tissues and elucidated roles of nucleic-acid oxidation and anti-oxidation. **Materials and Methods:** A polymer HRP detection system was used to detect 8-oxo-Gsn/dGsn and MTH1 expression in 51 gastric cancer and para-cancer tissue samples. Analyses of patient clinical and pathological data were also performed. **Results:** The expression of MTH1 and the 8-oxo-dGsn/Gsn ratio were significantly higher in cancer tissues than para-cancer tissues ($P<0.05$). Cytoplasmic 8-oxo-Gsn and MTH1 were both found to positively correlate ($P<0.05$) with tumor differentiation, while no significant associations were found with gender, age, invasion depth, lymph node metastasis and clinical stage ($P>0.05$). **Conclusions:** We found 8-oxo-dGsn/Gsn and MTH1 are both highly expressed in gastric cancer tissues, especially in well differentiated lesions. In addition, oxidated mtDNA is prevalently expressed in gastric cancers, while 8-oxo-Gsn expression in cytoplasmic RNA is a bit lower, but more selectively.

Keywords: Gastric cancer - ROS - MTH1 - nucleic acids - oxidation

Asian Pac J Cancer Prev, 16 (15), 6335-6338

Introduction

The accumulation of oxidative damage in nucleic acids is one of the major causes for mutagenesis and cell death (Nakabeppu et al., 2004). Among the cytoplasmic oxidative nucleic acids, 8-oxo-7,8-dihydroguanine (8-oxoGsn) of RNA and 8-oxo-7,8-dihydro-2' deoxyguanosine (8-oxodGsn) of Mt-DNA are the major types, while oxidative NTP pools, such as 8-oxo-dGTP, which is a product of dGTP oxidation and can be inserted into opposite dA or dC residues of template DNA at almost identical efficiencies, causing G:C to T:A or T:A to G:C transversion mutations. While, MTH1 is an oxidized purine nucleoside triphosphatase that upregulates to prevent cellular DNA or RNA oxidative damage, when 8-oxodGsn/Gsn increase (Shimura-Miura et al., 1999, Kosuke et al., 2006). Recently, Helge et al. (2014) and Huber et al. (2014) reported in nature that cancer cells required MTH1 activity to avoid incorporation of oxidized NTPs, resulting in nucleic-acid damage and cell death.

Overexpression of MTH1 has been reported (Okamoto et al., 1996; Kennedy et al., 2003; Koketsu et al., 2004) in various tumors except gastric cancer. To explore the correlation between oxidation, MTH1 expression and

human gastric adenocarcinoma, we investigated the expression pattern of MTH1 and 8-oxoGsn/dGsn in this form of cancer. To the best of our knowledge, this is the first report describing the expression of MTH1 and 8-oxoG in gastric cancer.

Materials and Methods

Clinical data collection

In this study, 51 cases were selected. The patients had been confirmed histologically gastric cancer and received cancer radical operation at the second affiliated hospital of Wenzhou Medical University, during 2009-2013. Histological stages were graded according to the TNM classification (UICC/AJCC 2010).

Experimental reagents

Ployclonal rabbit anti-human MTH1 antibody (dilution 1:200) and monoclonal mouse Anti-8 Hydroxyguanosine antibody (dilution 1:300) were both purchased from Abcam. The corresponding secondary donkey polymer immunohistochemical staining hypersensitivity kit anti-mouse/rabbit antibody were obtained from ZSGB-BIO. (Beijing, China).

¹Department of Gastrointestinal Surgery, the Second Hospital of Wenzhou Medical University, Wenzhou, Zhejiang, ²The Key Laboratory of Geriatrics, Beijing Hospital & Beijing Institute of Geriatrics, Ministry of Health, Beijing, China *For correspondence: Zhe_Zhi2000@aliyun.com

Immunohistochemistry experimental procedures.

Resected tumor tissue of all cases were fixed in 4% formaldehyde solution (pH7.0) for periods not exceeding 24 h. The tissues were processed routinely for paraffin embedding, and 3ul thick sections were cut within a cryostat and placed on cationic anti-slip glass slides (ZSGB BIO., Beijing, China) for immunohistochemistry. Tissue samples were stained with hematoxylin and eosin to determine histological type and grade of tumors.

For the detection of 8-oxo-dGsn and 8-oxoGsn (Zheng et al.,2009; Song et al., 2011). The sections were de-waxed using xylene and gradually dehydrated with gradient ethanol and washed with PBS. Antigen retrieval was performed by microwave at 95°C for 15min with buffer solution of citrate salts (pH 6.0) (Maixin Bio., Beijing, China). For the detection of 8-oxo-dGsn in mitochondria, 5mg/ml RNase A (10mg/ml, TakaRa Biotechnology Co., Ltd, Dalian, China) treated sections were directly subjected to IHC with the 15A3 mAb. While to detect the 8-oxo-Gsn in RNA, the sections were treated with 3N HCl at room temperature (RT) for 30min, thus denaturing the nuclear and mitochondrion DNA, then the sections were treated with 50mM Tris-Base for 5 min, furthermore, the sections were treated with DNase I (1000U/ml, TakaRa Biotechnology Co., Ltd, Dalian, China) to remove nuclear or mitochondria DNA, then subjected to IHC with the 15A3 mAb. Besides, the MTH1 staining was performed according to the instructions provided by manufacturer.

The staining intensity of the cells was graded as follows: 0, negative; 1, light yellow granules; 2, deep yellow granules; and 3, brown granules points. Grading was performed as follows: 0, positive cell ratio ≤5%; 1, 5% < positive cell ratio ≤25%; 2, 25% < positive cell ratio ≤50%; 3, 50% < positive cell ratio ≤75%; and 4, 75% < positive cell ratio ≤100% points. The final points score for expression was determined through the multiplication of

the points for staining intensity by the points for positive cell ratio. The expression levels were graded as follows: -, points ≤4; +, 4 < points ≤8; ++, 8 < points ≤12; and +++, points >12. Points less than 4 was determined as MTH1 and 8-oxo-dGsn negative, whereas +, ++ and +++ were determined as positive. The expression of 8-oxo-Gsn in RNA, was defined as points <3 as negative and ≥3 positive.

Statistical analyses

Data analyses were performed using SPSS software, version 20.0 (SPSS Inc., Chicago, IL, USA). The χ^2 test was used to evaluate the MTH1 and 8-oxo-dGsn/Gsn expression differences between gastric cancer and para-cancer tissues. The association between MTH1 or 8-oxo-dGsn/Gsn expression and other clinicopathological parameters, including gender, age, clinical stage, histological grade, lymph node metastasis, tumor size and depth of invasion were also analyzed. *P* values of less than 0.05 were considered statistically significant.

Results

Patient characteristics

The mean age of the 51 patients studied was 63.27 years (range 42-87), including 34 male and 17 female. No significant difference was found in age and gender (*P*=0.43). Within the total sample, 11 gastric cancer are determined as pathological grade I, 13 as grade II, 5 as grade II-III, 13 as grade III, and 8 grade IV.

Assessment of MTH1 and 8-oxo-dGsn/Gsn expression

Of the 51 gastric cancer cases, 24 (47.1%) exhibited positive MTH1 expression (mainly in the cytoplasm) and 27 (52.9%) exhibited negative MTH1 expression. In the corresponding para-cancer tissue samples, only 6 (11.7%) exhibited positive MTH1 expression. The difference in

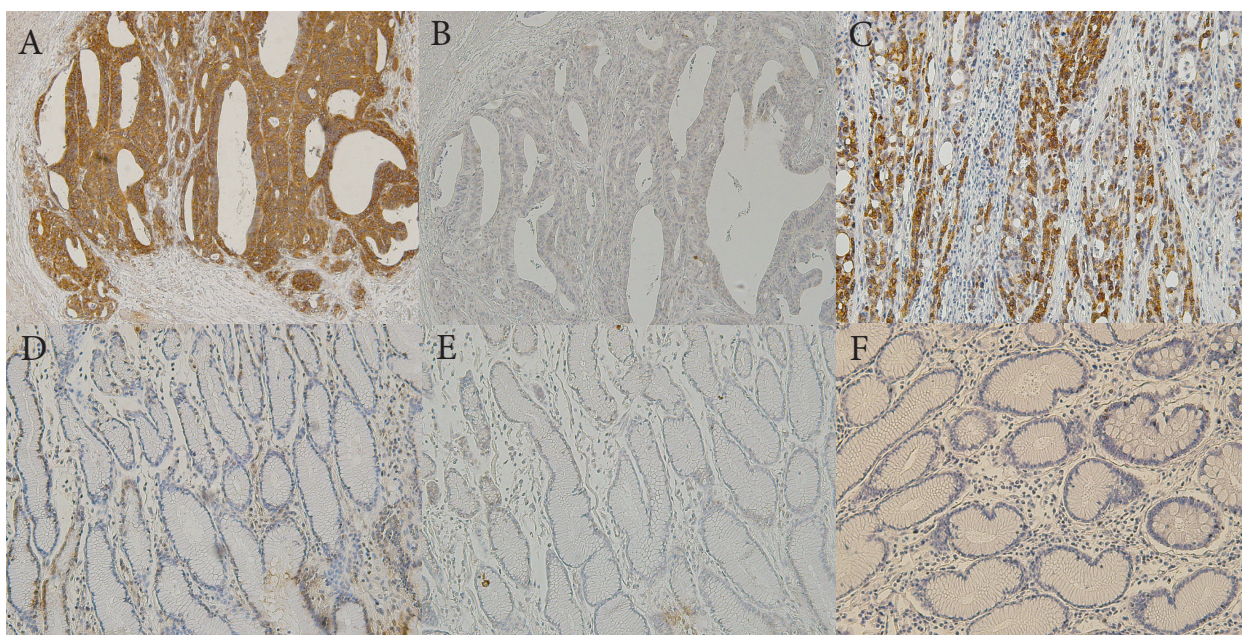


Figure 1. MTH1 Expression in Gastric Cancer and Para-Cancer Tissues Detected by Using Polymer Immunohistochemical Staining (Magnification, x200). (A) 8-oxo-dG staining in Moderately differentiated gastric cancer. (B) Negative expression of 8-oxo-Gsn. (C) Positive expression of MTH1. (D)(E)(F) are negative expression of para-cancer tissues of 8-oxo-dG/G and MTH1, respectively

Table 1. Oxidative Nucleic Acids Expression in Gastric Cancer and Para-Cancer Tissues

	Gastric cancer		Expression ratio	Para-cancer tissues		Expression ratio	P-value
	Positive	Negative	%	Positive	Negative	%	
MTH1	24	27	47.1	6	45	11.7	<0.05
8-oxo-dGsn	27	24	52.9	12	39	19.6	<0.05
8-oxo-Gsn	16	35	31.4	7	44	13.7	<0.05

p<0.05

Table 2. Association between MTH1, 8-oxo-dG/G Expression and other Clinicopathological Features of Gastric Cancer

Clinical data	MTH		P value	8-oxo-dGsn		P value	8-oxo-Gsn		P value
	Positive	Negative		Positive	Negative		Positive	Negative	
Gender			0.074			0.552			0.831
Male	19	15		19	15		11	23	
Femal	5	12		8	9		5	12	
Age(years)			0.692			0.869			0.135
≤65	12	15		14	13		6	21	
>65	12	12		13	11		10	14	
Pathological grading			0.017*			0.895			0.012*
Highly differentiated (I, II)	16	9		13	12		12	13	
Poorly differentiated(II-IV)	8	18		14	12		4	22	
Clinical staging			0.507			0.22			0.279
Stage I+II	12	11		10	13		9	14	
Stage III+IV	12	16		17	11		7	21	
Depth of invasion			0.712			0.796			0.078
T1+T2	6	8		7	7		7	7	
T3+T4	18	19		20	17		9	28	
Lymph node metastasis			0.585			0.539			0.203
No	8	11		9	10		8	11	
Yes	16	16		18	14		8	24	
Tumor size (cm)			0.869			0.692			0.776
≤3	13	14		15	12		8	19	
>3	11	13		12	12		8	16	

*: P<0.05; **: P<0.01

MTH1 expression between gastric cancer and para-cancer tissues was found to be statistically significant ($P<0.05$).

As for mitochondrial 8-oxo-dGsn expression, 27 (52.9%) gastric cancer cases exhibited positive expression, and 24 (47.1%) negative. While 12 (19.61%) para-cancer tissue samples exhibited positive 8-oxo-dG expression, statistically significant difference ($P<0.05$) was found between cancer and para-tissue (Table 1).

The similarity was seen in 8-oxo-Gsn expression, 16 (31.4%) cases exhibited positive 8-oxo-Gsn expression, and 35 (68.6%) negative. While 7 (13.7%) para-cancer tissue samples exhibited positive 8-oxo-dG expression, statistically significant difference ($P<0.05$) was found between cancer and para-tissue. The results are shown in Figure 1 and Table I.

Association between MTH1, 8-oxo-dG/G expression with other clinicopathological features

There was no significant association between MTH1 or 8-oxo-dGsn/Gsn expression and gender, age, tumor size, tumor location, tumor invasion depth, clinical stage, as well as lymph node metastasis ($P>0.05$). However, both MTH1 and 8-oxo-Gsn expression exhibited a significant positive correlation with pathological grade ($P<0.05$). The results are presented in Table 2.

Discussion

Accumulation of ROS is a double-edged sword. On one hand, ROS has been proved to be an endogenous class of carcinogens in the past decades (Guyton et al., 1993; Cerutti et al., 1994; Feig et al., 1994), on another, excessive ROS might induce cancer cells apoptosis, necrosis, or autophagy (Green et al., 1998; Golstein et al., 2007; Orrenius et al., 2007; Levine et al., 2008), leading to a low survival of cancer cells.

8-Oxo-dGTP is a product of dGTP oxidation and can be inserted into opposite dA or dC residues of template DNA at almost identical efficiencies, so is the same as 8-oxo-GTP. As a result, G:C to T:A or T:A to G:C transversion mutations occur (Shibutani et al., 1991; Maki et al., 1992; Cai et al., 1997). As to mtDNA, which is more susceptible to mutations or damage induced by high level of ROS production in mitochondria of cancer cells, due to limited repair mechanisms compared to nuclear DNA (Zhu et al., 2005; Saffran et al., 2006; Trachootham et al., 2006; Clay Montier et al., 2009). And now it is clear that mtDNA mutation influences OXPHOS function which associated with tumorigenesis (Woo et al., 2012; Yadav et al., 2013). In our study, 52.9% (27/51) gastric cancer samples show positive expression of 8-oxo-dGsn in mtDNA, besides,

no significant difference was found with other parameters, which means that oxidated mtDNA is prevalent among the whole gastric cancer, meanwhile, it is also a metabolic dysfunction signal of cancer cells, or even for normal cells.

However, 8-oxo-Gsn in cytoplasmic RNA expression is a bit lower, but more selectively. 8-oxo-Gsn is positive expressed in 31.4% (16/51) of all the gastric cancer samples. In pathological grade I and II cases, the expression ratio are 6/11 and 6/14, while, in grade II-III, III, IV are 1/5, 2/13, 1/8, respectively. Which suggesting that better-differentiated gastric cancer specimen show higher expression of 8-oxo-Gsn in RNA than poorly-differentiated specimen. Interestingly, this just in accordance with the tendency of MTH1 expression, which, was expressed in grade I, II, II-III, III and IV, by 8/11, 8/14, 1/5, 4/13, 3/8, respectively.

The MTH1 protein sanitizes both oxidized dNTP and NTP pools, for example, by converting 8-oxoGTP to monophosphate, thereby preventing incorporation of 8-oxo-7, 8-dihydroguanine into RNA or 8-hydroxy-2'-deoxyguanosine into DNA. Recently, Helge et al. (2014) and Huber et al. (2014) reported on Nature that, MTH1 is required for cancer survival, suggesting anticancer strategy by inhibiting MTH1 protein, thus, resulting in excessive oxidative damage of cancer nucleic acid, causing a considerable decrease of cancer survival. Our study revealed the high expression of MTH1 protein, which just accorded with the reports of Helge Gad and Huber, moreover, we found MTH1 selectively high expressed in well differentiated gastric cancer.

Therefore, We speculated that the increased ROS level of gastric cancer mainly originated from its dysfunctional mitochondria. The level of ROS might dramatically relevant with mitochondrial capacity (quantity, size and maturity level of mitochondria), and oxidized RNA might produce abnormal protein that, with the dysfunctional mitochondria together, influence cancer differentiation and cancer behavior. However, MTH1 is a momentous protein for cancer cells defending oxidative damage. Thus, a novel anticancer strategy could be actualized through enhancing cancer oxidative stress and inhibiting MTH1 protein, simultaneously.

Acknowledgements

This work was supported by a grant from the Key Laboratory of Geriatrics, Beijing Hospital.

This work would not have been possible without the pioneering work and the great mentorship of Dr. Ping-Jiang and Dr. Xiaoyang-Zhou.

References

- Cai JP, Kawate H, Ihara K, et al (1997). Significance of the conserved amino acid sequence for human MTH1 protein with antimutator activity. *Nucleic Acids Res*, **25**, 1170-6.
- Cerutti PA (1994). Oxy-radicals and cancer. *Lancet*, **344**, 862-3.
- Trachootham D, Zhou Y, Zhang H, et al (2006). Selective killing of oncogenically transformed cells through a ROS-mediated mechanism by beta-phenylethyl isothiocyanate. *Cancer Cell*, **10**, 241-52.
- Woo DK, Green PD, Santos JH, et al (2012). Mitochondrial genome instability and ROS enhance intestinal tumorigenesis in APC (Min/+) mice. *Am J Pathol*, **180**, 24-31.
- Feig DI, Reid TM, Loeb LA (1994). Reactive oxygen species in

- tumorigenesis. *Cancer Res*, **54**, 1890-4.
- Golstein P, Kroemer G (2007). Cell death by necrosis: Towards a molecular definition. *Trends Biochem Sci*, **32**, 37-43.
- Guyton KZ, Kensler TW (1993). Oxidative mechanisms in carcinogenesis. *Brit Med Bull*, **49**, 523-44.
- Green DR, Reed JC (1998) Mitochondria and apoptosis. *Sci*, **281**, 1309-12.
- Saffran HA, Pare JM, Corcoran JA, Weller SK, Smiley JR (2006). Herpes simplex virus eliminates host mitochondrial DNA. *EMBO Rep*, **8**, 188-93.
- Helge Gad, Tobias Koolmeister, Ann-Sofie Jemth, et al (2014). MTH1 inhibition eradicates cancer by preventing sanitation of the dNTP pool. *Nature*, **508**, 215-21.
- Saffran HA, Pare JM, Corcoran JA, Weller SK, Smiley JR (2006). Herpes simplex virus eliminates host mitochondrial DNA. *EMBO Rep*, **8**, 188-93.
- Kosuke Kajitani, Hiroo Yamaguchi, Yukihiro Dan (2006). MTH1, an oxidized purine nucleoside triphosphatase, suppresses the accumulation of oxidative damage of nucleic acids in the hippocampal microglia during kainate-induced excitotoxicity. *J Neurosci*, **26**, 1688-98.
- Huber KV, Salah E, Radic B, et al (2014). Stereospecific targeting of MTH1 by (S)-crizotinib as an anticancer strategy. *Nature* **508**, 222-7.
- Kennedy CH, Pass HI, Mitchell JB (2003). Expression of human MutT homologue (hMTH1) protein in primary non-small-cell lung carcinomas and histologically normal surrounding tissue. *Free Radic Biol Med*, **34**, 1447-57.
- Koketsu S1, Watanabe T, Nagawa H (2004). Expression of DNA repair protein: MYH, NTH1 and MTH1 in colorectal cancer. *HepatoGastroenterol*, **51**, 638-42.
- Clay Montier LL, Deng JJ, Bai Y (2009). Number matters: control of mammalian mitochondrial DNA copy number. *J Genet Genomics*, **36**, 125-31.
- Levine B and Kroemer G (2008). Autophagy in the pathogenesis of disease. *Cell*, **132**, 27-42.
- Maki H, Sekiguchi M (1992). MutT protein specifically hydrolyses a potent mutagenic substrate for DNA synthesis. *Nature*, **355**, 273-5.
- Nakabeppu Y, Tsuchimoto D, Furuichi M, Sakumi K (2004). The defense mechanisms in mammalian cells against oxidative damage in nucleic acids and their involvement in the suppression of mutagenesis and cell death. *Free Radic Res*, **38**, 423-9.
- Yadav N, Chandra D (2013). Mitochondrial DNA mutations and breast tumorigenesis. *Biochim Biophys Acta*, **1836**, 336-44.
- Okamoto K, Toyokuni S, Kim WJ (1996). Overexpression of human MutT homologue gene messenger RNA renal cell carcinoma: evidence of persistent oxidative stress in cancer. *Int J Cancer*, **65**, 437-41.
- Orrenius S, Gogvadze V, and Zhivotovsky B (2007). Mitochondrial oxidative stress: Implications for cell death. *Annu Rev Pharmacol Toxicol*, **47**, 143-83.
- Shimura-Miura H, Hattori N, Kang D, et al (1999). Increased 8-oxo-dGTPase in the mitochondria of substantia nigral neurons in Parkinson's disease. *Ann Neurol*, **46**, 920-4.
- Song XN, Zhang LQ, Liu DG, et al (2011). Oxidative damage to RNA and expression patterns of MTH1 in the hippocampi of senescence-accelerated SAMP8 mice and Alzheimer's disease patients. *Neurochem Res*, **36**, 1558-65.
- Shibutani S, Takeshita M, Grollman AP (1991). Insertion of specific bases during DNA synthesis past the oxidation-damaged base 8-oxodG. *Nature*, **349**, 431-4.
- Zhu W, Qin W, Bradley P, et al (2005). Mitochondrial DNA mutations in breast cancer tissue and in matched nipple aspirate fluid. *Carcinogenesis*, **26**, 145-52.
- Zheng JD, Hei AL, Zuo PP, et al (2009). Age-related alterations in the expression of MTH2 in the hippocampus of the SAMP8 mouse with learning and memory deterioration. *J Neurol Sci*, **287**, 188-96.