

RESEARCH ARTICLE

Diagnostic Performance of Diffusion - Weighted Imaging for Multiple Hilar and Mediastinal Lymph Nodes with FDG Accumulation

Katsuo Usuda^{1*}, Sumiko Maeda¹, Nozomu Motono¹, Masakatsu Ueno¹, Makoto Tanaka¹, Yuichiro Machida¹, Munetaka Matoba², Naoto Watanabe², Hisao Tonami², Yoshimichi Ueda³, Motoyasu Sagawa¹

Abstract

Background: It is sometimes difficult to assess patients who have multiple hilar and mediastinal lymph nodes (MHMLN) with FDG accumulation in PET-CT. Since it is uncertain whether diffusion-weighted magnetic resonance imaging (DWI) is useful in the assessment of such patients, its diagnostic performance was assessed. **Materials and Methods:** Twenty-three patients who had three or more stations of hilar and mediastinal lymph nodes with SUVmax of 3 or more in PET-CT were included in this study. **Results:** For diagnosis of disease, there were 20 malignancies (lung cancers 17, malignant lymphomas 2 and metastatic lung tumor 1), and 3 benign cases (sarcoidosis 2 and benign disease 1). For diagnosis of lymph nodes, there were 7 malignancies (metastasis of lung cancer 7 and malignant lymphoma 1) and 16 benign lymphadenopathies (pneumoconiosis/silicosis 7, sarcoidosis 4, benign disease 4, and atypical lymphocyte infiltration 1). The ADC value ($1.57 \pm 0.29 \times 10^{-3} \text{mm}^2/\text{sec}$) of malignant MHMLN was significantly lower than that ($1.99 \pm 0.24 \times 10^{-3} \text{mm}^2/\text{sec}$) of benign MHMLN ($P=0.0437$). However, the SUVmax was not significantly higher (10.0 ± 7.34 as compared to 6.38 ± 4.31) ($P=0.15$). The sensitivity (86%) by PET-CT was not significantly higher than that (71%) by DWI for malignant MHMLN ($P=1.0$). The specificity (100%) by DWI was significantly higher than that (31%) for benign MHMLN ($P=0.0098$). Furthermore, the accuracy (91%) with DWI was significantly higher than that (48%) with PET-CT for MHMLN ($P=0.0129$). **Conclusions:** Evaluation by DWI for patients with MHMLN with FDG accumulation is useful for distinguishing benign from malignant conditions.

Keywords: Diffusion-weighted imaging - magnetic resonance imaging - PET - lymph nodes

Asian Pac J Cancer Prev, 16 (15), 6401-6406

Introduction

Accurate staging of mediastinal and hilar lymph nodes is a critical factor in determining operability of patients with non-small cell lung cancer (NSCLC). Although several noninvasive procedures including computed tomography (CT) and positron emission tomography (PET) are widely used for diagnosing pulmonary nodules and nodal involvement, mediastinal node staging with 18-fluoro-2-deoxy-glucose (FDG)-PET/CT in coal workers is insufficient due to the high false-positive rates as a result of the presence of pneumoconiosis (Saydam et al., 2012). We have difficulty with assessing multiple hilar and mediastinal lymph nodes (MHMLN) with FDG accumulation in PET-CT.

Recently diffusion-weighted magnetic resonance imaging (DWI) has been used to detect the restricted diffusion of water molecules. The principals of DWI exploit the random motion, or so-called Brownian

movement, of water molecules in biologic tissue (Le Bihan et al., 1988). The primary application of DWI has been in brain imaging, mainly for the evaluation of acute ischemic stroke, intracranial tumors and demyelinating diseases (Tien et al., 1994; Sorensen et al., 1996; Schaefer et al., 2000). DWI makes it possible to detect malignant tumors based on the difference in the diffusion of water molecules among tissues. Diffusion of water molecules in malignant tumors is usually restricted compared to that in normal tissue, resulting in a decreased apparent diffusion coefficient (ADC) value (Szafer et al., 1995; Nasu et al., 2004; Takahara et al., 2004). In DWI, blood flow showing high diffusion and normal tissue with fat depression are likely to be undetectable, but cancer tissue with low Brownian motion of water molecules shows the restricted diffusion of water molecules, and it is likely to be detectable. In terms of the diagnosis of lymph nodes, MRI was reported to be helpful in distinguishing between progressive massive fibrosis of pneumoconiosis and lung

¹Department of Thoracic Surgery, ²Department of Radiology, and ³Department of Pathophysiological and Experimental Pathology, Kanazawa Medical University, Ishikawa, Japan *For correspondence: usuda@kanazawa-med.ac.jp

cancer (Chong et al., 2006). DWI has advantages over PET-CT in diagnosing malignant from benign lymph nodes of lung cancers (Usuda et al., 2013). Although another report showed that the etiology of 100 PET-CT positive lymph node stations were metastasis in 14, anthracosis in 40, reactive in 39, granulomatous in 4, and silicosis in 3 patients (Koksal et al., 2013), it is uncertain whether DWI is useful in the assessment of patients who had MHMLN with FDG accumulation in PET-CT. If DWI is shown to have higher diagnostic efficacy than that by PET-CT for MHMLN with FDG accumulation, DWI may become a more useful examination tool in the assessment of MHMLN with FDG accumulation. The purpose of this prospective clinical study was to compare DWI and PET-CT in assessing MHMLN with FDG accumulation.

Materials and Methods

Eligibility

The study protocol for examining DWI and PET-CT in patients with thoracic diseases was approved by the Institutional Review Board in Kanazawa Medical University (the approval number: No.189). Patients who had metal or pacemakers in their body or tattoos on their skin were excluded because of contraindication in MRI examinations. Written informed consent to participate in this study was obtained from all patients after discussing the risks and benefits of the study with their surgeons.

Patients

The clinical study started in January 2010. All patients who had three or more stations of MHMLN with SUVmax of 3 or more in PET-CT were included in the study. They underwent MRI including DWI within two weeks of PET-CT. Most MHMLN were pathologically diagnosed by resection, or by biopsy under CT or VATS, and the others were judged as benign or malignant by radiological follow-up study.

Positron emission tomography - computed tomography (PET-CT)

PET-CT scanning was performed with a dedicated PET camera (Biograph Sensation 16; Siemens Erlangen Germany) before surgery. All patients fasted for 6 hours before scanning. The dose of 18F-FDG administered was 3.7MBq/Kg of body weight. After a 60- min uptake period, an emission scan was acquired for 3 min per bed position and a whole-body scan (from head to pelvis) was performed. After image reconstruction, a 2-dimensional (2D) round region of interest (ROI) was drawn on a slice after visual detection of the highest count on the fused CT image by the radiologist (N.W.) with 30 years of radioisotope scintigraphy and PET-CT experience who was unaware of the patients' clinical data. For the lesions with negative or faintly positive PET findings, the ROI was drawn on the fusion image with the corresponding CT. From those ROI, the maximum standardized uptake value (SUVmax) was calculated. The radiologist (N.W.) and one pulmonologist (K.U.) with 29 years of experience evaluated the FDG-PET data. A consensus was reached if there were any differences of opinion. The optimal cutoff

value (OCV) of SUVmax for diagnosing malignancy in FDG-PET was determined to be 4.45 using receiver operating characteristics curve as previously reported (Usuda et al., 2013). Hilar and mediastinal lymph nodes with SUVmax of the same or more than the OCV was defined as positive. Hilar and mediastinal lymph nodes with SUVmax less than the OCV, or those that could not be detected on FDG-PET were defined as negative.

Magnetic resonance imaging (MRI)

All MR images were obtained with a 1.5 T superconducting magnetic scanner (Magnetom Avanto; Siemens, Erlangen, Germany) with two anterior six-channel body phased-array coils and two posterior spinal clusters (six-channels each). The conventional MR images consisted of a coronal T1-weighted spin-echo sequence and coronal and axial T2-weighted fast spin-echo sequences. DWIs using a single-shot echo-planar technique were performed with slice thickness of 6mm under SPAIR (spectral attenuated inversion recovery) with respiratory triggered scan with the following parameter: TR/TE/flip angle, 3000-4500/65/90; diffusion gradient encoding in three orthogonal directions; b value = 0 and 800 s/mm²; field of view, 350 mm; matrix size, 128x128. After image reconstruction, a 2-dimensional (2D) round or elliptical region of interest (ROI) was drawn on the lesion which was detected visually on the ADC map with reference to T2-weighted or CT image by the radiologist (H.T.) with 39 years of MRI experience who was unaware of the patients' clinical data. Areas with necrosis were excluded from the ADC measurement. The procedure was repeated three times and the minimum ADC value was obtained. The radiologist (H.T.) and one pulmonologist (K.U.) with 29 years of experience evaluated the MRI data. A consensus was reached if there were any differences of opinion. The OCV of ADC for diagnosing malignancy in DWI was determined to be $1.70 \times 10^{-3} \text{mm}^2/\text{sec}$ using receiver operating characteristics curve as previously reported (Usuda et al., 2013). Hilar and mediastinal lymph nodes with ADC value of the same or less than the OCV was defined as positive. Hilar and mediastinal lymph nodes with ADC value of more than the OCV or those that could not be detected on DWI were defined as negative.

Statistical analysis

Statistical analysis was performed using StatView for Windows (Version 5.0; SAS Institute Inc. Cary, NC, USA). The data are expressed as the mean \pm standard deviation. A two-tailed Student t test was used for comparison of ADC values or SUVmax in several pathological factors. The sensitivity, specificity, and accuracy of DWI versus PET-CT for mediastinal tumor were compared by using McNemar test. A P value of <0.05 was considered statistically significant.

Results

From January 2010 to December 2014, 23 patients who had three or more stations of hilar and mediastinal lymph nodes with SUVmax of 3 or more in PET-CT were enrolled in this study. Four MHMLN were judged

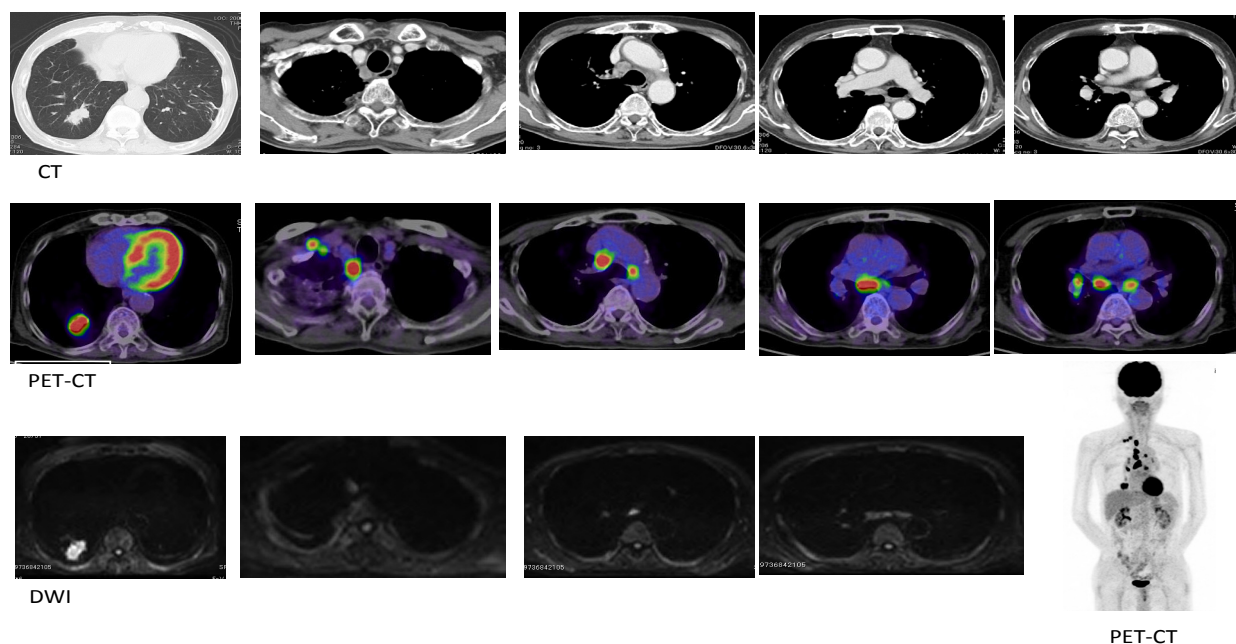


Figure 1. 79 y.o. Male with Pulmonary Adenocarcinoma and Ipsilateral and Contralateral Pathological Nodal Involvement. Metastatic lymph nodes were diagnosed correctly by PET-CT and DWI

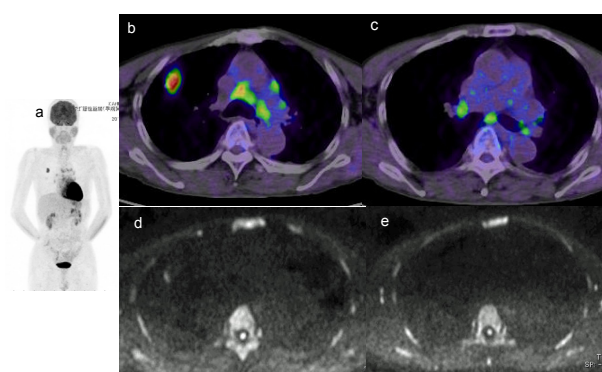


Figure 2. 66 y.o. Male with Pulmonary Squamous Cell Carcinoma, but Without Lymph Node Metastasis. The patient was diagnosed as n2 disease by PET-CT, but n0 disease by DWI. DWI showed lymph node station #4R as negative (d), and lymph node station #7 as negative (e). The lymph nodes were diagnosed as pneumoconiosis pathologically

Table 1. Diagnosis and Number of Patients with MHMLN with SUVmax of 3 or more

Diagnosis	No. of patients	Diagnosis of lymph nodes	No. of patients
Lung cancer	17	Pneumoconiosis / silicosis	7
Sarcoidosis	2	Metastasis of lung cancer	6
Malignant lymphoma	2	Sarcoidosis	4
Metastatic lung tumor	1	Benign disease	4
Benign disease	1	Malignant lymphoma	1
		Atypical lymphocyte filtration	1

as benign diseases by radiological follow-up study. For diagnosis of disease, there were 20 malignancies (lung cancer 17, malignant lymphoma 2 and metastatic lung tumor 1), and 3 benign diseases (sarcoidosis 2 and benign disease 1) (Table 1). For diagnosis of lymph nodes, there were 7 malignancies (metastasis of lung cancer 6 and malignant lymphoma 1), 16 benign lymphadenopathies

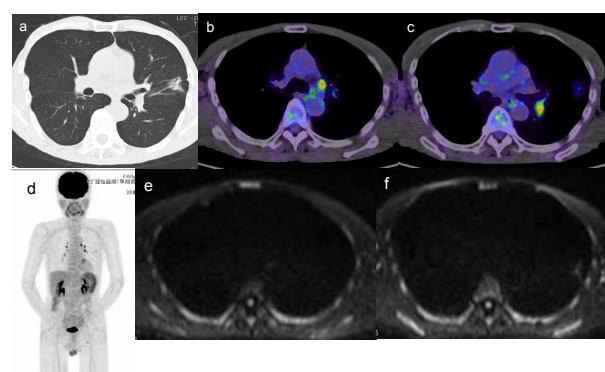


Figure 3. 74 y.o. Male with Pulmonary Adenocarcinoma, but Without Lymph node Metastasis. The patient was diagnosed correctly by DWI, not by PET-CT. The patient was diagnosed as n2 disease by PET-CT, but n0 disease by DWI. Lymph node station #4L was diagnosed positive by PET-CT (b), but negative by DWI (e). Lymph node station #11 was diagnosed positive by PET-CT (c), but negative by DWI (f). The lymph node stations were diagnosed as sarcoidosis pathologically

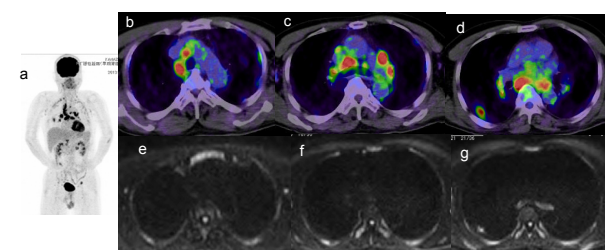


Figure 4. 64 y.o. Male with Pulmonary Adenocarcinoma, but without Lymph Node Metastasis. Lymph nodes without metastasis were diagnosed correctly by DWI, not by PET-CT. The patient was diagnosed as n3 disease by PET-CT, but n0 disease by DWI. DWI showed lymph node station #2R as negative (e), lymph node stations #4R/#6 as negative (f) and lymph node stations #7/#10 as negative (g) (ADC 2.036 $\times 10^{-3} \text{ mm}^2/\text{sec}$) by DWI. The lymph nodes were diagnosed as pneumoconiosis pathologically

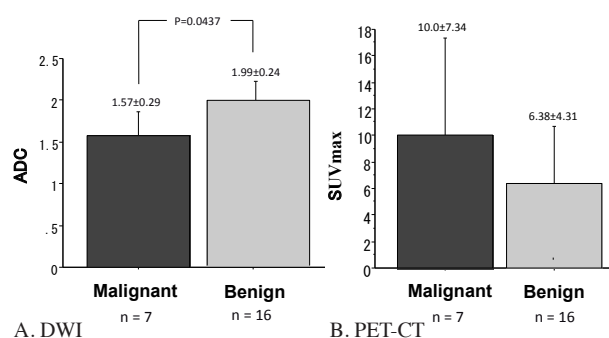


Figure 5. Differences in ADC Values and Differences in SUVmax between Malignant and Benign Hilar and Mediastinal Lymph Nodes. (A) The ADC value ($1.57 \pm 0.29 \times 10^{-3} \text{mm}^2/\text{sec}$) of malignant lymph nodes was significantly lower than that ($1.99 \pm 0.24 \times 10^{-3} \text{mm}^2/\text{sec}$) of benign lymph nodes ($P=0.0437$). (B) The SUVmax (10.0 ± 7.34) of malignant lymph nodes was not significantly higher than that (6.38 ± 4.31) of benign lymph nodes ($P=0.15$)

Table 2. Diagnostic Ability by PET-CT for 23 Patients with MHMLN with SUVmax of 3 or More

	Diagnostic ability				No of patients
	TP	FN	TN	FP	
Pathological or final diagnosis of lymph nodes					
Metastasis of lung cancer	5	1	0	0	6
Malignant lymphoma	1	0	0	0	1
Atypical lymphocyte filtration	0	0	0	1	1
Sarcoidosis	0	0	0	4	4
Pneumoconiois / silicosis	0	0	2	5	7
Benign lesion	0	0	3	1	4
Total	6	1	5	11	23

*TP = true-positive, FN = false-negative, TN = true-negative, FP = false-positive

(pneumoconiosis/silicosis 7, sarcoidosis 4, benign disease 4 and atypical lymphocyte infiltration 1) (Table 1).

Diagnostic imaging between PET-CT and DWI with MHMLN with SUVmax of 3 or more in PET-CT are shown in Figure 1-4. The ADC value ($1.57 \pm 0.29 \times 10^{-3} \text{mm}^2/\text{sec}$) of malignant MHMLN was significantly lower than that ($1.99 \pm 0.24 \times 10^{-3} \text{mm}^2/\text{sec}$) of benign MHMLN ($P=0.0437$) (v 5A). The SUVmax (10.0 ± 7.34) of malignant MHMLN was not significantly higher than that (6.38 ± 4.31) of benign MHMLN ($P=0.15$) (Figure 5B).

Diagnostic ability by PET-CT for MHMLN with SUVmax of 3 or more are presented in Table 2. The sensitivity by PET-CT was 86% (6/7), the specificity by PET-CT was 31% (5/16) and the accuracy by PET-CT was 48% (11/23). Diagnostic ability by DWI for MHMLN with SUVmax of 3 or more are presented in Table 3. The sensitivity by DWI was 71% (5/7), the specificity by DWI was 100% (16/16) and the accuracy by DWI was 91% (21/23).

Concerning sensitivities between DWI and PET-CT for 7 patients with malignant MHMLN with SUVmax of 3 or more, 4 (57%) were true-positive (TP) with DWI and PET-CT, 2 (29%) were TP with PET-CT but false-negative (FN) with DWI and 1 (14%) were TP with DWI but FN with PET-CT. The sensitivity (86%) by PET-CT

Table 3. Diagnostic Ability by DWI for 23 Patients with MHMLN with SUVmax of 3 or More

	Diagnostic ability				No of patients
	TP	FN	TN	FP	
Pathological or final diagnosis of lymph nodes					
Metastasis of lung cancer	4	2	0	0	6
Malignant lymphoma	1	0	0	0	1
Atypical lymphocyte filtration	0	0	1	0	1
Sarcoidosis	0	0	4	0	4
Pneumoconiois / silicosis	0	0	7	0	7
Benign lesion	0	0	4	0	4
Total	5	2	16	0	23

*TP = true-positive, FN = false-negative, TN = true-negative, FP = false-positive

Table 4. Comparison of Sensitivities between DWI and PET-CT for 7 Patients with Malignant MHMLN with SUVmax of 3 or more in the McNemar Test

	PET-CT	
	True-positive	False-negative
DWI		
True-positive	4	1
False-negative	2	0
Total	6	1

P=1.0

Table 5. Comparison of Specificities between DWI and PET-CT for 16 Patients with Benign MHMLN with SUVmax of 3 or more in the McNemar Test

	PET-CT	
	True-negative	False-positive
DWI		
True-negative	5	11
False-positive	0	0
Total	5	11

P=0.0098

Table 6. Comparison of Accuracies between DWI and PET-CT for 23 Patients with MHMLN with SUVmax of 3 or more in the McNemar Test

	PET-CT	
	Correct	Incorrect
DWI		
Correct	9	12
Incorrect	2	0
Total	11	12

P=0.0129

was not significantly higher than that (71%) by DWI for 7 patients with MHMLN with SUVmax of 3 or more in the McNemar test ($P=1.0$) (Table 4).

Concerning specificities between DWI and PET-CT for 16 patients with benign MHMLN with SUVmax of 3 or more, 5 (31%) were TN with DWI and PET-CT, 11 (69%) were TN with DWI but FP with PET-CT (Table 5). The specificity (100%) by DWI was significantly higher than that (31%) for 16 patients with benign MHMLN with

SUVmax of 3 or more in the McNemar test ($P=0.0098$).

Concerning accuracies between DWI and PET-CT for all 23 patients with MHMLN with SUVmax of 3 or more, 9 (39%) were correct with DWI and PET-CT, 12 (52%) were correct with DWI but incorrect with PET-CT, 2 (9%) were correct with PET-CT but incorrect with DWI (Table 6). The accuracy (91%) by DWI was significantly higher than that (48%) by PET-CT for all 23 patients with MHMLN with SUVmax of 3 or more in the McNemar test ($P=0.0129$).

Discussion

Although PET-CT is widely accepted as the imaging modality of choice in tumor staging, false positive results of hilar and mediastinal lymph nodes by PET-CT were reported to be due to pneumoconiosis, silicosis, pulmonary tuberculosis, and sarcoidosis (Jain et al., 2011; Lin et al., 2012; Usuda et al., 2013; Maturu et al., 2014). In PET-CT, care should be taken in lymph node staging for patients who have other pulmonary complications, including interstitial pneumonitis, previous pulmonary tuberculosis and silicosis (Konishi et al., 2003). For early stage lung cancer, the false positive rates by PET-CT scan in N1 and N2 nodes were reported to be 70% and 78%, respectively, primarily due to inflammatory process (anthracosis as the leading cause) (Lin et al., 2012). Silicotic lesions of hilar and mediastinal lymph nodes were reported to have moderate accumulation of FDG in PET-CT, and were likely to be judged as false-positive (Usuda et al., 2013). PET had some limitations for evaluating sarcoidosis (Jain et al., 2011). The SUVmax of sarcoidosis were usually high: 12.4 (early), and 16.2 (delayed) (Maturu et al., 2014). PET gives false-negative results for well-differentiated pulmonary adenocarcinoma (Higashi et al., 1998; Cheran et al., 2004; Usuda et al., 2014), and false-positive results for inflammatory nodules (Goo et al., 2000; Nomori et al., 2004).

Recently, there have been advancements in MR gradient technology. In this study, specificity and accuracy by DWI for MHMLN with SUVmax of 3 or more were shown to be significantly higher than that by PET-CT. In cervical lymph nodes, the mean ADC value of malignant nodes was significantly lower than that of benign nodes (Abdel et al., 2006; Perrone et al., 2011). DWI was reported to be a new promising technique for differentiating inflammatory from metastatic lymph nodes on animal model (Xue et al., 2008). Some reports indicate the superiority of DWI in comparison with PET-CT. First, DWI was reported to be superior to PET-CT in detection of primary lesions and nodal assessment of non-small cell lung cancers (Usuda et al., 2011). DWI with ADC value and signal intensity can be useful in the differentiation of malignant and benign mediastinal lymph nodes (Kosucu et al., 2009). Nomori et al., 2008 reported that the accuracy of N staging in the 88 patients was 0.89 with DWI, which was significantly higher than the value of 0.78 obtained with PET-CT, because of less overstaging in the former. The superiority of DWI can be explained not only by DWI giving fewer false-positive results for N staging of non-small cell lung cancer compared with PET-CT

(Nomori et al., 2008), but DWI also gave fewer false-negative results for N staging of non-small cell lung cancer compared with PET-CT (Usuda et al., 2011). PET-CT is likely to show false-positive results when lymph nodes contain inflammation, and is likely to show false-negative results when the lymph nodes contain a small amount of cancer cells. Second, DWI has easier accessibility, and is relatively cheaper compared with PET-CT. The number of hospitals equipped with PET-CT is limited because of the difficulty in handling the radioisotope of ^{18}F -FDG, but MRI with DWI is usually available in hospitals nowadays. In addition, an MRI examination carries no risk of radiation exposure, whereas a PET-CT examination carries some risk of radiation exposure. In a DWI examination patients do not have to fast before the examination, do not need exogenous contrast medium, and less time is required for the examination.

There are limitations of DWI. The evaluation of several areas such as brain, spinal cord, spleen, kidney, and bone marrow may not be useful using DWI because an impeded diffusion can also be seen in these normal structures (Kwee et al., 2010). Furthermore, in interpretation of DWI, it should be kept in mind that a number of benign lesions can exhibit restricted diffusion on images, thus mimicking malignant lesions (Humphries et al., 2007; Feuerlein et al., 2009). Abscesses and thrombi are believed to impede the diffusivity of water molecules because of their hyperviscous nature (Desprechins et al., 1999; Kwee et al., 2010).

DWI is shown to have higher diagnostic efficacy than that by PET-CT for MHMLN with FDG accumulation, and DWI may become a more useful examination tool in the assessment of MHMLN with FDG accumulation. DWI is a new imaging modality, adding diagnostic performance to PET-CT.

Acknowledgements

This study was supported by a Grant-in-Aid for Scientific Research from the Ministry of Education, Culture, Sports, Science and Technology, Japan (25462186). We are grateful to Mr. Masaru Takahashi and Mr. Keiya Hirata of the MRI Center, Kanazawa Medical University hospital, for technical assistance.

References

- Abdel Razek AA, Soliman NY, Elkhamary S, Alsharaway MK, Tawfik A (2006). Role of diffusion-weighted MR imaging in cervical lymphadenopathy. *Eur Radiol*, **16**, 1468-77.
- Cheran SK, Nielsen ND, Patz EF (2004). False-negative findings for primary lung tumors on FDG positron emission tomography. Staging and prognostic implications. *AJR*, **182**, 1129-32.
- Chong S, Lee KS, Chung MJ, et al (2006). Pneumoconiosis. Comparison of imaging and pathologic findings. *Radiographics*, **26**, 59-77.
- Desprechins B, Stadnik T, Koerts G, et al (1999). Use of diffusion-weighted MR imaging in differential diagnosis between intracerebral necrotic tumors and cerebral abscesses. *Am J Neuroradiol*, **20**, 1252-7.
- Feuerlein S, Pauls S, Juchems MS, et al (2009). Pitfalls in

- abdominal diffusion-weighted imaging. How predictive is restricted water diffusion for malignancy. *AJR*, **193**, 1070-6.
- Goo JM, Im JG, Do KH, et al (2000). Pulmonary tuberculoma evaluated by means of FDG PET. Findings in 10 cases. *Radiol*, **216**, 117-21.
- Higashi K, Ueda Y, Seki H, et al (1998). Fluorine-18-FDG PET imaging is negative in bronchioloalveolar lung carcinoma. *J Nucl Med*, **39**, 1016-20.
- Humphries PD, Sebire NJ, Sieel MJ, Olsen OE. (2007) Tumors in pediatric patients at diffusion-weighted MR imaging. Apparent diffusion coefficient and tumor cellularity. *Radiol*, **245**, 848-54.
- Jain V, Hasselquist S, Delaney MD (2011). PET scanning in sarcoidosis. *Ann N Y Acad Sci*, **1228**, 46-58.
- Koksal D, Demirag F, Bayiz H, et al (2013). The correlation of SUVmax with pathological characteristics of primary tumor and the value of tumor/ lymph node SUVmax ratio for predicting metastasis to lymph nodes in resected NSCLC patients. *J Cardiothorac Surg*, **8**, 63.
- Konishi J, Yamazaki K, Tsukamoto E, et al (2003). Mediastinal lymph node staging by FDG-PET in patients with non-small cell lung cancer: analysis of false-positive FDG-PET findings. *Respirat*, **70**, 500-6.
- Kosucu P, Tekinbas C, Erol M, et al (2009). Mediastinal lymph nodes. assessment with diffusion-weighted MR imaging. *J Magn Reson Imaging*, **30**, 292-7.
- Kwee TC, Takahara T, Ochiai R, et al (2010). Complementary roles of whole-body diffusion-weighted MRI and 18F-FDG PET. The state of the art and potential application. *J Nucl Med*, **51**, 1549-58.
- Le Bihan D, Breton E, Lallemand D, et al (1988). Separation of diffusion and perfusion in intravoxel incoherent motion MR imaging. *Radiol*, **168**, 497-505.
- Lin WY, Hsu WH, Lin KH, Wang SJ (2012). Role of preoperative PET-CT in assessing mediastinal and hilar lymph node status in early stage lung cancer. *J Chin Med Assoc*, **75**, 203-8.
- Maturu VN, Agarwal R, Aggarwal AN, et al (2014). Dual-time point whole-body 18F-fluorodeoxyglucose PET/CT imaging in undiagnosed mediastinal lymphadenopathy: a prospective study of 117 patients with sarcoidosis and TB. *Chest*, **146**, 216-20.
- Nasu K, Kuroki Y, Kuroki S, et al (2004). Diffusion-weighted single shot echo planar imaging of colorectal cancer using a sensitivity-encoding technique. *Jpn J Clin Oncol*, **34**, 620-6.
- Nomori H, Mori T, Ikeda K, et al (2008). Diffusion-weighted magnetic resonance imaging can be used in place of positron emission tomography for N staging of non-small cell lung cancer with fewer false-positive results. *J Thoracic Cardiovasc Surg*, **135**, 816-22.
- Nomori H, Watanabe K, Ohtsuka T, et al (2004). Evaluation of F-18 fluorodeoxyglucose (FDG) PET scanning for pulmonary nodules less than 3cm in diameter, with special reference to the CT images. *Lung cancer*, **45**, 19-27.
- Perrone A, Guerrisi P, Izzo L, et al (2011). Diffusion-weighted MRI in cervical lymph nodes: differentiation between benign and malignant lesions. *Eur J Radiol*, **77**, 281-6.
- Saydam O, Gokce M, Kilicun A, Tanriverdi O (2012). Accuracy of positron emission tomography in mediastinal node assessment in coal workers with lung cancer. *Med Oncol*, **29**, 589-94.
- Schaefer PW, Grant PE, Gonzalez RG (2000). Diffusion-weighted MR imaging of the brain. *Radiol*, **217**, 331-45.
- Sorensen AG, Buonanno FS, Gonzalez RG, et al (1996). Hyperacute stroke. Evaluation with combined multisection diffusion-weighted and hemodynamically weighted echoplanar MR imaging. *Radiol*, **199**, 391-401.
- Szafer A, Zhong J, Gore JC (1995). Theoretical model for water diffusion in tissues. *Magn Reson Med*, **33**, 697-712.
- Takahara T, Imai Y, Yamashita T, et al (2004). Diffusion weighted whole body imaging with background body signal suppression (DWIBS). Technical improvement using free breathing, STIR and high resolution 3D display. *Radiat Med*, **22**, 275-82.
- Tien RD, Felsberg GJ, Friedman H, Brown M, MacFall J (1994). MR imaging of high-grade cerebral gliomas. Value of diffusion-weighted echoplanar pulse sequences. *AJR*, **162**, 671-7.
- Usuda K, Sagawa M, Motono N, et al (2013). Advantages of diffusion-weighted imaging over positron emission tomography-computed tomography in assessment of hilar and mediastinal lymph node in lung cancer. *Ann Surg Oncol*, **20**, 1676-83.
- Usuda K, Sagawa M, Motono N, et al (2014). Diagnostic performance of diffusion weighted imaging of malignant and benign pulmonary nodules and masses. Comparison with positron emission tomography. *Asian Pac J Cancer Prev*, **15**, 4629-35.
- Usuda K, Zhao XT, Sagawa M, et al (2011). Diffusion-weighted imaging is superior to PET in the detection and nodal assessment of lung cancers. *Ann Thorac Surg*, **91**, 1689-95.
- Xue HD, Li S, Sun HY, Jin ZY, Sun F (2008). Experimental study of inflammatory and metastatic lymph nodes with diffusion weighted imaging on animal model: comparison with conventional methods. *Chin Med Sci J*, **23**, 166-71.