

RESEARCH ARTICLE

Diagnostic Performance of Breast MRI in the Evaluation of Contralateral Breast in Patients with Diagnosed Breast Cancer

Shaista Afzal Saeed^{1*}, Imrana Masroor¹, Madiha Beg¹, Romana Idrees²

Abstract

Aims: The purpose of our study was to evaluate the diagnostic performance of breast magnetic resonance imaging (MRI) in the evaluation of contralateral breast in patients with diagnosed breast cancer. A secondary objective was to determine accuracy of breast MRI in diagnosing multi-focal and multicentric lesions in the ipsilateral breast. **Materials and Methods:** Using a non-probability convenience sampling technique, patients with histopathologically diagnosed breast cancer with MRI of breast performed to exclude additional lesions were included. MRI findings were correlated with histopathology. In addition, follow-up imaging with mammography and ultrasound was also assessed for establishing stability of negative findings and for the detected of benign lesions. **Results:** Out of 157 MRI breast conducted during the period of 2008 to 2013, 49 were performed for patients with diagnosed breast cancer. The sample comprised of all females with mean age 50.7 ± 11.0 years. The patient follow-up imaging was available for a period of 2-5 years. The sensitivity, specificity, and positive and negative predictive values of MRI in the detection of multifocal/multicentric lesions was 85.7%, 88.8%, 60% and 96.6% respectively and for the detection of lesions in the contralateral breast were 100%, 97%, 83.3% and 100% respectively. **Conclusions:** Our study highlights the diagnostic performance and the added value of MRI in the detection of multifocal /multicentric and contralateral malignant lesions. In patients with diagnosed breast cancer having dense breast parenchyma and with infiltrating lobular carcinoma as the index lesion MRI is particularly useful with excellent negative predictive value in the exclusion of additional malignant foci in the ipsilateral and contralateral breasts.

Keywords: MRI breast - multicentric - multifocal - bilateral breast cancer

Asian Pac J Cancer Prev, 16 (17), 7607-7612

Introduction

Breast cancer is the most commonly diagnosed cancer in women with significant cancer related mortality in the developed and developing countries (Yusuf et al., 2013)

Patients with unilateral breast cancer have an added risk of cancer in the contra lateral breast with prevalence of 1-4% (Jobsen et al., 2003). These patients have a higher rate of distant metastasis and unfavorable disease specific survival as compared to those with unilateral breast tumour (Heron et al., 2000). It is important to diagnose contra lateral breast cancer at the time of initial diagnosis as the actuarial survival rates at 5 years is lower for patients with bilateral synchronous breast cancer (64.4%) as compared to patients with unilateral disease (75.8%). (Polednak et al., 2003). Screening mammography has resulted in early diagnosis of breast cancer which has led to more conservative surgical approach. Since undetected malignant foci frequently results in relapses after breast conservative surgery as reported in 3-19% of patients, (Goethem et al., 2004) this surgical option should be utilized after the exclusion of undetected multifocal /multicentric disease in addition to any contralateral synchronous cancer (Esserman et

al., 1999). The sensitivity of screening mammography is reduced in women with heterogeneously dense /dense breast parenchyma but whole breast ultrasounds is useful in the detection of mammographically and clinically occult ipsilateral and contra lateral breast cancer (Moon, 2002; Beysebayev, 2014) with reasonably accurate estimation of invasive cancer but often underestimates the component of ductal carcinoma in situ. (DCIS) (Satake et al., 2000).

Breast Magnetic resonance imaging (MRI) has emerged as an important adjunctive tool and multiple studies have shown increased detection of tumor foci not identified on mammography or ultrasound. Multiple diagnostic and screening indications for MRI breast have been discussed and suggested by American college of radiology (ACR 2013) An additional occult cancer in contralateral breast detected on MRI ranges from 3-24% and this subsequently alters the management plan (Lieberman, 2003; Kowalchik, 2012).

The purpose of our study was to evaluate the diagnostic performance of breast MRI in the evaluation of contra lateral breast in patients with diagnosed breast cancer.

The secondary objective was to evaluate accuracy of breast MRI in diagnosing multi focal and multicentric lesions in the ipsilateral breast.

¹Radiology, ²Pathology and Laboratory Medicine, Aga Khan University Hospital, Karachi, Pakistan *For correspondence: shaista.afzal@aku.edu

Materials and Methods

This cross sectional analytical study was conducted in the Radiology department AKUH after obtaining exemption (2862-Rad-ERC-13) from the hospital ethical review committee.

All MRI breast done during the period of January 2008 to December 2013 were included. Using non-probability convenience sampling technique, all of the patents with histopathologically diagnosed breast cancer and with MRI of breast done to exclude additional lesions were included. These patients had no clinical, mammographic or breast ultrasound evidence of occult additional breast lesions. Patients were excluded if the MRI breast was done for other indications like for assessment of BIRADS 3 lesions, implant evaluations, screening, neoadjuvant response evaluation, differentiation of scar versus recurrence. Patients were also excluded if no follow-up imaging was available.

Patient's mammography and ultrasound done at the time of breast cancer diagnosis were also assessed. The index lesion was defined as the first lesion detected by patient as palpable lump or first detected at imaging or the lesion assigned as highest BIRADS category when more than one lesions were detected at initial workup. (Kim et al., 2014). The MRI findings were correlated with histopathology. In addition follow-up imaging i.e. mammography and ultrasound were also assessed for establishing stability of negative findings and for the detected benign lesions. For the purpose of reporting and data analysis, the multi focal and multicentric cancers were taken as one group, For the study breast cancer on contralateral side was defined as cancer diagnosed in both breast concurrently or within a period of three months of diagnosis of the first lesion (Jobsen et al., 2003).

Statistical analysis plan

Data was entered and analyzed in SPSS 20.0 version. The data comprised of age of the patient, mammographic density, prior mammography and ultrasound findings, the breast involved, histopathology of index lesions and the MRI detected lesions in the ipsilateral breast i.e. multifocal/multicentric lesions and in contralateral breast. In addition development of malignancy on follow up imaging was also noted. Means and Standard deviation were computed for quantitative variable like age and proportions reported for qualitative variable. Sensitivity, specificity, positive and negative predictive values with 95% confidence interval were computed for MRI breast in the evaluation of contra lateral and ipsilateral breast in patients with diagnosed breast cancer. Diagnostic accuracy of breast MRI was also calculated.

Reported sensitivity of breast MRI for the detection of breast carcinoma is 92% (Hillman et al., 2012) with confidence interval of 95%, bound on error of 8%, the calculated sample size was N=45.

Breast MRI technique

All cases underwent a breast MRI in a 1.5 tesla unit. The conventional departmental breast MRI protocol was

carried out using breast coil with patient in prone position. The field of view was 300-340 mm and slice thickness of 4 mm.

Prior to post contrast images axial TRIM, T1 and T2 weighted images were obtained. In addition diffusion weighted images and sagittal T2 fat saturated images also obtained. This is followed by dynamic post contrast images in the axial plane. Vascular access obtained with a cannula for the administration of Gadolinium using power injector at a dose of 0.1 mmol/kg of body weight followed by 20 ml of saline flush. The dynamic image sequence was repeated six times with 30 sec interval and the images were obtained in the axial plane. The delayed post contrast image were obtained in coronal sections. Post processing included subtracted images, 2D and 3D MIP (maximum intensity projection) reconstructions, wash in and washout maps and kinetic curve analysis.

The images were interpreted by radiologist with more than 5 years' experience in breast imaging on soft copy using picture archiving and communication system (PACS) with provision of manual window setting and parameters optimization. The radiologist was provided with patient clinical history and all available imaging like mammograms and ultrasound of breast. The breast lesion was categorized using Breast imaging reporting and data system (BIRADS) MR Lexicon.

The MRI detected lesions were classified in accordance to that described in literature (Liberman et al., 2002) based on T2 signal intensity, mass or non-mass like enhancement, features of a mass like margins, shape, enhancement and kinetic curve analysis

For all MRI detected suspicious findings second look sonography was performed to determine if a correlate of the lesion is evident and to assess for feasibility of ultrasound guided biopsy. The mammograms were also reviewed to assess for presence of mammographic correlate.

Patients follow up imaging ie mammography and ultrasound were reviewed and any suspicious finding recorded.

The mastectomy/ lumpectomy specimen was grossed according to the standard criteria and representative sections were submitted, five micron sections were cut from paraffin embedded tissue blocks and were stained with hematoxylin and eosin. The microscopic findings were noted and reported by an experienced pathologist. Where the need arise, immunohistochemical stains were also performed. Reporting was done on a synoptic pattern according to the College of American pathologist (CAP) guidelines.

Results

Out of the 157 MRI breast done during the period of 2008 to 2013, 49 were performed in patients with diagnosed breast cancer. Four patients were post unilateral mastectomy (duration post-surgery being 1 to 3 months) and MRI studies were done for the evaluation of contralateral breast only.

The sample comprised of all female with mean age 50.7 +/-11.04 years. Age range was 46 years and minimum

Table 1. Diagnostic Performance of MRI Breast for Evaluation of Multifocal/Multicentric & Contralateral Lesions

Type of Lesion	Sensitivity (95% CI [§])	Specificity (95% CI [§])	* PPV (95% CI [§])	[§] NPV (95% CI [§])	Accuracy
Multifocal / Multicentric lesion	85.71% (0.42-0.99)	88.88% (0.73-0.96)	60% (0.27-0.86)	96.96% (0.82-0.99)	88.37%
Contralateral Breast	100% (0.46-1 [§])	97.73% (0.86-0.99)	83.33% (0.36-0.99)	100% (0.89-1 [§])	97.96%

[§] 95% CI: 95% confidence interval; * PPV: Positive Predictive Value; [§] NPV: Negative Predictive Value; [§]: CI insignificant as one of the cell contains a "zero value"

Table 2. Table 2 : Comparison of previous studies for assessment of multifocal / multicentric & contralateral malignant lesions by Breast MRI

Author	Publication Year	Sample Size	Multifocal	Multicentric lesions	Contralateral lesions
Liberman et al	2003	70	20%	4%	5.0%
Berg et al	2004	120	30% **		2.7%
Pediconi et al	2007	164	4.2%	2.4%	29.0%
Mameri et al	2008	99	18.0%	0.7%	3.0%
Duygulu et al	2012	68	5.8%	4.4%	1.4%
Afzal et al ~	2015	49	12% **		10.0%

** : Authors did not demarcate between multifocal and multi centric lesions; ~: Current study reports results

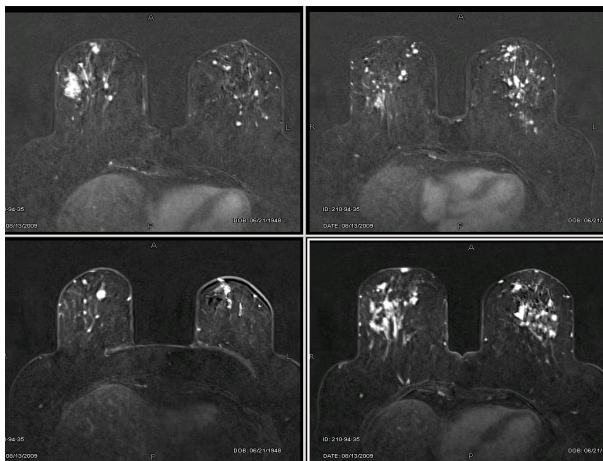


Figure 1. Dynamic Post Contrast Enhanced MRI Showing Index Lesion in Right Breast with Multiple Enhancing Foci Suggestive of Multifocal/Multicentric and Bilateral Disease. On second look ultrasound a well-defined hypo echoic lesion correlated with the right breast nodular enhancing lesion which on biopsy diagnosed as fibroadenoma. No correlate seen on second look ultrasound for the contralateral breast. No suspicious finding in left breast on follow up imaging

and maximum were 26 and 71 years respectively. The patient follow-up imaging was available for a period of 2 to 5 years.

Second look ultrasound performed to evaluate the 21 MRI detected suspicious findings in the ipsilateral (n=11) and contralateral (n=10) breast. Ultrasound correlate was identified for suspicious lesions presenting with mass like enhancement in 13 (62%). Abnormal foci of enhancement without an associated mass and measuring less than 5 mm noted in 8 cases showed no corresponding sonographic correlate and these patients on follow-up imaging were

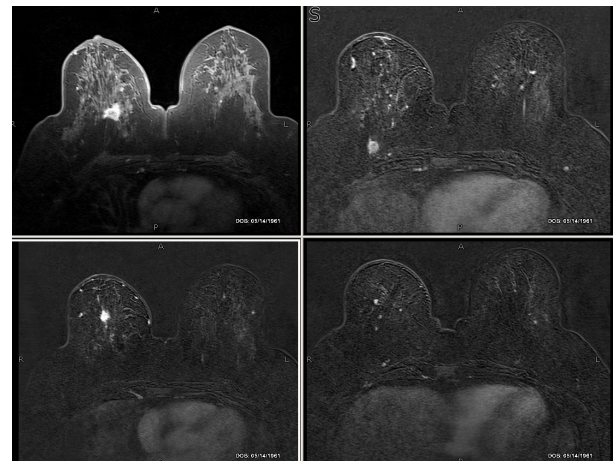


Figure 2. Right Breast Multifocal Multicentric Disease (Arrows) on Dynamic Contrast Enhanced Scan. An ultrasound correlate was detected for these lesions, which on biopsy confirmed presence of multifocality /multicentricity

stable without any interval development.

Due to the nonexistence of a national screening programme in our country the indication for initial imaging in 69% of patients was palpable breast lump, pain in 8%, and nipple discharge in 2%. In 20% of patients the reason for initial imaging was as a part of general medical checkup. The breast density on mammography was heterogeneously dense in 45%, fibro glandular in 31% and dense in 20%.The breast parenchyma was fatty on mammography in only 4%.

The size of the index lesion at the time of presentation was from 1 to 2cm in 43% (n=21) followed by 2 to 5 cm in 35 % (n=17). Less than 1cm index lesions were seen in 14%. The size of the index lesion was more than 5 cm in 8%.

The predominant histopathology of the primary /

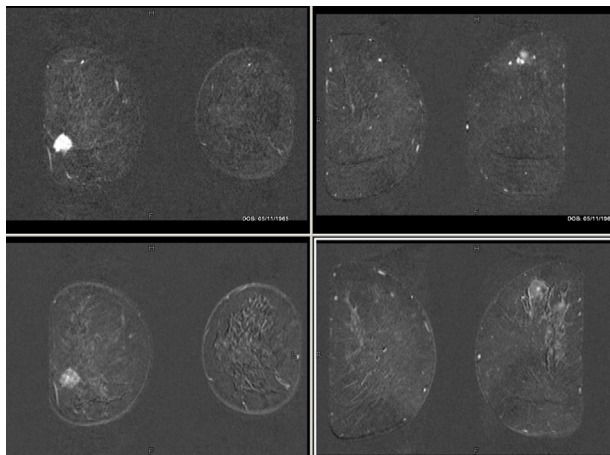


Figure 3. Dynamic Contrast Enhanced MRI Showing Index Lesion in Right Breast. Suspicious lesion with rapid enhancement and early washout on left side. On second look ultrasound revealed ill defined hypoechoic lesion which on subsequent biopsy was diagnosed as infiltrating ductal carcinoma and confirmed presence of malignancy in contralateral breast

index breast lesions was infiltrating ductal carcinoma 61% followed by infiltrating lobular carcinoma in 22%. The others were papillary carcinoma, mucinous carcinoma and DCIS.

On the basis of MRI scan, suspicious findings detected in the contralateral breast were confirmed to be malignant in five patients; this comprised the true positive group. Out of these two were invasive lobular carcinoma (ILC) and one each of invasive ductal carcinoma (IDC), ductal carcinoma in situ (DCIS) and papillary carcinoma. The size of the index lesion in this group ranged from 1 to 5 cm. The size of the lesion in contralateral breast detected on MRI was below 1.0 cm and no axillary lymph node involvement was present.

The false positive MRI of contralateral breast on histopathology was diagnosed as florid ductal hyperplasia, papilloma, apocrine metaplasia, adenosis and fibrocystic change.

The diagnostic performance of breast MRI for detection of lesions in contralateral breast and in the ipsilateral breast in the present study as shown in Table 1.

Discussion

Breast MRI is an expensive test, reported to have high sensitivity (94-100%) but low specificity that ranges from 37-97% (Orel and Schnall, 2001). These factors restricts its usage as a screening modality for the population and hence it is utilized for limited indications like women with genetic predisposition, strong family history /personal history of breast cancer, women with lobular carcinoma or atypia, etc (Tilanus-Linthorst et al., 2000). Analysis of the MRI detected enhancing lesions in accordance to the American college of Radiology breast imaging reporting and data system (BIRADS) lexicon is an essential factor in improving the diagnostic performance. (Abdulkareem, 2014).

In this retrospective study we evaluated the diagnostic performance of breast MRI in the detection of an otherwise occult contra lateral breast cancer in addition to multifocal

/multicentric lesions (Table 1). Additional cancer foci that are histologically proven are reported in 21 to 63 % of women with clinical diagnosis of localized cancer and further confirmed by imaging (Houssami et al., 2008) In this study cancer was detected in contralateral breast in patients with diagnosed breast cancer in 10 % which is in line with the various published reports in literature (3% - 24%) (Lehman et al., 2007) In Asian population however synchronous bilateral cancer ranges from 1.5 -2% (Kim et al., 2012) which is much lower than our study. The detection rate of multifocal /multicentric lesions in the present study is 12% and is in the range as stated in previous studies i.e. 2.4 to 30 % (Berg et al., 2004; Pediconi et al., 2007) (Table 2)

The breast cancer screening programme is non-existent in our country and majority of patients present with palpable tumors as is also evident in our study. In our study 78% of our patients, the index lesion at the time of presentation was in the range of 1 to 5 cm. Increase size of index tumor is identified as a correlate for the increased frequency of additional malignant foci in ipsilateral and contralateral breast. (Moon et al., 2002)

In the present study the index and the contralateral lesions showed similar histology in 80 % cases. (Liberian et al., 2003) reports concordant histology in 67% of women. Early age at initial diagnosis, family history of breast cancer and a lobular histology have been identified as risk factors associated with development of contralateral breast cancer in women with a known primary of breast. The two risk factors i.e. early age at diagnosis and lobular histology is also noted in our patients with synchronous bilateral breast cancer. (Chen et al., 1999; Ji and Hemminki, 2007)

An important risk factor associated with breast cancer is the mammographic density, the principal mechanism likely to be masking rather than rapid tumor growth (Wang et al., 2012). In such cases alternative imaging techniques are likely to enhance detection of occult / additional cancer (Boyd et al., 2007).

The specificity of MRI in the evaluation of contralateral breast in our study is 97.7% and is at the higher side of that reported in literature (37-97%). (Orel and Schnall , 2001) The proposed reason for this is because sonographic correlate was found in 62 % of the lesions detected on MRI. The results are similar to the study by Kim et al which reports detection of ultrasound correlates in 64% and out of these 69% of lesions characterized as masses and 46% as non-mass like enhancement on MRI (Demartini et al., 2009) In the present study none of the enhancing foci less than 5 mm had any ultrasound correlate on second look ultrasound and in the absence of any correlate, MRI was categorized as probably benign finding. All of these patients were stable on follow-up imaging without development of interval malignancy hence confirming the benign nature of the enhancing foci. (Figure 1). In keeping with multiple previous studies (Candelaria and Fornage, 2011), more malignant lesions showed a second look ultrasound correlate than benign lesions. (Figure 2 and 3) Based on the previous reports (Beran et al., 2005) describing the lower probability of malignancy in MRI detected lesions which are occult on ultrasound some sites

also recommend short term imaging follow up.

Breast MRI although being highly sensitive but false negative findings do occur, mostly due to lack of apparent mass as seen with DCIS and lobular carcinoma (Hillman et al., 2012). The false negative cases mostly result from lack of enhancement of lesions or misinterpretation of enhancing lesion. (Millet et al., 2012). In the present study lack of enhancement of lesion being the cause of false negative in the evaluation of multicentric/multifocal disease. There was no false negative case in the MRI screening of contralateral breast in the present study which is also confirmed by stability of the findings on follow up imaging.

The sensitivity and NPV of MRI in the screening of contralateral breast for synchronous lesions is 100% in the present study. This information questions the value of contralateral prophylactic mastectomies (Herrinton et al., 2005) and is expected to influence the decision making by women and breast surgeons regarding the surgical options. In addition it also results in lower rate of cancer recurrence at follow up.

In comparison to contralateral breast, more false positive cases were identified in the ipsilateral breast. Our sample size is small and further studies with large sample size are needed to explain this biological behavior and micro environmental influences (Cichon et al., 2010; Yang et al., 2010).

Several limitations of the study were identified, One of these being small sample size and retrospective design. The non-availability of MRI guided biopsy instruments also added to the limitation of the study. But in the present study, second look ultrasound was performed for all MRI detected lesions by radiologist interpreting the MRI with more than 5 years of experience in breast imaging. Pathological confirmation for all the lesions could not be obtained due to reason described above, but follow-up imaging ranging from 2 to 5 years was available to confirm the benign nature of MRI detected findings without an ultrasound correlate. In the present study the impact of diagnosing additional malignant foci on the treatment and survival of patient are not evaluated.

Our study highlights the diagnostic performance and the added value of contrast enhanced breast MRI in the detection of multifocal /multicentric and contralateral malignant lesions. In patients with diagnosed breast cancer showing dense breast parenchyma on mammography and with infiltrating lobular carcinoma as index lesion MRI is particularly useful with excellent negative predictive value in the exclusion of additional malignant foci in the ipsilateral and contralateral breast.

References

- Abdulkareem ST (2014). Breast magnetic resonance imaging indications in current practice. *Asian Pac J Cancer Prev*, **15**, 569-75.
- American college of Radiologists ACR (2013). American college of radiology practice guidelines for the performance of Magnetic resonance Imaging of the Breast.
- Barchie MF, Clive KS, Tyler, et al (2011). Standardized pretreatment breast MRI-accuracy and influence on mastectomy decisions. *J surg oncol*, **104**, 741-5.
- Beran L, Liang W, Nims T, Paquelet J, Sickie-Santanello B (2005). Correlation of targeted ultrasound with magnetic resonance imaging abnormalities of the breast. *Am J Surg*, **190**, 592-4.
- Berg WA, Gutierrez L, NessAiver MS, et al (2004). Diagnostic accuracy of mammography, clinical examination, US, and MR imaging in preoperative assessment of breast cancer. *Radiol*, **233**, 830-49.
- Beysebayev E, Tulebayev K, Meymanalyev T (2014). Breast cancer diagnosis by mammography in Kazakhstan-staging results of breast cancer with double reading. *Asian Pac J Cancer Prev*, **16**, 31-4.
- Boyd NF, Guo H, Martin LJ, et al (2007). Mammographic density and the risk and detection of breast cancer. *N Engl J Med*, **356**, 227-36.
- Candelaria R, Fornage BD (2011). Second-look us examination of MR-detected breast lesions. *J Clin Ultrasound*, **39**, 115-21.
- Chen Y, Thompson W, Semenciw R, Mao Y (1999). Epidemiology of contralateral breast cancer. *Cancer Epidemiol Biomarkers Prev*, **8**, 855-61.
- Cichon MA, Degnim AC, Visscher DW, Radisky DC (2010). Microenvironmental influences that drive progression from benign breast disease to invasive breast cancer. *J Mammary Gland Biol Neoplasia*, **15**, 389-97.
- DeMartini WB, Eby PR, Peacock S, Lehman CD (2009). Utility of targeted sonography for breast lesions that were suspicious on MRI. *AJR Am J Roentgenol*, **192**, 1128-34.
- Duygulu G, Oktay A, Bilgen IG, Kapkac M, Zekioglu O (2012). The role of breast MRI in planning the surgical treatment of breast cancer. *Diagn Interv Radiol*, **18**, 460-7.
- Esserman L, Hylton N, Yassa L, et al (1999). Utility of magnetic resonance imaging in the management of breast cancer: evidence for improved preoperative staging. *J Clin Oncol*, **17**, 110-19.
- Heron DE, Komarnicky LT, Hyslop T, Schwartz GF, Mansfield CM (2000). Bilateral breast carcinoma: risk factors and outcomes for patients with synchronous and metachronous disease. *Cancer*, **88**, 2739-50.
- Herrinton LJ, Barlow WE, Yu O, et al (2005). Efficacy of prophylactic mastectomy in women with unilateral breast cancer: a cancer research network project. *J Clin Oncol*, **23**, 4275-86.
- Hillman BJ, Harms SE, Stevens G, et al (2012). Diagnostic performance of a dedicated 1.5-T breast MR imaging system. *Radiol*, **265**, 51-58.
- Houssami N, Ciatto S, Macaskill P, et al (2008). Accuracy and surgical impact of magnetic resonance imaging in breast cancer staging: systematic review and meta-analysis in detection of multifocal and multicentric cancer. *J Clin Oncol*, **26**, 3248-58.
- Ji J, Hemminki K (2007). Risk for contralateral breast cancers in a population covered by mammography: effects of family history, age at diagnosis and histology. *Breast Cancer Res Treat*, **105**, 229-36.
- Jobsen JJ, Van der Palen J, Ong F, Meerwaldt JH (2003). Synchronous, bilateral breast cancer: prognostic value and incidence. *Breast*, **12**, 83-8.
- Kim AH, Kim MJ, Kim EK, Park BW, Moon HJ (2014). Positive predictive value of additional synchronous breast lesions in whole-breast ultrasonography at the diagnosis of breast cancer: clinical and imaging factors. *Ultrasonography*, **33**, 170-7.
- Kim TH, Kang DK, Jung YS, Kim KS, Yim H (2012). Contralateral enhancing lesions on magnetic resonance imaging in patients with breast cancer role of second-

- look sonography and imaging findings of synchronous contralateral cancer. *J Ultrasound Med*, **31**, 903-13.
- Kowalchik KV, Vallow LA, McDonough M, et al (2012). The role of preoperative bilateral breast magnetic resonance imaging in patient selection for partial breast irradiation in ductal carcinoma in situ. *Int J Surg Oncol*, 206342.
- Kneeshaw PJ, Turnbull LW, Smith A, Drew PJ (2003). Dynamic contrast enhanced magnetic resonance imaging aids the surgical management of invasive lobular breast cancer. *Eur J Surg Oncol*, **29**, 32-7.
- Lehman CD, Gatsonis C, Kuhl CK, et al (2007). MRI evaluation of the contralateral breast in women with recently diagnosed breast cancer. *N Engl J Med*, **356**, 1295-303.
- Liberman L, Morris EA, Kim CM, Kaplan JB, et al (2003). MR imaging findings in the contralateral breast of women with recently diagnosed breast cancer. *AJR Am J Roentgenol*, **180**, 333-41.
- Liberman L, Morris EA, Lee MJY, et al (2002). Breast lesions detected on MR imaging: features and positive predictive value. *AJR Am J Roentgenol*, **179**, 171-8.
- Millet I, Pages E, Hoa D, et al (2012). Pearls and pitfalls in breast MRI. *Br J Radiol*, **85**, 197-207.
- Moon WK, Noh DY, Im JG (2002). Multifocal, multicentric, and contralateral breast cancers: bilateral whole-breast us in the preoperative evaluation of patients. *Radiol*, **224**, 569-76.
- Orel SG, Schnall MD (2001). MR Imaging of the breast for the detection, diagnosis, and staging of breast cancer 1. *Radiol*, **220**, 13-30.
- Pediconi F, Catalano C, Padula S, et al (2007). Contrast-enhanced magnetic resonance mammography: does it affect surgical decision-making in patients with breast cancer? *Breast Cancer Res Treat*, **106**, 65-74.
- Polednak AP (2003). Bilateral synchronous breast cancer: a population-based study of characteristics, method of detection, and survival. *Surgery*, **133**, 383-9.
- Satake H, Shimamoto K, Sawaki A, et al (2000). Role of ultrasonography in the detection of intraductal spread of breast cancer: correlation with pathologic findings, mammography and MR imaging. *Eur Radiol*, **10**, 1726-32.
- Tilanus-Linthorst MM, Obdeijn IMM, Bartels KC, de Koning HJ, Oudkerk M (2000). First experiences in screening women at high risk for breast cancer with MR imaging. *Breast Cancer Res Treat*, **63**, 53-60.
- Van Goethem M, Schelfout K, Dijckmans L, et al (2004). MR mammography in the pre-operative staging of breast cancer in patients with dense breast tissue: comparison with mammography and ultrasound. *Eur Radiol*, **14**, 809-16.
- Wang FL, Chen F, Yin H, et al (2012). Effects of age, breast density and volume on breast cancer diagnosis: a retrospective comparison of sensitivity of mammography and ultrasonography in China's rural areas. *Asian Pac J Cancer Prev*, **14**, 2277-82.
- Yang JX, Han YJ, Zheng H, Luo RC (2010). Expression of PAK4 in breast cancer and benign breast pathological changes. *J South Med Univ*, **30**, 981-83.
- Yusuf A, Ab Hadi IS, Mahamood Z, Ahmad Z, Keng SL (2013). Understanding the breast cancer experience: a qualitative study of Malaysian women. *Asian Pac J Cancer Prev*, **14**, 3689-98.