

REVIEW

Editorial Process: Submission:09/24/2022 Acceptance:02/12/2023

Value of Conventional MRI, DCE-MRI, and DWI-MRI in the Discrimination of Metastatic from Non-Metastatic Lymph Nodes in Rectal Cancer: A Systematic Review and Meta-Analysis Study

Arvin Arian¹, Hayder Jasim Taher^{2*}, Hayder Suhail Najm Alareer³, Mehdi Aghili⁴

Abstract

Background: Today, despite many studies on the diagnosis of metastasis to lymph nodes (LNs) in Rectal Cancer (RC), its diagnosis is still very challenging for radiologists. The purpose of the present study was to the assessment of the diagnostic value of conventional MRI, DCE-MRI, and DWI-MRI in the discrimination of metastatic from non-metastatic lymph nodes in RC. **Methods:** In the present meta-analysis study, we surveyed international databases including PubMed, Scopus, Embase, and Science Direct with appropriate keywords. Using the binomial distribution formula, the variance of each study was calculated and the data were analyzed using STATA version 14. Finally, the results of the studies were entered into the random-effects meta-analysis. Also, we used the chi-squared test and I2 index to calculate heterogeneity among studies, and for evaluating publication bias, Funnel plots and Egger tests were used. **Results:** 31 articles published between 2005 and 2021, comprising 2517 patients were included in the present study. The sensitivity and specificity of DCE-MRI were 83% (74% to 80%), and 86% (80% to 93%), respectively with PPV 84% (76% to 89%) and NPV 88% (79% to 95%). Also, the sensitivity and specificity of DWI-MRI were 81% (74% to 88%), and 74% (78% to 91%), respectively with PPV 63% (54% to 74%), NPV 85% (77% to 93%), AUC 80% (75% to 86%) and accuracy 82% (75% to 88%). For conventional MRI, the sensitivity 74% (67% to 80%), specificity 77% (71% to 83%), PPV 62% (48% to 69%), NPV 70% (62% to 77%), AUC 78% (72% to 83%) and 71% accuracy (68% to 78%) was obtained. **Conclusion:** Based on our finding DCE-MRI is the most suitable technique for the discrimination of metastatic lymph nodes in rectal cancer.

Keywords: DCE-MRI- DWI-MRI- discrimination- rectal cancer

Asian Pac J Cancer Prev, 24 (2), 401-410

Introduction

Rectal cancer (RC) with an incidence of 40,000 cases per year is the second most common cancer in the United States (Siegel et al., 2020). It is predicted that the incidence of RC will increase soon. The incidence is presently estimated at 125,000 cases per year (15-25 cases per 100,00) in EU countries (Glynn-Jones et al., 2017).

The existence of nodal metastases is one of the essential prognostic factors in RC. Previous studies have reported that patients with pN2 nodal involvement have a shorter life expectancy (Chang et al., 2007). Therefore, the existence of metastasis to lymph nodes is decisive for predicting the prognosis of the disease, and the status of lymph nodes is an important factor in deciding the

requirement for adjuvant chemotherapy after surgical resection (Chang et al., 2007; Karjol et al., 2020).

Recently, many advances have been made in rectal cancer imaging. In order to staging purposes, magnetic resonance imaging (MRI) has a fundamental diagnostic role in the evaluation of primary RC (Surov et al., 2021). Because of MRI's ability to deliver high-resolution images is the most precise imaging modality for evaluation of tumor stage (T-stage), lymph node visualization for primary lymph node (N) staging, and circumferential resection margin (CRM) for locally progressive tumors (Alberda et al., 2013). Using a combination of endoscopy and imaging, tumor height can be accurately evaluated. MRI is a valuable technique for assessing tumor invasion of the mesorectal fascia ("Diagnostic accuracy of preoperative

¹MD Radiology, TUMS (Cancer Institute-ADIR), Tehran University of Medical Sciences (TUMS), Tehran, Iran. ²Technology of Radiology and Radiotherapy Department, Tehran University of Medical Sciences, International Campus, Tehran, Iran. ³Radiology Department, Collage of Health & Medical Technology, Al-Ayen University, Thi-Qar, Iraq. ⁴Department of Radiation Oncology, Cancer Institute, Imam Khomeini Hospital Complex, Tehran University of Medical Sciences, Tehran, Iran. *For Correspondence: haiderdr75@gmail.com

magnetic resonance imaging in predicting curative resection of rectal cancer: prospective observational study,” 2006; Kaur et al., 2012).

Recently, several novel imaging methods have been investigated to further improve MRI-based staging of RC. One of the newest techniques used in the spectrum of MR imaging in RC is dynamic contrast-enhanced (DCE) MRI. This technique can assess tumor vascularity, which provides valuable data about tumor invasiveness and degree of angiogenesis and aid re-staging of RC. DCE-MRI is presently used in breast and prostate cancer imaging to recognize malignant tumors based on specific enhancement patterns (Dijkhoff et al., 2017; Rosenkrantz et al., 2013).

DCE-MRI may have additional diagnostic value in differentiating malignant from non-malignant tissue, because of malignant tissue reveals specific enhanced contrast patterns due to neo angiogenesis, which increases perfusion and permeability in patients without neoadjuvant therapy (Rudisch et al., 2005).

Some past studies reported that diffusion-weighted imaging (DWI) is a more suitable technique for tumor detection and tumor identification than conventional MRI (Le Bihan, 2013). Maybe, due to its relationship with cellularity and microvasculature, DWI may be helpful for differentiating metastatic from non-metastatic lymph nodes as it can mirror specific histopathological differences between these cases (Surov et al., 2021).

DW-MRI, a component of functional MRI, is capable of investigative biological properties such as tissue cellularity and water content. It provides tissue properties and image contrast as determined by Apparent Diffusion Coefficient (ADC). The ADC is usually used as a measure of diffusion instead of the diffusion coefficient in biological systems. It has been reported that this quantitative biomarker is useful in differentiating benign from malignant lesions as well as detecting some histopathological features (Schnapauff et al., 2009) Areas with low ADC values have been reported to reflect dense cellular structures. A study reported that limited diffusion in RC as demonstrated by DW-MRI was related with an aggressive tumor profile (Curvo-Semedo et al., 2012).

Therefore, the objective of the present study was to investigate the value of MRI, DCE-MRI, and DWI in the discrimination of metastatic lymph nodes in RC.

Materials and Method

The present meta-analysis and systematic review was conducted based on the PRISMA statement (Liberati et al., 2009).

Search strategies

In the present study, a comprehensive literature search was conducted regarding the evaluation of the accuracy of MRI in distinguishing metastatic from non-metastatic lymph nodes. The search was done using international databases and search engines including PubMed, Medline, Embase, Scopus, and Web of Science. Keywords such as rectal cancer, High-resolution MRI, Lymph nodes, MRI, High-resolution MRI, Lymphatic metastasis,

Apparent diffusion coefficient, Diffusion-weighted magnetic resonance imaging, and size criterion were used in different possible combinations using AND, OR. References of collected studies were also checked for any uncovered study. Titles and abstracts of all studies were checked to select relevant studies. All authors contributed to the searching part.

Studies selection

In order to find out the eligible studies, the following inclusion criteria were considered:

1. Original studies on people with biopsy-confirmed rectal cancer.
2. Studies that examined lymph nodes using MRI.
3. Studies without patients with remote metastases or unresectable primary tumors.

The exclusion criteria were studies lacking the sensitivity and specificity of MRI. Qualitative and descriptive studies. Abstract articles, articles presented in the conference, systematic review, and meta-analysis. Studies published in non-English language publications.

In the first step, the titles and abstracts of all collected articles were listed by two authors. The list was investigated to choose the relevant topics separately. Duplicate titles and articles with duplicate data were then excluded. Afterward, the selected articles were considered in the research process. In the last step, the articles were checked and evaluated by other authors.

Screening and data extraction

Two reviewers independently assessed identified articles considering inclusion and exclusion criteria. Initially, articles were screened by title and abstract. Then, these two authors evaluated selected articles by their full text. The articles selected by both of our reviewers were included in our article. If only one of our reviewers selected a study, a third reviewer evaluated that article to include in our study. Finally, included studies data were extracted by two independent authors. The following information was considered to be extracted: first author, authors' country, year of publication, study design, sample size, age, specificity, sensitivity, negative predictive value (NPV), positive predictive value (PPV), accuracy, and area under the curve (AUC). When there was a disagreement between the extracted data, all discrepant items were assessed by a third author.

Risk of bias in individual studies (Quality assessment)

The studies quality was evaluated with the Quality Assessment of Diagnostic Accuracy Studies 2 (QUADAS-2) in four main domains included patient selection, 'index test', 'reference standard', and 'flow and timing'. These are evaluated with responses of "yes," "no," and "uncertain," of seven "signaling questions" (eg, was the control case design evaded). These responses were used to assess the risk of bias and applicability of the research. The articles were grouped based on their score into high (6-7 points), moderate (4-5 points), and low (0-3 points) quality categories (Figure 2) (Whiting et al., 2011).

Risk of bias across studies

For the estimation of publication bias, the Begg's and Egger test was used.

Statistical analysis

the effect size and the 95% CI were calculated using Stata version 17. Also, the publication bias was assessed using Begg's test. We measured the heterogeneity of each group using the inconsistency index (I²). An I² greater than 50% or a P-value lower than 0.05 is recognized as significant heterogeneity. If the heterogeneity were high, a random-effect model was used to calculate the pooling effect and 95% CI. Otherwise, the fixed effect was used. The for characteristic metastatic from non-metastatic lymph nodes was determined by calculating pooled specificity, sensitivity, PPV, NPV, accuracy, and AUC with 95% confidence intervals (CI).

Results

After removing duplicate and irrelevant studies, finally, 31 articles aligned with the inclusion criteria, published between 2005 and 2021, were included in the study (Table 1). The steps of selecting the studies are shown in Figure 1. This meta-analysis includes 16

prospective articles, 13 retrospective articles, and 2 cross-sectional articles. A total of 2,517 people were examined. The average age of the investigated subjects was 59.2 years and the age range was 25 to 88 years. 63.3% of people were men and 36.7% were women. In 12 articles, patients were studied with a conventional MRI device, in 10 articles with a DWI-MRI device, and in 7 articles with a DCE-MRI device. Also, CMT-MRI machine was used in one study and a D-MRI device was used in another study. In 11 articles, the criterion for distinguishing metastatic from non-metastatic lymph nodes was lymph node size, in 15 articles, apparent diffusion coefficient (ADC) was used, lymph node eradication in 2 articles, Ktrans in 2 articles, and T2 apping in 1 article. The publication bias was shown symmetrically in the funnel diagram, and the P-value was calculated as 0.092, means that there is a publication bias. (Figure 3).

In terms of the quality of studies, 25 articles with good quality and 6 articles with average quality were included in the study. 12 articles met all QUADAS-2 core criteria. 13 articles scored only 1 point for the risk of bias component (42%). Only 1 article (3.2%) scored 4. Most of the studies scored 3 points in the applied component (65%). 12% of the fields had an "uncertain" answer. "Uncertain" answers were reported in the sections of the index test

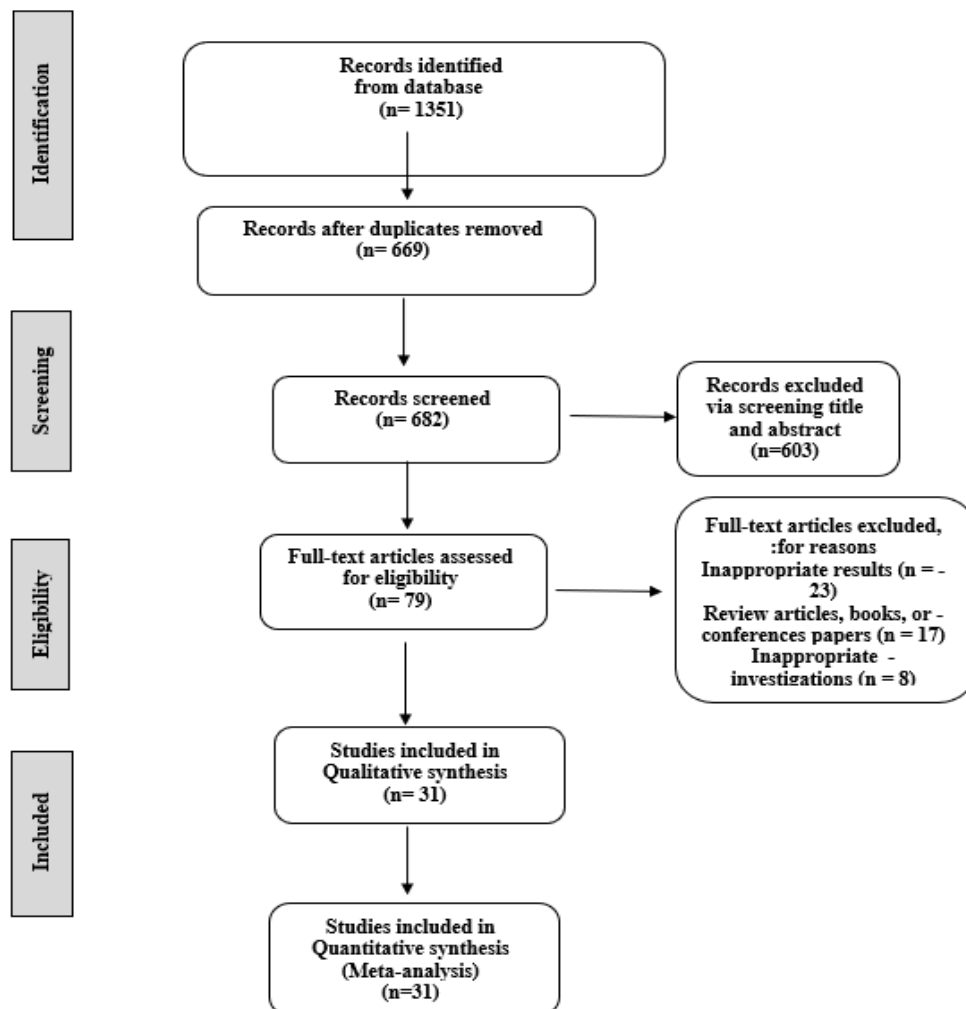


Figure 1. PRISMA Diagram of Studies

Table 1. Characteristics of the Studies Reviewed in the Present Study

| Author Ref | Year | Country | Sample Size | Age (range) | Age (m) | Study design | Diagnosis criteria | Imaging modality | Cut-off value |
|-------------------------|------|-------------|-------------|-------------|---------|-----------------|--|------------------|---|
| Alberda WJ (2016) | 2012 | Netherlands | 55 | 33-78 | | Retrospective | size criterion | DCE-MRI | |
| Amin F G (2108) | 2016 | Egypt | 75 | 20-65 | 40 | Prospective | LN ADC | DWI- MRI | |
| Armbruster M (2010) | 2018 | Germany | 22 | 40.5-84.7 | 63.7 | Prospective | size criterion | DCE-MRI | >5 mm |
| Baumann T (2013) | 2010 | Germany | 128 | 25-80 | | Retrospective | size criterion | CMT MRI | >10 mm |
| Cho E Y(2015) | 2013 | Koreaa | 34 | 37-82 | 62.7 | Retrospective | size criterion & LN ADC | DWI- MRI | 3/8 mm 1/0 ×10 ³ mm ² /s |
| Choi J (2013) | 2015 | Koreaa | 160 | 20-85 | 59.7 | Retrospective | size criterion | MRI | 4/1 mm |
| Elmi A (2020) | 2013 | USA | 49 | | 59.8 | Retrospective | LN ADC | | 0.883 ×10 ³ mm ² /s |
| Fornell-Perez R (2006) | 2019 | Spain | 46 | 40-81 | 61.4 | Cross-sectional | morphological criteria & size criterion | DWI- MRI | |
| Harisinghani M G (2013) | 2005 | USA | 77 | | | Cross-sectional | size criterion | DCE-MRI | |
| Heijnen L A (2021) | 2013 | Netherlands | 14 | | | Retrospective | LN ADC | DWI- MRI | |
| Kargol J (2014) | 2021 | Poland | 103 | | | Retrospective | | MRI | |
| Kim S H (2020) | 2014 | Koreaa | 53 | 34-79 | 58 | Retrospective | size criterion & LN ADC | MRI | 4.8 mm 1.25×10 ³ mm ² /s |
| Li F (2011) | 2019 | China | 21 | | | Prospective | LN ADC | MRI | 1.0×10 ³ mm ² /s |
| Mizukami Y (2016) | 2011 | Japan | 129 | 36-89 | | Retrospective | nodules with high signal intensity | DWI- MRI | |
| OGAWA M (2016) | 2016 | Japan | 119 | 39-79 | 58 | Prospective | size criterion | D-MRI | >10 mm |
| Qiu L (2016) | 2016 | China | 68 | 25-86 | 57.7 | Prospective | LN ADC | MRI | 0.8×10 ³ mm ² /s |
| Ryu K H (2014) | 2015 | Koreaa | 95 | 32-82 | 59 | Prospective | LN eradication | DWI- MRI | |
| Vag T (2017) | 2014 | Germany | 9 | | 65 | Retrospective | size criterion | DCE-MRI | 6mm |
| Van Heeswijk M M (2021) | 2016 | Netherlands | 90 | 31-80 | | Retrospective | LN eradication | DWI- MRI | |
| Xian M F (2019) | 2021 | China | 87 | | | Prospective | morphological criteria & high signal intensity | MRI | |
| Yang X (2019) | 2019 | China | 197 | | 59.7 | Prospective | LN ADC | DWI- MRI | 0.555×10 ³ mm ² /s |
| Yang X (2020) | 2018 | China | 122 | | 58.9 | Prospective | K _{trans} | DCE-MRI | 0.088 min ⁻¹ |
| YILDIRIM M (2021) | 2020 | TURKEY | 36 | 39-87 | | Prospective | LN ADC | DWI- MRI | 1.33×10 ³ mm ² /s |
| Li Ch (2016) | 2012 | China | 162 | | 63.8 | Retrospective | LN ADC | DWI- MRI | |
| Yu X P (2016) | 2016 | China | 32 | 35-73 | 56 | Prospective | LN ADC | MRI | 0.667×10 ³ mm ² /s |
| Grovik E (2021) | 2016 | Norway | 17 | 50-88 | | Prospective | K _{trans} | DCE-MRI | |
| Ge Y X (2021) | 2020 | China | 134 | | | Prospective | T2 apping | DCE-MRI | 77ms |
| Yuan Y (2021) | 2020 | China | 61 | | 57.5 | Prospective | LN ADC | MRI | 1.209×10 ³ mm ² /s |
| Zhao L (2014) | 2021 | China | 95 | | 58/03 | prospective | LN ADC | MRI | |
| Zhou J (2021) | 2014 | China | 52 | | 63 | prospective | size criterion | MRI | |
| Zhou Y (2017) | 2021 | China | 175 | | 58/86 | Retrospective | LN ADC | MRI | |

Table 2. Sensitivity, Specificity, PPV, PPV, AUC and Accuracy of MRI in Distinguishing Metastatic from Non-Metastatic Lymph Nodes

| | (%)interval 95% Confidence | | |
|-------------|-----------------------------|-------------|-------------|
| | Mean | Lower limit | Upper limit |
| Sensitivity | 78% | 75% | 81% |
| Specificity | 78% | 74% | 83% |
| PPV | 68% | 61% | 74% |
| NPV | 80% | 76% | 84% |
| AUC | 81% | 77% | 84% |
| Accuracy | 79% | 75% | 83% |

and the standard area of reference for assessing the risk of bias because of these studies did not obviously report the details of the blinded evaluation (Figure 4).

Findings of the present study conducted to investigate the efficiency of MRI in differentiating metastatic from non-metastatic lymph nodes, sensitivity 78% (75% to 81%), specificity 78% (74% to 83%), PPV 68% (61% to 74%), NPV 80% (76% to 84%), AUC 81% (77% to 84%) and accuracy 79% (75% to 83%) were obtained (Table 2 and Figures 4-7). Also, finding of subgroup analysis based on the criteria for metastatic from non-metastatic lymph nodes: lymph node eradication subgroup showed the highest sensitivity and accuracy (Table 3).

Table 4. Sensitivity, specificity, PPV, NPV, AUC and accuracy according to MRI type

| MRI | Number of studies | Sensitivity (95% CI) | Specificity (95% CI) | PPV (95% CI) | NPV (95% CI) | AUC (95% CI) | Accuracy (95% CI) |
|------------------|-------------------|----------------------|----------------------|------------------|------------------|------------------|-------------------|
| MRI Conventional | 14 | 74% (67% to 80%) | 77% (71% to 83%) | 62% (48% to 69%) | 70% (62% to 77%) | 78% (72% to 83%) | 71% (68% to 78%) |
| DWI- MRI | 13 | 81% (74% to 88%) | 74% (78% to 91%) | 63% (54% to 74%) | 85% (77% to 93%) | 80% (75% to 86%) | 82% (75% to 88%) |
| DCE-MRI | 10 | 83% (74% to 80%) | 86% (80% to 93%) | 84% (76% to 89%) | 88% (79% to 95%) | - | - |

Table 3. Sensitivity, Specificity, PPV, NPV, AUC, and Accuracy based on Criteria for Distinguishing Metastatic from Non-Metastatic Lymph Nodes

| Diagnosis criteria | Number of studies | Sensitivity (95% CI) | Specificity (95% CI) | PPV (95% CI) | NPV (95% CI) | AUC (95% CI) | Accuracy (95% CI) |
|------------------------|-------------------|----------------------|----------------------|------------------|------------------|------------------|-------------------|
| Size criteria | 13 | 76% (71% to 81%) | 76% (77% to 88%) | 75% (66% to 83%) | 85% (80% to 90%) | 80% (75% to 85%) | 79% (71% to 88%) |
| ADC | 16 | 77% (70% to 83%) | 77% (70% to 83%) | 60% (50% to 70%) | 75% (67% to 83%) | 81% (76% to 86%) | 78% (71% to 84%) |
| Lymph node eradication | 3 | 82% (72% to 93%) | 56% (44% to 63%) | to (36% to 96%) | 75% (67% to 83%) | - | 80% (76% to 85%) |




Figure 2. Checking the Quality of Included Studies

Conventional MRI

The sensitivity 74% (67% to 80%), specificity 77% (71% to 83%), PPV 62% (48% to 69%), NPV 70% (62% to 77%), AUC 78% (72% to 83%) and 71% accuracy (68% to 78%) was obtained.

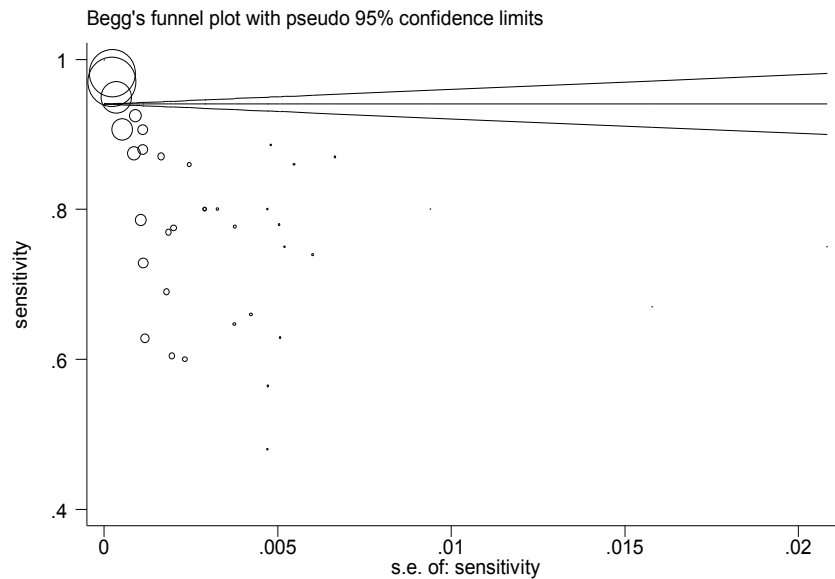


Figure 3. Publication Bias Diagram in the Studies, the Circles Show the Weight of the Studies

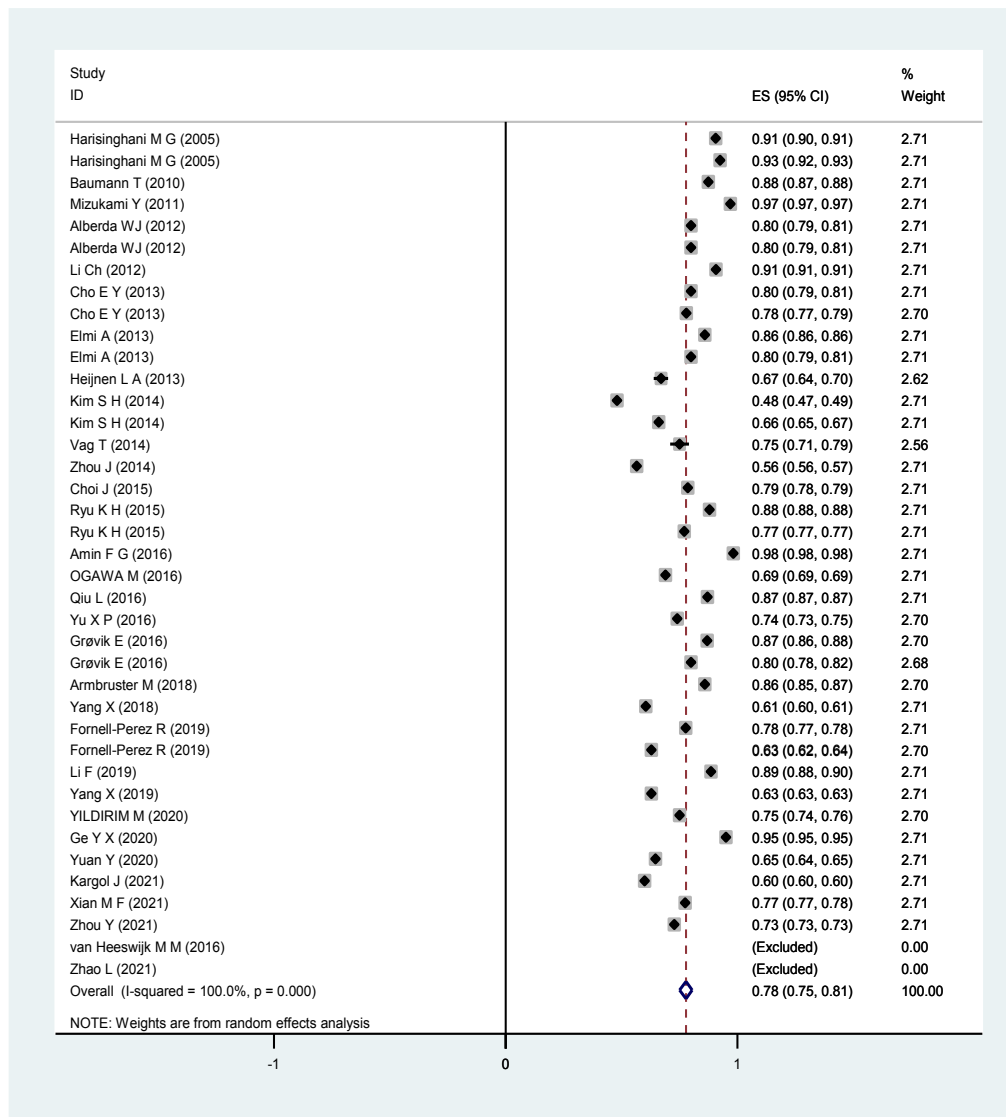


Figure 4. MRI Sensitivity in Detecting Metastatic Lymph Nodes. The square reflects the effect estimate of each study with over 95% CI with the square sizes proportionate to the weight allocated to the study within the meta-analysis

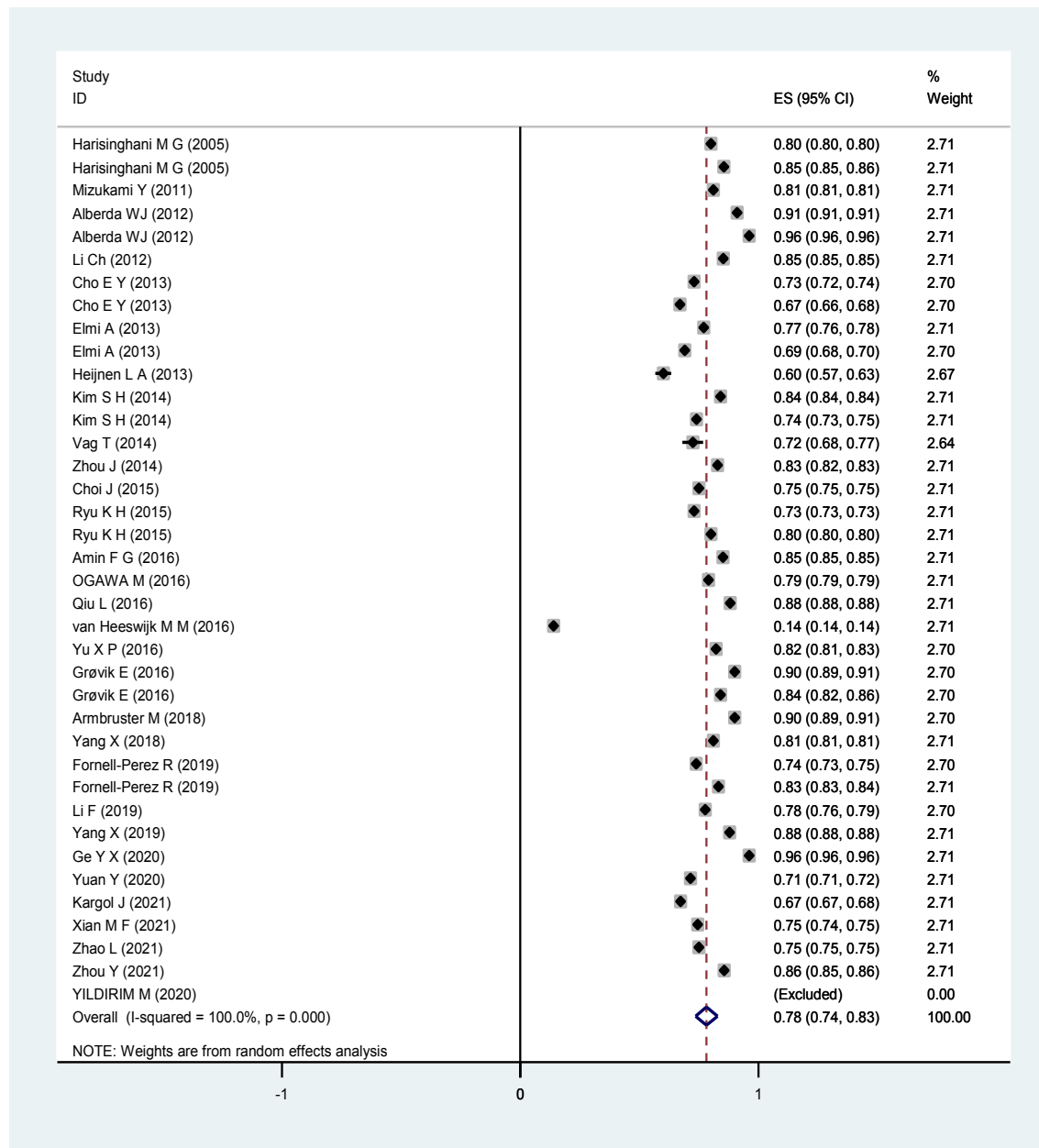


Figure 5. Specificity of MRI in the Diagnosis of Metastatic Lymph Nodes. The square reflects the effect estimate of each study with over 95% CI with the square sizes proportionate to the weight allocated to the study within the meta-analysis

DWI-MRI

The sensitivity 81% (74% to 88%), specificity 74% (78% to 91%), PPV 63% (54% to 74%), NPV 85% (77% to 93%), AUC 80 % (75% to 86%) and accuracy 82% (75% to 88%) were obtained.

DCE-MRI

The sensitivity 83% (74% to 80%), specificity 86% (80% to 93%), PPV 84% (76% to 89%) and NPV 88% (79% to 95%).

Discussion

Although the role of DWI and DCE-MRI is promising for discrimination between metastatic from non-metastatic

lymph nodes in RC, the findings from either of these methods alone presently lack adequate precision and standardization to be usually used to change clinical patient management. Most of the past studies have measured single parameter values from diffusion or perfusion MRI, such as the average ADC or Ktrans of the pixels in the ROI, which alone cannot reflect tumor heterogeneity (Pham et al., 2017). Also, considering that small (5 mm) mesorectal lymph nodes in patients with RC may contain metastases, it is necessary to consider how they can be detected by MR imaging with high spatial resolution (Pham et al., 2017).

We investigated the value of MRI, DCE-MRI, and DWI in the discrimination of metastatic lymph nodes in RC. The results showed that the DCE-MRI technique is the

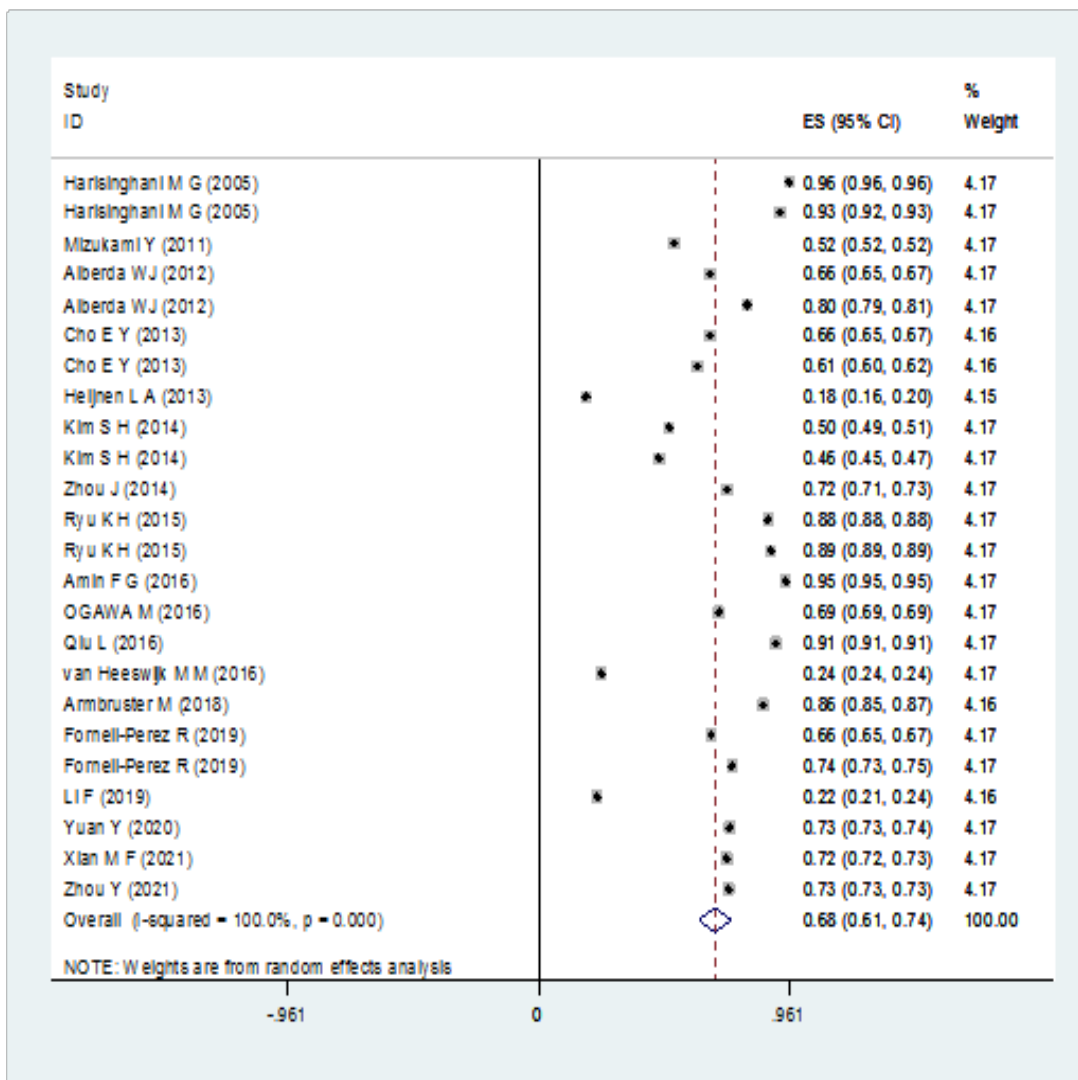


Figure 6. PPV of MRI in the Diagnosis of Metastatic Lymph nodes. The square reflects the effect estimate of each study with over 95% CI with the square sizes proportionate to the weight allocated to the study within the meta-analysis

most sensitive and specific method with an acceptable PPV and NPV for the discrimination of metastatic lymph nodes in RC. Also, the results of subgroup analysis based on the criteria for discrimination metastatic from non-metastatic lymph nodes showed the lymph node eradication subgroup has the highest sensitivity and accuracy.

Previous studies have shown that DWI can aid in the visual examination for qualitative analysis. Mir et al., (2010) showed DWI has a high sensitivity for detecting small lymph nodes and metastatic lymph nodes when used with T2WI for RC. But prior animal studies discovered that both metastatic and non-metastatic lymph nodes could display high signal intensities (SI) on DWI, which shows that DWI alone is not qualitatively adequate for a precise interpretation. Also, considering that the use of DWI alone can lead to overdiagnosis of lymph nodes metastasis. So, lymph nodes that showing clear SI on DWI in RC should be interpreted carefully (Kim et al., 2012).

Mizukami et al., (2011) study showed that conventional DWI + MRI is highly effective for detecting lymph node metastasis and can be used to select the optimal treatment

for RC.

A meta-analysis study conducted by Al-Sukhni et al., (2012), showed that although the evaluation of lymph nodes in MRI is poor, it is highly accurate for peripheral resection margin (CRM) involvement and T category, and it can be considered for rectal cancer staging before surgery. Also, another meta-analysis study conducted by Zhang et al., (2016), Reported the same results and mentioned that MRI should be reliable for clinical decision-making for rectal cancer patients. In contrast to the results of these studies and the present study, some previous studies have shown that although new magnetic resonance imaging methods have made significant improvements in the diagnosis of RC nodal disease, the performance is still unreliable for clinical decision-making (Kim et al., 2011; Zhou et al., 2022). Wei et al., (2020) conducted a study with the aim of investigating the diagnostic precision of MRI for RC. The results of the study showed that MRI is a very accurate diagnostic tool for RC staging T3-T4 and N staging, but its sensitivity and specificity are low. The finding of the Song et al., (2020)

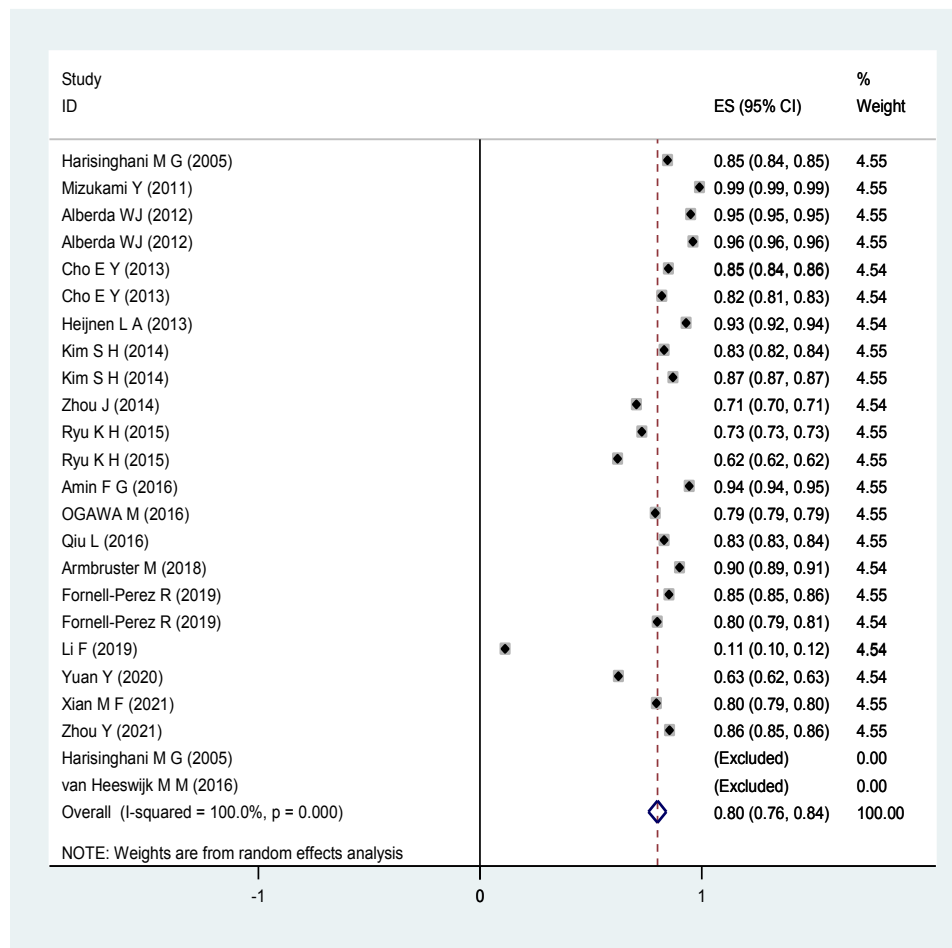


Figure 7. NPV of MRI in the Diagnosis of Metastatic Lymph nodes. The square reflects the effect estimate of each study with over 95% CI with the square sizes proportionate to the weight allocated to the study within the meta-analysis

's study showed that texture features derived from T2WI were valuable in predicting N stage for patients with RC. Liu et al., (2017)'s study revealed that histogram texture features obtained from ADC maps were connected with extramural invasion in rectal tumors.

The limitations of our study, it can be mentioned that in spite of the comprehensive search of the literature, the limit of articles in the English language and the neglect of unpublished studies may have caused potential publication bias.

In conclusion, the findings showed that DCE-MRI is the best technique to differentiate between metastatic from non-metastatic lymph nodes in RC. Regarding the sensitivity and specificity, the use of DCE-MRI can increase the diagnostic performance in monitoring RC treatment.

Abbreviations

RC: Rectal cancer
MRI: Breast magnetic resonance imaging
DWI: Diffusion-weighted imaging
QUADAS-2: Quality Assessment of Diagnostic

Author Contribution Statement

HT, AA designed the conception of the study; HT, AA

focus on the statistical analysis; HA, MA, HT technical support and conceptual advice. All authors contributed to the draft of the manuscript, revised it critically, and approved the final version.

Acknowledgments

The authors extend their gratitude to the Tehran University of Medical Sciences. Accuracy Studies-2.

Availability of data and Materials

All data generated or analyzed during this study are included in this published article.

Conflict of interest

The authors declare that they have no conflict of interests.

References

- Albritton RB (1999). Political diversity among Muslims in Thailand. *Asian Studies Rev*, **23**, 233-46.
- Antoniou AC, Casadei S, Heikkinen T, et al (2014). Breast-cancer risk in families with mutations in PALB2. *N Engl J Med*, **371**, 497-506.
- Armstrong N, Ryder S, Forbes C, et al (2019). A systematic

- review of the international prevalence of BRCA mutation in breast cancer. *Clin Epidemiol*, **11**, 543-61.
- Asphaug L, Melberg HO (2019). The Cost-Effectiveness of Multigene Panel Testing for Hereditary Breast and Ovarian Cancer in Norway. *MDM Policy Pract*, **4**, 2381468318821103.
- Buys SS, Sandbach JF, Gammon A, et al (2017). A study of over 35,000 women with breast cancer tested with a 25-gene panel of hereditary cancer genes. *Cancer*, **123**, 1721-30.
- Catana A, Apostu AP, Antemie RG (2019). Multi gene panel testing for hereditary breast cancer - is it ready to be used?. *Med Pharm Rep*, **92**, 220-5.
- de Souza Timoteo AR, Goncalves A, Sales LAP, et al (2018). A portrait of germline mutation in Brazilian at-risk for hereditary breast cancer. *Breast Cancer Res Treat*, **172**, 637-46.
- Ghoncheh M, Pournamdar Z, Salehiniya H (2016). Incidence and Mortality and Epidemiology of Breast Cancer in the World. *Asian Pac J Cancer Prev*, **17**, 43-6.
- Gonzalez-Angulo AM, Timms KM, Liu S, et al (2011). Incidence and outcome of BRCA mutations in unselected patients with triple receptor-negative breast cancer. *Clin Cancer Res*, **17**, 1082-9.
- Iwamoto T, Kajiwara Y, Zhu Y, et al (2020). Biomarkers of neoadjuvant/adjunct chemotherapy for breast cancer. *Chin Clin Oncol*, **9**, 27.
- Julián Esteban Londoño Hernández ML, Gonzalo Vásquez P, Juan David F, et al (2014). Prevalence of BRCA1 and BRCA2 mutations in unselected breast cancer patients from medellín, Colombia. *Hereditary Cancer Clin Pract*, **12**.
- Kaur RP, Shafi G, Benipal RPS, et al (2018). Frequency of pathogenic germline mutations in cancer susceptibility genes in breast cancer patients. *Med Oncol*, **35**, 81.
- Lertwilaiwittaya P, Roothumnong E, Nakthong P, et al (2021). Thai patients who fulfilled NCCN criteria for breast/ovarian cancer genetic assessment demonstrated high prevalence of germline mutations in cancer susceptibility genes: implication to Asian population testing. *Breast Cancer Res Treat*, **188**, 237-48.
- Majeed W, Aslam B, Javed I, et al (2014). Breast cancer: major risk factors and recent developments in treatment. *Asian Pac J Cancer Prev*, **15**, 3353-8.
- Manahan ER, Kuerer HM, Sebastian M, et al (2019). Consensus Guidelines on Genetic Testing for Hereditary Breast Cancer from the American Society of Breast Surgeons. *Ann Surg Oncol*, **26**, 3025-31.
- Oranratnachai S, Yamkaew W, Tunteeratum A, et al (2022). Characteristics of breast cancer patients tested for germline BRCA1/2 mutations by next-generation sequencing in Ramathibodi Hospital, Mahidol University. *Cancer Rep (Hoboken)*, **2022**, e1664.
- Piccinin C, Panchal S, Watkins N, et al (2019). An update on genetic risk assessment and prevention: the role of genetic testing panels in breast cancer. *Expert Rev Anticancer Ther*, **19**, 787-801.
- Robson M, Im SA, Senkus E, et al (2017). Olaparib for Metastatic Breast Cancer in Patients with a Germline BRCA Mutation. *N Engl J Med*, **377**, 523-33.
- Sriplung H, Bilheem S, Kuntipundee T, et al (2014). Differences in cancer incidence among predominantly Muslim and Buddhist subpopulations in Songkhla. *Asian Pac J Cancer Prev*, **15**, 9979-83.
- Stenhjem DD, Telford C, Unni SK, et al (2021). BRCA testing and outcomes in women with breast cancer. *Breast Cancer Res Treat*, **186**, 839-50.
- Stucci LS, Interno V, Tucci M, et al (2021). The ATM Gene in Breast Cancer: Its Relevance in Clinical Practice. *Genes (Basel)*, **12**.
- Sun J, Meng H, Yao L, et al (2017). Germline Mutations in Cancer Susceptibility Genes in a Large Series of Unselected Breast Cancer Patients. *Clin Cancer Res*, **23**, 6113-9.
- Thompson EC (2012). Anthropology in Southeast Asia: National Traditions and Transnational Practices. *Asian J Soc Sci*, **40**, 664-89.
- Thorat MA, Balasubramanian R (2020). Breast cancer prevention in high-risk women. *Best Pract Res Clin Obstet Gynaecol*, **65**, 18-31.
- Tung N, Battelli C, Allen B, et al (2015). Frequency of mutations in individuals with breast cancer referred for BRCA1 and BRCA2 testing using next-generation sequencing with a 25-gene panel. *Cancer*, **121**, 25-33.
- Tung N, Lin NU, Kidd J, et al (2016). Frequency of Germline Mutations in 25 Cancer Susceptibility Genes in a Sequential Series of Patients With Breast Cancer. *J Clin Oncol*, **34**, 1460-8.
- Valencia OM, Samuel SE, Viscusi RK, et al (2017). The Role of Genetic Testing in Patients With Breast Cancer: A Review. *JAMA Surg*, **152**, 589-94.
- Virani S, Wetzel EC, Laohawiriyakamol S, et al (2018). Ethnic disparity in breast cancer survival in southern Thai women. *Cancer Epidemiol*, **54**, 82-9.
- Wendt C, Margolin S (2019). Identifying breast cancer susceptibility genes - a review of the genetic background in familial breast cancer. *Acta Oncol*, **58**, 135-46.
- Yoshida R (2020). Hereditary breast and ovarian cancer (HBOC): review of its molecular characteristics, screening, treatment, and prognosis. *Breast Cancer*, **2020**.



This work is licensed under a Creative Commons Attribution-Non Commercial 4.0 International License.